This is a digital copy of a book that was preserved for generations on library shelves before it was carefully scanned by Google as part of a project to make the world's books discoverable online.

It has survived long enough for the copyright to expire and the book to enter the public domain. A public domain book is one that was never subject to copyright or whose legal copyright term has expired. Whether a book is in the public domain may vary country to country. Public domain books are our gateways to the past, representing a wealth of history, culture and knowledge that's often difficult to discover.

Marks, notations and other marginalia present in the original volume will appear in this file - a reminder of this book's long journey from the publisher to a library and finally to you.

Usage guidelines

Google is proud to partner with libraries to digitize public domain materials and make them widely accessible. Public domain books belong to the public and we are merely their custodians. Nevertheless, this work is expensive, so in order to keep providing this resource, we have taken steps to prevent abuse by commercial parties, including placing technical restrictions on automated querying.

We also ask that you:

+ *Make non-commercial use of the files* We designed Google Book Search for use by individuals, and we request that you use these files for personal, non-commercial purposes.

+ *Refrain from automated querying* Do not send automated queries of any sort to Google's system: If you are conducting research on machine translation, optical character recognition or other areas where access to a large amount of text is helpful, please contact us. We encourage the use of public domain materials for these purposes and may be able to help.

+ *Maintain attribution* The Google "watermark" you see on each file is essential for informing people about this project and helping them find additional materials through Google Book Search. Please do not remove it.

+ *Keep it legal* Whatever your use, remember that you are responsible for ensuring that what you are doing is legal. Do not assume that just because we believe a book is in the public domain for users in the United States, that the work is also in the public domain for users in other countries. Whether a book is still in copyright varies from country to country, and we can't offer guidance on whether any specific use of any specific book is allowed. Please do not assume that a book's appearance in Google Book Search means it can be used in any manner anywhere in the world. Copyright infringement liability can be quite severe.

About Google Book Search

Google's mission is to organize the world's information and to make it universally accessible and useful. Google Book Search helps readers discover the world's books while helping authors and publishers reach new audiences. You can search through the full text of this book on the web at `http://books.google.com/`

MANUAL
OF
HUMAN EMBRYOLOGY

WRITTEN BY

CHARLES R. BARDEEN, Madison, Wis.; HERBERT M. EVANS, Baltimore, Md.; WALTER FELIX, Zurich; OTTO GROSSER, Prague; FRANZ KEIBEL, Freiburg i. Br.; FREDERIC T. LEWIS, Boston, Mass.; WARREN H. LEWIS, Baltimore, Md.; J. PLAYFAIR MCMURRICH, Toronto; FRANKLIN P. MALL, Baltimore, Md.; CHARLES S. MINOT, Boston, Mass.; FELIX PINKUS, Berlin; FLORENCE R. SABIN, Baltimore, Md.; GEORGE L. STREETER, Ann Arbor, Mich.; JULIUS TANDLER, Vienna; EMIL ZUCKERKANDL, Vienna.

EDITED BY

FRANZ KEIBEL AND FRANKLIN P. MALL
Professor in the University at Freiburg i. Br.
Professor of Anatomy in the Johns Hopkins University, Baltimore, U.S.A.

IN TWO VOLUMES

VOLUME I

With 423 Illustrations

PHILADELPHIA & LONDON
J. B. LIPPINCOTT COMPANY
1910

Printed by J. B. Lippincott Company
The Washington Square Press, Philadelphia, U. S. A.

CONTENTS

CHAPTER I.

BY F. KEIBEL.

CHAPTER II.

BY F. KEIBEL.

CHAPTER III.

BY F. KEIBEL.

CHAPTER IV.

BY F. KEIBEL.

CHAPTER V.

BY F. KEIBEL.

CHAPTER VI.

BY F. KEIBEL.

CHAPTER VII.

BY O. GROSSER.

CHAPTER VIII.

By F. P. Mall.

CHAPTER IX.

By F. P. Mall.

CHAPTER X.

By F. Pinkus.

CHAPTER XI.

By C. R. Bardeen.

CHAPTER XII.

By W. H. Lewis.

CHAPTER XIII.

By F. P. Mall.

PREFACE

THE circumstances that led to the publication of this Manual of Human Embryology, of which the present is the first volume, have been recorded in the Introductory Chapter, where the aims of the work are also set forth. A number of German and American embryologists have collaborated in its production, and the work appears simultaneously in Germany and America. The translation of the chapters originally written in German has been made by Professor McMurrich, and the publishers desire to express their thanks to him for his careful work. The English chapters have been translated for the German edition by one of the editors, Professor Keibel. Valuable assistance has been rendered in the correction of the proofs by Dr. C. Elze, and to him also the thanks of the publishers are due. The editors desire to express their indebtedness to the publishers, Messrs. S. Hirzel, of Leipzig, and J. B. Lippincott Company, of Philadelphia, for their generosity in making it possible for the collaborators to enrich the text with numerous excellent illustrations and for the aid they have rendered in bringing the work to a successful completion.

The second volume will appear at an early date.

FRANZ KEIBEL,
FRANKLIN P. MALL.

INTRODUCTION.

BY FRANZ KEIBEL, FREIBURG I. BR.

VESAL has rightly been regarded as the founder of human anatomy. He emancipated anatomy from the dogmas of Galenism and showed that Galen's anatomical observations had really been made upon apes and that he had attributed to the human body the structure observed in these forms. Vesal studied the human body and based his immortal work upon that study. Embryology was, however, only incidentally considered by him, and in his studies in this field he was false to his principles in that, like Galen in anatomy, he attributed to man what he observed in the embryos of animals.[1]

However, the path which Vesal opened in anatomy was also followed by his successors in embryology. In this connection Gabriele Fallopia (1523–1562) deserves mention as the first who gave a correct description of the placenta and of the chorion and its vessels, and also, on the basis of his own observations, denied the occurrence of an allantois in man. Bartholomeo Eustachi (d. 1574) studied the development of the teeth in human embryos, and Julio Cæsare Aranzi (1530–1588) expressly noted that differences exist between the early stages of development of man and those of the lower animals. Vesal's successor and pupil, Matteo Realdo Colombo (d. 1559), endeavored to do for human embryology what Vesal had done for human anatomy, promising a consideration of human embryology and not animal embryology, since Nature had formed man and animals upon different plans. His efforts, however, to establish an embryology on the basis of observations on human material must, as Bloch has pointed out, be regarded as a failure. And the reasons why Colombo was able to record only exceedingly incomplete observations are not far to seek. The number of human embryos accessible to a single investigator in his day must have been very small; in addition they were, in part, exceedingly altered pathologically, and, what was still more important, the phenomena of greatest significance for embryology occur at such an early period of development that they could not possibly

---

[1] Those interested in the history of Embryology are referred to the paper of Bruno Bloch, Die geschichtlichen Grundlagen der Embryologie bis auf Harvey. Nova Acta Leop.-Carol. Akademie, No. 3, 1904, p. 295 et seq., a work written under the stimulus and influence of Rudolf Burckhardt.

be observed with the methods of investigation available at that time. Even in the case of animals these phenomena were still altogether obscure, and almost three hundred years were to elapse before the necessary preliminary work in this field was accomplished. Ulisse Aldrovandi (1526–1605) must first lay a foundation for modern embryology. He was the first to trace systematically the development of the chick up to the time of hatching and to give a consecutive account of the development. After Aldrovandi followed his pupil Volcher Koyter (1534–1600), and then Hieronymus Fabricius ab Aquapendente (1537–1619). Harvey and Malpighi need be only mentioned here, but a few words may be devoted to the less known Adrian van den Spieghel (Spigelius) (1578–1625).

Spieghel, as may be seen from the introduction to his work De formato fetu, published the year after his death (1626), had a clear appreciation of the value of embryology to the physician, and while his predecessors studied especially the fetal accessory organs, he turned his attention mainly to the development of the fetus itself and that of its organs. Since his object was a history of the development of the human embryo, he was met by the difficulties mentioned above, but where these difficulties were less pronounced, as in the history of the development of the bones, he made valuable contributions and materially advanced the investigations of Koyter and Fallopia in this field. In this connection he made the first attempt at a description based on observation of the genesis of a tissue, distinguishing those osseous elements which were formed in preformed cartilage from those which arose in membrane and describing the growth of membrane bones by the apposition of osseous spicules at the margins. What Spieghel had to say concerning the development of the other organs of the body does not compare favorably with his description of the development of the bones, and he also devoted more than half the contents of his book to the consideration of the chorion, the placenta, and the umbilical vessels; he recognized the occurrence of an allantois in man. And Spieghel also rendered important service by his observations on the fetal circulation. In his time the teaching of Galen that the direction of the blood-stream was the same in both the umbilical arteries and veins was generally accepted, and with this false belief it was naturally impossible to obtain a correct understanding of the fetal circulation. Spieghel, for a number of good reasons, concluded that the direction of the flow in the umbilical arteries was centrifugal; he believed, however, that the vessels carried not blood but Galen's spiritus vitalis, and this prevented him from obtaining a clear idea of the true relations and an accurate knowledge of the circulation of the blood. The difficulties which stood in the way of this discovery were exceedingly great, and the service rendered by Harvey, as Bloch points out (*l. c.*, p. 333, note), can be rightly appreciated only when, from a study of the literature, an idea is obtained of how confused were the notions of even the most distinguished physiologists of the time concerning the movements of the blood.

Without entering into details the names may be mentioned here of Gualtherus Needham, Nicolaus Hoboken, Nicolaus Steno, and Thomas Wharton, who rendered services in connection with the anatomy and physiology of the egg-membranes. The discoveries of Regner de Graaf, Swammerdam, Hamm, and Leeuwenhoek are generally known and have many times been recounted; and the much-admired "Icones Ossium Fœtus Humani" of Albinus gave a certain amount of completeness to the knowledge of the development of the human skeleton. Albrecht von Haller and Kaspar Friedrich Wolff are worthy of mention for more than the formulation of the theories of evolution and epigenesis. Haller wrote important works on the development of the osseous system and of the heart, and Kaspar Friedrich Wolff was the founder of the theory of the germ layers, which was further developed by Döllinger's pupil, Christian Pander, and especially by Karl Ernst von Baer and Remak. Karl Ernst von Baer finally discovered the long-sought-for ovum of man and of the mammalia, and is the real founder of comparative embryology. His work, "Ueber Entwicklungsgeschichte der Tiere, Beobachtung und Reflexion" (Königsberg, 1828 and 1837), must be considered, according to Kölliker ("Entwicklungsgeschichte," 1879, p. 14), "the best that embryological literature of all times and all peoples has to show." The origin of the germ layers and the origin of the organs from these were now subjected to most careful investigation on all sides and in all classes of animals. Here Remak's work, which exercised a very deep and lasting influence, need only be mentioned. The progress in human embryology did not, however, at first keep pace with that in comparative embryology. William Hunter's "Anatomia Uteri Gravidi" (Birmingham, 1774) gave splendid representations of the egg-membranes and of the gravid uterus, but did not advance our actual knowledge of embryology, the condition of which at the close of the eighteenth century can be well understood from the book by D. Ferdinand Georg Danz ("Grundriss der Zergliederungskunde des ungebornen Kindes," vol. i, Frankfurt and Leipzig, 1792; vol. ii, Giessen, 1793), which was accompanied by annotations by Sömmerring, the first authority of that period. Sömmerring himself published in 1799 his "Icones Embryonum Humanorum," which does not, however, contain satisfactory representations of even the later stages of human development, although it is interesting as citing all important earlier observations. How small was the amount of useful material of the early stages of human development accessible even to Karl E. von Baer can readily be appreciated if one examines the concluding part of his great work, edited by Stieda in 1888. In addition the methods of satisfactory fixation, of sectioning, to say nothing of serial sections and of reconstruction, were still lacking. Consequently, the most important early stages in the development of man remained unknown, and progress even in the case of animals, of which abundant material was available and could be studied under the lens while still fresh and transparent, was slow and difficult, even when the method of fixing the embryos in alcohol and dissecting them under the lens with fine needles and knives was learned. Indeed, it is remarkable what was accomplished in spite of these arduous and uncertain methods, but results could be obtained only by oft-repeated observations, and, in the case of man, the material for these was wanting. Thus, we read in Friedrich Tiedemann's "Anatomie und Bildungsgeschichte des Gehirns im Fetus des Menschen" (Nürnberg, 1816) that in embryos of the first month the place of the spinal cord and brain is occupied by a clear fluid. His observations begin with an embryo which had been preserved for some time in alcohol and measured seven lines in length (from the figure it is to be concluded that Rhenish lines of 2.18 mm. are meant; the Parisian line corresponds to 2.25 mm.), that is to say, about 15 mm. Johannes Müller in his "Bildungsgeschichte der Genitalien" (Düsseldorf, 1830) begins his observations on human embryos with an embryo of 8 lines[2] in length (measurement of the figure gives a length of 20 mm.). What the younger stages were like could only be conjectured from observations on animals, and so matters practically remained until His published his "Anatomie menschlicher Embryonen." It is true that human embryos and the egg membranes were extensively investigated and to a certain extent very well figured at this time—as in Coste's "Embryogénie" (Paris, 1837), in the works of Pockel (Isis, 1825), Seiler ("Die Gebärmutter und das Ei des Menschen," Dresden, 1831), Breschet ("Études anatomiques sur l'œuf humain," Paris, 1832), Th. L. W. Bischoff ("Beiträge zur Lehre von den Eihüllen des menschlichen Fetus," Bonn, 1831), and in the briefer publications of E. H. Weber, Joh. Müller, R. Wagner, Von Baer, Wharton Jones, Allen Thomson, and Eschricht—but the observations remained isolated, they were not sufficient to round out the whole story, and frequently the results failed to attain completeness owing to a disinclination to destroy a valu-

---

[2] "A wonderful human embryo, 3¼ lines in length measured along its curvature, with a long-stalked umbilical vesicle and traces of branchial clefts," he could not sacrifice for investigation; he described it in Meckel's Archiv, 1830. He also refers to a similar embryo in Meckel's possession (Beiträge zur vergl. Anat., vol. i, pp. 71 and 72).

able specimen. The technic of investigation made little progress, and it is in this particular that His made a change. He had prepared himself by a study of the embryology of the chick and in connection with this study had worked out a successful technic; he fixed his embryos, he had constructed an apparatus for section cutting which, primitive as it now seems, led the way to our modern microtomes, and he had thought out a method of reconstruction which has been gradually improved, especially by Born, into a method that is now absolutely indispensable in embryological investigation. With this equipment His began the study of human embryology. Although he was fortunate in obtaining material, yet this was still scanty, and he was far from imagining that with it he could study the complete development of man; but with the help of the method of reconstruction he first thoroughly worked out the anatomy of the individual embryos so far as his technic permitted, and the results so obtained formed a sure foundation for human embryology. His models, as well as those he had constructed from the chick, were reproduced by Dr. Ziegler in Freiburg, and, since these came to be regarded as indispensable by every anatomical institute, they served, more than anything else, to increase the knowledge and interest in human embryology. Gradually the gaps which existed were filled in by His's own continued observations and by those of others who studied their material by similar methods, and in this connection there may be mentioned the work of Fol, of Phisalix, of Êternod, and, especially, of Graf Spee. Monographs of individual embryos were contributed by Piper, Mall, Frederic T. Lewis, Susanna Phelps Gage, and Bremer, and in connection with the "Normentafel zur Entwicklungsgeschichte des Menschen" of Keibel and Elze, to be considered later, by Thompson, Ingalls, Elze, and Low. In the meantime the investigation of the individual organ-systems was not standing still. It was very natural that the foundation stones upon which certain systems of organs are built up should be brought together sooner than those of other systems, and, this happening, His directed his attention to these systems, although the development of the organism as a whole still remained the chief object of his thoughts. Thus were achieved the results recorded in the third part of his "Anatomie menschlicher Embryonen," of which those treating of the general differentiation of the digestive tract and those concerning the heart may be especially mentioned. He also published other larger works on the development of the nervous system, one of which appeared shortly before his death.

There should also be mentioned in this connection the work of A. von Kölliker (eye and olfactory organ); of Hammar (the branchial arch region); of Broman, Mall, and Swaen (cœlom and diaphragm); of Hochstetter, Tandler, Erik Müller, and de Vriese (vascular system; also Elze); of Bardeen (skeleton); of W. H. Lewis (musculature); of Nagel, Keibel, and Bayer (the urogenital system); of the younger His, Hammar, and Streeter (ear); and of the younger His and Romberg (the sympathetic system).

The above enumeration makes no pretence of completeness, but is merely intended to show how human embryology was approached from all sides and how the material for a full exposition of the subject was gradually accumulated.

As has been stated, the idea of working out a complete account of the development of the human body was always before the mind of His, but as time went on the hope of accomplishing the task single-handed failed him; and so he suggested that I should collaborate with him in writing a text-book on human embryology. Unfortunately, the plan was never carried out; I have, however, gone further with it and prepared the way for its fulfilment by another work. In the pages of my "Normentafel zur Entwicklungsgeschichte der Wirbeltiere" I have published, in conjunction with Curt Elze, a Normentafel for the development of man. In this I have had the assistance of a large number of other investigators, some of whom, such as Hammar and Tandler, have made personal contributions, while others have contributed valuable material, frequently material obtained by operation and most admirably preserved. Thus I have been able to follow the development of the body in an almost perfect series of embryos from about the twelfth day[3] up to the end of the second month and to obtain many data concerning the first appearance and degree of development of the organs. An explanation of the stages of development earlier than those that I examined had been furnished by the admirable investigations of Graf Spee and Hubert Peters,[4] already mentioned, and the time seemed to me to be propitious for giving an account of the development of the human body, based throughout on human material. We have already, it is true, a whole series of text-books on human embryology, some of them excellent; but they are based, for the most part, on other than human material. They have been written from the comparative embryo-

---

[3] According to the age estimate usually employed; if the estimates of Bryce and Teacher, to which I shall refer later, are correct, the above statement should be "from about the eighteenth day." (Compare Chapter VIII, The Age of Human Embryos and Fetuses.)

[4] Quite recently the observations of Spee and Peters have been confirmed and extended by Ph. Jung ("Beitrag zur frühesten Eieinbettung beim menschlichen Weibe," Berlin, 1908); Bryce, Teacher, and Kerr ("Contribution to the Study of the Early Development and Imbedding of the Human Ovum," Glasgow, 1908); and Frassi ("Ueber ein junges menschliches Ei in Situ," Arch. f. mikr. Anat., vol. lxx, 1907, and Weitere Ergebnisse des Studiums eines jungen menschliches Eies in Situ, *ibid.*, vol. lxxi, 1908).

logical stand-point, and, in the interests of continuity, an endeavor to conceal the gaps in our knowledge is frequently evident. This will not be the case in the present book. On the contrary, its endeavor will be to indicate clearly and precisely these gaps, for thus only can they be filled in; and frequently, as I know, the material for filling them in is already available. I do not propose, of course, to dispense with the assistance of comparative embryology and anatomy, but when a gap has been indicated the manner in which it is probably to be bridged will be pointed out, and, similarly, attention will be given to those facts of comparative embryology and anatomy which serve to render intelligible to us special processes of development in man. As a rule, however, such considerations will be printed in smaller type, in order that there may be a clear distinction between facts and deductions. So far as I can see, all the material necessary for a human embryology, with the exception of the earlier stages which concern the development of the germ layers and the first stages of placentation, is already available or at least is comparatively readily obtainable. It would be possible, therefore, to describe the development of all the organs exclusively from human material if it were possible to bring together all the material which is now available. If my colleagues and myself have not succeeded in this, nevertheless we have been able to approach the goal, and we may hope that it will fare better with us than with Realdo Colombo, and even if the first attempt has not been perfectly successful, the second, whether made by us or by others, will come so much nearer the goal. The material is in hand and to be obtained; it will be brought forward if we only point out clearly what is lacking.

When working at my Normentafel I had very striking evidence of the community of purpose which to-day inspires our scientific world. A considerable number of investigators deprived themselves for long periods of time of valuable material which they themselves had not yet had opportunity to study thoroughly, in order that a larger undertaking might be completed. In the time of Realdo Colombo such scientific co-operation did not exist; we can with pride regard this as a great step in advance. Without it the completion of such a work as the Normentafel would have been unthinkable; to-day the post and the telegraph, railways and steamboats, are at our service and may be turned to the service of science. And so it has been possible to bring to completion such a "Handbook of Human Embryology" as His had planned with me in Germany with the assistance of one of his most loyal pupils on the far side of the ocean, Franklin P. Mall, of the Johns Hopkins Medical School in Baltimore. It has seemed proper to Mall and myself to enlist the services of a considerable number of collaborators, the necessary similarity of treatment being secured by the common purpose and by editorial supervision; in this way the book would the sooner be brought to completion and, what is more important, the various chapters would be written with a complete mastery of the subject. Considered purely objectively and scientifically the embryology of man has no more interest than that of any other mammal or vertebrate, and from this stand-point special endeavors to work out human embryology by itself may seem to be misplaced. Our interest in the development of the human body is justified, however, first, by the fact that we are human beings, and, secondly, because, as Spieghel long ago pointed out, it is of importance to physicians. That we do not undervalue the information to be obtained from comparative embryology and anatomy has already been stated.

HANDBOOK
of
HUMAN EMBRYOLOGY

I.

THE GERM-CELLS.

BY FRANZ KEIBEL, FREIBURG I. BR.

THE germ-cells of man are the ovum (oide, ovium, mature ovum), formed in the ovary, and the spermium, formed in the testes. *The mature human ovum* (the *oide* of Korschelt and Heider, the *ovium* of Waldeyer) *is not yet known, nor have the processes which bring about its maturation yet been certainly observed.* Nagel[1] (1888) in connection with his Pl. XXI, Fig. 7, speaks of remains of polar bodies, but this interpretation, as Waldeyer (1902, in Hertwig's Handbuch, vol. i, part i, p. 333) has pointed out, cannot be accepted in view of the occurrence in the ovum figured of a perfectly unaltered nucleus.

The human ovum which has reached its full size in the ovary is a true cell, with cytoplasm, in the ovum termed oöplasm (yolk), a nucleus, frequently spoken of as the germinal vesicle, and a nucleolus, also termed the germinal spot. In the nucleus there is, in addition to the nucleolus, a fine, somewhat scanty nuclear reticulum containing chromatin. We must assume that processes of maturation occur in such an ovum, similar to those which occur in the ova of other animals. Briefly stated the maturation consists in that from the ovum, by two rapidly succeeding divisions, four cells, one large and three small, are formed. The large cell is the mature ovum, the oide or ovium, the three other cells are the polar bodies (polocytes), formerly known as the directive corpuscles. At the first division the first polar body is separated, at the second division the second one, the first one at the same time also undergoing division. The divisions take place by mitosis and the final products possess only half the number of chromosomes characteristic of the ordinary cell-divisions of the species. A reduction of the number of chromosomes by one-half is thus brought about, but how this reduction is accomplished and what may be its significance is still a matter of discussion; indeed, whether the reduction always actually takes place during the nuclear divisions which produce the polocytes—whether at the one or the other of these divisions there is really a reduction division—is yet uncertain. For further

---

[1] W. Nagel: Das menschliche Ei, Arch. f. mikr. Anat., vol. xxxi, 1888.

consideration of this point reference may be had to Korschelt and Heider,[2] Haecker,[3] Waldeyer,[4] and E. B. Wilson.[5] Individually many variations occur in the process; the division of the first polocyte may not take place, the formation of one of the polar bodies may be suppressed, and, what is noteworthy, modifications occur in individuals of one and the same species.

The centrosome of the egg-cell seems usually to degenerate during these processes. The time, with reference to the fertilization, at which the formation of the polar bodies takes place, varies; the first one is often formed while the ovum is still in the ovary. In mammals these phenomena have been especially well studied in the mouse (Sobotta,[6] Leo Gerlach,[7] and others), and they have also been investigated in the guinea-pig (Rubaschkin). In man, as has been stated, nothing is known of these things. We may with perfect certainty assume that polocytes are formed and that there is a reduction of the chromosomes to one-half the typical number; but whether variations from the general plan occur, whether or not the formation of one of the polar bodies is suppressed, we do not know. Similarly we can say nothing as to the time at which the polocytes are formed. It may be that the first one is formed while the ovum is still in the ovary, and observations on this point are much to be desired.

But even although, as is clear from what has just been said, the mature human ovum is unknown, nevertheless descriptions have frequently been given of a so-called mature human ovum, that is to say, of an ovum which was near maturity, and usually the figure and description given by Nagel has formed the basis of these accounts. O. Hertwig follows Nagel's description and Waldeyer quotes it almost verbally; it may be given here as well as the figure.

The human ovum retains its transparency in all stages of development, so that all its anatomical characteristics can be fully made out in the living object. The cell substance, which may be termed the oöplasma, and which is frequently spoken of as the yolk, is separated into two layers. In the inner (central) layer is found the greater part of the deutoplasm, that is to say, the inclusions of the ovum, which are usually regarded as nutritive or reserve substances; they produce merely a slight opacity in comparison with what is found in the ova of other mammals. The deutoplasm consists partly of feebly and partly of strongly refractive, finer and coarser granules; but a distinct delimitation of the deutoplasmic elements, such as one finds not only in the ova of the lower vertebrates but also in those of many mammals, cannot be made out. The outer layer, the marginal zone of the oöplasma, is much

---

[2] Korschelt and Heider: Lehrbuch der vergleichenden Entwicklungsgeschichte, 1902.

[3] Haecker: Die Chromosomen als angenommene Vererbungsträger, Ergebnisse und Fortschritte der Zoologie, herausgegeben von J. W. Sprengel, vol. i, 1907.

[4] Waldeyer: Chapter I in O. Hertwig's Handbuch der vergleichenden und experimentellen Entwicklungslehre, 1906.

[5] E. B. Wilson: The Cell in Development and Inheritance, New York, 1906.

[6] J. Sobotta: Die Bildung der Richtungskörper im Ei der Maus, Anatom. Hefte, cvi, 1907. The remaining literature is cited here.

[7] L. Gerlach: Ueber die Bildung der Richtungskörper bei Mus musculus, Wiesbaden, 1906.

more finely granular and transparent. It contains the germinal vesicle, that is to say, the nucleus of the cell, in which is to be seen a large germinal spot or nucleolus. In ova examined while fresh in the liquor folliculi Nagel observed amœboid movements in the nucleolus, and such movements have also been described as occurring in the nucleoli of other ova, although Flemming ("Zellsubstanz, Kern, und Zellteilung," Leipzig, 1882, p. 157), to whom Nagel ("Die weibliche Geschlechtsorgane," in K. von Bardeleben's "Handbuch der Anatomie des Menschen," vol. vii, p. 59, 1896) refers in connection with the egg of *Paludina,* expressly states that in spite of many endeavors he had not succeeded in perceiving changes of form in living nucleoli. Further observations on this point are much needed. The nucleus appears to be homogeneous in the freshly stained ovum, but with proper staining a scanty chromatin network becomes visible. The membrane which encloses the ovum, the zona pellucida, is remarkably broad and is finely striated radially. It is separated from the oöplasma by a narrow perivitelline space and is surrounded by cells, derived from the cumulus ovigerus which surrounds the ovum in the ovarian follicle.



Fig. 1.—A fresh ovum from an ovarian follicle of a woman of thirty years. The side of the yolk upon which is the nucleus is towards the observer, so that one looks directly down upon the nucleus and this rests upon the deutoplasm. (From W. Nagel: Arch. f. mikr. Anat., vol. xxxi, 1888, Pl. XX, Fig. 5.)

These cells form three or four layers, those of the layer nearest to the zona pellucida having a markedly radiating arrangement and forming in the fully formed ovum the corona radiata of Bischoff. This author regarded the corona as an indication of the maturity of the ovum, a view with which Waldeyer coincides to the extent that he regards a well-developed corona as a sign of approaching maturity, without, however, acknowledging it to be an indication of complete ripeness. In this he agrees with Van Beneden and Nagel.

To this description of the approximately ripe ovum it must be added that the existence of a perivitelline space is in dispute. Nagel believes that the space is of importance in that it permits a rotation of the ovum so that the nucleus usually lies upon its upper surface, for this was the position in which he found it in all fresh, approximately ripe ova. Ebner (Kölliker's "Handbuch der Gewebelehre," vol. iii, p. 517, 1902) disputes both the existence of a perivitelline space and the assumption that the ovum rotates within the zona pellucida, the nucleus thereby coming to lie upon the upper surface. He is of the opinion that the nucleus ascends through the almost fluid oöplasma on account of its lesser specific gravity, and that the ovum as a whole does not rotate; he bases his opinion on the fact that when a fresh ovum is burst the greater part of the oöplasma together with the nucleus is expelled, but the apparently denser marginal zone of the oöplasma always remains adherent to the zona pellucida. This could not occur if an interval filled with fluid was interposed between the marginal oöplasma and the zona. Furthermore it could be observed, by carefully focussing an equatorial optical section of an uninjured fresh ovum, that the marginal oöplasma was in intimate contact with the inner surface of the zona pellucida. "What Nagel figures as a cleft is a line of refraction, which, with deep focussing, appears to be in the deeper layer of the yolk (oöplasma), and apparently separates the yolk (öoplasma) and the zona, but is really a purely optical phenomenon which depends on the curvature of the zona and resembles the line of refraction which one may observe under similar circumstances in cartilage cavities."

Waldeyer (*l. c.,* p. 332), on the other hand, mantains the correctness of Nagel's observation, since he has been able to convince himself of it from the ovum figured by Nagel. He is not, however, convinced as to the rotation of the ovum within the zona, but agrees with Ebner that the fact observed by Nagel may be explained by the ascent of the lighter nucleus through the almost fluid oöplasm. He himself shows in his Fig. 134 (*l. c.*), which is reproduced here as Fig. 2, an almost ripe human ovum (a fully grown oöcyte), taken from an ovary while it was still warm, in which there was not the slightest indication of a perivitelline space. Waldeyer explains this discrepancy by assuming that the ovum described by Nagel was further advanced towards maturity. The oöplasm is also arranged somewhat differently in this ovum from what it is in that described by Nagel. Close under the zona there is a very narrow zone of a finely granular material, the oöplasm cortex, which was clearly seen by Waldeyer as well as by Ebner; beneath this is a broader, clearer zone of oöplasm in which the nucleus lies in almost ripe ova, and then comes the central darker mass of the oöplasm.



FIG. 2.—Almost mature human ovum (fully grown oöcyte) taken from an ovary while still warm. On the outside appears the epithelium, with the clear zona pellucida; within this, a broad stratum of oöplasm with little yolk; and in the centre the oöplasm rich in yolk. Above to the left, is the nucleus, with nucleolus; and a few subzonal nuclei are seen. ×500. (After Waldeyer in Hertwig's Handbuch, vol. i, part i, p. 330, Fig. 134.)

It will be seen that in this connection important questions still await decision, and if gynæcologists and embryologists work with a common purpose a solution of them may be expected. Another question I regard as already settled. The human ovum has no micropyle, that is to say, no preformed opening in the zona pellucida for the entrance of the spermium. The question as to the existence of a micropyle has been recently revived by Holl (*Anat. Anz.*, 1891, p. 554; and *Sb. K. Acad. Wien.*, vol. cii, 1893), after it had long been regarded as settled. It seems to me to be certain that Holl has been the victim of a mistake. Ebner (Kölliker's "Gewebelehre," vol. iii, p. 518) says "Holl's figure of a section of an apparently degenerated human ovum shows, traversing the greatly shrunken zona, a small oblique cleft, probably formed by accident, perhaps by a wandering cell. True micropyles, so far as known, traverse the zona radially, not obliquely."

The development of the ovum will not be discussed here, but in the chapter on the urogenital apparatus; yet, since it has to do with the question of the relation of the follicle cells to the oöplasm, it must be noted here that the mode of formation of the zona pellucida is not yet certain. Waldeyer inclines to the opinion that it is a product of the oöplasm and is therefore a primary egg-membrane. R. Hertwig (O. Hertwig's "Handbuch") and others regard it as a chorion, that is, as a secondary egg-membrane, a product of the follicle cells; while for others it is a double product of the follicle cells and the oöplasm, at least so Waldeyer interprets the observations of Retzius,[8] Flemming,[9] and Ebner.[10] According to these authors there is first formed, from processes extending from the follicle cells to the oöplasm, a delicate network, which rests closely upon the surface of the ovum. The network is the first indication of the zona, and, later, a homogeneous substance appears between its fibres and forms with them the zona. Whence this homogeneous substance arises is uncertain; according to Waldeyer it may come from the oöplasm. A portion of the cell bridges that originally extend between the follicle cells and the oöplasm are retained in the forming zona substance in a protoplasmic condition, but whether such unions persist in the approximately ripe ovum is uncertain; certainly their existence can hardly be reconciled with the presence of a perivitelline space. Kölliker (according to Von Ebner in Kölliker's "Handbuch der Gewebelehre," vol. iii, p. 511) gives the diameter of the approximately ripe ovum as 0.22–0.32 mm., but Waldeyer remarks (*l. c.*, p. 352, note) that he has never seen a human ovum of over 0.25 mm. As regards further measurements Ebner gives the diameter of the nucleus (germinal vesicle) as 30–45 μ, that of the nucleolus (germinal spot) as 7–10 μ, that of the zona pellucida as 10–11 μ, and that of the deutoplasm granules (yolk granules, Von Ebner) as 2–3 μ.

---

[8] Retzius: Zur Kenntnis vom Bau des Eierstockeies und des Graaf'schen Follikels, Hygiea Festband, Stockholm, 1889.

[9] Flemming: Zellsubstanz, Kern und Zellteilung, Leipzig, 1882, p. 35.

[10] Von Ebner: Ueber das Verhalten der zona pellucida zum Ei, Anat. Anz., vol. xviii, 1900.

The production of ova begins at a very early period of life in the human species. According to Waldeyer (*l. c.*, p. 373; and "Eierstock und Ei," 1870) at birth or shortly thereafter all the oögonia have become oöcytes of the first order, and so have before them only further growth and maturation. (The contrary opinion of Paladino[11] I do not consider well founded.) Already in the ovary of the child the ova may approach ripeness (see C. Hennig; Ueber frühreife Eibildung, *Sb. d. Leipzig. Naturf. Ges.*, p. 5, 1878). Also Waldeyer says, "One finds in the ovaries of newly-born and young children follicles the size of a pea with normally developed ova." On the other hand, those ova which ripen only after the cessation of ovulation require for their development about fifty years.

Into the broad field of the pathology of the ovum I cannot enter here; nevertheless, follicles with several ova, multinucleated ova, and the fragmentation of the ovum may be briefly mentioned. Follicles with several ova may be explained (Schottlander: *Arch. f. mikr. Anat.*, vol. xli, 1893; M. and P. Bouin; *C. R. Soc. Biol.*, vol. lii, p. 17 and 18, Paris, 1900 [dog]; Ch. Honoré: *Arch. de Biol.*, vol. xvii, p. 489–497, 1900 [rabbit]) by supposing that the different ova of an egg mass in the embryo and child have not completely separated, so that several ova have become enclosed within a common follicle wall. They may very naturally tend to the production of twin pregnancies. They may also be supposed to have arisen by the fusion of originally distinct follicles. Multinucleated ova have been accounted for in various ways and perhaps have various methods of origin. They may be formed by direct nuclear division (Stöckel: *Arch. f. mikr. Anat.*, vol. liii, 1899; Falcone: *Monitore zool. ital.*, Suppl., 1899) or one may suppose that originally distinct ova have subsequently fused (H. Rabl: Mehrkernige Eizellen und mehreiige Follikel, *Arch. f. mikr. Anat.*, vol. liv, 1899; S. von Schumacher und C. Schwarz: *Anat. Anz.*, vol. xviii, 1900). Finally, they may be produced by the division of the nucleus of an oögonium, without the corresponding division of the cytoplasm taking place, as sometimes occurs in spermatogonia. Cases in which several nuclei occur in an ovum as the result of an immigration of leucocytes need not be considered here.

In mammals a division or fragmentation of ripe ova after the expulsion of polar bodies has been observed (Henneguy, Janošik, H. Rabl, Gurwitsch, Van der Stricht), and I have also seen such a condition in human ova. The phenomenon is one leading to the degeneration of the ovum; some authors have compared it with segmentation and have seen in it a parthenogenetic process, but Bonnet[12] has disposed of such notions.

We may now turn to a consideration of the male germ-cell, the spermium, which is formed in the testis. It is well known that for a considerable time it was uncertain whether the male cells were

---

[11] Paladino: La renovazione del parenchima ovarico nella donna, Atti dell' XI Congr. internaz. med. di Roma, vol. ii, Anatomia, 1894, p. 19. Compare also Arch. ital. de Biologie, vol. xxi, p. 15, 1894; and Monitore zoolog. ital., Anno V, p. 140, 1894; also, Per il tipo di struttura dell' ovaja, Rendic. Acad. Sc. fis. math., Napoli, vol. iii, p. 232, 1897; also, Sur le type de structure de l'ovaire, Arch. ital. de Biol., vol. xxix, p. 139, 1898.

[12] Bonnet: Gibt es bei Wirbeltieren Parthenogenesis? Ergebnisse d. Anatomie und Entwicklungsgeschichte, vol. ix, 1900.

not parasites in the seminal fluid—the name spermatozoa is a reminder of this idea. The development of the spermium first clearly showed that this structure is nothing else than a modified cell. Spermatogenesis has also been studied in man and some figures from Meves[13] (*Arch. f. mikr. Anat.*, vol. liv, p. 378) may be reproduced here. Other figures have been given by Ebner (Kölliker's "Handbuch," vol. iii, p. 454). In the study of human spermatogenesis attempts have been frequently made to determine the number of the chromosomes. Duesberg,[14] who also cites the literature bearing on the question, finds that in the spermatocytes there are in all probability twelve. If this be correct in the spermatogonia and the soma cells there would be twenty-four, as Flemming had already (1898) supposed. Good figures of human spermia have recently been given by Retzius (*Biol. Unters.*, neue Folge x, 1902), and an excellent diagram by Meves is reproduced by Waldeyer in Hertwig's "Handbuch," vol. i, p. 146. In the human spermium, which is essentially similar to that of other mammals, there may be recognized a head and a tail; a neck piece is not clearly distinguishable. In the tail, if the indistinct neck piece be disregarded, there are a connecting piece, a principal piece, and an end piece.

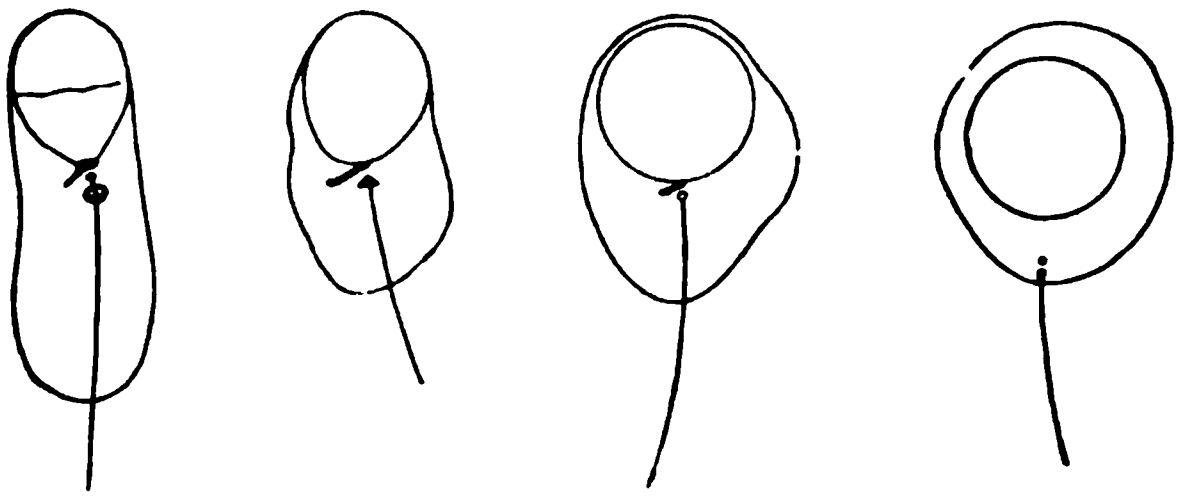

FIG. 3.—Four stages in the spermatogenesis of man. (After Meves, Arch. f. mikr. Anat., vol. liv, p. 378, 1899.)

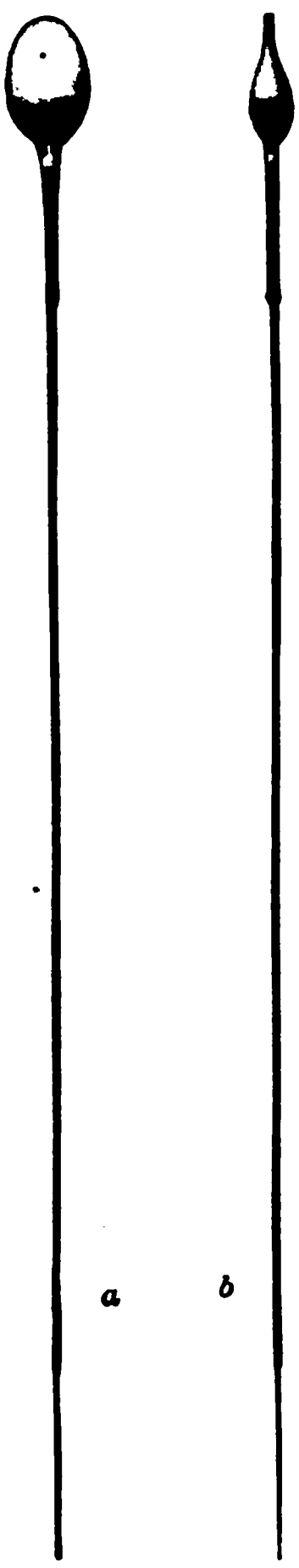

FIG. 4.—A typical human spermium, straightened out. In *a* the head is seen from the surface and in *b* from the edge. In both figures there are shown the head cap, the neck piece with the centrosomes lying close to the head, the connecting piece, and the principal and end pieces of the tail. In *a* is shown in the anterior part of the head a dark dot. (After G. Retzius, Biol. Untersuchungen, neue Folge, vol. x, Pl. 15, Figs. 1 and 2.)

Seen from the surface the head is oval, and in side view it is elongated pear-shaped, the tail being attached to the broader end; upon each surface of the head there is a slight depression.

---

[13] See, also, Meves: Zur Entstehung der Achsenfäden menschlicher Spermatozoen, Anat. Anz., vol. xiv, 1897; and Ueber das Verhalten der Centralkörper bei der Histogenese der Samenfäden von Mensch und Ratte, Verh. Anat. Ges. (Kiel), 1898.

[14] J. Duesberg: Sur le nombre des chromosomes chez l'homme, Anat. Anz., vol. xxviii, 1906.

According to Waldeyer one sees with very strong magnification a constriction between the head and the connecting piece, and this is an indication of the neck; and in this situation Krause and Waldeyer describe a small depression in the head, which receives the neck together with the connecting piece. By staining the head cap can be brought into view, its posterior border marking off an anterior and a posterior portion of the head. The anterior sharp border of the cap represents the perforatorium; special perforatoria, such as Nelson[15] and Bardeleben[16] have described, may be produced by special conditions and perhaps have been confused with attached bacteria. The neck has the form of a disk, which is formed by the anterior centrosome bodies, the noduli anteriores (Fig. 5, *A* and *B*, *Nd.a*, dark), and a homogeneous intermediate substance, the massa intermedia (*Ms.int.*, clear). The succeeding connecting piece (pars conjunctionis) begins with the noduli posteriores (the posterior centrosome bodies), represented in the diagram as a black stripe, and ends with the annulus; it includes, therefore, the region of the posterior centrosome, which during spermatogenesis has divided into these two portions. The filum principale of the tail traverses the axis of the connecting piece, extending from the proximal portion of the posterior centrosome. In this region the filum principale has a delicate investment which probably passes over posteriorly into the thicker sheath of the tail and finally ends at the beginning of the filum terminale. Around this delicate sheath is the spiral sheath, and external to this the mitochondria sheath. The spiral sheath consists of a spiral filament, not recognizable in the mature spermium, and an intermediate substance, the substantia intermedia, represented as clear in the diagram. The mitochondria sheath is the matrix of the spiral filament and is characterized by the presence of mitochondria granules. At the beginning of the principal portion of the tail the spiral and mitochondria sheaths terminate, but the inner thin sheath is probably continued into the involucrum of the tail. A spiral membrane has been described for the human spermium by several authors, but does not really occur. The measurements of the human spermium are, according to W. Krause ("Handbuch der menschl. Anat.," vol. i, p. 559, 1876), as follows: Entire length 52–62 μ, of which the head measures 4.5 μ, the connecting piece 6 μ, and the tail 41–52 μ. The width of the

---

[15] E. M. Nelson: Some Observations on the Human Spermatozoon, Journ. Quekett Micr. Club, London, ser. 2, iii, pp. 310–314, 1889.

[16] Von Bardeleben: Ueber die Entstehung der Achsenfäden im menschlichen und Säugetierspermatozoon, Anat. Anz., vol. xiv, 1897; also, Beiträge zur Histologie des Hodens und zur Spermatogenese beim Menschen, Arch. f. Anat. und Entwicklungsgesch., Supplementband, 1897; also, Weitere Beiträge zur Spermatogenese beim Menschen, Jenaische Zeitschrift, vol. xxxi, 1898.

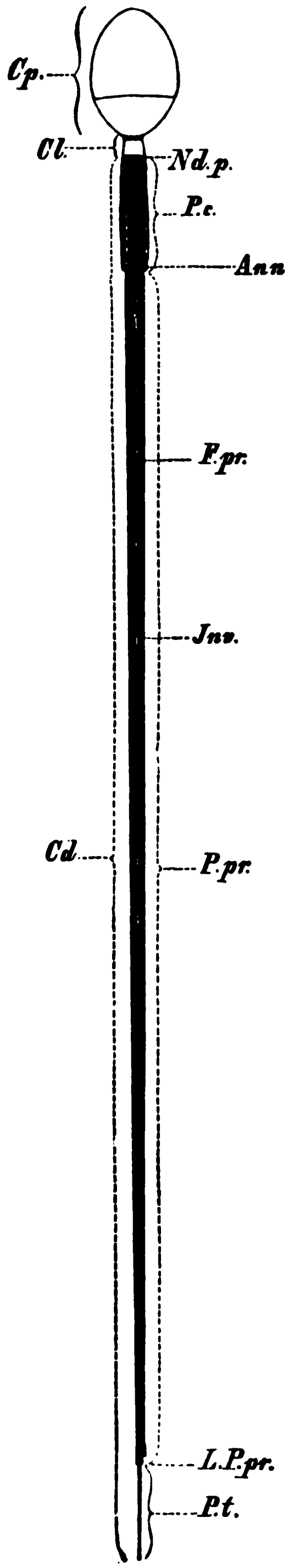

FIG. 5, *A*.

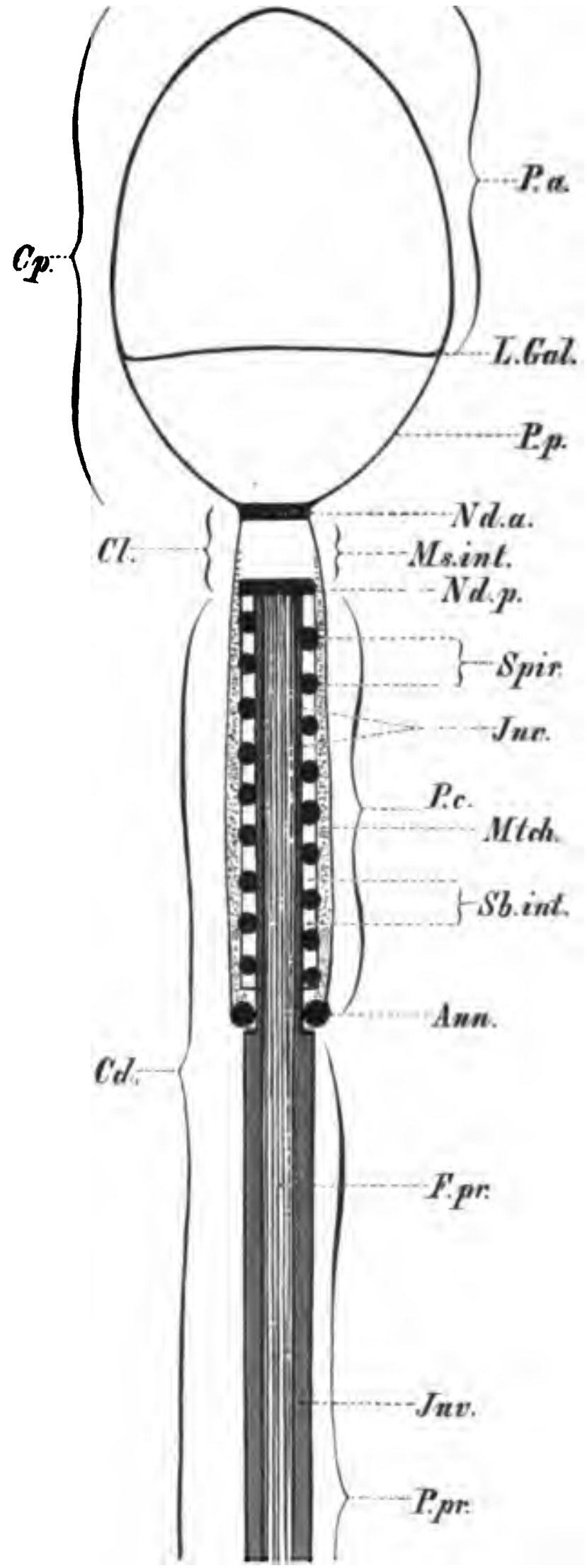

FIG. 5, *B*.

FIG. 5, *A* and *B*.—Diagram of a human spermium according to Meves. *Cp.*, caput (head); *Cl.*, collum (neck): *Cd.*, cauda (tail); *P.c.*, pars conjunctionis (connecting piece); *P.pr.*, pars principalis (principal portion of the tail); *P.t.*, pars terminalis (end piece); *Nd.p.*, noduli posteriores (anterior boundary of the connecting piece); *Ann.*, annulus (posterior boundary of the connecting piece); *L.P.pr.*, limes partis principalis (posterior boundary of the principal portion); *P.a.*, pars anterior capitis (anterior portion of the head); *L.Gal.*, limes galeæ (boundary of the head cap); *P.p.*, pars posterior capitis (posterior portion of the head; *Nd.a.*, noduli anteriores (anterior centrosome bodies); *Ms.int.*, massa intermedia (intermediate substance of the neck); *Spir.*, spiral filament; *Inv.*, involucrum (sheath of the axial filament in the connecting piece and principal portion of the tail); *Mtch.*, mitochondria; *Sb.int.*, substantia intermedia (intermediate substance of the spiral sheath); *F.pr.*, filum principalis (axial filament). (From Waldeyer: Die Geschlechtszellen, in Hertwig's Handbuch, vol. i, p. 146, Figs. 43, A and B.)

head is 2–3 μ, its thickness 1–2 μ. Giant spermatozoa also occur. Such a structure was figured by Widersperg[17] in 1885. Since then abnormal forms of human spermatozoa, after G. Retzius[18] had described double-tailed forms in 1881, have been recently specially studied by Ivar Broman.[19] Some of his figures are here reproduced. Fig. 6, *a* and *b*, shows a giant and a dwarf sperm; the tails have in both cases about the normal length. Fig. 6, *c* and *d*, shows double-tailed spermia; *e*, one with four tails; *f*, a double-headed one; and *g*, a normal sperm under the same enlargement. Broman remarks that certain forms of abnormal spermia may be the result of a general weakening of the body by illness and by the influence of morphine, coffee, and alcohol. The idea of Bardeleben[20] that two different forms of human spermia occur

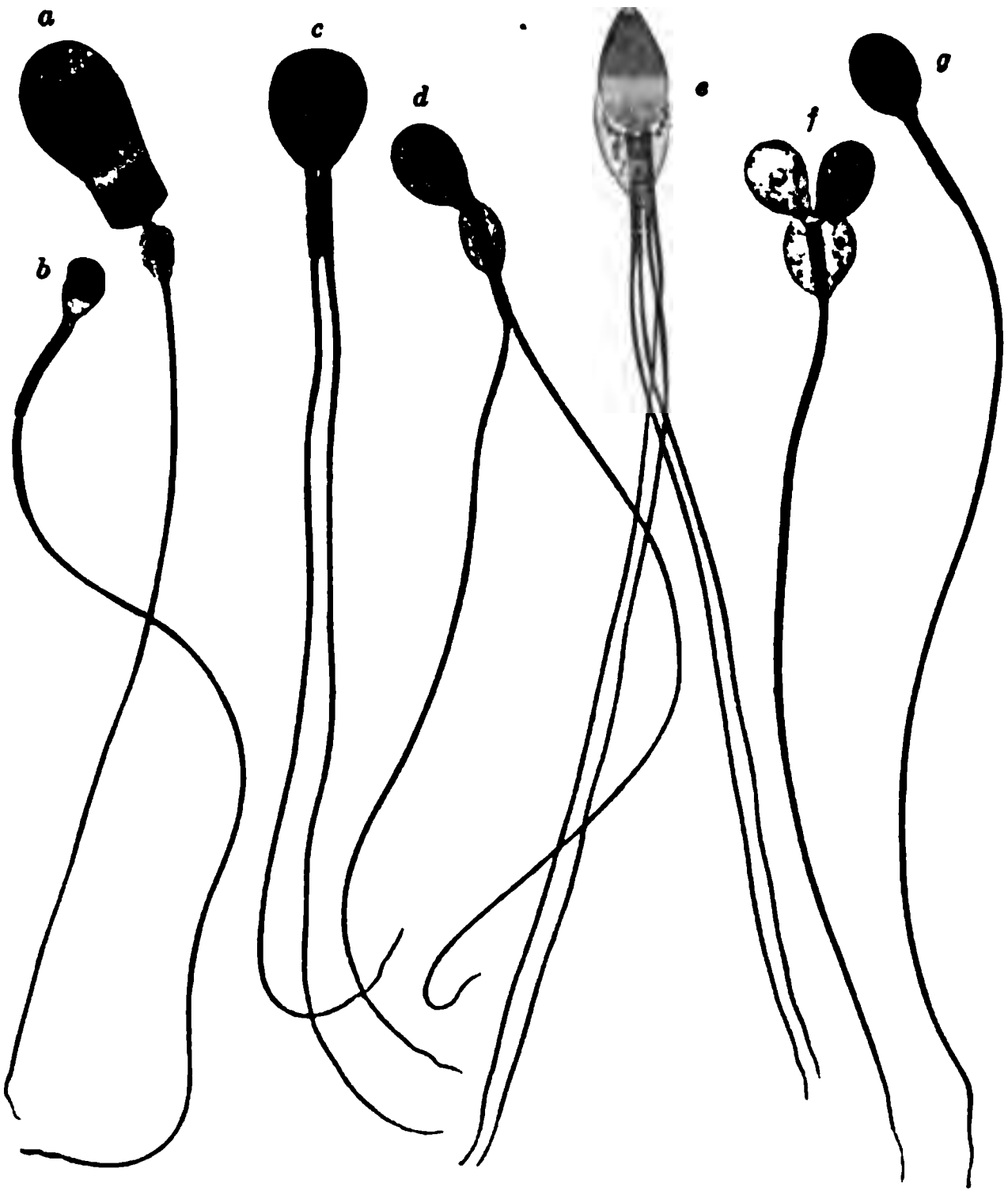

FIG. 6.—*a–f*, abnormal human spermia; *g*, a normal sperm under the same enlargement. *a*, giant sperm; *b*, dwarf sperm; *c* and *d*, double-tailed forms; *e*, a four-tailed, and *f*, a double-headed form. (After Ivar Broman, Anat. Anz., vol. xxi, 1902.)

---

[17] Gustav von Widersperg: Beiträge zur Entwicklungsgeschichte der Samenkörper, Arch. f. mikr. Anat., vol. xxv, 1885 (Pl. VI, Fig. 18).

[18] G. Retzius: Zur Kenntnis der Spermatozoon, Biol. Untersuch., 1881.

[19] Ivar Broman: Ueber atypische Spermien (speziell beim Menschen) und ihre mögliche Bedeutung, mit 107 Abbildungen, Anat. Anz., vol. xxi, p. 455–461, 1902.

[20] Von Bardeleben: Dimorphismus der männlichen Geschlechtszellen bei Säugetieren, Anat. Anz., vol. xiii, 1897.

has been disproved, although such a dimorphism occurs among the invertebrates.

The spermia are motile, being propelled by movements of the tail. They swim against a current, as was determined independently by Roth[21] and Adolphi,[22] although this fact had previously been observed by Lott (1872) and Hensen (1876), whose results had been forgotten. The current exercises a directing force upon the spermia, but for this it must have a certain strength. The influence begins with currents flowing with a rate of 3–4 μ per second; in currents of 4–20 μ the spermia move forward, the more slowly the more rapid the current; in a flow of 25 μ they can just hold their own; and in more rapid currents they are carried backward. The absolute rapidity of the spermia is 23–26 μ; only at the beginning of its action does the current increase their activity. Since dead spermia also move with the head against the current, the explanation of the effect must be sought in their physical structure. This adaptation is of great importance for fertilization, since it determines that the spermia will direct their course against the outwardly moving current produced by the cilia of the uterus and tubes and pass in the most direct route toward the infundibulum. Waldeyer (*l. c.*, p. 209), following Henle ("Allgem. Anat.," p. 954), makes the rapidity of movement of the spermia considerably higher than Adolphi; in seven and a half minutes they cover a distance of 27 mm., this being at a rate of 60 μ per second.

How long the human spermia may remain motile and capable of producing fertilization is uncertain. I found still motile spermia on the third day in the testes of an executed criminal, the organs having been placed unopened in picro-sublimate; that they may remain motile for just as long a period in the cadaver is known (F. Strassmann, "Lehrbuch der gerichtlichen Medizin," p. 61, 1895). Bossi[23] found still living spermia in the vagina twelve to seventeen days and in the cervix five to seven and a half days after the last cohabitation; Dührssen (*Sb. Ges. Geburtshilfe und Gynaekol.*, Berlin, May 19, 1893; also Zweifel: "Lehrbuch der Geburtshilfe," 3 Aufl., 1902) observed living spermia in a diseased tube nine days after the admission of the patient to the

---

[21] A. Roth: Ueber das Verhalten beweglicher Mikroorganismen in stromenden Flussigkeiten, Deutsche med. Wochenschrift, Jg. 19, p. 351–352, 1893; also, Zur Kenntnis der Bewegung der Spermien, Arch. f. Anat. und Physiol., Physiol. Abt., 1904.

[22] H. Adolphi: Die Spermatozoen der Säugetiere schwimmen gegen den Strom, Anat. Anz., vol. xxvi, 1905.

[23] Bossi: Étude clinique et expérimentale de l'époque la plus favorable à la fécondation et de la vitalité des spermatozoïdes séjournant dans le nidus seminis, Rivista di ostetric. e ginecol., 1891, no. 10, also in Nouv. Arch. d'obstétr. et de gynécol., April, 1891.

clinic; according to the statements of the patient the last cohabitation had occurred three and a half weeks previously. Ahlfeld succeeded in keeping spermia alive for eight days at body temperature, and Wederhake ("Zur Technik der Spermauntersuchungen," *Monatsschrift Urol.,* vol. x, p. 520–525, 1905) found, in sperm that had been kept sterile, still living spermia on the eighth day. All these data indicate that human spermia in the female genitalia remain still capable of fertilization for a considerable period, certainly over a week. In animals spermia capable of producing fertilization may remain in the female genitalia for months, as in the bats, in which, as I have satisfied myself, copulation occurs in the autumn while the fertilization does not result until the following April or the beginning of May.

COMPARISON OF THE OVIUM AND SPERMIUM.

A comparison of the ovium and spermium is possible only when the development of both cells is considered. This will be done in the chapter on the urogenital apparatus and it will be only briefly treated here. In the development of the male and female germ-cells three periods may be distinguished. The first period is that of increase, in which the germ-cells—at this stage termed oögonia in the female and spermatogonia in the male—undergo a rapid increase by mitotic division. At a certain period of development the divisions cease and the cells produced by the last divisions—the oöcytes of the first order in the female and the spermatocytes of the first order in the male—then enter upon a period of growth, which, especially in the female, leads to a great increase in size. At the close of this period that of maturation begins, during which the polocytes are formed in the female cell. A corresponding period occurs in spermatogenesis. Two divisions follow quickly on one another; each spermatocyte of the first order divides first into two spermatocytes of the second order and each of these again divides into two spermatids. Just as in the case of the matured ovum, the oide or ovium, and the three polocytes, which are to be regarded as rudimentary oides, the chromatin elements are reduced to half their original number, so too in each of the four spermatids that are formed by the division of a spermatocyte of the first order the chromosomes are reduced by one-half. A marked difference, however, occurs: whereas the four oides (the ovium and the three polocytes) are very unequal in size, the ovium being many times larger than each of the polocytes, the four spermatids from each spermatocyte of the first order are equal in size. And another difference lies in this, that while the ovium is capable of being fertilized immediately after or even during the second maturation division, the four spermatids must still undergo a complicated process of development, that has no equivalent in the ovium; they must be transformed into spermia before they are capable of fertilizing. A comparison of spermatogenesis and oögenesis is clearly shown by Boveri's diagram (Fig. 7), taken from Waldeyer (p. 225).

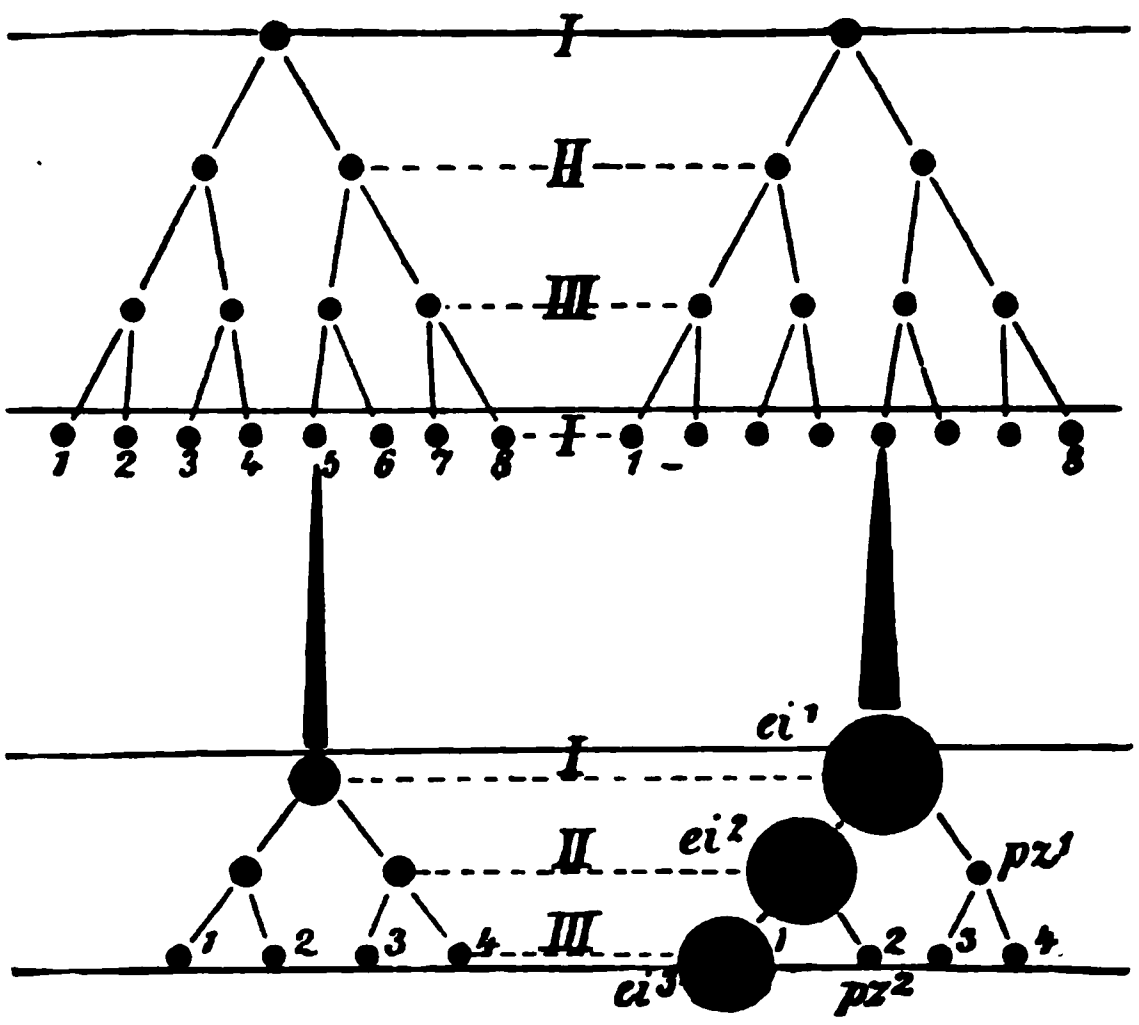

Fig. 7.—Diagram of the development of the primitive germ-cells (I in the zone of increase)—the primitive sperm cells to the left, the primitive ova to the right—into spermatids and spermia or into ovia; II and III in the zone of increase represent the spermatogonia and oögonia. The upper small cells in the zone of growth enlarge to form spermatocytes or oöcytes (*ei*^{1}) of the first order. By the division of these cells (I in the maturation zone) there are formed (to the left) two spermatocytes of the second order (prespermatids) or (to the right) an oöcyte of the second order (*ei*^{2}) and a first polocyte (*pz*^{1}). The succeeding division, represented at II in the maturation zone, produces the spermatids (1, 2, 3, 4, to the left) or a mature ovium (*ei*^{3}), together with the second polocyte (*pz*^{2}). A division of *pz*^{1} may also take place and then there will be formed, to the right as well as to the left, four descendants from the cells represented by I of the maturation zone. (After Boveri and O. Hertwig, from Waldeyer's "Geschlechtszellen" in Hertwig's Handb., vol. i, part i, p. 225, Fig. 55.)

The male and female germ-cells are shown by this comparison to be essentially equivalent, and yet the subordinate differences are of the greatest importance. Both are cells in which the number of the chromosomes has been reduced to one-half by quite comparable processes; their differences are associated with a division of labor. In the ovum nutriment is stored up for the new being that will be formed; it consequently grows to a considerable size. During the maturation divisions all the nutritive material is retained by one cell; the polocytes receive none of it, the ovium contains it all. On account of the mass of nutritive material the ovium becomes heavy and is not in a condition to move toward a union with the male germ-cell; it must await it. In the spermatocytes of the first order there is, in the first place, much less nutritive material stored up, and, in the second place, it is equally distributed among all the four spermatids during the maturation divisions; and, in order that they may be able to seek out the ovium, each of these four spermatids must be further modified into spermia. While, therefore, from each oöcyte of the first order but one ovium capable of being fertilized is produced, from each spermatocyte four spermia arise, and thus there are formed from an equal number of spermatocytes and oöcytes of the first order four times as many fertilizing spermia as there are fertilizable oides. And yet this difference, as we shall see later, does not represent, even approximately, the numerical relations of the mature ova and the spermia.

It must be noted, however, that so far as man and the mammals are concerned the comparison of the oögenesis and spermatogenesis shown in Boveri's diagram is not quite free from objection, for it is doubtful if the oögonia and spermatogonia can be exactly homologized in these forms. For although both arise from the germinal epithelium, nevertheless they appear to belong to different cell generations. In the male, according to recent observations, the germ-cells have their origin from cells which correspond to those of the medullary cords of the ovary; the ingrowths which give rise to the germinal cords, in which the ova develop, have no homologue in the testis. The annexed diagram will make this clear.

Bonnet[24] imagines that exceptionally the polocytes may also be fertilized and give rise to embryomata.

As regards the number of germ-cells which may normally be produced, Hensen estimates that a human female develops in each ovary about 200 ova ripe for fertilization. Lode[25] found in 1 c.mm. of a human ejaculate 60,876 spermia, and from that calculates for the entire ejaculate, which averages 3373 c.mm., over 200 million spermia, so that during his life a man may produce about 340 billion spermia. Consequently for every mature ovium there are about 850 million spermia.

Finally, the question is to be considered whether the sex of the future individual is in any way determined in the germ-cells, the ovium or spermium. In the chapter on the development of the urogenital organs it will be shown that with our present methods of observation the sex of the human embryo cannot be determined before the fifth or sixth week of development; as is well known it has been supposed that during the earlier stages of pregnancy influences may be brought to bear which will determine the formation of the one or the other sex. This, however, seems to be impossible, since whether the developing organism shall be of the male or the female sex is, apparently, already determined at fertilization. This is indicated by the fact that twins and double monsters formed from a single ovum are always of the same sex. Most observers now incline to the belief that the sex is always determined before fertilization in the ovium, that there are mature ova (ovia) from which only females and others

---

[24] Bonnet: Zur Aetiologie der Embryome, Greifswald. med. Verein, Bericht in Münchener Med. Wochenschrift, 1901, p. 315.

[25] A. Lode: Untersuchungen über Zahlen und Regenerationsverhältnisse der Spermatozoïden bei Hunde und Mensch, Arch. f. ges. Phys., 1891; also, Experimentelle Beiträge zur Physiologie der Samenblasen, Sb. K. Acad. Wiss. Wien., Abt. 3, vol. civ, p. 33, 1895.

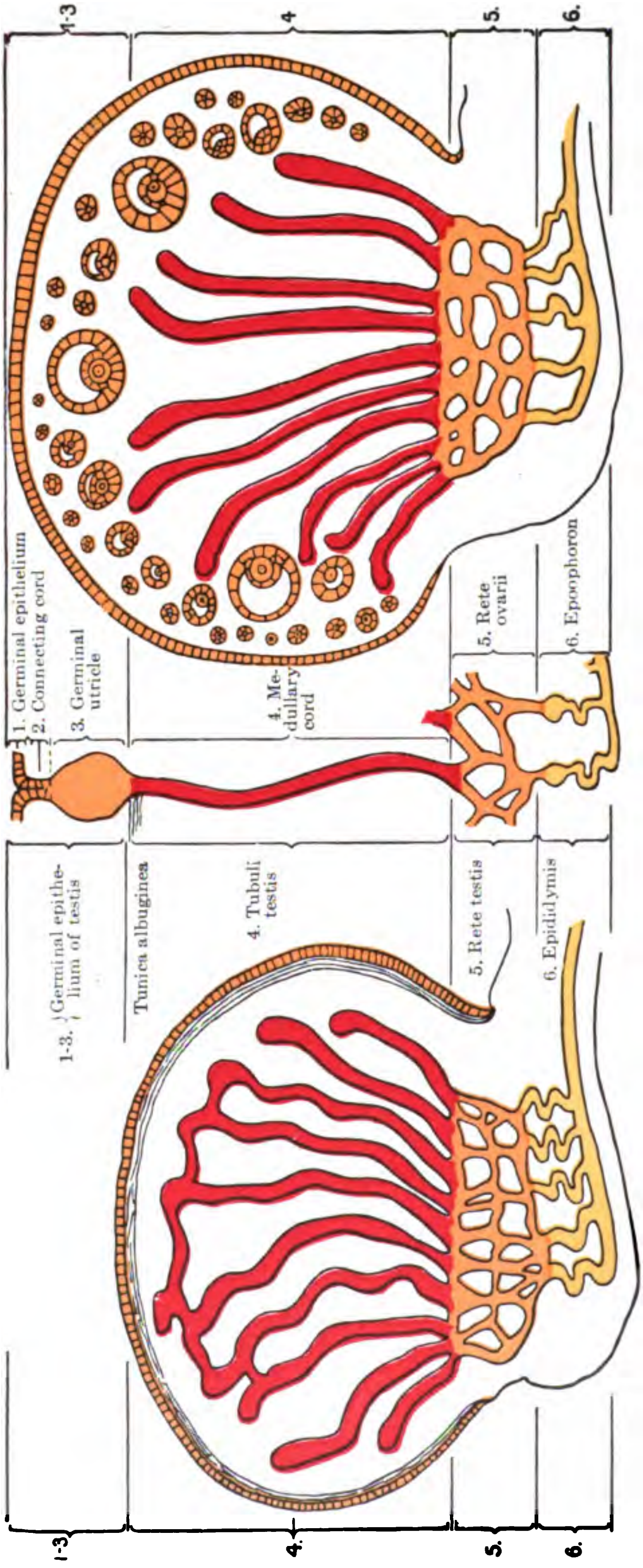

FIG. 8.—Diagram showing a comparison of the testis and the ovary (based on the results of Winiwarter and Waldeyer). The germinal epithelium of the testis corresponds to portions 1–3 of the ovary.

from which only males can be formed. In my opinion the question is not yet settled so far as man and the vertebrates are concerned, but it is certain that in many invertebrates the sex is already determined in the egg. How the germ-cells of the human female or male may be influenced so that they will produce either the one or the other sex has been frequently discussed, but none of the conclusions will stand serious criticism. Nussbaum[26] has shown that in the rotifer *Hydatina senta* the sex of the progeny is determined while they are still within the body of the mother, since all poorly nourished females deposit eggs from which males develop, while from the eggs deposited by well-nourished females only females were formed. All the eggs of any one female produce the same sex and neither fertilization nor any treatment after fertilization has any effect. In an extensive series of observations on a mammal, the mouse, O. Schultze[27] did not succeed in influencing the sex character; no influence was exerted by the age or the difference of age of the parents, by the age of the sexual products, by in-breeding or by incest-breeding, by sexual appetency, etc. For further consideration of the question reference may be made to Henneberg[28] and Lenhossék.[29]

---

[26] M. Nussbaum: Die Entstehung des Geschlechts bei *Hydatina senta,* Arch. f. mikr. Anat., vol. xlix, p. 227–308, 1897.

[27] O. Schultze: Zur Frage von den geschlechtsbildenden Ursachen, Arch. f. mikr. Anat., vol. lxiii, p. 197–257, 1903.

[28] B. Henneberg: Wodurch wird das Geschlechtsverhältnis beim Menschen und bei den höheren Tieren beeinflusst? Ergebnisse der Anat. und Entwicklungsgesch., vol. vii, p. 697–721 (Lit., 1897), 1898.

[29] M. von Lenhossék: Des Problem der geschlechtsbestimmenden Ursachen, Jena, 1903.

II.

FERTILIZATION.

By FRANZ KEIBEL, Freiburg i. Br.

Nothing is known concerning the fertilization of the human ovum, but it may be presumed that it takes place in essentially the same manner as in other mammals, and for an account of the process in these forms reference may be had to the works of Sobotta and Leo Gerlach, cited in the preceding chapter. The usual place for fertilization must be the first portion of the tube. That the spermia penetrate into the tube has been observed (Dührssen: *Sb. d. Ges. f. Gyn. und Geburtsh. in Berlin,* 1893; and Zweifel: "Lehrbuch der Geburtshilfe," 3 Aufl., 1902), and is also made certain by the occurrence of tubal pregnancies. Occasionally the union of the ovum and sperm-cell may take place upon the surface of the ovary or even in the interior of the Graafian follicle, as is definitely shown by rarely occurring cases of ovarian pregnancy (see Freund and Thomé,[1] and Bryce, Teacher, and Kerr [2]). Accurate estimates of the rapidity of penetration of the spermia into the uterus and tubes are not available, but it may be supposed that in one or two hours after coitus the spermia have penetrated far into the tubes. That fertilization of the ovum may take place after it has reached the uterus seems to me from observations on other mammals very improbable; at all events no good grounds for such a supposition seem to exist. Nevertheless Wyder [3] regards the uterus as the normal site of fertilization; and other gynæcologists—Hofmeier, for example—agree that fertilization may occasionally take place in the uterus. Waldeyer also comes to this conclusion and states (Hertwig's "Handbuch," vol. i, p. 370) that, "It cannot be denied, however, that under certain circumstances fertilization may first occur in the uterus"; he does not state, however, what these circumstances may be.

---

[1] H. W. Freund and R. Thomé: Eierstockschwangerschaft, Virch. Arch., vol. clxxxviii, pp. 54–91.

[2] Bryce, Teacher, and Kerr: Contributions to the Study of the Early Development and Imbedding of the Human Ovum, Glasgow, 1908.

[3] Th. Wyder: Beiträge zur Lehre von der Extrauterinschwangerschaft und dem Orte des Zusammentreffens von Ovulum und Spermatozoen, Arch. f. Gynäkol., vol. xxviii, 1886.

III.

SEGMENTATION.

BY FRANZ KEIBEL, FREIBURG I. BR.

THE segmentation stages of the human ovum have not yet been observed. We may with certainty assume that the early stages of fertilization are passed through during the passage of the ovum through the tube, but whether the entire segmentation takes place during this passage, or in what stage of segmentation the ovum reaches the uterus, cannot even be conjectured. In mammals there are apparently differences in this respect. The time, also, that the human ovum requires for the passage of the tube is very difficult to estimate; according to the data obtained from other mammals it cannot well be believed that the uterus is reached before the fifth day. Similarly, it is unknown whether the ovum becomes imbedded in the mucous membrane immediately after it has reached the uterus. That it is possible by good fortune and persistency yet to observe segmenting human ova in the tube is shown by the observations of Letheby[1] and Hyrtl (in a work by Bischoff[2] and in Froriep's "Neue Not.," 1852, No. 603), who discovered ova in the tube, although they were not able to make observations of the segmentation, partly on account of the imperfections of their technic and partly because the ova were unfertilized. The relative certainty with which experienced embryologists are able to-day to obtain the segmentation stages of even large mammals is an encouragement for further efforts in this direction. The force which propels the ovum through the tube into the uterus is the ciliary action of the tubal epithelium, and injury to this epithelium may be the cause of the retention of the ovum in the tube or in a diverticulum of it and so the cause of a tubal pregnancy. If the ciliary current is not impaired, the ova are readily driven over any diverticula that may exist (Krömer[3]).

---

[1] H. Letheby: An Account of Two Cases in which Ovules or Their Remains Were Discovered in the Fallopian Tubes of Unimpregnated Women who Had Died during the Period of Menstruation, Philos. Transact. Royal Soc. London, 1852 (altogether unsatisfactory). See also Froriep's Neue Notizen, 1852, No. 603.

[2] Th. L. W. Bischoff: Beiträge zur Lehre von der Menstruation und Befruchtung, Zeitschrift für rationelle Medizin, neue Folge, vol. iv, 1854.

[3] P. Krömer: Untersuchungen über den Bau der menschlichen Tube, Leipzig, 1906.

It may be regarded as quite certain not only that the human ovum undergoes a segmentation quite similar to that of the other mammals, but also that it is a secondary total segmentation. The ancestors of the human species, like those of other mammals, must have once possessed yolk-laden meroblastic ova. A separation of the segmentation cells according to their developmental potencies has been variously postulated for the earlier stages of the mammalian segmentation, but conclusive evidence for this is lacking, the observations hitherto made not being capable of such an interpretation. This is true also of the observations which have been supposed to indicate the existence of a gastrulation process in the later stages, but this question will be considered in the chapter dealing with the formation of the germ layers and the gastrulation problem. Finally, it may be noted here that Hubrecht has recently succeeded in finding the ovum of a monkey in segmentation. It has been figured in the posthumous paper by Selenka which I have edited ("Menschenaffen," 5 Lief., Zur vergleichenden Keimesgeschichte der Primaten, Wiesbaden, 1903) and is reproduced here (Fig. 9), since it is the only primate ovum in a segmentation stage at present known. Selenka states concerning this ovum, which was found in serial sections of a tube of a *Macacus nemestrinus* from Java: "At about the middle of the oviduct was the ovum, having a diameter of 0.04 mm. and loosely attached to the somewhat frayed out ciliated cells. The largest of the approximately ripe ovarial ova were of about the same size. Four segmentation cells of about equal size are clearly to be distinguished; two of these (the central and left upper ones in the figure) are irregularly oval, the other two are almost spherical. The cells are naked; no trace of an enclosing membrane is to be observed. The shrinkage which the tissues of the oviduct show suggests the idea that the segmenting ovum no longer retains its natural condition. It is, however, of importance to note what the preparation reveals: The segmentation begins in a manner similar to that of other higher mammals, and it is probable that it is completed as soon as the ovum has entered the uterine enlargement." This last conclusion I cannot accept.

FIG. 9.—Ovum of a monkey in segmentation, from the tube of a *Macacus nemestrinus* Demarest. × 400. (From Selenka: "Menschenaffen," 5 Lief., Fig. 1, p. 331, 1903.)

IV.

YOUNG HUMAN OVA AND EMBRYOS UP TO THE FORMATION OF THE FIRST PRIMITIVE SEGMENT.

(A CRITICAL ACCOUNT)

BY FRANZ KEIBEL, FREIBURG I. BR.

BY the term ovum is understood in human embryology not only the egg-cell but also later the entire structure developed from the egg-cell, the embryo or fetus surrounded by the amnion and chorion. In this sense the word is used here. I do not intend to enumerate and describe here all young and very young human ova that have been observed, but only those which may be regarded as normal or approximately so, and as such I can regard only those in which an embryo has been observed. The observations of Graf Spee and Peters on human ova, and of Selenka on those of monkeys, have shown that in man and the primates the chorion grows much more rapidly than the embryo, that, consequently, a relatively large ovum may contain a very small embryo, and that even in the youngest ova yet studied the amnion and the yolk sack are already formed. I shall show later that in all probability the embryo never lies free upon the surface of the ovum, as it does in the birds and in many mammals, but that from the beginning it is sunk in the interior of the ovum, and that the amniotic cavity arises as a cleft and not by the formation of folds, and is always closed. The extraordinary minuteness of the embryonic anlage is a sufficient explanation why in early times, when the methods of investigation were imperfect, it was overlooked or unrecognized; many of these earlier described ova may have been normal or nearly so. But when no embryonic anlage is found in an ovum that has been investigated according to all the rules of modern technic, as is the case with that which G. Leopold[1] has lately studied with so much care, that ovum is certainly to be regarded as pathological; and the occurrence of maternal blood in the interior of the ovum is further evidence in this direction, as Spee has pointed out in Schwalbe's *Jahresbericht*. Leopold's

---

[1] G. Leopold: Ueber ein sehr junges menschliches Ei, Arb. Kgl. Frauenklinik, Dresden, vol. iv, Leipzig, 1906.

ovum does not, therefore, require consideration here; on the other hand, some older observations may be noticed, such as those of Reichert, Wharton Jones, and Breuss. The ovum of Reichert especially has played and is still playing, though improperly, an important rôle in human embryology.

Reichert[2] found the ovum in the uterus of a suicide and estimated its age at twelve to thirteen or thirteen to fourteen days. It was completely enclosed by the mucous membrane of the uterus. On the side of the capsule which was turned towards the uterus there was a transparent area measuring 3 mm., which Reichert termed the capsule scar, believing that at the sides of it the mucous membrane of the uterus had grown up to surround the ovum. The ovum itself was a lenticular vesicle, whose diameters were 5.5 and 3.3 mm. The surface of the vesicle which was turned towards the uterus, the basal surface, was almost flat, that turned toward the lumen of the uterus somewhat curved. The marginal zone was richly furnished with small villi, the largest of which were 0.2 mm. in length and were already partly provided with lateral branches. From the margin small villi, diminishing in size, extended for some distance upon the surface of the vesicle turned toward the uterus wall (the basal surface of Reichert); but at the centre of the surface an area of about 2.5 mm. diameter remained free from them. In the centre of this free area Reichert described a dull circular spot. The surface of the ovum turned toward the lumen of the uterus was free from villi. The statements that Reichert makes concerning the finer structure of the ovum are in part insufficient and in part quite erroneous. Thus the wall of the ovum could not have been, as he supposed, purely epithelial, nor the villi hollow epithelial structures, but the wall must have been formed of mesodermal tissue with an epithelial covering and the axes of the villi occupied by mesodermal tissue. Reichert, indeed, perceived this mesodermal tissue, but regarded it as coagulated material. Also what he says concerning the ingrowth of the villi into the uterine glands is undoubtedly incorrect. As regards the structure of the dull spot on the uterine surface of the ovum, he supposed that it was formed by a layer of small, finely granular, nucleated, polyhedral cells, situated within the epithelial wall. It was taken for the embryonic anlage, and His has estimated the diameter of this "embryonic spot" as 1.6 mm. That this spot really represents the uninjured embryonic anlage is improbable, and Kollmann's statement in his "Handatlas der Entwicklungsgeschichte des Menschen" (1907)—"From what we know from the mammals this spot would now be regarded as the embryonic shield"—is, as will be shown later, absolutely disproved. A definite opinion cannot be given on account of the insufficiency of Reichert's description; nevertheless, I regard as well founded the conclusion of Spee, that Reichert had destroyed the actual embryonic structure during his preparation of the ovum and that in its degree of development it would have occupied a place between the ovum of Peters, to be described in detail later, and the Van Herff ovum of Spee. Probably Reichert had casually observed the embryo; it may have been the spherical body on the basal wall which he mentions on p. 26.

Another ovum which deserves mention is that described by Wharton Jones[3] in 1837; it was of the size of a pea. The figure drawn from the preparation in alcohol shows a diameter of 6.2 × 4.7 mm. The surface turned toward the lumen

---

[2] Reichert: Beschreibung einer frühzeitigen menschlichen Frucht im bläschenförmigen Bildungszustande, etc., Abh. Kgl. Akad. d. Wiss., Berlin, 1873.

[3] Thomas Wharton Jones: On the First Changes in the Ova of the Mammifera in Consequence of Impregnation and on the Mode of Origin of the Chorion, Philosoph. Transact. Royal Soc. London, 1837, p. 2.

of the uterus was free from villi. Imbedded in the cavity of the ovum was a spherical body, with a diameter of 1.5 mm., which His, probably correctly, identified as the embryonic structure, that is to say, the actual embryonic anlage together with the amnion, yolk sack, and belly stalk. His assumes that this embryonic structure may have been artificially displaced.

Next comes an ovum described by Breuss[4] in 1877. It was expelled together with the entire lining of the uterus. The wall of the ovum, which had a diameter of 5 mm., consisted of two layers, the outer of which was epithelial and the inner formed of connective tissue. The villi were for the most part unbranched and were about 1 mm. in length and 0.07 mm. in diameter; they left free a roundish area 2 mm. in diameter. Vessels could not be distinguished in their interior. A projection which occurred in the interior of the ovum, consisting of nucleated cells and having a length of 1 mm. and a diameter of 0.5 mm., may have been the embryonic structure. If it is assumed that the ovum was normal, we must suppose that Breuss overlooked the amniotic cavity and the cavity of the yolk sack, a supposition which I regard as possible.

Mention may also be made of two other ova, described by Allen Thomson.[5] In one of these the embryonic structure must be regarded either as pathological or as not corresponding to the degree of development of the ovum. Thomson estimates the age of the smaller of the two ova at twelve to thirteen days. It had a diameter of 6.6 mm., was everywhere surrounded with villi, and was almost completely filled by a vesicle which was apparently the yolk sack. Upon the yolk sack was an embryo 2.2 mm. long and with both its cranial and caudal ends separated from the sack. Thomson makes no mention of an amnion, but we may suppose that it was present and covered the embryo on the surface opposite the yolk sack; and a belly stalk must also have been present, since Thomson states that the embryo was attached by its dorsal surface to the external egg membrane, that is to say, to the chorion.

Although the ovum is larger than that of His, to be described below, the second observation of Thomson may be recorded here; it concerns an ovum measuring 13.2 mm. in diameter, whose age was estimated at fifteen days. It was oval in shape and was evenly surrounded with villi. In the interior was a large cavity filled with fluid; and at one spot was the embryo, closely attached to the chorion and with a yolk sack and the remains of the amnion. The embryo had a length of 2.2 mm. and its cranial and caudal ends projected somewhat beyond the yolk sack. Viewed from the surface turned toward the chorion, it showed distinctly the medullary folds, which manifested a tendency to fuse at the middle of their length; ventrally was the heart. The diameter of the yolk sack was also 2.2 mm.; nothing is said concerning an amnion, but a lobe which is shown in Thomson's figure at the head end of the embryo is apparently the remains of an amnion that had been destroyed during the preparation of the embryo. It is interesting to note that Kölliker[6] in 1879 regarded this second ovum described by Thomson as not quite normal on account of the large space which separated the embryo and yolk sack on the one side from the inner surface of the chorion on the other. We now know that this is the normal condition in embryos of this stage; and it is rather the smaller of Thomson's ova, which Kölliker was inclined to regard as normal, that shows abnormal conditions, since the yolk sack never fills the chorion so completely either in human or mammalian ova of this stage.

In all the ova so far mentioned a correct identification of the embryo, the

---

[4] K. Breuss: Ueber ein menschliches Ei aus der zweiten Woche der Gravidität, Wiener med. Wochenschrift, 1877, pp. 502–504.

[5] Allen Thomson: Edinburgh Med. and Surg. Journal, vol. ii, 1839; and Froriep's Neue Notizen, vol. xiii, 1840.

[6] A. Kölliker: Entwicklungsgeschichte des Menschen, 1879.

yolk sack, amnion, belly stalk, and chorion is possible only in the two described by Thomson, which contained embryos already rather well developed; and even in these the identifications were only general ones, as may be seen from Kölliker's comments upon the ova. He regarded, on the basis of the information available at that time, the normal ovum as abnormal and the abnormal one as normal, and the same conclusion was reached by Ecker, another distinguished embryologist of the time. A definite idea of the relations of the amnion and the belly stalk was also impossible for Kölliker. A correct interpretation of the discoveries mentioned could not be given at the time of their publication and, indeed, in part, not for some time after. The investigators who sought such interpretations were led from the right path, and Reichert's ovum, as I have stated, gave rise to many false ideas, even up to recent times. Consequently, as Elze and I[7] have already pointed out in our "Normentafel zur Entwicklungsgeschichte des Menschen," an observation by His[8] marks an important advance. The ovum in question (No. XLIV [Bff.] of His's collection) had a greater diameter of 8 mm. and, at right angles to this, a diameter of 7 mm.; it was somewhat flattened and at one point the villi were somewhat fewer than elsewhere. "On opening it there was found, on one wall, a small body measuring 1.4 mm. in its longest diameter and consisting of an ellipsoidal opaque body with a transparent vesicle attached to it. The opaque body, which seemed from partial foldings of its surface to be hollow, had a greater diameter of 0.85 mm. and a diameter at right angles to this of 0.6 mm. The transparent vesicle surrounded by its border one end of the ellipsoid. The connection with the chorion was by means of a short stalk, which stood in relation to both the vesicle and the ellipsoid." "I regard," His says in another place, "the more solid body as the umbilical vesicle and the transparent part as the amnion, and conclude from this that the embryonic anlage, so far as it is present, lies at the boundary between the two. With this idea the manner in which the structure is attached to the chorion agrees. That is to say, the place of attachment lies on the boundary between the vesicle and the opaque body." His's interpretation, we can say to-day with all certainty, is in agreement with the actual facts, and His was the first to give a perfectly correct interpretation of a human ovum of this stage. He further reported concerning this ovum that to the lower pole of the yolk sack there were attached threads of that looser tissue "which traverses the cavity of the ovum, one of these threads being especially distinguished by its tougher consistency and its opacity."

Later observations of young human embryos, carried out with the methods of modern technic, and especially with the aid of well stained and perfect series of sections, have, as has been already stated, confirmed His's views and have led to further, partly unexpected, results. It was the observations of Graf Spee, especially, that opened the way, and, later, H. Peters rendered great service; but for the sake of continuity the ova in question will not be described in the order in which they were discovered, but according to their degree of development. Consequently I shall begin with the ovum described by Bryce and Teacher.[9]

The ovum was obtained from an abortion, and although the preservation of the embryo proper is not perfect yet it is of the greatest importance; Fig. 10 shows the ovum as it lay in the uterine mucous membrane, according to a diagram by Bryce. With the exception of a small area it is completely surrounded by

---

[7] Franz Keibel and Curt Elze: Normentafel zur Entwicklungsgeschichte des Menschen, Jena, 1908.

[8] W. His: Anatomie menschlicher Embryonen, Leipzig, 1882, part ii, pp. 32 and 87 *et seq.* See also Mall, Journ. of Morph., vol. xix, p. 151.

[9] Bryce, Teacher, and Kerr: Contributions to the Study of the Early Development and Imbedding of the Human Ovum, Glasgow, 1908.

decidua, and the opening in the decidua (capsularis) is closed by coagulated fibrin containing leucocytes. A large opening with fungoid tissue (the closing coagulum of Bonnet) is wanting.

The ovum, surrounded with blood, lies in a relatively large chamber, with whose walls it is not united; the maternal and fetal tissues are quite separate. The innermost layer of the decidua, which forms the capsule of the ovum, is in an advanced stage of coagulation necrosis and, together with some deposits of fibrin, forms around the ovum a capsule of dead tissue, which is interrupted only at one or two places, where blood-vessels open into the egg chamber, and at one where a hemorrhage has broken through into it.

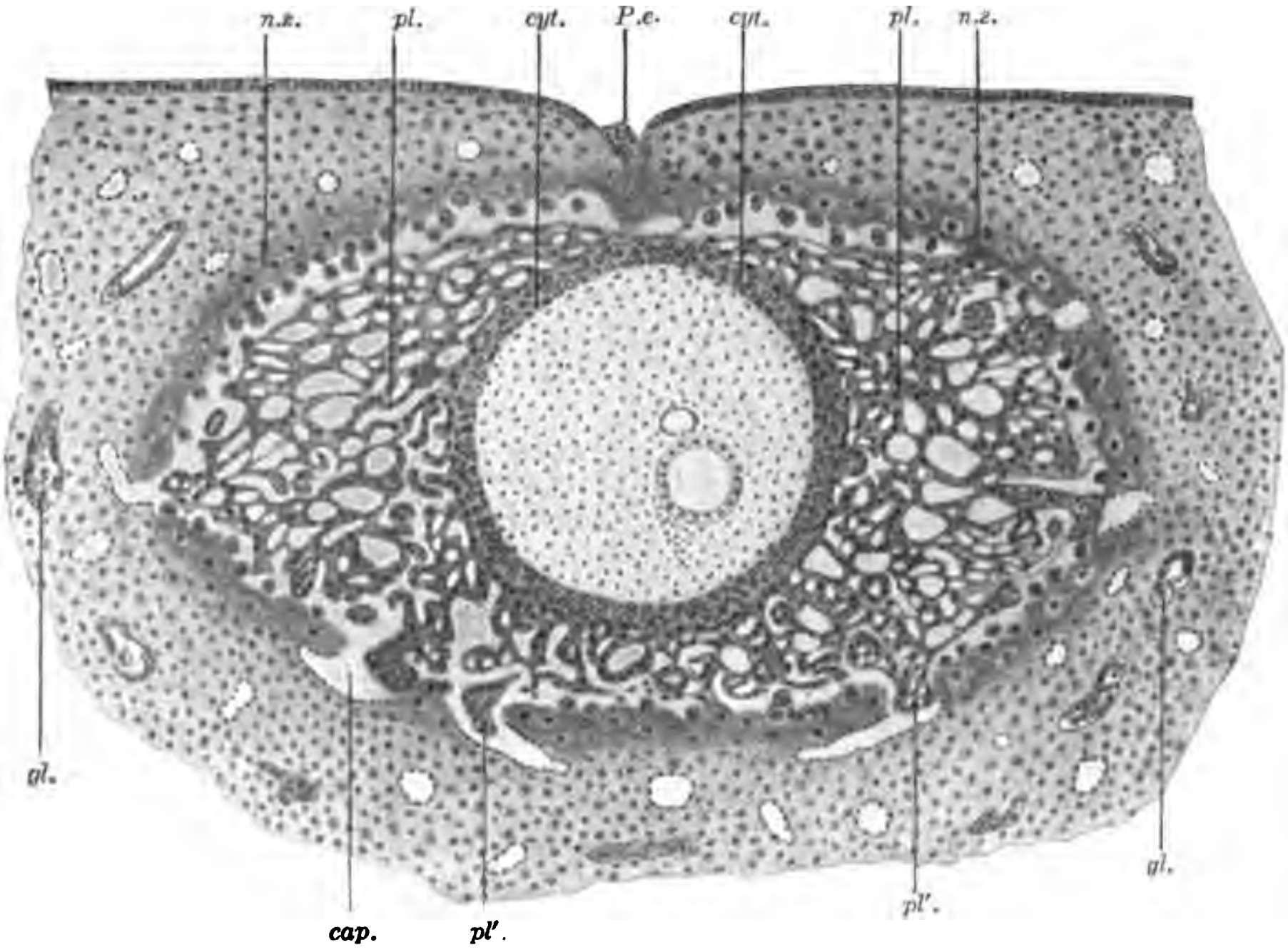

Fig. 10.—Diagram of the ovum of Teacher and Bryce, after Bryce. *P.e.*, point of entrance; *cyt.*, cytotrophoblast; *pl.*, plasmoditrophoblast; *n.z.*, necrotic decidua zone; *gl.*, glands; *cap.*, capillaries; *pl'.*, vacuolized plasmodia which are penetrating capillaries. The cavity of the ovum is completely filled with mesoblast, and in this the medullo-amniotic and entodermic (intestine-yolk sack) vesicles are imbedded. The natural proportions of the various parts have been accurately preserved. × 50. (From Contributions, etc., 1908, p. 41, Fig. VII.)

The wall of the ovum consists of an inner layer (the cytotrophoblast, the layer of Langhans's cells), whose cells are poorly separated from one another and externally pass over into a very irregularly arranged plasmoditrophoblast; this has a distinctly plasmodial character and forms a loose network, whose spaces are filled with maternal blood. The cytotrophoblast is nowhere continued into the plasmoditrophoblastic trabeculæ.

The cavity of the ovum is occupied by a delicate tissue which has the characters of mesenchyme. This primitive mesoblast shows no traces of a splitting into a parietal and a visceral layer; there is, accordingly, no cœlom. Also, projections of the mesoblast toward the cytotrophoblast (mesodermic villi) are not yet present.

The embryonic structures (the embryo together with the amnion and yolk sack) are represented by two vesicles which have an excentric position, and are completely separated from the cytotrophoblast by the mesenchymatous tissue.

The cavity of the larger vesicle is supposed to be the amniotic cavity and that of the smaller the cavity of the yolk sack. The cells which enclose the amniotic cavity are cubical and those enclosing the yolk sack are flattened, but in neither vesicle do they show individual differentiation.

The egg-chamber is oval in form, the longest axis, lying parallel to the surface of the uterus, measuring 1.95 mm.; perpendicular to this and also parallel to the uterine surface the lumen of the egg-capsule measures 1.1 mm. and its depth (perpendicular to the surface of the uterus) is 0.95 mm. Since the wall of the ovum itself is folded the measurements of the cavity can be stated only approximately as 0.77 and 0.63 mm. The relative sizes of the amniotic cavity and of the yolk sack may be perceived from Fig. 10; unfortunately these structures were not intact.

The estimate of the age of the ovum made by Teacher and Bryce is very interesting and important, since it is based on exact data concerning the menstruation and the cohabitations. They estimate the age at thirteen to fourteen days, the ovum having been expelled sixteen and one-half days after the fertilizing coitus. The cause of the abortion is supposed to have been a later coitus. If this estimate be correct the other ova to be described later on are all older than has hitherto been supposed. The table given by Bryce and Teacher may be reproduced here.

TABLE I. (From Bryce and Teacher.)

Chronological table of twelve well-described early pregnancies. Fertilization is assumed to be effected about 24 hours after insemination, and 24 to 48 hours are allowed for the completion of abortion. The leading data are supplied by the histories of Nos. 1, 4, 5, 8, 9, 10; and the position of the remainder is adjusted according to their dimensions and state of development. The ages according to the convention of His are shown in the column headed, "Days elapsed from omitted period."

Number.	Author.	Dimensions in millimetres.			Days elapsed			Age in days.	Remarks. How obtained.
		Ovum.		Embryo.	From beginning of last period.	From end of last period.	From omitted period.		
		External.	Internal.						
1	TEACHER-BRYCE..	1.95×0.95×1.10	0.77×0.63×0.52	about 0.15	38	34	10	13–14	Abortion 16½ days after cohabitation.
2	PETERS	2.4×1.8	1.6×0.8×0.9	0.16	30	..	2	14–15	Suicide. Autopsy.
3	JUNG..............	....	2.5×2.2×1.0	....	32	..	..	14½–15½	Periods every 5–6 weeks. Curetting on account of leucorrhœa.
4	MERTTENS	4.0×3.0	3.0×2.0	....	21	16	..	14½–15½	Curetting.
5	BENEKE	....	4.2×2.2×1.2	like 6 but young'r	25	20	..	16–17	Curetting.
6	VON SPEE (VON HERFF)	6.0×4.5	4.0	0.37	40	..	12	17–18	Abortion two days after beginning of influenza.
7	LEOPOLD..........	6.0×6.5	4.0×3.7	....	15	10	..	17–18	Hysterectomy; carcinoma of cervix. Menstruation during pregnancy (?).
8	REICHERT	....	5.5×3.3	....	42	..	14	17–18	Sudden death. Autopsy.
9	ROSSI DORIA	9.0×8.0	6.0×5.0	....	28	24	..	18–19	Abortion with sudden beginning and three days' retention.
10	ÊTERNOD	10×8.2×6.0	6.0×4.8×3.6	1.3	34	..	6	18–19	A single cohabitation 21 days before abortion.
11	FRASSI............	13×5.0	9.4×3.2	1.17	42	..	14	18–19	Hysterectomy; metritis chronica.
12	VON SPEE (GLAEVECKE)	....	10×8.5×5.5	1.54	40	..	12	19–20	Recent abortion.

TABLE II. (From Bryce and Teacher.)

Showing the relation of the dates of fertilization and of imbedding to the menstrual cycle, calculated from the data given in Table I. The higher figure in the age column is arbitrarily chosen in each instance, and allowance is made for the special circumstances of each case.

Fertilization.	Days of menstrual period.	Imbedding.
	1	
	2	
	3	
	4	
	5	
Merttens	6	
Rossi Doria	7	
Beneke	8	
	9	
	10	
	11	
	12	
	13	Merttens
Êternod	14	Rossi Doria
	15	Beneke
Peters	16	
Jung	17	
	18	
Von Spee (Glaevecke)	19	
	20	
Von Spee (Von Herff)	21	Êternod
	22	
Frassi	23	Peters
Teacher-Bryce and Reichert	24	Jung
Leopold	25	
	26	Von Spee (Glaevecke)
	27	
	28	Von Spee (Von Herff)
	Days of succeeding menstrual period.	
	1	
	2	Frassi
	3	Teacher-Bryce and Reichert
	4	Leopold
	5	
	6	
	7	
	8	
	9	
	10	

We now come to the ovum described by Hubert Peters[10]; it was obtained at the autopsy of a woman who had poisoned herself with caustic potash. Death had occurred within three hours after the taking of the poison and the autopsy was performed on the same day, a few hours after death. The ovum, together with the entire egg capsule, fixed by Prosector Kretz in Müller's fluid and hardened in alcohol, was successfully stained and microtomized by Hochstetter; it found in Peters an exceedingly careful observer. The uterus, from which the ovum was taken, was the size of a goose's egg, and thick-walled, and felt somewhat more doughy and softer than a normal uterus. "The decidua of the corpus uteri was traversed by numerous furrows which crossed one another at various angles and occasionally formed grooves, so that the mucous membrane between

---

[10] Hubert Peters: Ueber die Einbettung des menschlichen Eies und das früheste bisher bekannte menschlichen Placentationsstadium, Leipzig und Wien, 1899.

these bounding furrows formed root-like or occasionally rounded projections toward the uterine lumen. In the middle of the posterior wall Prosector Kretz noticed a small area which was of the size of a hemp seed, which was somewhat paler but not prominent"; it contained the ovum. This was ellipsoidal in form, its diameters being 1.6 × 0.8 × 0.9 mm., these measurements, however, being of the cavity of the egg capsule. The part of the decidua in which the ovum lay presented, as the study of the sections showed, a slight, rounded elevation toward the cavity of the uterus. "While the decidua stretched as a very thin sheet, in the form of a capsularis, over the lateral portions of the ovum, the summit of the ovum was quite free from maternal tissue and projected freely into the lumen of the uterus by means of a blood-granulation mass which rested upon it"; this mass Peters terms the fungoid tissue (Gewebspilz). If the interpretation which Peters gives of the fungoid tissue is correct and it is not a post-mortem phenomenon or a result of the poisoning, we have for the first time a human ovum that is not yet quite covered by a capsularis. Later Spee (*Verh. Anat. Ges.,* 1902 (discussion of Marchand's paper); compare Schwalbe's *Jahresber.,* n. F., vol. viii, No. 2, p. 298) stated that occasionally young ova were to be found in which the egg capsule had an opening toward the uterus at the place where the scar tissue occurred, and at the corresponding place the ovum of Bryce and Teacher showed, as has been mentioned, only a small opening and no well-marked fungoid tissue. Upon the mesoblast layer of the ovum, which shows indications of the first few and as yet but slightly developed villi, follows a layer of epithelial cells, which reaches in places a thickness of more than 0.5 mm. and is traversed in a honeycomb manner by smaller and larger blood lacunæ, but still remaining continuous at the periphery. Peters interprets this rightly, as I believe, as an "ectoblast shell" and names it the trophoblast, adopting the term which Hubrecht had proposed as a result of his observations on the hedgehog. Its further significance will be fully considered in the chapter on placentation and it will there also be compared with the corresponding structures of other mammals (cheiroptera) and with what is found in older human ova (Kastschenko, Merttens, Von Herff). As in the ovum of Bryce and Teacher differentiation of the cells of the trophoblast investment was evident, and the cytotrophoblast (Langhans's cells) and the spongiotrophoblast were distinguishable.[11]

The embryonic anlage in this remarkable ovum was extraordinarily small, the embryo measuring, as estimated from the sections, 190 μ in length. I quote, as Peters has done, the description which Graf Spee has given of the cavity of the ovum. "The entire cavity of the ovum enclosed by the chorionic ectoblast [trophoblast shell, cytotrophoblast, and spongiotrophoblast] is filled up to the cavities of the embryonic anlage with mesoblast. This latter is very irregular as regards its possession of mesoderm cells. These are more numerous in the mesoderm layer resting upon the chorion, this consisting of two or at the most four cell-layers, presenting a greater thickness only in the region where the embryonic anlage occurs." Exception must be made of those places where there occur the mesodermic rudiments of the villi, already mentioned. "The more central portions of the egg cavity are very poor in cellular elements. Only scattered tracts of spindle-shaped mesoderm cells traverse it. In the intervals there is a feebly staining fibrogranular mass which occupies most of the cavity. The cellular tracts frequently unite with the mesoderm enclosing the embryonic anlage and with that of the opposite wall of the ovum." Spee has found similar cords in all younger human ova.

---

[11] Those portions of the trophoblast which come into relation with the tissues of the uterine wall and take an active part in the implantation of the ovum and in the excavation of the egg chamber have been termed trophoderm by Minot (Charles S. Minot: The Implantation of the Human Ovum in the Uterus, Trans. Americ. Gynæcol. Soc., 1904).

"The embryonic anlage (cut obliquely in the preparations) shows two *very small* epithelial cavities (amnion and yolk sack), completely surrounded by mesoderm and contained within a thickening of the chorionic mesoblast. The amniotic cavity is completely closed. Its wall is differentiated into a very thin amniotic membrane, lying nearer the surface of the ovum, and a plate consisting of high cylindrical cells, the germinal disc (germinal shield, embryonic shield). Between these and the wall of the yolk sack, composed of entoderm cells occasionally difficult to recognize, a layer of mesoderm is interposed. At one (the cranial) end (section 49 [44, 43?]) the cellular portion of the mesoblast does not appear to reach the median line. It lies on the yolk sack and is separated from the ectodermal territory by a 'membrana prima.' This membrana prima (Hensen) always develops as a fine contour at the boundary between the ectoblast and mesoblast. It extends across the middle line in the preparations. . . . The series of sections clearly reveals the relations of most portions of the embryonic anlage. One end of the series only presents difficulties in the way of observation, partly on account of the unfavorable plane of the sections and partly, perhaps, on account of some complications in this region; for instance, it is impossible to determine the continuity of the ectoblast and mesoblast in some sections, and the condition of the yolk sack cannot be made out in this region." Spee considers this to be the caudal end. "An isolated cord connecting the embryonic structures with the chorion cannot be said to exist, since almost the entire embryonic anlage seems to be imbedded in a thickening of the chorionic mesoderm. Whether the first small rudiment of an entoblastic diverticulum (the allantoic duct) has begun to bud out and is represented by a ring of epithelium-like cells arranged around a lumen, is altogether uncertain." Grosser figures a section through the ovum *in situ* (see Fig. 96, from Peters's figure) in the chapter on the development of the egg membranes and the placenta. I have reconstructed the embryonic structures from plates left by Selenka and found neither an allantoic nor an amniotic duct. The surface of the yolk sack appeared warty, as if the blood and vessels were beginning to form upon it; naturally, the wax plates and the model give no definite information on this point.

The ovum which Graf Spee has described, unfortunately only briefly (*Verh. deutsch. Ges. Gynäk.*, 1905, pp. 421–423; compare Schwalbe's *Jahresb.*, n. F., vol. xi, No. 2, p. 241), comes nearest to that of Peters. In a woman poisoned by oxalic acid one of the swollen areas of the mucous membrane on the ventral wall of the uterus immediately in front of the opening of the right tube was markedly prominent and its depressed summit showed a distinctive coloration. In it was found, in an egg capsule of 1.5 × 2.5 mm. diameter, an ovum poorly provided with villi and with a very small embryonic anlage that was surrounded by a quantity of blood. The summit of the egg capsule showed an implantation opening, which was 0.8 mm. in diameter and covered by a very flat blood-clot; in its neighborhood the villi were more numerous than elsewhere. Very near is also an ovum studied quite recently by Ph. Jung[12]; it was obtained from an abrasio mucosæ. The preparation is splendidly preserved and apparently normal. Jung confirms in general the observations of Peters and Spee; comparatively little attention was devoted to the embryonic structures, and it is very desirable that these should be thoroughly studied. The cavity of the ovum measured 2.5 × 2.2 mm.

The Von Herff ovum described by Graf Spee[13] takes its place in the series here. It was expelled after a menopause of five weeks on the second

---

[12] Ph. Jung: Beiträge zur frühesten Eieinbettung beim menschlichen Weibe, with 20 figs. on 7 plates, Berlin, 1908.

[13] Graf von Spee: Neue Beobachtungen über sehr frühe Entwicklungsstufen des menschlichen Eies, Arch. f. Anat. u. Physiol., Anat. Abt., 1896.

day after a severe attack of influenza, probably as a result of the illness, and was apparently normal; it was throughout richly supplied with villi. Spee's remark that the diameters of the egg capsule, which he believes must have been really about 7 and 5½ mm., were actually greater than these, is based upon the fact that the capsule was strongly distended with blood. Since, however, the periphery of the ovum must have reached the maternal tissues such a condition cannot be regarded as normal, but must have arisen shortly before or during the abortion. Spee estimates the diameter of the space within the chorion at barely 4 mm. The thickness of the chorion was 0.9 mm.; the villi measured 0.16–0.18 mm. at the base and were separated from each other by intervals of 0.2–0.78 mm. where the distance could be determined. The villi were covered by a double layer of cells, the Langhans layer and the syncytium, the latter, although not so well developed as in later stages, being nevertheless quite distinct. Both layers are regarded as differentiations of the ectoblastic trophoblast shell, as cytotrophoblast (the Langhans layer) and spongioblast (the syncytium).

The embryonic structure had the form of an elongated thick papilla, attached at only one of its extremities to the chorion and elsewhere projecting quite freely into the interior of the cavity of the ovum (that is to say, into the periembryonic mesoderm space, the exocœlom of Selenka). Its long axis cuts the chorion at a very acute angle. A superficial furrow marks off on the papilla two elliptical portions. The larger of these forms the free pole of the papilla and proved to be the relatively very large yolk sack; the smaller one contains, on the surface which lies close to the chorion, a completely closed cavity, which was the amniotic cavity with its ectoblastic lining, but for the rest it is a compact cord composed of mesoderm, which extends from the mesoblastic covering of the yolk sack to the chorion, surrounding almost three-fourths of the amnion, so that this structure seems to be sunken into it. This part is the actual belly stalk and the sole connection with the chorion. In it there was an allantoic duct extending from the yolk sack. The portion of the ectoblastic lining of the medullo-amniotic cavity that rests on the yolk sack consisted of cylindrical cells and formed a thick plate, evidently the embryonic shield (the germinal disk). The plane of the embryonic shield is somewhat perpendicular, that is to say, radial, to the surface of the chorion, the head end being nearest it. In the model the embryonic shield presents an oval outline and a median furrow lying between lateral portions which are convex dorsally and are somewhat unequal in size in the transverse direction. At the same time the dorsal surface of the shield is adapted to the form of the amniotic cavity and is, on the whole, concave. Spee gives the following measurements:

"Direct measurements of the embryonic papilla: Longest diameter, 1.84 mm.; diameter through the constricted portion, 0.475 mm. Almost perpendicular to these the longest diameter of the yolk sack is 1.054 mm. The amnion together with the belly stalk measures 0.76 mm.; the greatest length of the two latter structures is 0.76 mm.; the greatest breadth of the yolk sack, 1.083 mm.; its thickness about the same.

"Measurements taken on the model (divided by 100 and so reduced to the actual size): Length of the germinal disk, 0.37 mm.; its breadth, 0.23 mm. (this is the ectoblast plate of the germinal disk); height of the amniotic cavity, up to 0.34 mm.; thickness of the belly stalk together with the amnion, 0.62 mm.; length of the allantoic duct, 0.35 mm."

An amniotic duct or cord was not present. The entire anlage of the germinal disk (embryonic shield) was apparently, according to Spee, only a portion of the primitive streak region, notwithstanding that the typical fusion of the ectoblast and mesoblast could not be recognized in the sections, probably as a result of the preparation. No trace could be found of a differentiation of the medullary plates or of the chorda. "The primitive streak region extends right up to the cranial end of the germinal disk" (the embryonic shield).

The walls of the yolk sack seem to have advanced further in development than any other part of the embryonic anlage. The lining of its cavity is throughout single-layered and formed by cubical cells. Its mesoblastic covering forms irregular elevations and knobs, which project like small papillæ, especially over the pole that is turned away from the embryonic shield. In each papilla a blood island was interposed between the mesoblast and entoblast and produced a bulging of the mesoblast, but very little irregularity of the entoblast. The formation of blood islands ceased at a much less distance from the embryonic shield in this ovum than in Von Spee's Glaevecke embryo, to be described later. The youngest stages of the blood islands lay nearest the embryonic shield; the oldest, at the distal pole of the yolk sack.

Near to this Von Herff ovum—indeed, according to the opinion of its finder somewhat younger—is that which Beneke[14] found in a curetting done for therapeutic reasons. The curetting was made March 30, 1903, the last menstruation having lasted from March 5 to 10. No cohabitation had occurred after March 22. The cavity of this ovum was 3.8 mm. long, 2.2 mm. broad, and 1.2 mm. high; and the embryo itself had a length of 1.74 mm.,[15] its greatest thickness in the dorsoventral diameter being 0.6 mm. The medullo-amniotic cavity was elongated caudally in a fusiform manner and was connected with the chorionic ectoblast by a cord of epithelial cells. It is stated that a typical medullary epithelium was already present in the anterior part of the germinal disk, and mention is made of a head process and of a chorda-like mass of cells. A neurenteric canal was present, but an allantoic duct was " not distinct." Although the statements in the brief description are not always as clear as could be desired, yet it seems to me, from the presence of a canalis neurentericus, of an amniotic duct or cord, and of an anlage of the medulla at the anterior end, that the embryo is more developed than that of the Herff ovum described by Spee.

A thorough study of the ovum is expected and when its results appear more definite conclusions will be possible; a thorough description may also make clear the meaning of certain peculiar structures that have been taken for blood-vessels, but which I shall not discuss here.

The embryonic anlage of an ovum described by Carlo Giacomini[16] was probably in about the same stage of development as the Spee embryo Von Herff; but on account of its poor preservation it would not have deserved mention here were it not that Giacomini states that it was expelled eleven days after a single cohabitation, so that its age may be estimated at nine or ten days, an estimate that does not agree with the conclusions of Bryce and Teacher that have been thoroughly discussed and reproduced above. The occurrence may also be noted of a small duct that opened on the surface of the chorion near the point of fixation of the embryonic structures and has been identified by Marchand[17] as the remains of an amniotic duct. A young ovum described by Mall[18] may also be mentioned here, although since it possessed a well-developed

---

[14] Beneke: Ein sehr junges menschliches Ei (Ost.-Westpreuss. Gesellsch. f. Gynäkol.), Deutsche med. Wochenschrift, Jahrg. xxx, 1904; and Mitteilungen und Demonstrationen mit dem Universalprojektionsapparat über ein sehr junges menschliches Ei, Marburger Sb., 1908, pp. 29–38.

[15] Surely a misprint.

[16] Carlo Giacomini: Un uovo humano di 11 giorni, Giornale della Reale Academia di Medicina di Torino, vol. iii, anno 60, Fasc. 10–11, Torino, 1897.

[17] F. Marchand: Beobachtungen an jungen menschlichen Eiern, Anat. Hefte, vol. xxi, 1903.

[18] Franklin P. Mall: A Contribution to the Study of the Pathology of Early Human Embryos, Johns Hopkins Hospital Reports, Festschrift for Welch, vol. ix, 1900. Also Journ. of Morph., vol. xix, p. 144, 1908.

allantoic duct, it may have been somewhat older. Its diameter favors this view. Its long diameter was 10 mm. and its short one 7 mm., and, like the Reichert ovum, it had villi only around its greatest circumference, two areas being thus bare. The villi were 0.5–0.7 mm. long and were branched. Mall now regards the ovum, probably correctly, as being pathological.

A very interesting ovum, similar, but probably in a slightly older stage of development, is described by Siegenbeek van Heukelom,[19] who unfortunately considers the embryonic structures only casually.

It was obtained from a woman who received some burns during an epileptic attack and died six hours later. An autopsy was performed fourteen hours after death. With the exception of the burns the body showed no noteworthy departures from the normal. The entire uterus was placed in 3 per cent. formalin for some days and was then washed and fixed in alcohol. Since the ovum was collapsed as the result of a slight tear, accurate measurements could not be made; but Van Heukelom estimates its meridian at about 16½ mm., which would give a diameter of 5.1 mm. The ovum was completely covered with villi; the insertion of thirty-one of these could be counted in a meridional section, fifteen occurring on the basal portion of the section (the portion nearest the uterine wall), twelve at the opposite pole, and two on each side at the equator. The villi of the embryonic pole were better developed than those of the opposite pole, and those at the equator were "especially heavy and thick." They varied greatly in length, some being small and short, the majority 0.75 mm. long and those at the equator as much as 1 mm. Some were little branched, others, especially the basal and equatorial ones, had many offsets, and some divided into numerous branches. The epithelial covering of the villi was composed of two layers; the outer showed no cell limits, so that we have to deal again with the Langhans layer and the syncytium, a cytotrophoblast and a spongiotrophoblast. All the large branches of the villi were connected peripherally by means of epithelial trabeculæ (ectoblast trabeculæ, cell columns) to form an epithelial shell (ectoblast or trophoblast shell) provided with large and small spaces. This shell was often very thin, consisting of only a single cell layer; at other times it was very thick and in its thicker parts there were peculiar blood lacunæ, resting directly upon the maternal compacta. The remaining conditions resembled in essence those of the Von Herff ovum of Spee. At the basal wall of the ovum was the embryonic papilla (the embryonic structures) united to the chorion at a very acute angle by a stalk. A distinct allantoic duct was present and the amniotic cavity was lower than in the Von Herff ovum described by Spee. Only one of the sections through the embryonic shield is figured, and this is reproduced here as Fig. 11. In it, in the region of the primitive streak, a mass of cells is seen projecting beyond the surface of the shield; Van Heukelom suggested that this might be Hensen's node, a suggestion which I, as well as the author, would mark with a large note of interrogation. Nothing is said of an amniotic duct.

Somewhat older again is the ovum that I[20] described in 1890; it contained an embryonic shield with a well-developed primitive streak and was the first of this stage to be described. The ovum was expelled in an abortion with the egg capsule, which was lenticular in shape and measured 12 × 9½ × 7 mm.; it had a scar measuring 2½ mm. Like all human ova of this period it was easily separated from the capsule, and measured 8½ × 7¾ × 6 mm. It had two areas free from villi: a larger one, measuring 6½ × 5¾ mm., at the pole opposite the embryonic anlage, that is, the pole toward the lumen of the uterus; and a smaller one at

---

[19] Siegenbeek van Heukelom: Ueber die menschliche Plazentation, Arch. f. Anat. u. Physiol., Anat. Abt., 1898.

[20] Franz Keibel: Ein sehr junges menschliches Ei, Arch. f. Anat. u. Physiol., Anat. Abt., 1890.

the embryonic pole, situated excentrically in front of the point of attachment of the belly stalk and measuring 2 mm. in diameter. The tissue of the Reichert scar showed neither glands nor blood-vessels, nor was it bounded by epithelium. The structure of the chorion and villi was the same as in the Spee ovum Von Herff, except that the syncytium was more strongly developed. The embryonic shield was about 1 mm. long and showed in the sections a well-developed primitive streak. The yolk sack had a diameter of 1 mm. and showed numerous blood and blood-vessel anlagen. The endothelial walls of the blood-vessels were already clearly distinguishable from the blood-corpuscles. There was an allantoic duct.

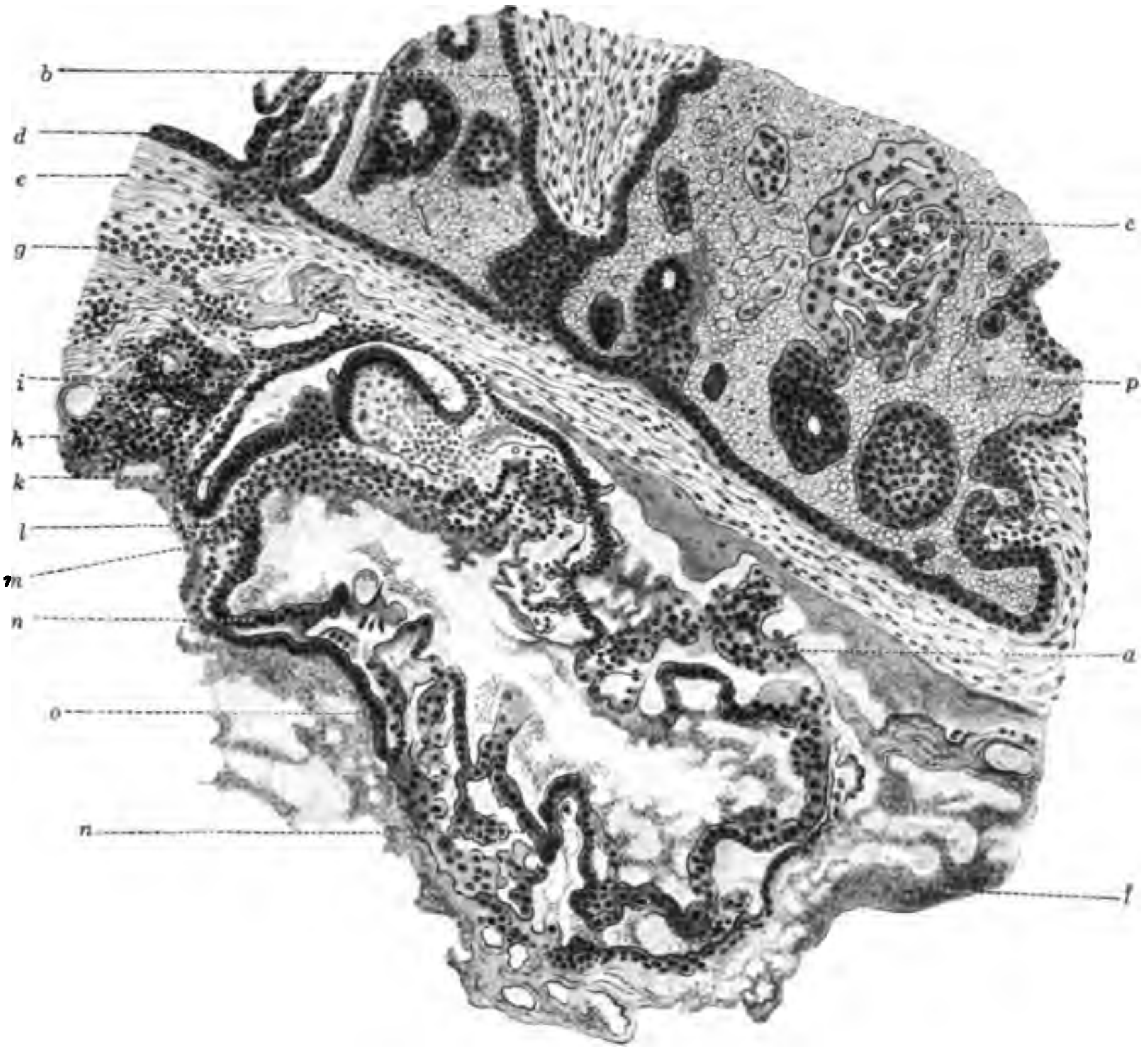

Fig. 11.—Section through the basal portion of the ovum described by Siegenbeek van Heukelom, with the embryonic structures (embryonic papilla). *a*, intervillous space; *b*, villus; *c*, ectoblast mass of a villus not included in this section; *d*, outer, epithelial layer of chorion; *e*, inner, mesoblastic layer of chorion (parietal mesoblast); *f*, clot and granular deposits; *g*, mesoblastic stalk; *h*, part of the stalk with many cells; *i*, amnion; *k*, embryonic shield in cross-section (ectoblast); *l*, mesoblast; *m*, hypoblast; *n*, hypoblast of the yolk sack; *o*, visceral layer of mesoblast; *p*, maternal blood. (After Siegenbeek van Heukelom: Arch. f. Anatomie u. Physiol., Anat. Abt., 1898.)

The ova described by Merttens,[21] by Leopold[22] in his Atlas, by Marchand and by Rossi need be mentioned here only in so far as they present especially striking peculiarities. Merttens had for study only four sections found accidentally in the investigation of a uterine curetting. Leopold in his ovum obtained by operation and estimated by him, "with doubtful accuracy," according to Spee, to be seven to eight days old—it was undoubtedly older—found no distinct embryonic

---

[21] J. Merttens: Beiträge zur normalen und patholog. Anat. der menschl. Placenta, Zeitschr. f. Geburtsh. u. Gynäkol., vol. xxx, 1894, and vol. xxxi, 1895.

[22] G. Leopold: Uterus und Kind, Leipzig, 1897.

papilla, either on account of unsatisfactory preservation, as Van Heukelom suggests, or, as Spee believes, because the ovum was abnormal. At all events the ovum, whose diameter was 4 × 3.7 mm., need not be further considered here. Concerning the ova described by Marchand (1898) I may remark briefly that that author describes (*Marburger Sb.*, 1898, pp. 150–153), in an imperfectly preserved ovum of the size of a pea, at that portion of the surface of the chorion where the remains of the embryonic anlage occurred, a funnel-like depression of the surface of the chorion which led into a canal filled with syncytium; this he interpreted as the remains of an amniotic duct.[23]

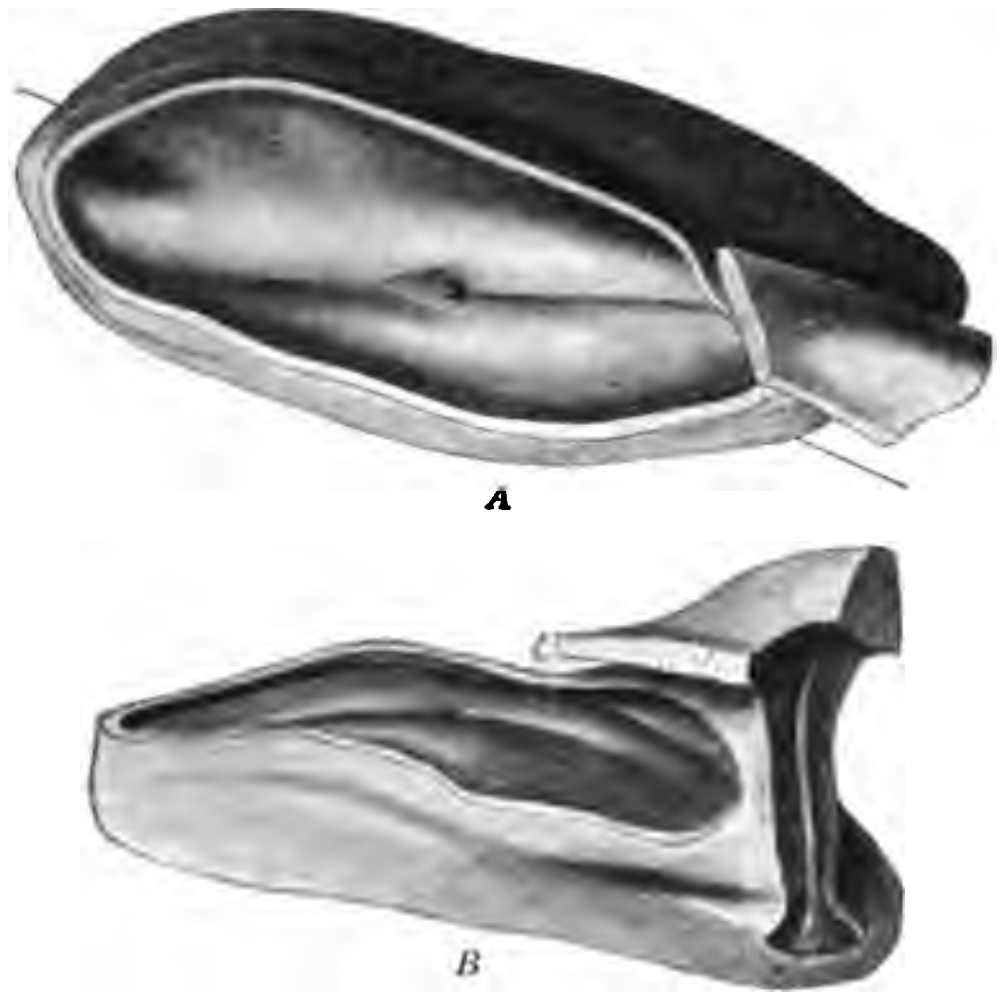

FIG. 12, *A* and *B*.—Figures of the embryonic shield of the Frassi ovum, from a model by Elze. The belly stalk, together with the portion of the chorion to which it is attached, is shown to the right; the yolk sack and amnion have been removed. In *A* one is looking down upon the shield; at about its middle is the dorsal opening of the canalis neurentericus, to the left of this is the shallow medullary groove flanked by elevations with indistinct boundaries, to the right are the primitive streak and primitive groove. The plane of the sections is shown by an arrow. *B* shows the shield from the left side. In the belly stalk the allantoic duct has been exposed so that its origin from the yolk sack can be seen. × 25. (Fig. 12, *B*, from Frassi: Arch. f. mikr. Anat., 1908, vol. lxxi, Fig. 9.)

From two later publications by Marchand ("Beobachtungen an jungen menschlichen Eiern," *Anat. Hefte,* No. 67, vol. xxi, 1902, pp. 217–278; and "Einige Beobachtungen an jungen menschlichen Eiern," *Verh. Anat. Ges.,* 1902) it may be noted that he found in one ovum[24] that the intervillous space was not filled with maternal blood, notwithstanding that the blood-vessels of the neighboring portions of the mucous membrane were excessively engorged. The intervillous space seemed to be separated from the cavity of the egg chamber peripherally by strong ectoblastic proliferations; blood-vessels opening into the cavity of the egg chamber could not be found. From this it would follow that the blood must normally enter the intervillous space only at a later period of development; a precocious entrance of the blood may, according to Marchand, lead to an abortion.

Also, according to Rossi Doria,[25] who described an ovum of less than 9 × 8 mm. contained in a completely closed egg capsule, an actual circulation of

---

[23] In a later publication (Anat. Hefte, 1903, p. 223) he says: "We have to do therefore with a narrow canal traversing the chorion, which from its opening at the surface is lined or, more properly, filled by a prolongation of the so-called surface epithelium, and ends blindly a short distance below the inner surface, just where the remains of the embryonic anlage occur." He ascribes the same significance to a depression on the surface of the chorion of an ovum of 14 × 3 mm. diameters, which was laterally compressed by a blood-clot.

[24] The ovum was obtained from the body of a woman who had died as the result of a gunshot wound. It was studied *in situ,* but the ovum and egg capsule were folded; the latter, according to Marchand, had a length of about 1.5 cm. and a breadth and depth of about 5–6 mm. The entire ovum was covered with branched villi. The embryo was completely disintegrated.

[25] Tullio Rossi Doria: Ueber die Einbettung des menschlichen Eies, studiert an einem kleinen Ei der zweiten Woche, Arch. f. Gynäkol., 1905, vol. lxxvi, pp. 433–505.

the blood does not take place at the beginning of the second week of development, because at that time the maternal blood has not yet gained access to the intervillous space; he regards the so-called prickle processes on the surface of the syncytium as a deposit formed from degenerated blood-corpuscles and the "scar" of the egg capsule as formed by regressive changes of the summit of the reflexa. Nothing is stated concerning the embryonic anlage, and the entire ovum was apparently little favorable for the settlement of important questions.

We may now consider an ovum obtained by operation and studied by Frassi[26] under my direction. The entire uterus, removed per vaginam, was at once placed in a warm 5 per cent. solution of formalin; it remained there forty-eight hours and was then washed for twelve hours and finally passed through alcohols of gradually increasing strength. Only then was it opened, cut into portions, and these imbedded in celloidin, in which condition it came into the hands of Frassi. The ovum, together with the portion of the uterus that contained it, was cut into serial sections. The ovum and embryonic structures were undoubtedly normal.

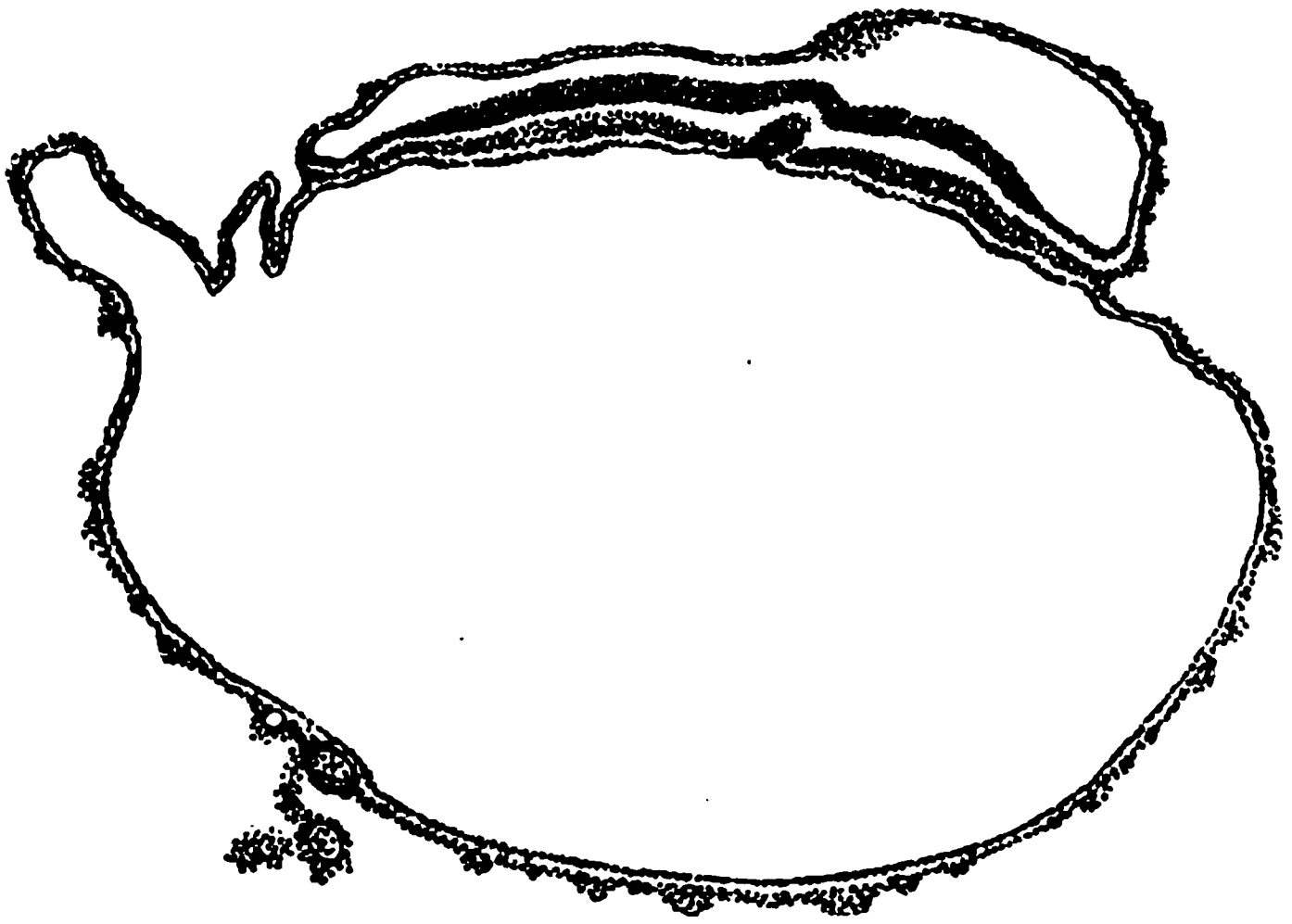

FIG. 13.—Section of the embryonic anlage of the Frassi ovum, taken 30 μ cranial to the dorsal opening of the neurenteric canal; the head process is cut obliquely and the ventral opening of the neurenteric canal practically tangentially. × 50. (From Frassi: Arch. f. mikr. Anat., vol. lxxi, 1908.)

The diameter of the egg capsule parallel to the surface of the uterine lumen, in the plane of the sections, was 13 mm., perpendicular to this surface it was 5 mm. at the middle of the ovum; the corresponding diameters of the cavity of the ovum were 9.4 and 3.2 mm. A scar could not be detected in the decidua capsularis. The ovum was completely covered with villi, which were especially developed in the equatorial zone; their length varied between 0.5 and 1.9 mm. Both blood-vessels and glands opened into the intervillous space, but with regard to the latter it could be perceived that they had been laterally eroded, so that their communication with the space was secondary. It is remarkable that practically no blood was contained in the intervillous space, notwithstanding that blood-vessels opened into it; it must be that the blood had completely escaped during the operation. The Langhans layer, syncytium, and cell columns were present; and of these the Langhans layer and the cell columns may be regarded as cyto-

---

[26] L. Frassi: Ueber ein junges menschliches Ei *in situ,* Arch. f. mikr. Anat., vol. lxx, 1907; and Weitere Ergebnisse des Studiums eines jungen menschlichen Eies *in situ,* ibid., vol. lxxi, 1908.

trophoblast and the syncytium as spongiotrophoblast. The embryonic shield was cut somewhat obliquely; it showed the anlage of a well-developed primitive streak, at the anterior end of which was a neurenteric canal and at the posterior end the cloacal membrane. The section shown in Fig. 14 passed directly through the neurenteric canal. In front of the primitive streak is a flat medullary groove, bounded by still indistinct medullary folds. Anlagen of blood and blood-vessels occurred on the yolk sack. Anlagen of blood-vessels could be seen with certainty in the mesoderm of the chorion only in the neighborhood of the insertion of the belly stalk; none could be detected in the mesodermal axes of the villi. Models were made of the embryonic structures as well as of the embryonic shield, but only those of the shield need be figured here, together with some of the sections.



Fig. 14.—Section of the embryonic anlage of the Frassi ovum through the dorsal opening of the neurenteric canal. At the opposite pole of the yolk sack are anlagen of blood and of blood-vessels, and in addition a small cyst lined with cœlomic epithelium; it is shown more highly enlarged in Fig. 14a. Over the amnion is a portion of the chorion (*Ch.*) with a cut origin of a villus. ×50. (From Frassi: Arch. f. mikr. Anat., vol. lxxi, 1908.)

The measurements, made on the model, were:

1. Length of the embryonic shield	1.17 mm.
2. Breadth of the embryonic shield	0.6 mm.
3. Length of the primitive streak	0.5 mm.
4. Diameter of the yolk sack,	
a. Greatest	1.9 mm.
b. Least	0.9 mm.

The embryonic structures were attached to the inner surface of the chorion by a typical belly stalk, in which vessels could be made out.

We come now to the ovum Gle (Glaevecke), the careful study of which by Graf Spee has done so much to advance our knowledge of human embryology. It was an aborted ovum that was expelled, together with the entire uterine mucous membrane, five weeks after the cessation of the menses. The diameter of the egg capsule parallel to the surface of the decidua was 10 × 11 mm., and perpendicular to this, the thickness of the decidua basalis being included, 7.2 mm. The ovum was everywhere, but not very thickly, covered with villi. It was somewhat oval,

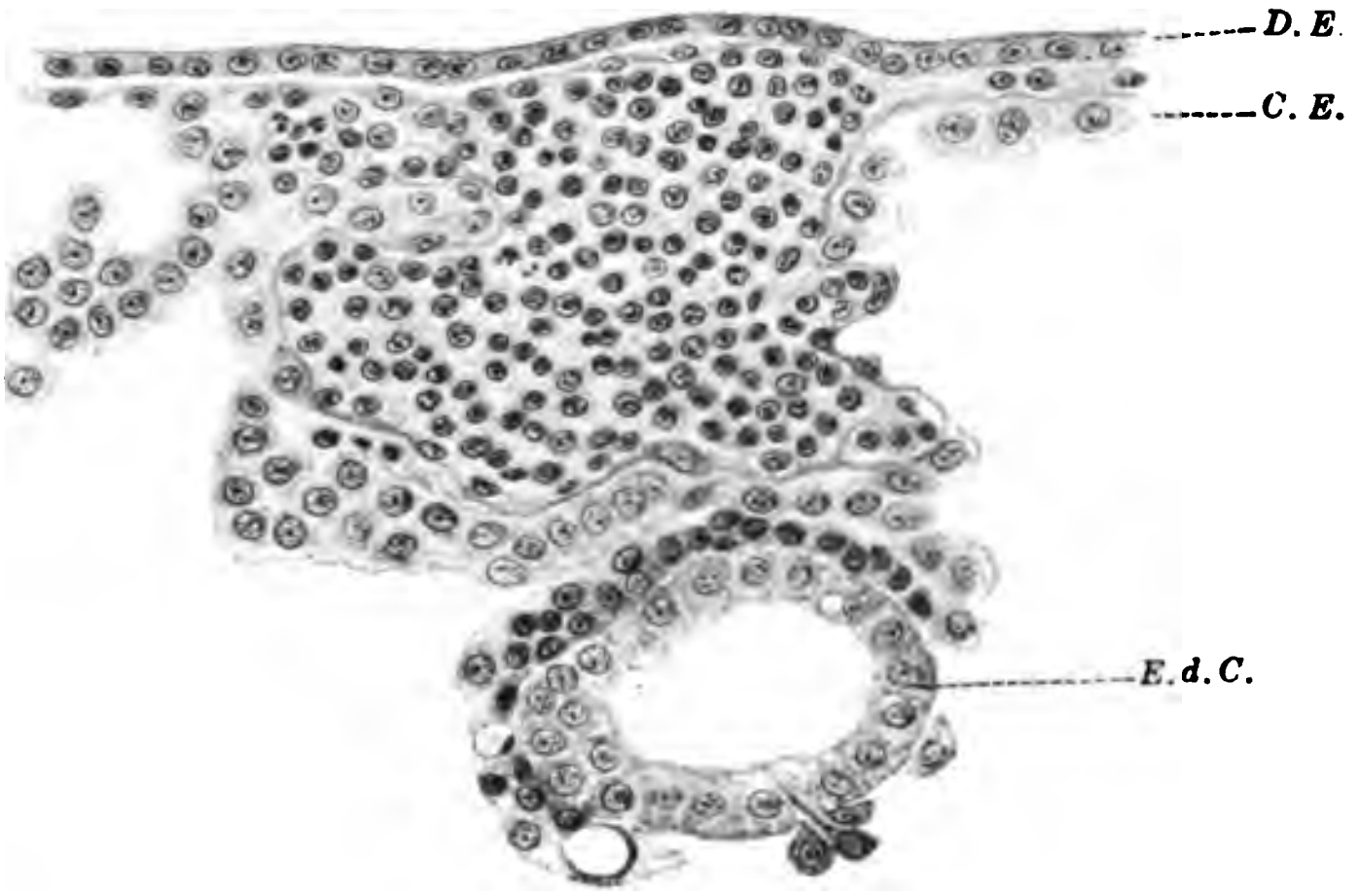

FIG. 14a.—The lower pole of the yolk sack of the section of the embryonic structures of the Frassi ovum reproduced in Fig. 14 with the anlage of a blood-vessel filled with blood and a small cyst. *D. E.*, epithelium of yolk sack; *C. E.*, cœlomic epithelium; *E. d. C.*, epithelium of the small cyst. × 300. (From Frassi: Arch. f. mikr. Anat., vol. lxxi, 1908.)

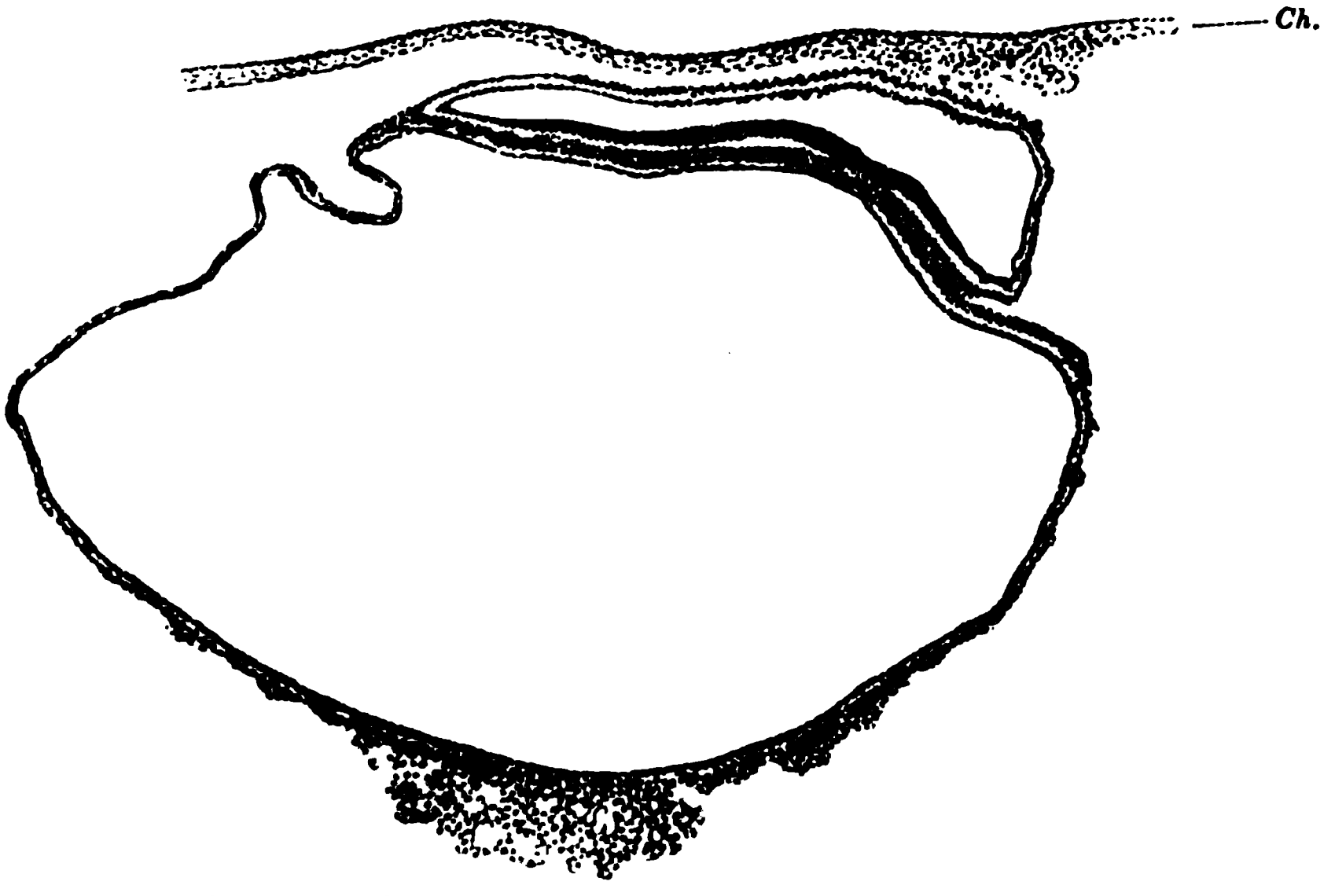

FIG. 15.—Section through the embryonic structures of the Frassi ovum. Typical primitive streak region. The amnion is closely apposed to the chorion (*Ch.*). × 50. (From Frassi: Arch. f. mikr. Anat., vol. lxxi, 1908.)

its diameters being 8.5 × 10 × 6.5 mm.; the last diameter is that perpendicular to the decidua basalis. The villi were covered by a Langhans layer (cytotrophoblast) and a syncytium layer (spongiotrophoblast), and the cavity of the ovum had a horizontal diameter of 7.5 × 8 mm.

Fig. 19 shows the embryonic structure after a model by Graf Spee (from Kollmann's "Atlas"), and Fig. 20 a median sagittal section of them. The amnion

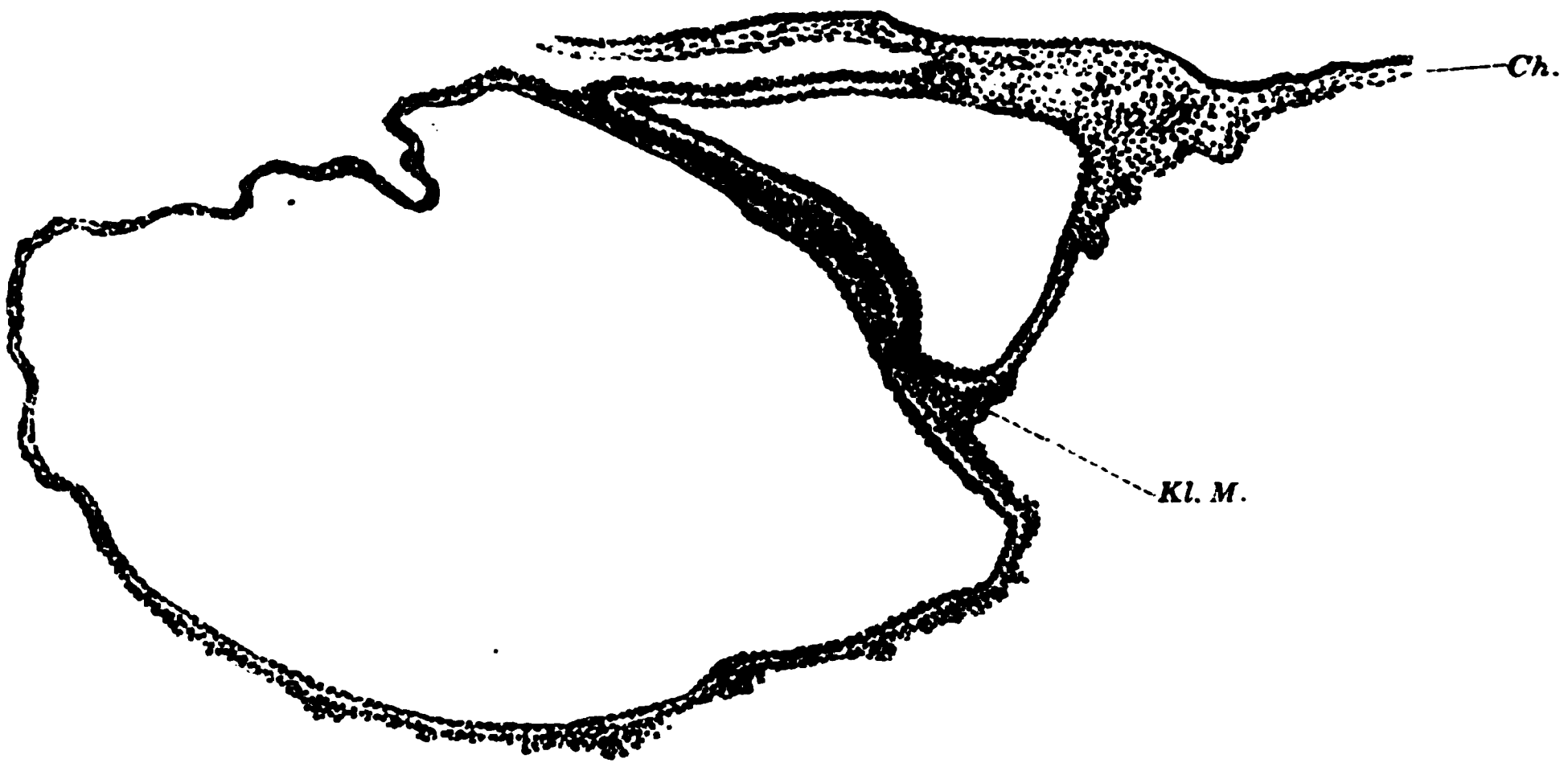

Fig. 16.—Section through the embryonic structures of the Frassi ovum passing through the cloacal membrane (*Kl. M.*); the amnion is united with the chorion. Anlagen of the blood-vessels occur in the mesenchymatous tissue which produces the union. ×50. (From Frassi: Arch. f. mikr. Anat., vol. lxxi, 1908.)

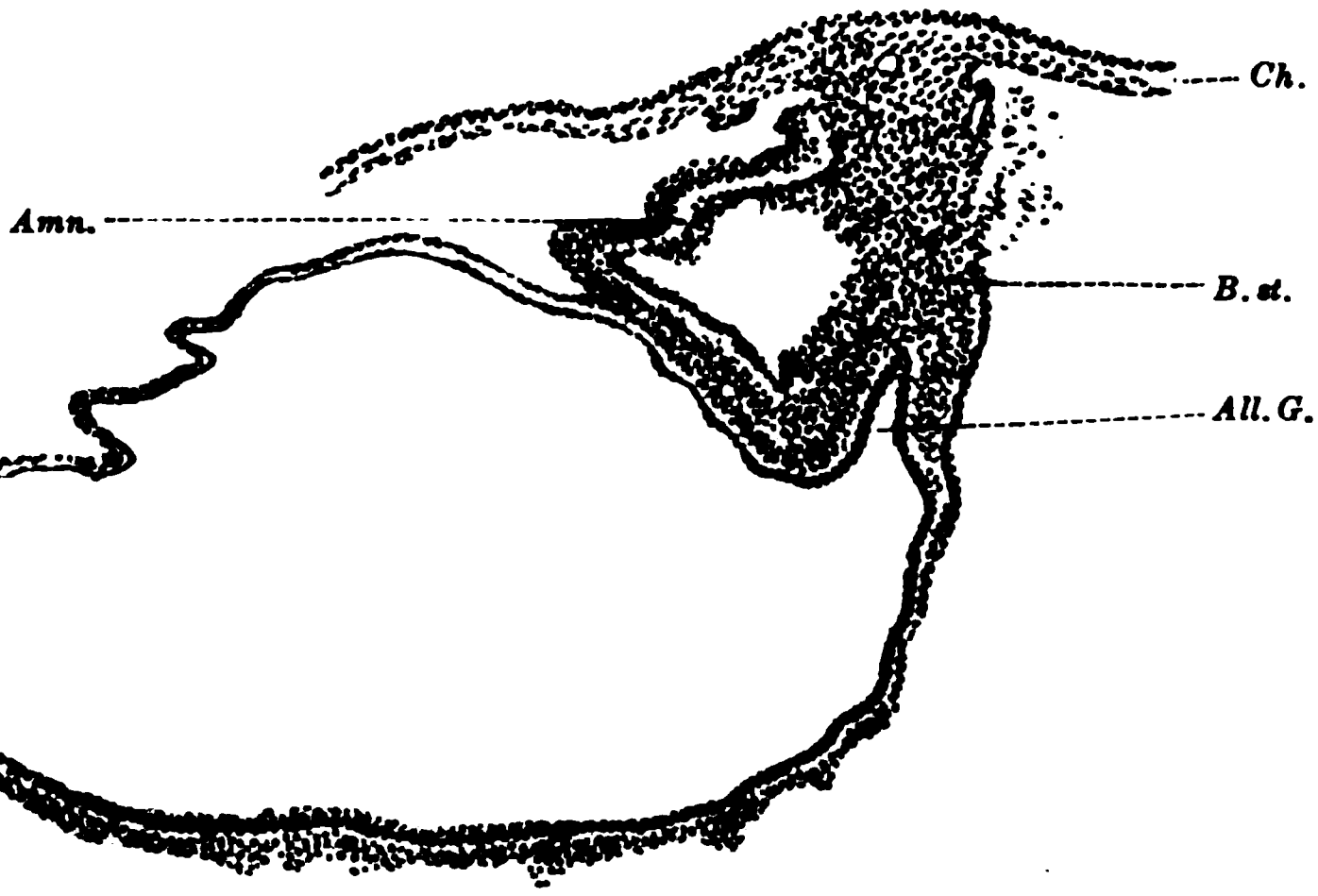

Fig. 17.—Section through the embryonic structures of the Frassi ovum passing behind the cloacal membrane. The origin of the allantoic duct (*All. G.*) from the yolk sack, the most caudal portion of the amniotic cavity, and the belly stalk (*B. st.*) with vascular anlagen are cut. *Amn.*, amnion. ×50. (From Frassi: Arch. f. mikr. Anat. vol. lxxi, 1908.)

Fig. 18.—Section through a portion of the wall of the yolk sack of the Frassi ovum. *D. E.*, epithelium of the yolk sack; *C. E.*, cœlomic epithelium. Between the cœlomic epithelium, which in the region shown is high and rich in tissue fluid, and the epithelium of the yolk sack are anlagen of blood-vessels and blood. The epithelium of the cœlom over the anlagen of the blood-vessels is exactly like that lining the small cyst at the lower pole of the yolk sack (Fig. 14a) and is distinctly different from that of the yolk sack. ×300. (From Frassi: Arch. f. mikr. Anat., vol. lxxi, 1908.)

is represented as opened in Fig. 19. The primitive streak, which occupied half of the germinal disk in the stage of development last described, is now limited to its posterior end, and this is bent strongly downward. At the anterior end of the streak was a well-developed canalis neurentericus, and in front of this the medullary groove bounded by well-formed medullary folds.

The greatest direct length of the embryonic structures, measured from the anterior curve of the amnion to the attachment to the chorion before the embryo had been placed in alcohol, was 2 mm., and that of the germinal disk from the anterior curve of the amnion to the hind end of the primitive streak was 1.54 mm. Throughout this length the disk rested like a lid upon the yolk sack. The average diameters of the germinal disk (*i.e.*, the distance in a direct line between the lines of reflection of the germinal layers into the amnion and yolk sack) were: anteriorly, 0.704–0.741 mm.; at the middle and posteriorly, 0.665 mm.; in the region of the canalis neurentericus and primitive streak, 0.589 mm.; and in the region of the belly stalk, about 0.4 mm. The medullary plate, disregarding its curvature, presented its greatest diameter of 0.517–0.57 mm. anteriorly; at its narrowest portion, about the middle of the germinal disk, it was 0.494 to 0.38 mm. in breadth. The height of the belly stalk together with the amnion was 0.722 mm., the width of the ectoblast plate exclusive of the amnion was 0.361 mm., and that of the subjacent mesoderm mass was 0.209 mm. The lumen of the neurenteric canal was 0.024 mm. in diameter and that of the circular swelling seen surrounding it on surface view was 0.13 mm.

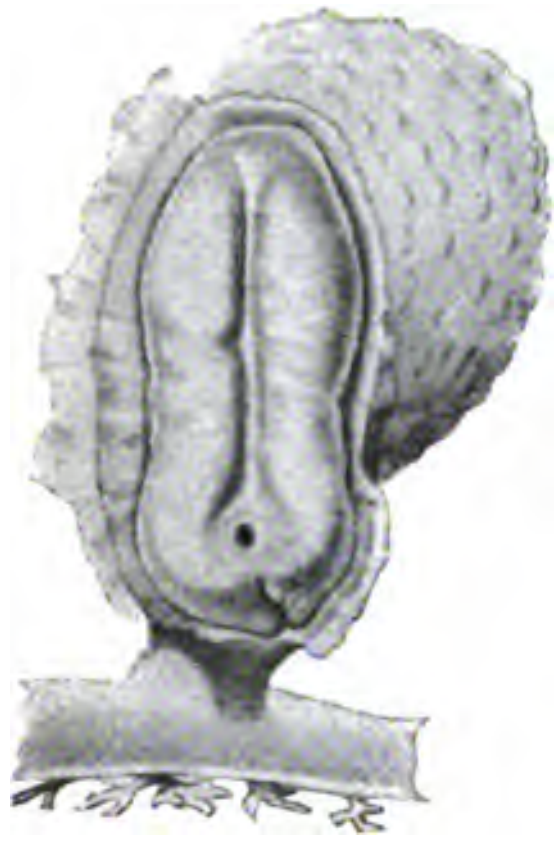

Fig. 19.—The Glaevecke embryo of Graf Spee seen from the dorsal surface. From a model. × 20. (Fig. II of the Normentafel of Keibel and Else, taken from Kollmann's Atlas.)

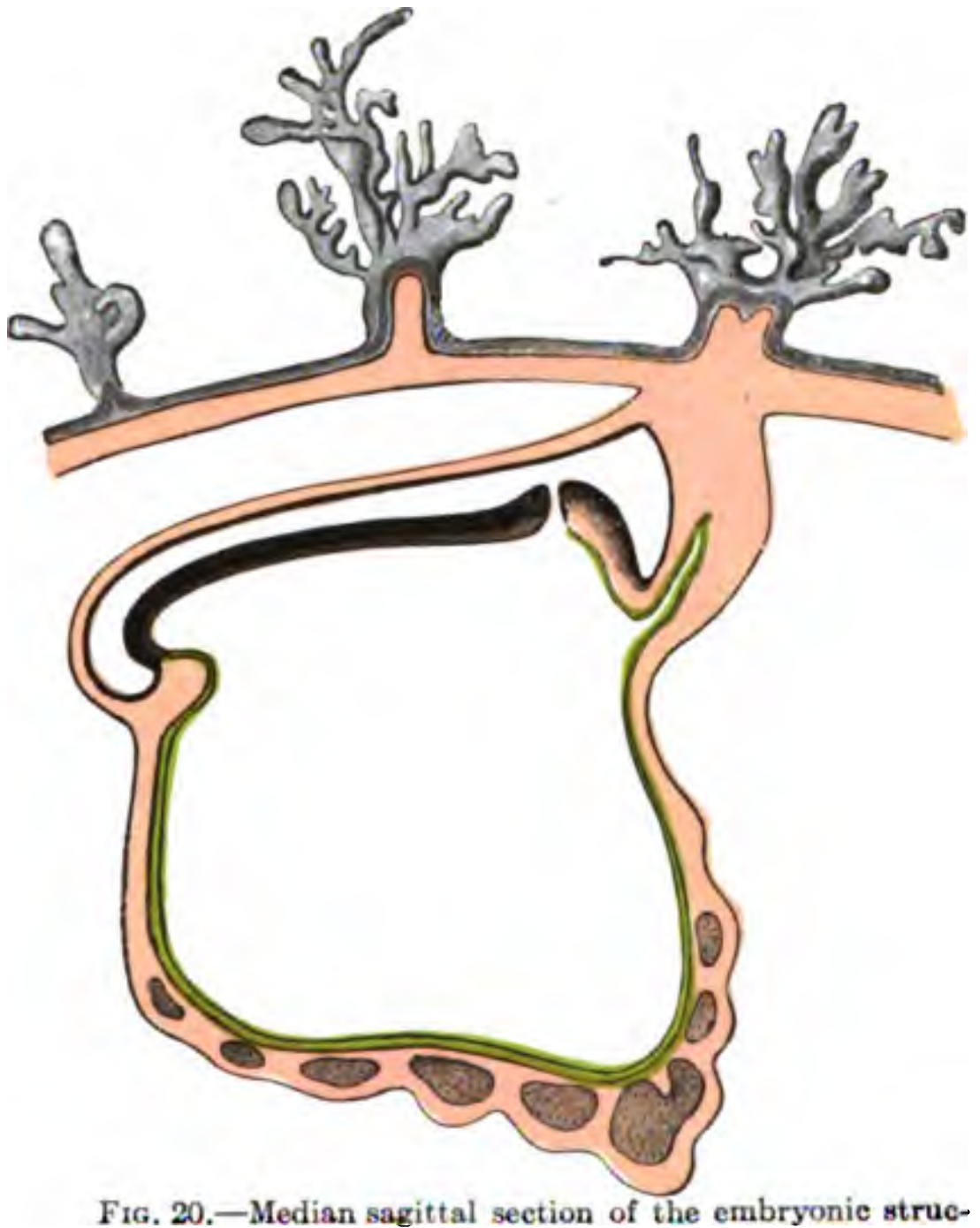

Fig. 20.—Median sagittal section of the embryonic structures of Spee's Glaevecke ovum. The head end is toward the left. Gray, trophoblast; black, ectoblast of the embryo and amnion; green, entoblast of the intestine and yolk sack. × 25. (Adapted from Fig. 68 of Kollmann's Atlas. From the Normentafel of Keibel and Else.)

Of this important embryo some figures are here reproduced, some of the yet intact embryo as published by Spee in his paper of 1889 and some of sections of it. Fig 21a shows the embryonic structure seen from the side as an opaque object: *K,* the embryonic shield (germinal disk); *D,* a constriction of the yolk sack; to the left one sees the caudal end of the embryonic shield bent down at right angles to the rest of the shield. Fig. 21b shows the dorsal surface of the embryo, and in Fig. 21c it is shown from the right and dorsally; both these drawings were made under direct illumination, the amnion being intact but cleared with turpentine, while the germinal disk still remained opaque. The reflection of the amnion into the embryonic shield is indicated by *g;* at the hinder end of the shield is the primitive streak (*Pst*) and in front of this is the opening of the neurenteric canal. In Fig. 21c the portion of the streak that is bent ventrally is also visible.

Figs. 22 and 22a represent a section passing through the neurenteric canal; the amnion, the yolk sack, and the relations of the germinal layers are shown. The distal portion of the yolk sack shows blood-vessels in course of development; the round spaces shown in that region represent vascular canals lined with endothelium and, for the most part, completely filled with young blood-corpuscles, not shown in the figure. The diameters of the vessels increase toward the distal surface of the yolk sack; on the right side the yolk sack was torn. Fig. 22a shows the middle portion of the section represented in Fig. 22 more strongly magnified.

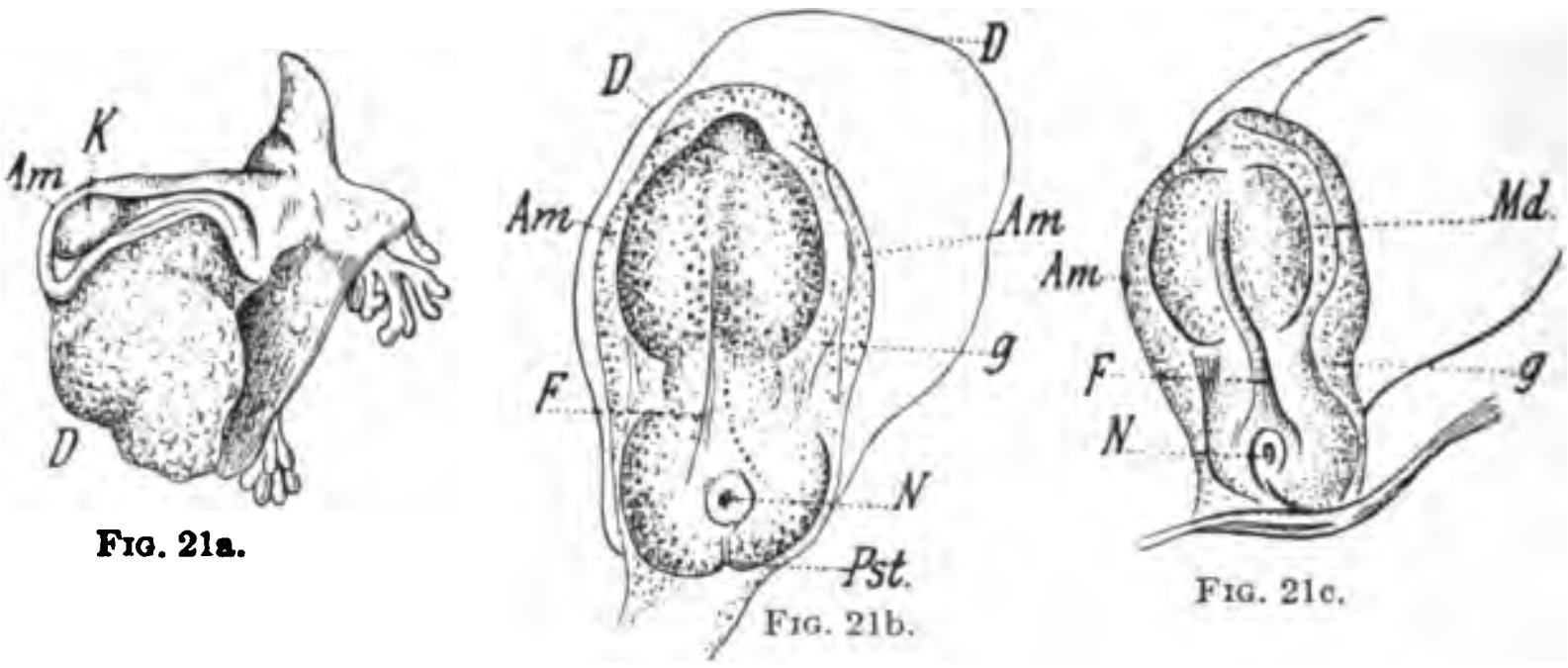

FIG. 21a.

FIG. 21b.

FIG. 21c.

FIGS. 21a–c.—Three views of the embryonic structures of Graf Spee's Glaevecke ovum. Fig. 21a. Lateral view: *K*, the embryonic shield; *D*, a constriction of the yolk sack; to the right is the caudal end of the embryonic shield which is bent downwards at right angles to the rest of the shield. Fig. 21b. Dorsal view. Fig. 21c. View taken dorsally and from the right. *Am*, amnion; *D*, yolk sack; *F*, medullary groove; *g*, line of reflection of the amnion; *Md*, medullary plate; *N*, canalis neurentericus; *Pst*, primitive streak. (From the Normentafel of Keibel and Elze.)

Fig. 23 is of a section through the region of the medullary groove. The chorda is included in the entoblast. The mesoblast shows to the left a small cavity (*h*) resembling the cavity of a primitive segment in process of formation, and to the right is a narrow cleft in communication with the extra-embryonic cœlom.

Fig. 24 shows a section through the broadest portion of the head plate; it shows already a tendency toward the closure of the intestine. The primitive streak and primitive groove are represented more highly enlarged in Fig. 25. At the primitive streak the ectoblast bends down to unite with the layer of mesoblast subjacent to it. The nuclei of the mesoblast are separated into two layers by a strip (*Z*) destitute of nuclei and also by a contour line that quickly disappears. The single layer that lies next to the entoblast cannot be distinguished from that layer in the middle of the section, and in this region the entoblast appears thickened. Fig. 26 shows the half of a section passing through the medullary groove, greatly enlarged; at *P* it shows the appearance of the pericardial cleft.

The embryo described by Êternod, a model of which has been reproduced by Friedr. Ziegler, is very similar to the Glaevecke embryo of Spee, but was not as well preserved. It was obtained from a woman who had cohabited only during the night of November 6–7. The menstruation expected on November 22 was omitted, the abortion occurred November 28.

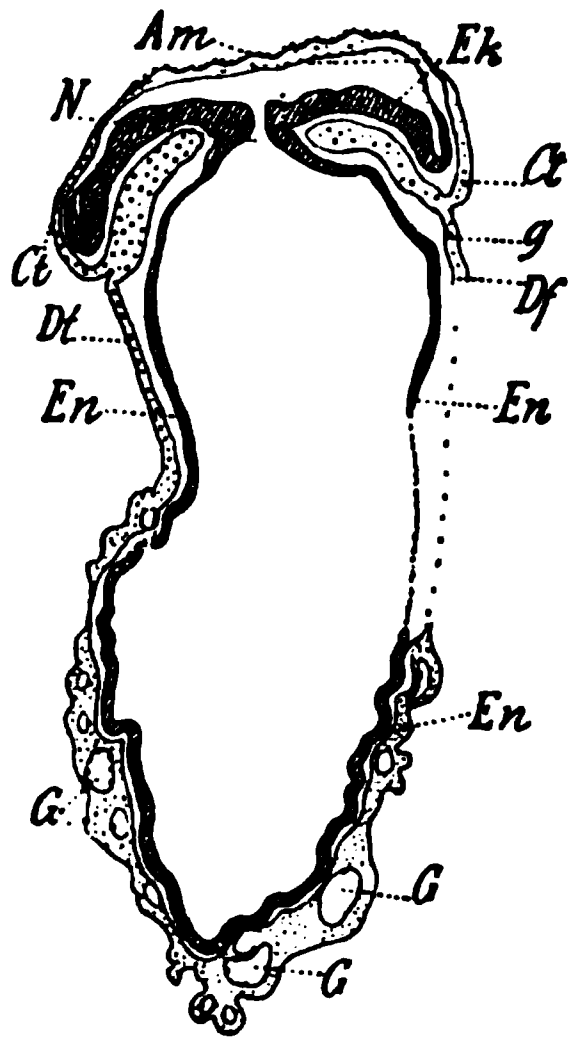

FIG. 22.

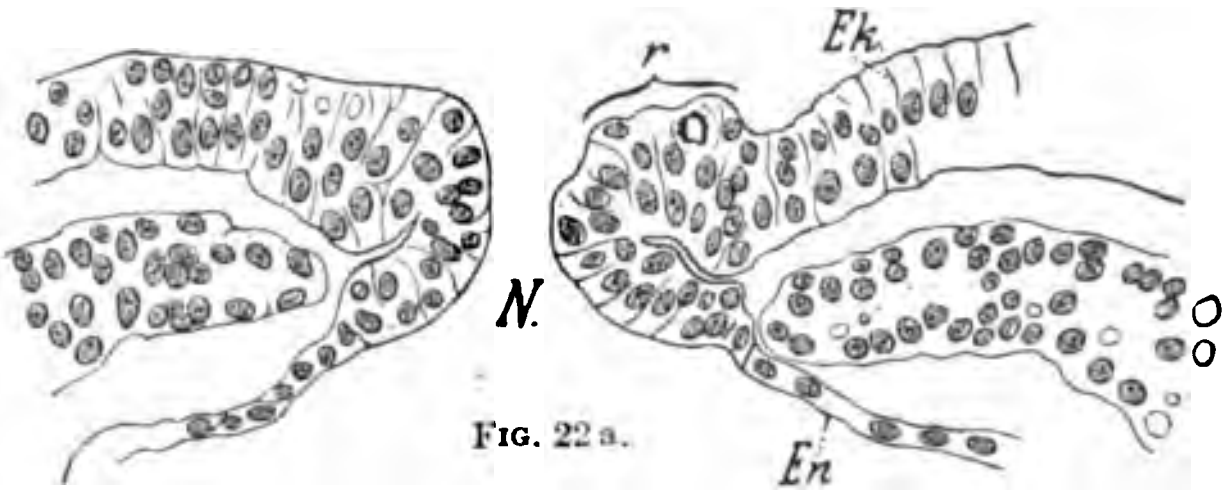

FIG. 22a.

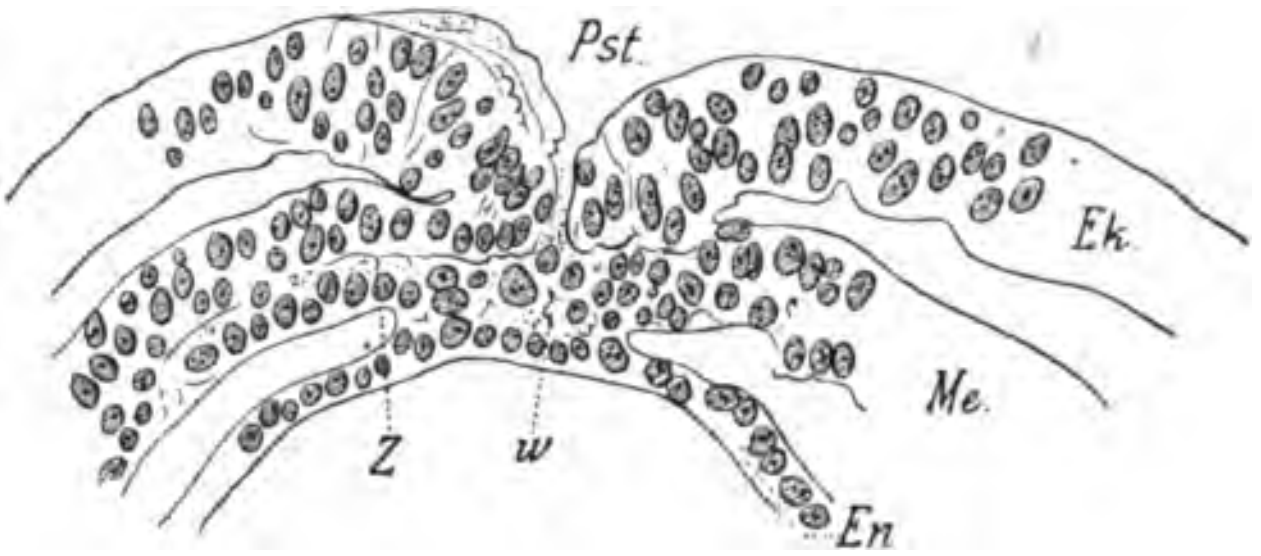

FIG. 25.

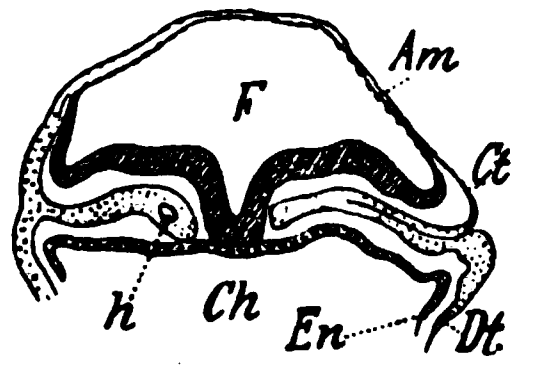

FIG. 23.

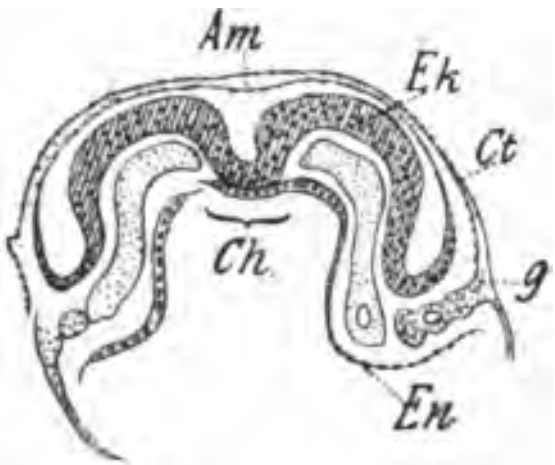

FIG. 24.

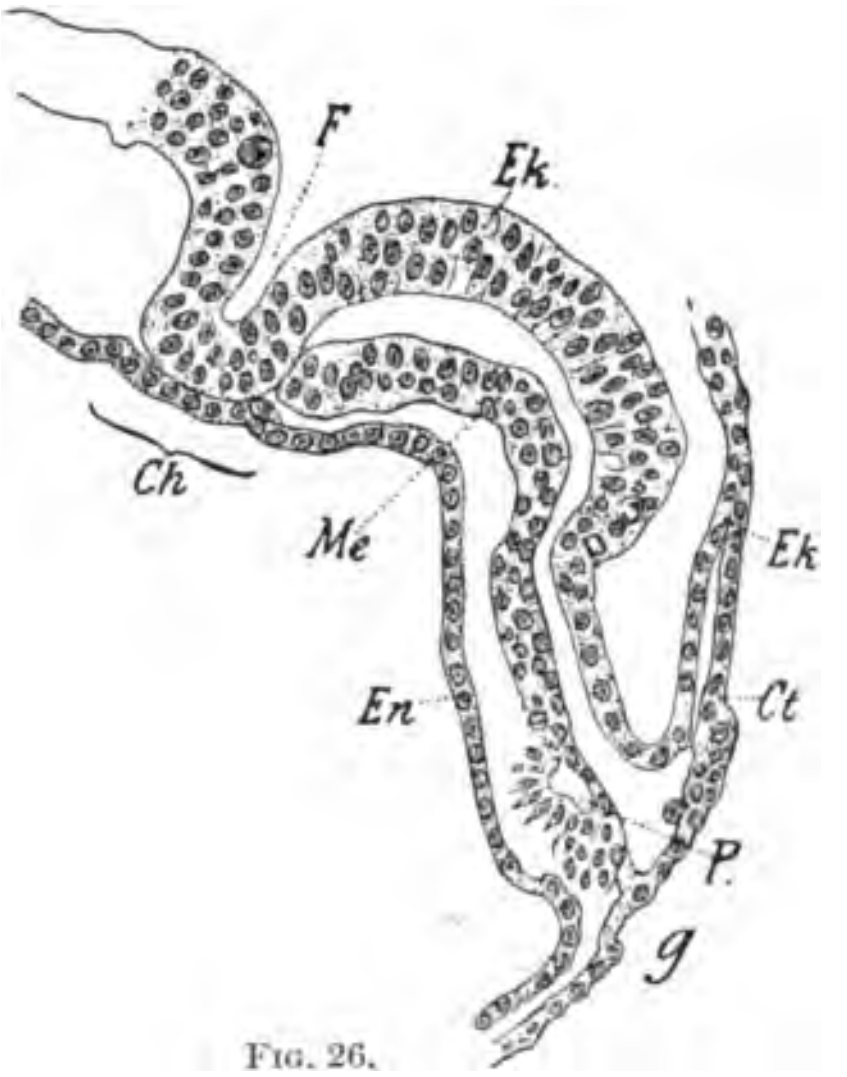

FIG. 26.

FIGS. 22–26.—Sections through the Glaevecke embryo after Graf Spee, from the Normentafel of Keibel and Elze. *Am*, amnion; *Ch*, chorda; *Ct*, parietal layer of the mesoblast; *D*, yolk sack; *Dt*, visceral layer of the mesoblast; *Ek*, ectoblast; *En*, entoblast; *F*, medullary groove; *g*, line of reflection of the amnion; *Md*, medullary plate; *Me*, mesoblast; *N*, canalis neurentericus; *Pst*, primitive streak.

FIG. 22.—Section cutting the neurenteric canal. The blood-vessels of the yolk sack, which are lined with endothelium and usually packed with blood-corpuscles, are represented as merely round spaces.

FIG. 22a.—The middle of the germinal disk of Fig. 22 more highly magnified.

FIG. 23.—Section through the region of the medullary groove. *h*, a small cavity resembling the beginning of a mesodermic cavity; to the right a small cleft apparently in communication with the extra-embryonic cœlom.

FIG. 24.—Section through the broadest portion of the head plate.

FIG. 25.—Section through the primitive streak, under stronger magnification. At the primitive streak the ectoblast bends down into the layer of the mesoblast (*Me*) lying subjacent to it. The nuclei of the mesoblast are separated into two layers by a strip (*Z*) destitute of nuclei and also by a contour line that quickly disappears. In this section the layer next the entoblast cannot be distinguished from that layer in the middle line and seems to be thickened in that region.

FIG. 26.—Section through the anterior region of the medullary groove, more enlarged. *P*, pericardial cleft.

In the fresh condition the entire ovum with its villi measured 10.0 × 8.2 × 6.0 mm. The villi had a length of 1.2–2.0 mm., their diameter being 0.3–0.8 mm. The embryonic shield was biscuit-shaped and measured in length from head cap of the amnion to the projecting caudal end 1.3 mm.; its breadth was 0.23 mm. in front and 0.18 mm. posteriorly. The closed amnion was continued into an amniotic duct. Further it may be remarked that Êternod describes the remains of a chorda canal in both the caudal and cranial ends of the chorda anlage, which is flattened and contained within the entoderm. Êternod's statements concerning the heart and the blood-vessels will be considered in the chapter dealing with those structures.

Since Spee's Glaevecke embryo showed indications of the commencing formation of the embryonic cœlom and the primitive segments, it represents the final stage of the period of development we are here considering.

V.

THE FORMATION OF THE GERM LAYERS AND THE GASTRULATION PROBLEM.

By FRANZ KEIBEL, Freiburg i. Br.

THE formation of the germ layers, like the processes of segmentation, has not yet been observed in the human species; in the youngest known human ova the germ layers are already present. The middle layer, it is true, is still in process of formation from the primitive streak in the younger ova; but it is a striking fact that in the very youngest ova, although a primitive streak cannot be recognized with certainty, nevertheless the middle germ layer is abundantly present. I have not employed the terms ectoderm, mesoderm, and entoderm—or ectoblast, mesoblast, and entoblast—because an accurate definition of them cannot be given so long as the middle layer is still in the process of formation; furthermore the nomenclature, influenced by theoretical considerations, is not altogether unambiguous and we must first understand its significance.

If we would understand the conditions in man, or even approach to an understanding of them, we must first briefly consider the corresponding conditions in other mammals, then those of other vertebrates, and, indeed, those of the invertebrates also. All the similarities that may be found in the processes back of the formation of the germ layers in the vertebrates and invertebrates we must regard as convergence phenomena, but with the formation of the layers we come so near to the common origin of the two groups that we may well look for something directly comparable. The formation of the germ layers is not yet entirely understood in mammals. Selenka[1] described an immigration gastrula in *Didelphys virginiana*, and Van Beneden came to the conclusion that in the mammals the material for the ectoblast and the entoblast or hypoblast was separated even at the first segmentation division. The descendants of the ectoblast cell grew around those of the hypoblast cell and so produced an epibolic gastrula, and the region where the epiblastic cells finally closed over the hypoblast was regarded as the blastopore; it was situated in the region at which the embryo later formed. Van Beneden has now given up this hypothesis for sufficient reasons, but it has been revived by Duval, who, however, places the closure of the gastrula at the anti-embryonic pole. I believe, with Van Beneden, whose conclusions rest on extensive observations, that Duval has been deceived by artefacts. Nor can I regard Selenka's observation as certain. The material was very scanty and its

---

[1] For the literature, other than that which is directly cited here, see Keibel: Die Gastrulation und die Keimblattbildung der Wirbeltiere Ergebnisse d. Anat. u. Entwicklungsgesch., vol. x (literature to 1900), 1901.

investigation does not seem to me to have been beyond criticism. If, for the present, we disregard theories, we can say that in mammals there is formed by segmentation a solid mass of cells, a morula, in which, in many cases, an outer layer can be distinguished at an early stage from an inner cell mass. If this outer layer is incomplete, the interruption occurs at the embryonic pole. At the opposite pole the outer layer separates itself from the inner cell mass. Van Beneden believes that this separation takes place by the vacuolation of the lower cells of the inner mass, but it may also be supposed to occur by a simple separation of the outer layer from the mass. There is thus formed, from a cell mass, a morula, a small vesicle, a blastula; to the embryonic pole of this blastula is attached a mass of cells, which, among other things, includes the actual embryonic anlage.

On the under surface of this mass of cells there arises, by a process which must be termed delamination, a layer of cells which will become the intestinal and yolk-sack epithelium, that is to say, the entoderm. It may be formed at a time when the cell mass still projects into the interior of the embryonic vesicle (as, for example, in the deer) or when it has spread out to form the embryonic shield (as in the dog), but these differences will be considered later. Here we must note that with the appearance of this cell layer, which grows around the inner wall of the embryonic vesicle and reaches the anti-embryonic pole sooner or later, except in some cases, the mammalian ovum has reached the gastrula stage; it consists of two layers or cell complexes, of which the inner one will become the intestinal and yolk-sack entoderm.

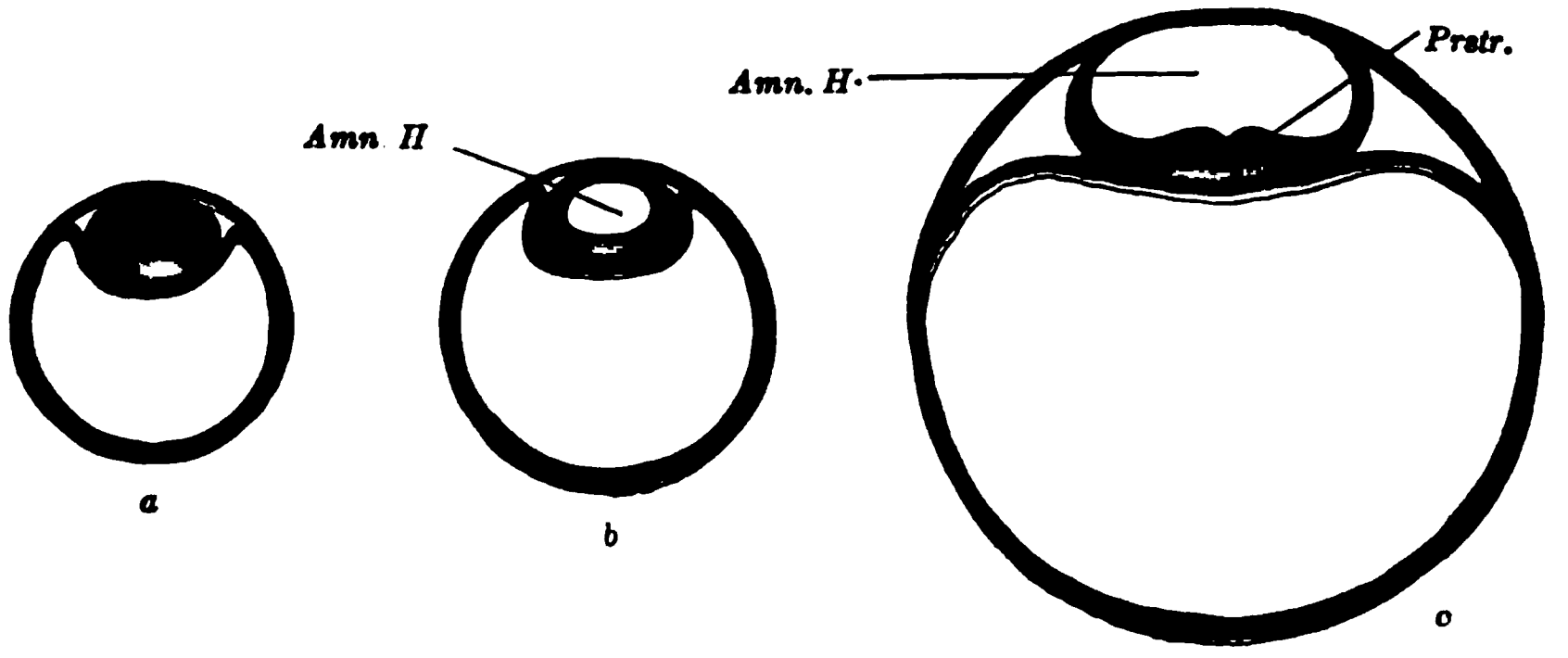

Fig. 27.—Diagrams of the formation of the amnion according to the hedgehog-bat type. *Amn. H.*, amniotic cavity; *Prstr.*, primitive streak. The prospective significance of the cells, even before the germ layers are delimited is represented in this and the following diagrams by colors. *Black* and *gray*, ectoblast (*black*, ectoblast of the embryo and of the amnion; *gray*, trophoblast); *green*, entoblast; *red*, mesoblast.

As has been already mentioned, the development may take place in different manners, even if those mammals which present a so-called inversion of the germ layers be disregarded. We will follow it through three different types.

In the hedgehog, according to Hubrecht, and similarly in the bat, according to Van Beneden, there is formed from the inner cell mass in addition to the entoblast mentioned above (Van Beneden's lecithophore, the yolk layer of other authors) an outer germinal layer, from which the ectoblast of the embryo and of the amnion and the mesoblast are formed. This occurs, as is shown in Fig. 27, *b*, by the appearance of a cavity in the round mass of cells shown in Fig. 27, *a*, which cavity is directly transformed into the amniotic cavity; in its floor the embryonic shield is formed, in the region of the embryonic shield the primitive streak appears, and from the primitive streak the middle germ layer or mesoblast arises. The development of the mesoblast and primitive streak in the different types will be discussed later and we may now consider the second type, shown by

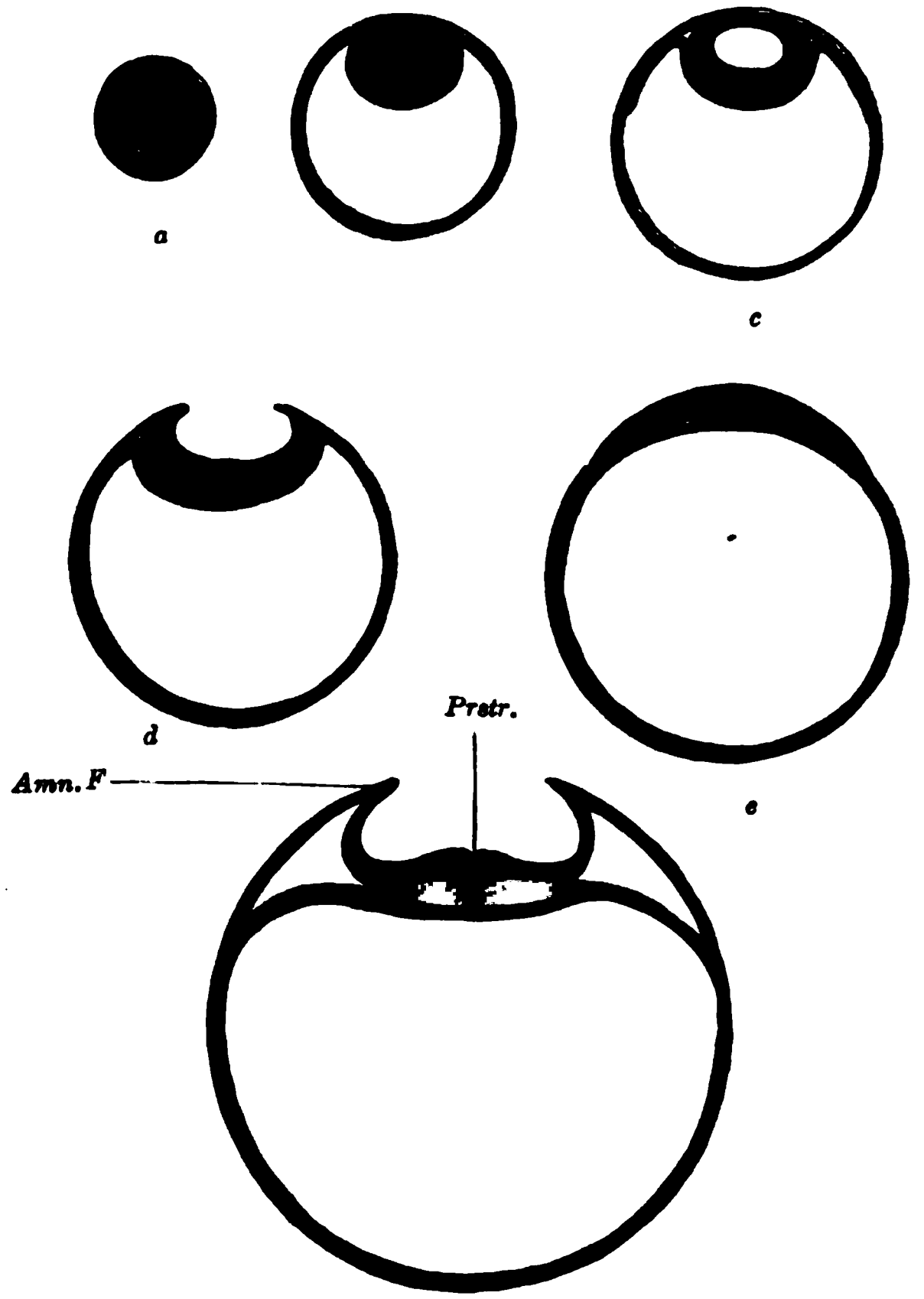

Fig. 28.—Diagrams of the formation of the germ layers and amnion in the deer (the ruminant and pig type; mammals with entypy of the germinal area). *Amn. F.*, amniotic folds: *Prstr.*, primitive streak.

Fig. 29.—Diagrams of the formation of the germ layers and amnion in carnivores. *Amn. F.*, amniotic fold; *Prstr.*, primitive streak.

the deer and also by the sheep and pig. In the deer, as in the hedgehog and bat, a cavity is formed in the inner cell mass (Fig. 28, *c*), but this cavity does not remain closed and is not directly transformed into the amniotic cavity; it opens to the exterior, the embryonic shield flattens out upon the surface of the ovum, and the amnion is formed from a fold that rises around the embryonic shield.

A third type (Fig. 29) is found, for example, in the dog and other mammals, and in it the inner cell mass flattens out to form the embryonic shield before the entoblast appears; from the beginning the embryonic shield is spread out upon the surface of the ovum, and in the rabbit it is at first covered by a thin layer of cells (Rauber's covering layer), which soon disappears. A fundamental difference between these three types does not exist, nor does it exist in the so-called inversion of the germ layers which may be observed in many rodents. The mode of development of mammals showing this inversion is readily intelligible if one takes as a starting point for it the first type of development described above (that of the hedgehog and bat, Fig. 27). In Fig. 30 are two diagrams which will make clear the so-called inversion. In Fig. 30, *a*, the two-layered ovum has become invaginated into itself and the invagination opening has become closed by a trophoblast growth. Fig. 30, *b*, shows the formation of the mesoblast and the amnion.

Opinions regarding the development of the mesoblast in mammals are still very divergent. Certain it is that the primitive streak is its principal seat of formation. It arises from the primitive node, a thickening of the upper germ layer, from which the mesoblast cells grow out between the upper and lower germ layers. But whether this primitive node appears within the limits of the embryonic shield and the primitive streak is formed by a growth from it directed caudally, or whether the primitive node appears at the caudal end of the embryonic shield and the primitive streak is formed by a forward growth from it—these are questions concerning whose answers there is still difference of opinion; this is true also as to the question whether the primitive streak is the only source of formation of the mesoblast. Bonnet, for example, recognizes two other sources. He believes that a mesoblast area surrounds the embryonic shield, the mesoblast in this area being formed from the inner germ layer. He described this area in the sheep, but could not find it in the dog; and it is certain that it does not occur in a number of other mammals. A second source of the mesoblast from entoblast Bonnet finds in the "completing plate" of the primitive gut cord. It lies in the anterior region of the head and from it, in addition to a premandibular rudiment of the gut, there arise the chorda and the mesoderm of the head region.[1]

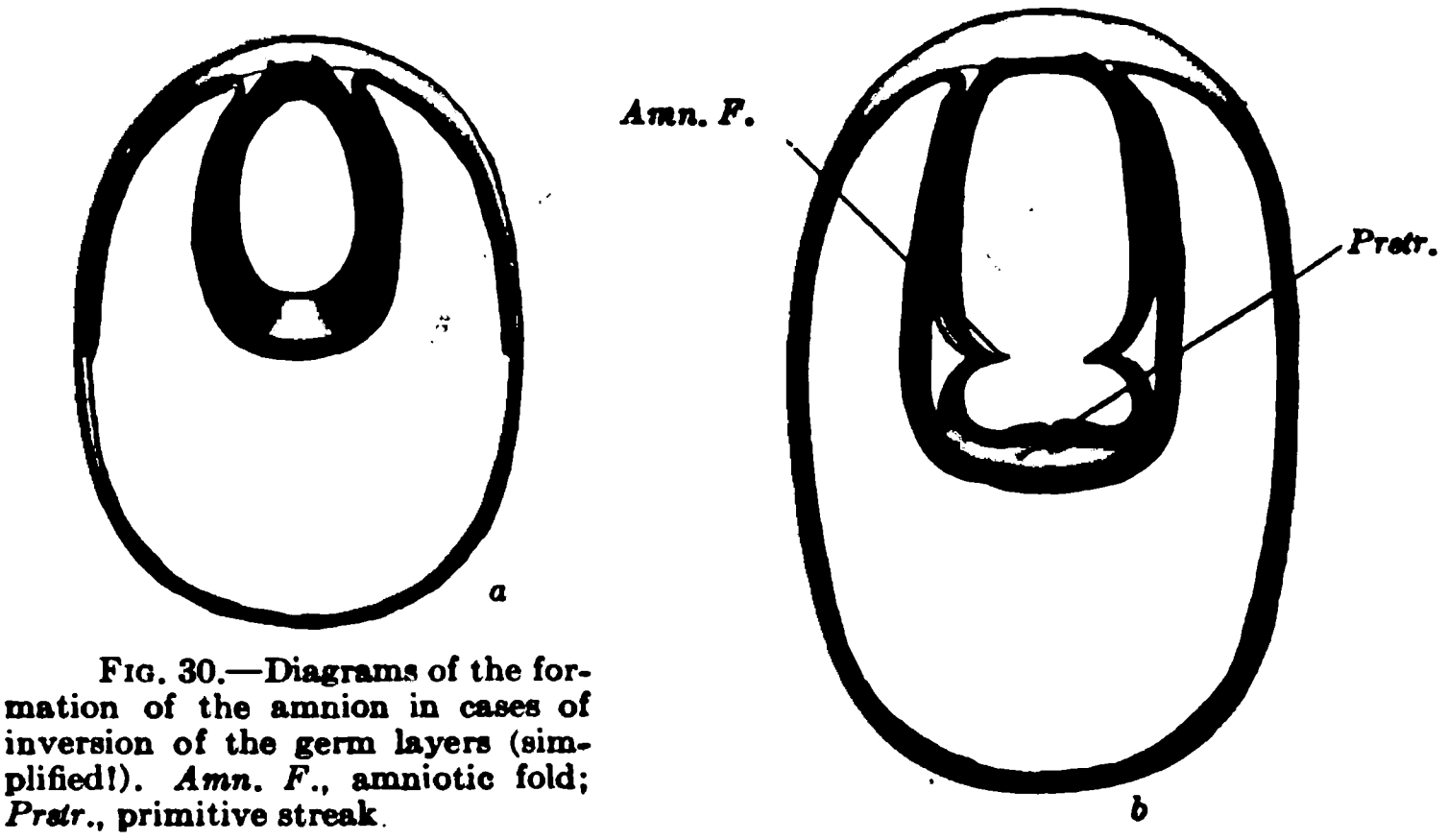

FIG. 30.—Diagrams of the formation of the amnion in cases of inversion of the germ layers (simplified!). *Amn. F.*, amniotic fold; *Prstr.*, primitive streak.

---

[1] Although it is impossible to consider here the various individual opinions regarding the formation of the mesoblast in mammals, nevertheless the observations of Wilson and Hill (J. T. Wilson and J. P. Hill: Observations on the Development of Ornithorhynchus, *Philosph. Transactions,* Ser. B. vol. cxcix, 1904) on Ornithorhynchus may be considered. In their opinion the primitive node, which

At the height of its development the mammalian primitive streak extends throughout almost the entire length of the embryonic shield, beginning a short distance behind its cranial end and extending to the caudal end; later it degenerates in a craniocaudal direction. At its cranial end a canal, the canalis neurentericus, which traverses the embryonic shield, may be formed; its caudal end gives rise to the cloacal membrane. From it there is formed a large portion of the body of the embryo, for, in my opinion, there can be no doubt but that it originally extends far into the head region; its anterior end and the neurenteric canal, when it is present, migrate, therefore, in a craniocaudal direction. From the axial mesoblast which is thus formed in front of the anterior end of the primitive streak the chorda arises, from the more lateral mesoblast the primitive somites and the mesoblast of the embryonic body situated still more peripherally.

The chorda anlage is transitorily enclosed within the entoderm, but later it again separates from it. For a time the growth of the primitive streak keeps pace with the amount of material separated off from it; but later the streak becomes gradually smaller, giving off more material than is replaced by growth, and, finally, it becomes transformed into a region of proliferation which is usually termed the tail bud, but which also gives rise to a portion of the body. This region of proliferation consists of an indifferent cell material into which the medullary tube, the chorda, intestine, and mesoderm pass and from which the caudal portions of these structures are differentiated.

A sharp distinction cannot be drawn between the primitive streak and the tail bud; but, since the tail bud is distinct as such even in mammalian embryos with less than twenty primitive somites and the degeneration of the primitive streak is in full swing in still younger embryos, it would perhaps be better to speak of a trunk bud than of a tail bud.

Having thus learned how the germ layers are formed in the mammals we may now inquire how their formation compares with what occurs in other animals; in other words, we now come to a consideration of the theories generally known as the gastrulation and the cœlom theories. And here we must first agree upon the definition which is to be applied to the process of gastrulation. The inconsistent and frequently actually contradictory definitions that have been given of gastrulation have so obscured what is in itself a difficult question, that it is not easy to give an account of it. The anatomists and purely vertebrate zoölogists are to blame for some of the difficulty, in that they have not perceived that the process of gastrulation is not something confined to the vertebrates, but, as the fundamental works of Ray Lankester and Haeckel have shown, is a process which occurs in the majority of metazoa. Hubrecht has rendered good service by energetically pointing out that it is not permissible to define gastrulation differently in the vertebrates and in the other metazoa; and I am thoroughly in agreement with him in this, even although I considered the question for many years entirely from the standpoint of a vertebrate zoölogist. Accordingly, I define *gastrulation as the process by which the cells of the metazoan ovum are separated into an upper and a lower layer*, into ectoblast (ectoderm) and entoblast (hypoblast, entoderm), and by entoblast I mean only the cells forming the intestinal epithelium.[8] That we must regard the final result as the most important thing in the idea of gastrulation and

---

marks the position of the blastopore, comes into relation with the primitive streak only secondarily; originally it lies outside the embryonic shield. Yet it seems to me questionable if the structure which the authors regard as the primitive node in early stages is the same structure which they so designate in later stages; I have wondered whether the primitive node of younger stages may not be the yolk navel.

[8] The intestine here includes its appendages, the yolk sack and the intestinal glands.

must disregard the manner in which this is brought about (delamination, immigration, invagination, epibole) I had already pointed out before Hubrecht, and had shown that the processes that had usually been designated as gastrulation in the vertebrates could not be directly compared with the gastrulation processes of the invertebrates. I must, therefore, consider the question here so far as is necessary for the understanding of the nomenclature and the older literature, and for further details would refer to my paper of 1901 already cited and to the explanations by Hubrecht,[4] myself,[5] and Brachet.[6]

The entire theory of the formation of the germ layers and gastrulation in the vertebrates is based upon the development of *Amphioxus.* In this form the material for the formation of the intestinal entoderm, the mesoderm, and the chorda is laid down in the interior by a single process, and for a long time all investigators have incorrectly designated this entire process as gastrulation and have started their consideration of gastrulation in the vertebrates from it. In the same way in 1901 I defined gastrulation, pointing out, it is true, that the definition could only apply to vertebrates, as the process by which the cell complexes for the intestinal entoderm (*i.e.,* intestinal and yolk-sack entoderm), the mesoderm, and the chorda were brought into the interior of the ovum. I stated, further, that this definition could be extended to all vertebrates if two phases were recognized in it: a first phase in which the intestinal entoderm, and a second, in which the mesoderm and the chorda were formed. If one assumed that alterations in the true relations of these two phases occurred, all variations could be explained and the common basis for both processes could be recognized.

I had come to this conclusion in 1889[7] as the result of studies in the development of mammalia, and at about the same time Hubrecht[8] also reached it independently. I have since carried the idea further and will here refer to some of the points which I brought together in my observations and conclusions in 1893.[9] I said then:

"In the mammals gastrulation takes place in two phases. In the first phase the lower germ layer, the entoderm of authors, is formed; in the second phase the chorda and mesoderm. From the so-called entoderm of the mammals there is formed essentially only the intestinal epithelium and that of the yolk sack. That additions are made to the intestinal epithelium from the cell mass which is formed in the interior of the ovum during the second phase of gastrulation cannot be absolutely denied; but in any event these additions, 'if they actually occur,' are insignificant and are limited to a small region of the intestine. In the other amniotes gastrulation also occurs in two phases, yet the cell complexes formed in the interior of the ovum by the two gastrulation phases do not exactly correspond either qualitatively or quantitatively in different forms: thus in the Reptilia, and especially in the Chelonia, the second phase of gastrulation carries into the interior of the ovum the whole, or at least a considerable portion, of the intestinal epithelium; while in the mammals the intestinal epithelium, together with that

---

[4] A. A. W. Hubrecht: Die Gastrulation der Wirbeltiere, Anat. Anz., vol. xxvi, 1905.

[5] F. Keibel: Zur Gastrulationsfrage, *ibid.*

[6] A. Brachet: Gastrulation et formation de l'embryon chez les chordés, *ibid.,* vol. xxvii, 1905.

[7] F. Keibel: Zur Entwicklungsgeschichte der Chorda, Arch. f. Anat. u. Physiol., Anat. Abt., 1889.

[8] A. A. W. Hubrecht: Die erste Anlage des Hypoblast bei den Säugetieren, Anat. Anz., 1888, vol. iii, pp. 906–912; and The Development of the Germinal Layers in *Sorex vulgaris,* Quart. Journ. Micr. Sci., vol. xxxi, 1890.

[9] F. Keibel: Studien zur Entwicklungsgeschichte des Schweines, Schwalbe's Morphol. Arb., vol. iii, 1893.

of the yolk sack, gains its definitive position during the first phase." Later observations, however, show that reptiles more closely approximate the mammals in this respect, and it is becoming more probable that in the Reptilia also the lower layer, usually termed the paraderm, yolk layer, or secondary entoderm, gives origin to the intestinal epithelium.[10]

Concerning the gastrula cavity I said:

"The gastrulation cavity of the first phase of gastrulation, if it is formed at all, fuses very early, or immediately, with the segmentation cavity in mammals; but probably it does not occur at all.

"The cavity of the mammalian ovum in the two-layered stage is, consequently, to be regarded as the sum of a portion of the gastrula cavity and a portion of the segmentation cavity. Another portion of it is to be found in the cleft between the two primary germ layers. Corresponding conditions, which I shall for the present regard as merely analogies, occur in the Amphibia. In birds and reptiles the germ, or subgerminal, cavity is also to be considered a portion of the gastrula cavity, and a portion of the segmentation cavity. A second portion of this latter cavity in the Sauropsida is also the cleft between the upper and lower layers of the two-layered germ.

"The chorda cavity of mammals is to be regarded as a part of the gastrula cavity and belongs to the second phase of gastrulation. Only exceptionally are cavities found in the second phase which can be considered as remains of the cœlomic diverticula of the archenteric cavity.

"In the mammals the primitive streak is to be regarded as equivalent to the blastopore. In the germinal ring of the germinal disk of the birds and reptiles I also see a homologue (morphologically equivalent part) of a portion of the blastopore; it has, of course, been extremely modified."

These views have, it is true, not been unopposed, but since they have been reproduced in O. Hertwig's "Handbuch" and in his "Lehrbuch" and his "Elements," they may be regarded as the prevailing ones. How they must be modified if we are to make use of the definition given above, which applies to all metazoa that have an intestine, must now be considered. In the first place, it may be said that the separation of the gastrulation process into two phases has not been without results. What I have hitherto termed the first phase of gastrulation in the vertebrates, and especially in the mammals, must now alone be regarded as gastrulation, and the process which I formerly termed the second phase of gastrulation, that is to say, the formation of the mesoderm and chorda, since there is nothing directly comparable to it in the invertebrates, or, at all events, nothing comparable that can be regarded as belonging to gastrulation, must be separated from that process and regarded as a process by itself, even although it has become intimately associated with or even, so to speak, included in gastrulation as the result of a shifting in the time relations. But with this formal separation of the two processes and the simple modification of the nomenclature we have not yet reached perfect clearness, difficulties still remaining as to the homologue of the blastopore. In my earlier definition I compared directly the primitive streak of the amniotes with the blastopore; but this will not now hold, since the characteristic of the invertebrate blastopore, the direct transition from ectoblast to entoblast, no longer obtains in the amniotes. Between the ectoblast and entoblast there is interposed in the primitive streak the mesoblast, derived

---

[10] Greil (Ueber die erste Anlage der Gefässe und des Blutes bei Holo- und Meroblastiern [speziell bei *Ceratodus forsteri*], Verh. Anat. Ges., 1908) states (p. 58) that it "must be recognized that in the first phase of Hertwig and other authors there is formed not the entoderm of the entire embryonic anlage but only the abortive entoderm of the yolk sack." This is certainly incorrect for mammals and birds, and probably for the reptiles also.

from the upper germ layer, and the streak also gives rise to the chorda; indeed, we may say that for a time, in early stages, the chorda arises directly from the upper layer. We can compare with the blastopore only the line of junction of the entoderm with the mesoblast and chorda, where such a line exists; and if we are to make comparisons with the invertebrates we must regard the mesoderm and chorda as products of the upper germ layer, the ectoblast.[11]

What has hitherto been designated as the blastopore in the vertebrates, *Amphioxus* included, lies in the territory of the ectoblast and its derivatives and not at the boundary between ectoblast and entoblast; this structure, which undoubtedly resembles the blastopore most closely, but can only be compared with it at its first formation, is comparable to the primitive streak. Furthermore, the vertebrate body is formed not by the simple conversion of the gastrula into it, but a budding zone is formed in the region of the blastopore from which the segments of the vertebrate body are budded off. At this stage a comparison with the *Trochophora* (Fig. 31), a widely distributed larva among the annelids and molluscs, is quite possible, as Kopsch[12] and J. Jablonowski[13] have shown. Just as we can distinguish in the body of the larva an anterior unsegmented portion

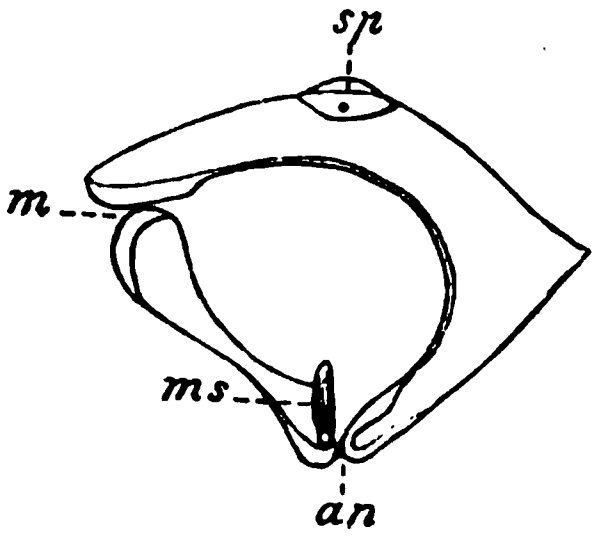

FIG. 31.—Young *Trochophora* of Polygordius in which the body is beginning to grow out. *an*, anus; *m*, mouth; *ms*, mesoderm; *sp*, apical plate. (Simplified from Hatschek, from Jablonowski: Anat. Anz., vol. xiv, 1898.)

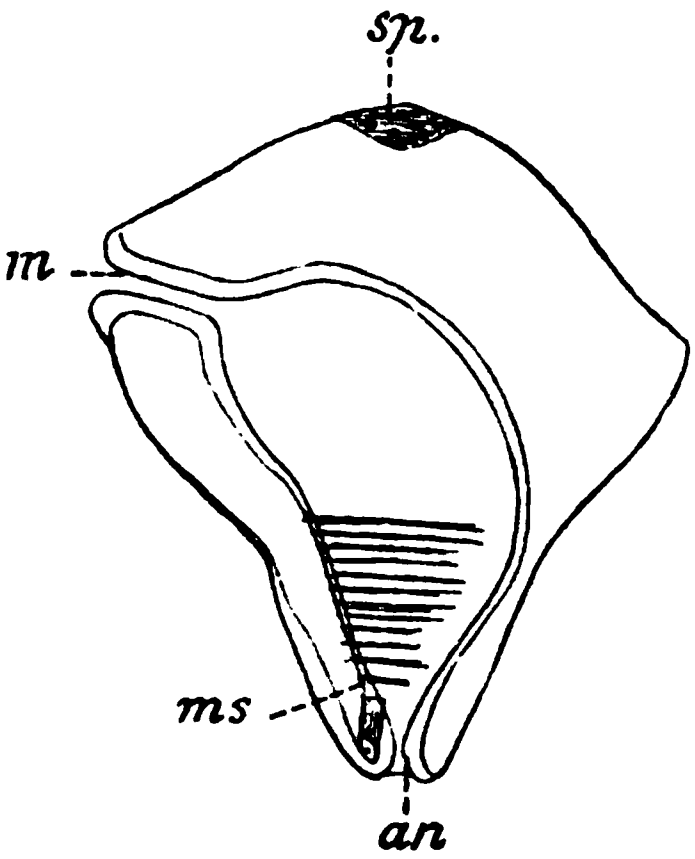

FIG. 31a.—Older *Trochophora* of Polygordius. The body region has grown larger and a number of segments have formed in the mesoderm. *an*, anus; *m*, mouth; *ms*, mesoderm; *sp*, apical plate. (From Jablonowski: Anat. Anz., vol. xiv, 1898.)

---

[11] This has already been done quite logically by Lwoff (B. Lwoff: Ueber einige wichtige Punkte in der Entwicklung des *Amphioxus,* Biol. Zentralbl. vol. xii, 1892; and Die Bildung der primären Keimblätter und die Entstehung der Chorda und des Mesoderm bei den Wirbeltieren, Bull. Soc. Impér. des Natural. de Moscou, 1894) in the case of *Amphioxus.* He regards as the principal result of his investigations the conclusion that "in *Amphioxus* the invagination is in no wise to be regarded as a simple gastrulation, as has hitherto been done. There are, rather two different phases to be distinguished in it: in the first place, the invagination of the entoderm cells, from which the intestine is formed; and, in the second place, the invagination of ectoderm cells from the dorsal transition border, which form the ectoblastogenic anlage of the chorda and mesoderm."

[12] Kopsch: Gemeinsame Entwicklungsformen bei Wirbeltieren und Wirbellosen, Verh. Anat. Ges., 1898.

[13] J. Jablonowski: Ueber einige Vorgänge in der Entwicklung des Salmonidenembryos und ihre Bedeutung für die Beurteilung der Bildung des Wirbeltierkörpers, Anat. Anz., vol. xiv, 1898.

which has been formed by the gastrulation process, and a posterior segmented portion which owes its existence to a budding process that succeeds gastrulation, so too is it possible in the vertebrate embryo. Hubrecht consequently distinguishes between cephalogenesis and notogenesis in the development of vertebrates. By cephalogenesis the anterior unsegmented portion of the vertebrate body is formed as a result of gastrulation; by notogenesis, a process of budding, the succeeding portion is formed. One must not, however, misunderstand these expressions. The limits of the two portions of the body must not be sought where the head now joins the trunk; trunk segments in unknown number have been taken up into the head and " the question concerns, on the one hand, only the most anterior region of the head, to which the olfactorius and opticus belong; and, on the other hand, the remaining portion of the brain, together with the base of the skull with the remains of the chorda and the visceral arches, and the entire trunk."

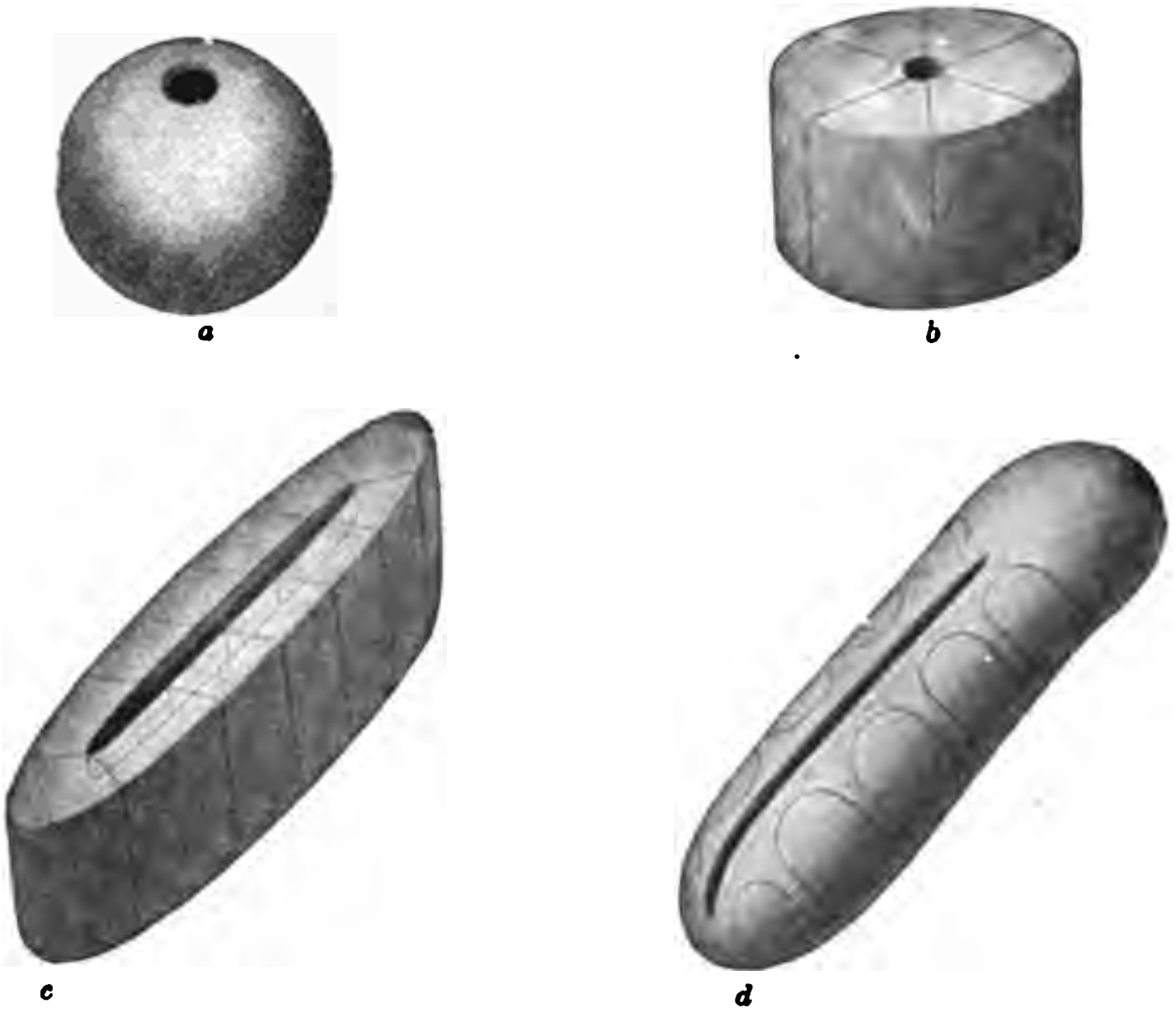

FIG. 32.—*a*, gastrula with open blastopore; *b*, a radially symmetrical actinian-like cœlenterate diagram; *c*, a bilaterally symmetrical, elongate, worm-like, and actinian-like animal with stomodæum and gut pouches; *d*, a worm-like protochordate with differentiation of a head, trunk, and chorda, and with a beginning metamerism. (From Hubrecht: Anat. Ans., vol. xxvi, 1905, Figs 3–6.)

While it is far from my intention to attempt a derivation of the vertebrates from the actiniæ at all directly, yet it may be well to consider the possibility of derivation from such simple forms. With this object I give here Hubrecht's speculations (Quart. Journ. Micr. Sci., vol. xlix, p. 410) (Fig. 32): " Once the didermic gastrula-stage reached, a second phase of ontogenetic development is inaugurated which is also of high phylogenetic importance. In this phase the bilaterally symmetric metameric animal gradually appears which we have to compare with possible phylogenetic transition forms that have connected the Vertebrates with radially symmetrical ancestors. This attempt at a plausible and rational reconstruction of the Vertebrate ancestry is, of course, hampered by the circumstance that no trace of those forms is any longer in existence. Still, an actinia-like, vermiform being, elongated in the direction of the mouth slit, imposes itself upon our imagination, such as has served for the theoretical speculations of Sedgwick on this same subject, and has once been accepted by van Beneden for the precursors of the Chordata." Hubrecht has pointed out that "the processes of growth by which a Cœlenterate gastrula becomes fixed and gradually changes into a sessile Actinian can hardly be looked upon as protracted phases of gastrulation. This will be more difficult yet when the animal has already acquired a higher degree of complication than that of the Cœlenterates, and swims about in the shape of a worm-like, lower chordate animal. We know of Polygordius and of other primitive worm types that to the radial, didermic larval stage—the Trochophora—another developmental phase succeeds, during which we observe proliferation in the anal region, leading to an increase in the distance between the anus and the apex of the metamerical worm, the latter budding off, so to say, from the radial trochophora.

"We find similar processes in the Vertebrates, but without a free trochophora larva, and to this latter radial and didermic primitive stage corresponds in the Craniata the rapidly passing earliest phase in which delamination calls forth two germinal layers. Both in Elasmobranchs and in mammals we notice that the cellular material which is present in those very earliest stages contributes especially—as it does in the trochophora—towards the formation of the anterior part, the head, and that, following upon this, a proliferation-process is inaugurated (comparable to the origin of the metamerical worm out of the trochophora larva) by which the notochord and the somites, *i.e.*, the bilaterally symmetrical metameric animal, are called into existence."

Hubrecht, going far back in the phylogeny, compares this proliferation with the growth of an elongated actinian. He imagines the cœlom pouches of the actinian, still in communication with the intestine, to represent the somites; the nerve ring on the oral disk would represent the spinal cord; the stomodæum, the chorda; and the actinian mouth, which is not to be regarded as its primitive mouth or blastopore, but is a secondary formation, represents the primitive streak, that stands in such intimate relation to the chorda (that is, to the actinian stomodæum).

The ingerent opening of the actinian gastrula elongates to form the actinian mouth that leads into the stomodæum; the blastopore of the mammalian gastrula, which never opens, elongates posteriorly to form the primitive groove, whose floor, the primitive streak, furnishes the material for the chorda.

"There is, then, during ontogeny an unbroken continuity between the blastopore of the Actinian and its oral slit, between the blastopore of the Vertebrate (often only potential in mammals and not identical with the opening that is called by that name in Sauropsids) and its primitive groove. A phylogenetic continuity has to be statuated between this oral slit of the Actinia and the peculiar spot (behind the so-called anterior lip of the blastopore) which on the Vertebrate embryonic shield gradually moves backwards and establishes in many cases an open communication between a portion of the Vertebrate intestine and the exterior. The primitive streak, however, the solid material that proliferates downwards from the ectoderm, coalesces with the entoderm, and brings forth the notochord from its median (though really paired) portion and the somites from its lateral wings—this primitive streak can never be identified with a blastopore. For we have above attempted to demonstrate that in this primitive streak we encounter the material which, also in the Actinia, (1) proliferates downwards from the ectoderm and produces the stomodæum, (2) coalesces with the entoderm, (3) is in direct continuity with those parts which are preparing to give rise to cœlomic pouches but are yet continuous with the primitive enteron." Hubrecht proposes a modification of the nomenclature in that for that portion of the vertebrate embryonic disk which he has compared with the actinian mouth and stomodæum he suggests the use of the name "dorsal mouth" instead of primitive mouth, gastrula mouth, or blastopore. In this manner the contrast with the phyla of the annelids and molluscs will be more plainly brought out.

If now we summarize what has been stated above and apply it to the formation of the germ layers in the mammals, we must say:

1. In the mammals the entoderm (yolk and intestinal entoderm) is formed by delamination; and it is only this delamination process that one can term gastrulation. The two cell-complexes which are formed as the result of gastrulation are to be termed ectoblast (ectoderm) and entoblast (hypoblast, entoderm). That the superficial layer of the wall of the embryonic vesicle, for a time the only layer that is present, must also be regarded as a portion of the ectoblast seems self-evident; the so-called covering layer belongs to it also. In so far as it is concerned in the nourishment of the ovum it may be termed, following Hubrecht, the trophoblast. As trophoderm—in the sense in which that word is used by Minot—a portion of the trophoblast is again to be distinguished, which in certain cases produces the penetration of the ovum into the wall of the uterus. Morphologically the trophoblast may be divided into the cytotrophoblast, from which the Langhans layer of cells is formed in the human ovum, and the spongiotrophoblast (plasmoditrophoblast), which gives rise to the syncytium.

2. A typical blastopore has not yet been certainly observed in the mammals. An invagination blastopore need not be expected to occur; some observations by which a connection of the ectoderm and entoderm was shown in early stages, before the formation of the mesoblast, have suggested the occurrence of a rudimentary blastopore. The primitive node and primitive streak—whether or not a primitive groove forms in the primitive streak is a matter of subordinate importance—are certainly associated with the blastopore, but cannot be directly homologized with it.

3. The anterior end of the primitive streak, at the time when the streak is at its greatest extension anteriorly, but not always its most anterior part, must be regarded as indicating the position of the blastopore.

4. The invagination processes by which in the mammals the formation of the chorda and mesoblast is initiated, are comparable to the corresponding processes in *Amphioxus,* but can be regarded as the gastrulation process neither in *Amphioxus* nor the vertebrates. We must accordingly say that the chorda and mesoblast arise from the ectoblast, the chorda partly directly and partly after it has belonged to the mesoblast for some time. The enclosure of the chorda in the entoblast is an entirely secondary phenomenon.

5. Even although the region of the primitive streak, with or without a primitive groove, cannot be compared directly with the fused lips of the blastopore of a gastrula, nevertheless they must be regarded as modified structures that have arisen in association with a typical blastopore and must be compared with what it has been the custom to call the lips of the blastopore in the vertebrates, from *Amphioxus* upwards. The processes which are here concerned are comparable to the budding processes which in the *Trochophora* larva succeed the gastrulation processes. This becomes especially clear when one considers the later transformation that the primitive streak undergoes and by which it becomes converted into the so-called "tail bud," a structure from which (as has already been pointed out) not only the tail arises, since the line between the tail and the trunk is merely conventional. The principal limit that concerns us here lies far forward in the head region, between those portions of the body which are formed by the gastrulation process and those that owe their existence to the succeeding proliferation process. The anterior end of the primitive streak, at the time of its greatest anterior extension, marks this limit.

There result from these theoretical considerations certain conclusions that are of interest from the more practical side. A longitudinal splitting of the embryo, which may extend into the head region, may, under some circumstances, be regarded as produced by inhibition of growth, which can be referred to the primitive streak and the processes which take place in it.

Roux's hemitheria anteriora such as the calf studied by Roux's pupil Eckhardt,[14] which Roux regarded as due to the early degeneration of the two segmentation cells which contained the anlagen of the caudal half of the body, are much more probably due to disturbances in the territory of the primitive streak. According as these occur early or late, a greater or smaller portion of the posterior extremity of the body will be wanting. Bob-tailed cats and dogs also belong to this class of developmental inhibitions; in these the inhibition first occurred after a portion of the tail had developed from the tail bud.

Embryology throws light upon the occurrence of coccygeal tumors and their varied structure by the fact that in the "tail bud" an indifferent cell material is present from which all the germ layers may be produced.

In conclusion, we may now return to man and endeavor, from what we at present know concerning his development and that of animals, to form a picture of the formation of his germ layers. We must assume that the human ovum, similarly to that of the guinea-pig, burrows into the mucous membrane of the uterus, destroys the maternal tissues, and so makes a cavity for itself. At the time of the penetration into the mucous membrane the diameter of the ovum can scarcely amount to 0.5 mm. Very early, but probably only after the ovum has burrowed into the mucous membrane, the formation of the cœlom and of the germ layers begins. I assume that this formation can begin only at that time because the burrowing process would otherwise encounter difficulties from the enlargement of the ovum made necessary by the formation of the cœlom and mesoblast; and it may also be supposed that those cells would first be formed which are intended for the destruction and absorption of the maternal tissue, the trophoblast cells, which belong to the later ectoblast complex. At all events, one must assume, as Spee pointed out as long ago as 1896, and as is now rendered almost certain by the Peters ovum, that at the time of the first formation of the mesoblast the diameter of the ovum does not exceed 0.5 mm.

The formation of the mesoblast follows immediately upon that of the amniotic (medullo-amniotic) cavity and that of the cavity of the yolk sack and intestine. That the cœlom in the human ovum is formed by a splitting process is indicated by the scattered mesoblastic strands which stretch between the yolk sack and the chorionic mesoblast, as well as by observations in many other mammals.[15]

The human ovum is, consequently, to be assigned to the category of schizocœl ova. It is, however, not yet quite clear how the cavity traversed by scattered strands of mesoblast and lying between the yolk sack and the chorion in the Peters ovum is

---

[14] Eckhardt: Ueber Hemitheria anteriora (Roux), Dissert., Breslau, 1889.

[15] This process may now be regarded as certain as a result of the observations of Bryce and Teacher (*l. c.*), which were published only after the first chapters of this "Handbook" had already been written and which must be noticed subsequently.

to be interpreted. It may be supposed to represent the extra-embryonic cœlom; but it may also be imagined that it has arisen from an extensive loosening up of the tissue and not by a splitting of the mesoderm, and that the triangular space beside the caudal extremity of the embryo (see Fig. 96, p. 108, in the chapter on the development of the egg membranes and the placentation), which is lined with flat cells having an epithelial arrangement, is the first anlage of the cœlom.

As to the amniotic (medullo-amniotic) cavity, it may be said with a probability bordering upon certainty that it arises by a splitting of a solid cell mass; consequently, amniotic folds never occur in man. The amniotic duct or cord—a connection between the epithelium of the amniotic cavity and the surface of the chorion, indications of which have been observed by Eternod and Marchand and more distinct evidence by Beneke in human ova and by Selenka in apes—appears to arise later, and, indeed, it is questionable if it is of regular occurrence; it is a phylogenetic memory from dim ancestral times. Selenka (1903) believes that this amniotic umbilicus, as he calls it, following Bonnet, does not reach complete development in apes; that may also be the case in man; at all events it is wanting in the youngest stages yet observed, and, if it is of constant occurrence, its existence must be limited to a very short period of time.

As the amniotic (medullo-amniotic) cavity, so also the cavity of the yolk sack is formed by the splitting of an originally solid mass of cells; in the Peters ovum it is still so small—smaller than the ripe ovarian ovum—that one can hardly imagine it to be formed by being enclosed by a surrounding epithelial lamella of entoblast. No important difficulties stand in the way of its origin by a splitting process.

Graf Spee in his paper of 1889 makes use of ova which present an inversion of the germ layers for an explanation of the conditions which obtain in the human ovum.

On the other hand, I maintained (1890) that the peculiarities of the human ovum were to be explained by the early formation of the extra-embryonic cœlom and of the amnion, and that a sinking of the human embryonic anlage deep into the yolk sack, as in ova with inversion of the germ layers, could not be imagined.

In the endeavor to obtain a clear picture of the processes just discussed, the extraordinary minuteness of the embryonic structures must constantly be borne in mind. The diameter of the yolk sack in the Peters ovum is 0.19 mm., that is to say, it is not quite the size of a ripe human ovum.[16]

---

[16] According to Kölliker and Ebner ("Handbuch der Gewebelehre," 6 Aufl., vol. iii, 1902), the diameter of the ripe human ovum is 0.22–0.32 mm.; and Waldeyer remarks in Hertwig's "Handbuch" concerning this statement, that he has never seen human ova measuring more than 0.25 mm.

Elze and I have endeavored in our "Normentafel zur Entwicklungsgeschichte" to embody the results of the above considerations in a series of diagrams. Fig. 33, *A,* represents an ovum towards the end of segmentation as a whole object. Fig. 33, *B–F,* are sections, and it is assumed that all sections pass through the median sagittal plane of the future embryo. The figures are of such a size that they may be regarded as enlarged twenty-five times. The ovum shown in Fig. 33, *A,* is still surrounded by the zona pellucida; it may have just reached the uterus. *B* represents an ovum which has already eaten its way into the mucous membrane of the uterus. Four groups of cells are to be recognized in it. The periphery consists throughout of ectoblast cells—the trophoblast, represented in gray. Inside this trophoblast mantle are three cell-complexes. That which gives rise to the ectoderm of the embryo and of the amnion is represented in black; to the right, corresponding to the caudal end of the later embryo, we have left indistinct the boundary between it and the mesoblast complex, represented in red, in order to indicate that in this region there is perhaps a transition between the two complexes. We have represented this connection in the diagram, because wherever the development of the mesoblast has been sufficiently studied, the greater portion of it, at least, is found to arise from the ectoblast complex, and we find later, even in human ova, a primitive streak. It is extraordinarily difficult to picture to oneself how the processes actually take place in man, owing to the minuteness of the human ovum at this stage. The mesoblast complex is everywhere forcing the entoblast complex, represented in green, away from the trophoblast shell.

Fig. 33, *C,* shows an older stage. By a process of splitting in the ectoblast and entoblast complexes, the amniotic (medullo-amniotic) cavity in the one case and the cavity of the intestine and yolk sack in the other have been formed, and in a similar manner the extra-embryonic cœlom has formed in the mesoblast complex. We have already pointed out that another mode of formation of the cœlom is possible. In this case we must suppose that in this stage the extra-embryonic cœlom is not yet formed and we must imagine the cavity inside the red, which is left white in *C,* to have a pale reddish tinge and to represent solid but very loosely compacted mesoblast. Around the amnion, the yolk sack, and at the periphery next the trophoblast, the mesoblast, which as a whole is still solid, is somewhat denser. The amnion at this stage may still be in contact with the trophoblast shell.

Diagram *D,* Fig. 33, shows the conditions which obtain in the Peters ovum. The trophoblast mantle surrounding the ovum has developed lacunæ which are filled with maternal blood, and the mesoblastic axes of the villi have begun to grow out into the

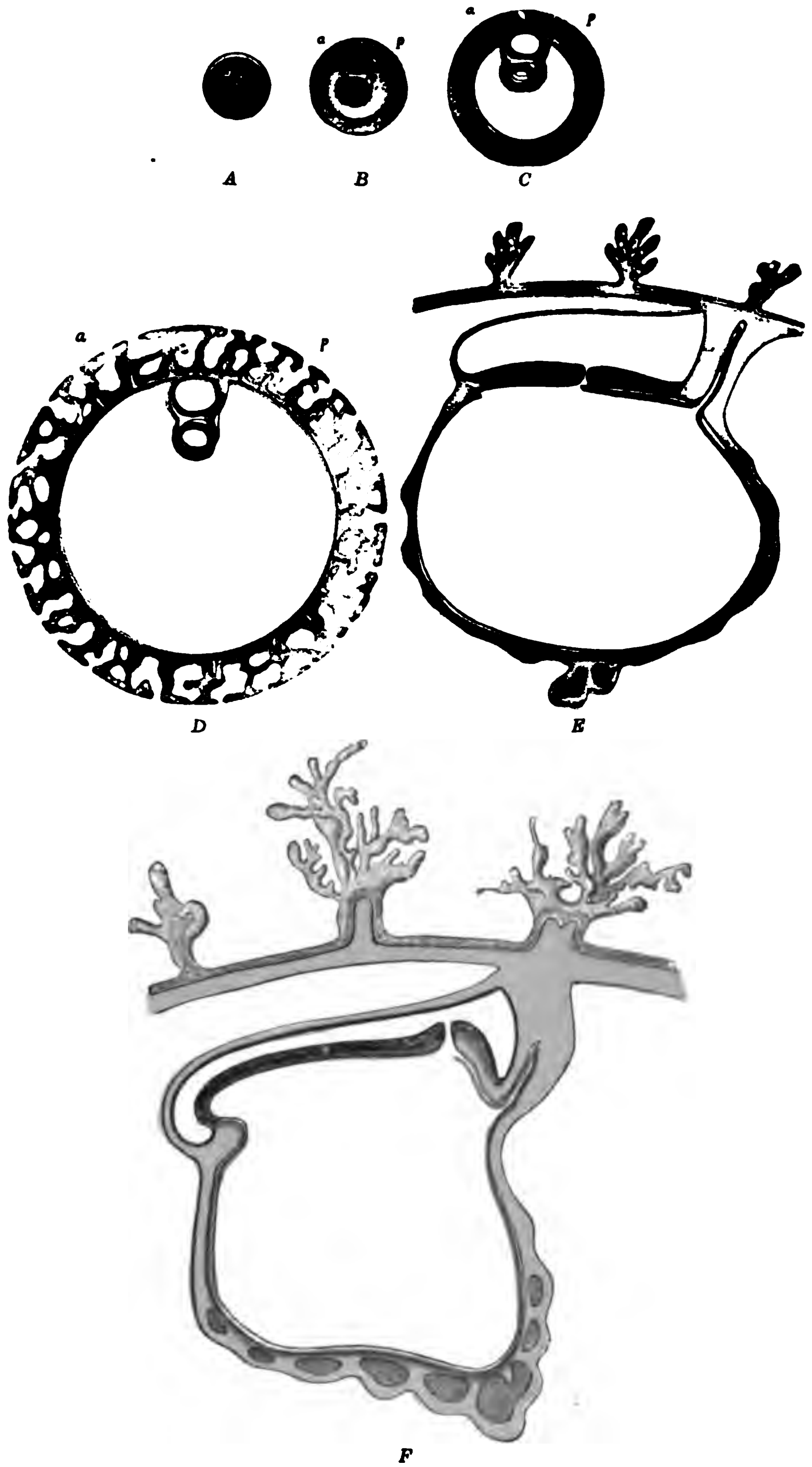

FIG. 33.—Stages in the development of germ layers. *Gray*, trophoblast; *black*, embryonic and amniotic ectoblast; *green*, intestinal and yolk-sack ectoblast; *red*, mesoblast. *a*, cranial end; *p*, caudal end. × 25. (From Keibel and Elze: Normentafel, p. 13, Fig. 2a-f.)

trophoblast. At the caudal extremity the belly stalk has become distinct, but an allantoic duct is not yet formed. Whether or not a very small primitive streak was present in the Peters ovum must remain doubtful; we assume that the delimitation of the ectoblast from the mesoblast was not quite sharp at the caudal end, and this we take to be the anlage of a primitive streak. The embryonic cœlom is represented as completely formed, although a somewhat different interpretation of the conditions in the Peters ovum has been mentioned. The ectoblastic covering of the embryo and the amnion are everywhere being forced away from the trophoblast by mesoblast cells.

Diagram *E,* Fig. 33, represents a median sagittal section through an ovum of the stage seen in the Frassi ovum. The anterior half of the section, in the region of the embryonic shield, is occupied by the floor of the medullary groove; behind it is the neurenteric canal; and then, lying in the same plane as the anterior half of the embryonic shield, the region of the primitive streak, which occupies about half the shield. At the caudal end of the primitive streak the cloacal membrane is already recognizable. The chorda is enclosed within the entoblast; anlagen of blood and blood-vessels occur in the yolk sack. An allantoic duct is present.

Diagram *F* shows a median sagittal section through the stage seen in Spee's Glaevecke embryo. Especially to be noted is the recession of the primitive streak and the fact that the now quite short primitive streak is bent down at an angle to the plane of the cranial extremity of the embryonic disk. A cloacal membrane must have been present at the caudal end of the primitive streak, but it is not represented in the diagram because it was not observed in the Spee embryo, probably on account of the direction in which the sections were made.

VI.

SUMMARY OF THE DEVELOPMENT OF THE HUMAN EMBRYO AND THE DIFFERENTIATION OF ITS EXTERNAL FORM.

BY FRANZ KEIBEL, FREIBURG I. BR.

THE first relatively satisfactory synopsis of the development of the external form of the human body is that given by His[1] in his "Anatomie menschlicher Embryonen" and in the Normentafel published with it. In the latter there is shown a series of human embryos dating from the end of the second week to the end of the second month. With this latter period the development of the embryo is so far advanced that the human in it is recognizable even to the laity; His designates this as the embryonic period and that succeeding it up to birth he terms the fetal period. A comprehensive account of the development of the body during the fetal period, with abundant illustrations, has been given by Gustav Retzius[2] in his memoir "Zur Kenntnis der Entwicklung der Körperform des Menschen während der fetalen Lebensstufen," published in 1904.

Disregarding studies of individual embryos there must also be mentioned here the "Normentafel zur Entwicklungsgeschichte" of Keibel and Elze,[3] Carl Rabl's "Entwicklung des Gesichtes"[4] and the splendid heliogravures of human embryos that Hochstetter[5] has published. Those who desire a comparison of human development with that of animals I would refer to Hertwig's "Handbuch"[6] in which I have considered the development of the external form in vertebrate embryos.

On account of the fundamental importance of His's "Anatomie menschlicher Embryonen," I here give a view of the

---

[1] W. His: Anatomie menschlicher Embryonen, Leipzig, 1880–1885.

[2] Gustav Retzius: Biologische Untersuchungen, neue Folge xi, 1904.

[3] Keibel and Elze: Normentafel zur Entwicklungsgeschichte des Menschen, Jena, 1908.

[4] Carl Rabl: Die Entwicklung des Gesichtes, Leipzig, 1902.

[5] F. Hochstetter: Bilder der äusseren Körperform einiger menschlicher Embryonen aus den beiden ersten Monaten der Entwicklung, Munich, 1907 (published by F. Bruckmann).

[6] F. Keibel: Die Entwicklung der äusseren Körperformen der Wirbeltierembryonen, etc., Hertwig's Handbuch, 1906, vol. i, chap. 6 (published 1902).

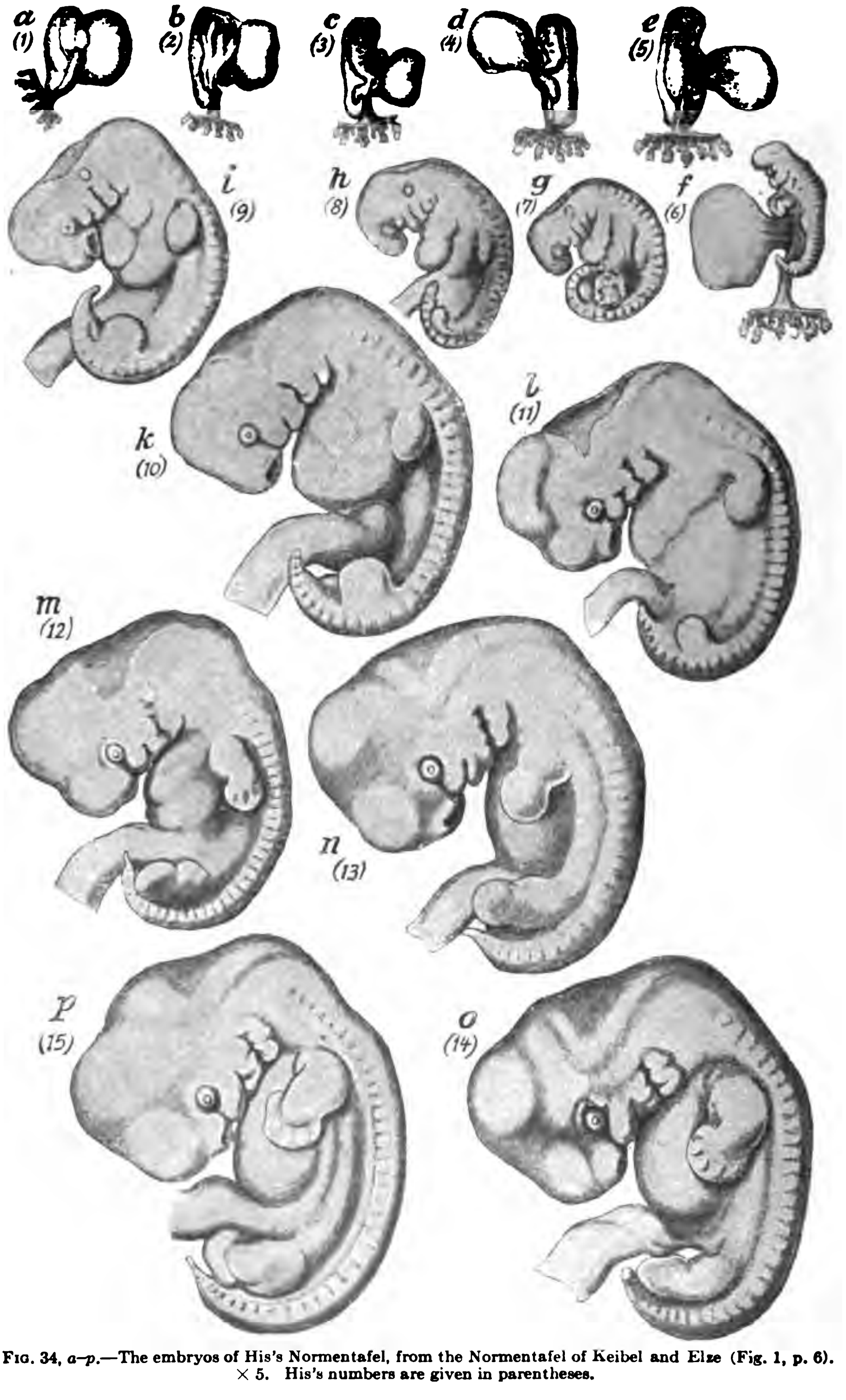

FIG. 34, *a–p*.—The embryos of His's Normentafel, from the Normentafel of Keibel and Elze (Fig. 1, p. 6). × 5. His's numbers are given in parentheses.

development of human embryos as shown in His's Normentafel, the first fifteen figures, as in the original, being enlarged five times, the remaining ones only two and a half times.

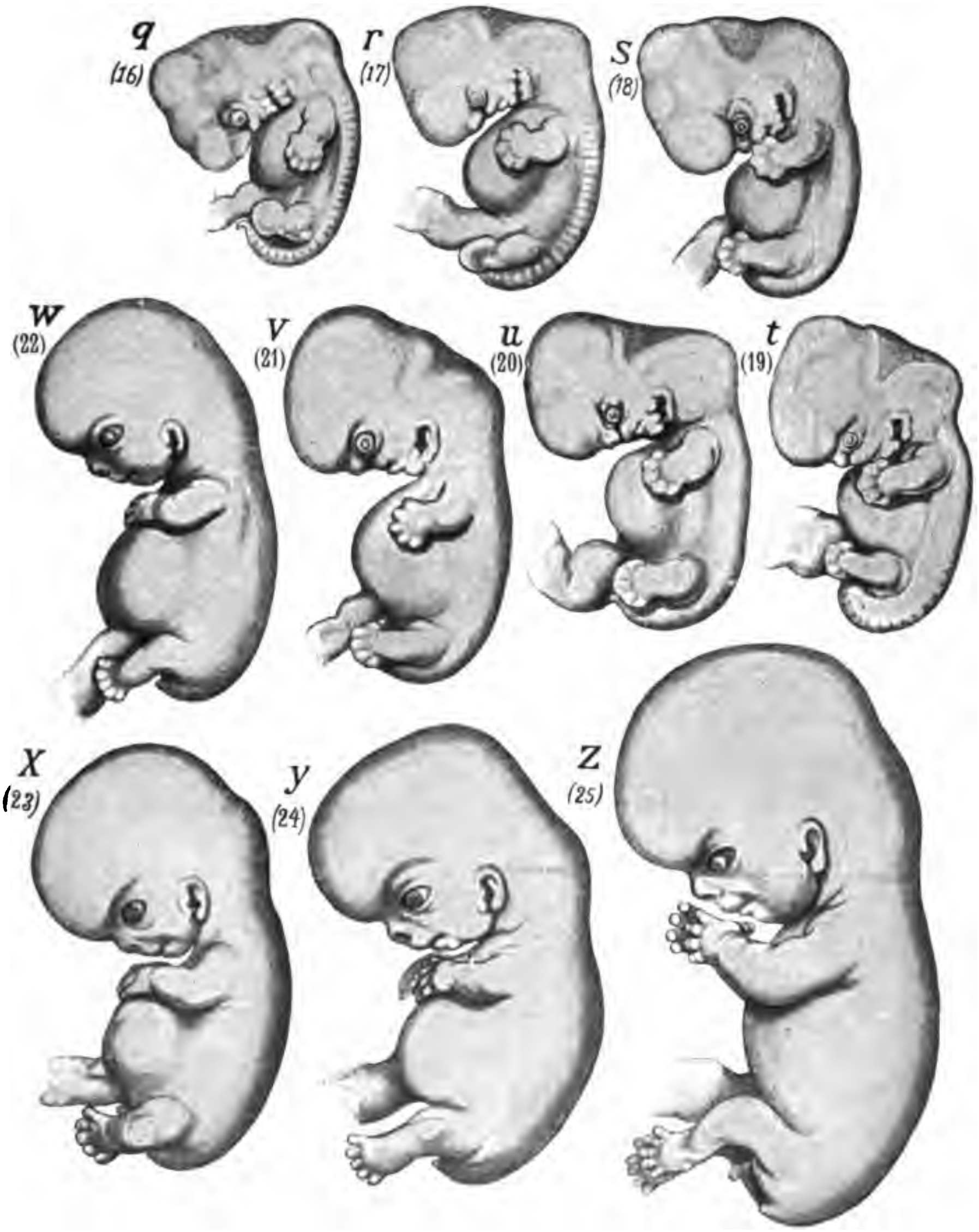

FIG. 34, *q–z*.—The embryos of His's Normentafel, from the Normentafel of Keibel and Elze (Fig. 1, p. 6) × 2.5. His's numbers are given in parentheses.

The individual embryos are lettered, His's numbers being given in parentheses.

To this reproduction of His's Normentafel I append a synoptic table from which it may be seen how His designated each embryo, its size, and its age, as estimated by His.

Fig. No.	His's designation.	Size in mm.	Source.	Estimated age in days.
a (1)	Embryo E (VII)	L. 2.1		12-15
b (2)	Embryo SR (VI)	L. 2.2		12-15
c (3)	Embryo Lg (LXVIII)	L. 2.15		12-15
d (4)	Embryo Sch (LXVI)	L. 2.2	Uterus	12-15
e (5)	Embryo M (IV)	L. 2.6		18-21
f (6)	Embryo Lr (LXVII)	L. 4.2		18-21
g (7)	Embryo *a* (III)	Nl. 4.0		23
h (8)	Embryo R (LVII)	Nl. 5.5		24-25
i (9)	Embryo A (II)	Nl. 7.5		27-30
k (10)	Embryo Pr.	Nl. 10.0	Uterus	27-30
l (11)	Berlin anat. collection	Nl. 9.1	Uterus	27-30
m (12)	Ruge's collection	Nl. 9.1		27-30
n (13)	Embryo M (X)	Nl. 10.5		31-34
o (14)	Embryo Br (XXIX)	Nl. 11.0		31-34
p (15)	Embryo Rg (LXXIV)	Nl. 11.5		31-34
q (16)	Embryo S_1 (XXXV)	Nl. 12.5		31-34
r (17)	Embryo CII	Nl. 13.7		31-34
s (18)	Embryo Sch_2 (XLVI)	L. 13.8		About 35
t (19)	Ruge's collection	L. 13.6		About 35
u (20)	Embryo Dr (XXXIV)	L. 14.5	Uterus	About 37-38
v (21)	Embryo S_2 (XXXVI)	L. 15.5		About 39-40
w (22)	Embryo XCI	L. 16.0		About 42-45
x (23)	Embryo Ltz	L. 17.5		47-51
y (24)	Embryo Zw	L. 18.5		52-54
z (25)	Embryo Wt (LXXVII)	L. 23.0	Extra-uterine	60

To avoid repetition I shall not proceed to describe His's Normentafel, but will consider a series of embryos which, in my opinion, present the best summary now available of the development of the external form of the human body; and in doing so I shall have occasion to consider the embryos of the Normentafel in their appropriate places. The so-called egg membranes will be described only in so far as they influence the form of the body.

Nothing need be added here concerning the youngest human embryonic disks to what has already been said in the chapter on "The Youngest Human Ova and Embryos." The embryonic disk of the Peters ovum had a length of 0.19 mm.; whether it possessed a very small primitive streak must remain doubtful. In Spee's Von Herff ovum the disk had an oval outline and presented a median groove lying between the dorsally convex lateral portions, which were somewhat unequal in the transverse direction. This groove is the primitive groove, and it may be supposed that the primitive streak extends through the entire length of the embryonic disk, since Spee says: "The entire anlage of the embryonic disk is apparently only a portion of the actual primitive streak region."

Close upon the embryonic disk of Spee's Von Herff ovum follows that of the Frassi ovum. In the former the primitive streak was at the height of its development, extending as it did throughout the entire germ; in the Frassi ovum it is about half the length of the embryonic disk, and at its cranial end it shows the anlage of a neurenteric canal, while at the caudal end, as has been noted (p. 36), the anlage of a cloacal membrane has appeared. In front of the primitive streak there is a shallow medullary groove bounded by low medullary folds. The entire embryonic disk is slightly convex in the craniocaudal direction and from right to left, and it covers the yolk sack like a lid.

FIG. 35.

Following this embryo that of Spee's Glaevecke ovum (Fig. 37) may be mentioned. The actual embryo had a somewhat "constricted pear-shaped" outline, and within this the outline of the biscuit-shaped medullary plate was distinctly marked. The caudal end of the embryo was bent sharply centrally, almost at a right angle, and, consequently, when looked at from above, appears greatly foreshortened. Slightly cranial to this downwardly bent portion there is a somewhat circular swelling, that in position corresponds to Hensen's node and surrounds, like a low wall, a roundish triangular opening, the neurenteric canal; behind this swelling is the primitive groove, resting upon the primitive streak. Anteriorly the primitive streak is embraced by the medullary folds. For the measurements of the embryo consult Chap. IV, p. 39.

FIG. 36.

FIGS. 35 and 36.—The Frassi embryo (Normentafel of Keibel and Elze, Fig. I, plate 1). Fig. 35 shows the embryo from above and Fig. 36 from the left side. Fig. 35 is from a model by Frassi, × 20; Fig. 36, from a model by Elze, × 25.

FIG. 37.—Graf Spee's Glaevecke ovum. × 20. (From the Normentafel of Keibel and Elze, Fig. II, plate 2.)

Next to this embryo comes embryo 1 of His's Normentafel.

This embryo was obtained from an ovum that measured in the fresh condition 8½ × 5½ mm. and was completely surrounded by villi. The length of the embryo, including the belly stalk, was 2.6 mm., and without the belly stalk was 2.1 mm. The yolk sack was somewhat flattened and measured 2.3 × 1.6 mm.

The embryo rested upon the yolk sack for about 2 mm. of its length and was enclosed in an amnion which also surrounded the upper surface of the belly stalk. In the embryo itself, the sectioning of which was unsuccessful, the medullary folds and medullary groove could be recognized, and laterally from the medullary folds at the anterior extremity the anlage of the heart was visible.

I place next the embryo Klb. of the Normentafel of Keibel and Elze, Figs. IIId and IIIa. The ovum which contained the embryo was obtained by a laparotomy and both it and the embryo may be regarded as quite normal. The embryo had five to six pairs of primitive somites. The vertex bend had already begun to form, otherwise the embryo lies flat on the yolk sack; it has no dorsal bend. Fig. 38 shows it from the dorsal surface, and, the amnion being cut away, it is seen to be attached to the chorion, a small portion of which is represented, by a short belly stalk. To the right and left of the cut edges of the amnion the yolk sack projects beyond the embryonic structures. Both the cranial and caudal ends of the embryo are separated from the yolk sack, but the middle portion is still spread out flat. The medullary groove is widely open, but rather deep. Caudally the medullary folds embrace the dorsal opening of the neurenteric canal and the cranial end of the primitive streak, which immediately bends downward so that it cannot be perceived in its entire extent; indeed, it has already undergone much retrogression. The well-marked medullary anlage shows the vertex bend, so that its cranial end cannot be seen in a dorsal view. The brain part of the medullary anlage shows a separation into three portions, the most caudal of which extends to about the fourth pair of primitive somites and then passes without any marked boundary into the spinal cord. I may here note that by far the greater part of the dorsal region of this embryo belongs to the later head region. The boundary between the head and trunk regions passes through the fourth primitive somite. The most anterior somite of the neck region is first differentiated.

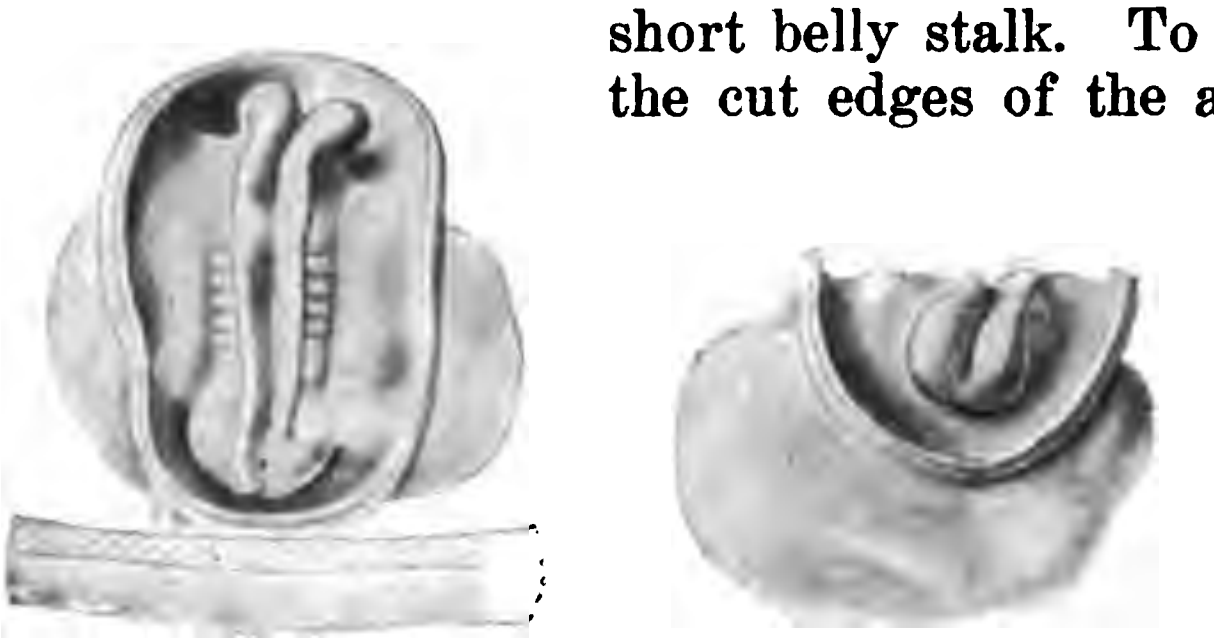

Figs. 38 and 39.—The embryo Klb. from the Normentafel of Keibel and Elze, Figs. IIId and IIIa. × 20.

Fig. 39 shows the embryo from in front. The amnion has again been removed; ventrally the relatively large yolk sack is seen. Of the embryonic anlage only the ventrally bent portion, as far back as about the vertex bend, can be seen; but it may be observed that the most anterior portion of the brain anlage is relatively greatly developed. The medullary groove terminates a little behind the cranial end of the medullary anlage, so that the latter shows anteriorly a transverse ridge. Nothing is yet to be seen of the optic pits, the forerunners of the optic vesicles.

Regarding the measurements of this embryo Krömer makes the following statements: "The greatest length of the embryonic anlage from the anterior amniotic border of the head cap to the chorionic end of the belly stalk was 1.95 mm.; the length of the embryo, without the belly stalk, from head to tail was 1.8 mm.; the greatest breadth of the yolk sack was barely 1.2 mm.; the breadth of the embryonic disk at the junction of the amnion and yolk sack (measured in an anterior view) was 0.9 mm." The size of the yolk sack was 1.1 mm. in height, 1.4 mm. in breadth, and 1.5 mm. in length.

After this embryo, that represented in Fig. 2 of His's Normentafel may follow, although on account of its possessing a dorsal flexure I am somewhat in doubt if it is normal in form. Its greatest length was 2.2 mm. The greatest diameter of the somewhat collapsed yolk sack was 1.9 mm.; and the embryo rests upon it in such a way that anteriorly the head end, for a distance of 0.4 mm., and posteriorly the caudal end, for a distance of 0.5 mm., project beyond the yolk sack navel, which is 1.3 mm. in length.

The body of the embryo shows the middle of the dorsal surface somewhat depressed and the head and tail ends are somewhat bent downwards. The margins of the medullary plate are still wide apart, and a number of primitive somites, how many could not be exactly determined, were formed. The anlage of the heart was still paired, and upon the surface of the yolk sack there were numerous wart-like elevations (anlagen of blood-vessels).

FIG. 40.—The Bulle embryo of Kollmann. ×20. (From the Normentafel of Keibel and Elze, Fig. IV, plate 5.)

The Bulle embryo of Kollmann (Fig. 40) may well come in here or even after the embryo Klb. Both the head and tail ends project beyond the yolk sack, which communicates widely with the intestine, so that one cannot yet speak of a yolk stalk. The yolk sack has been cut away, except for the part by which it is continuous with the embryo; and similarly the amnion has been cut away not far from its root; under the caudal end of the embryo is to be seen the belly stalk. The figure shows the embryo from behind and from the right, so that the heart swelling is hidden. The brain portion of the medullary canal, in which the segments of the brain can be seen, is still open, and the caudal end of the canal is also open, although this cannot be perceived from the figure. If we reckon three of the fourteen primitive somites as belonging to the head and eight to the neck region, there still remain three as representing the thorax; in the relatively small caudal end of the embryo almost all the segments of the trunk and tail must still be represented. In the region of the sixth to the fourteenth somites the dorsal surface of the embryo is slightly depressed. Kollmann says: "In the region of the sixth primitive somite the flexure of the dorsal region, which later becomes so striking, is noticeable." I cannot recognize in the figures of the embryo a flexure in the region of the sixth somite, and in any case the sixth segment belongs to the neck region. That a dorsal flexure occurs at this stage or later in normal human embryos I regard as disproved, and in this Spee[7] is in agreement with me. In 1905[8] I had come to the conclusion that even if a dorsal flexure normally occurs in human embryos it can only be at a stage of development in which six or at the most twelve primitive somites are present. I do not, however, regard the evidence of its occurrence at this stage as sufficiently based upon the embryo that Êternod[9] has had modelled by Ziegler and upon an embryo with seven pairs of primitive somites belonging to Graf Spee.[10]

It is a question whether in this and other cases one has not to deal with a deformity produced by swelling. (For further consideration of this matter see the Normentafel of Keibel and Elze, pp. 22–23.)

The greatest length of the embryo, measured after it had been preserved in alcohol, was 2.36 mm.

Figs. 41 and 42.—The embryo Pfannenstiel III. × 20. (From the Normentafel of Keibel and Elze, Figs. Vr and Vv.)

The embryo Pfannenstiel III (Figs. 41 and 42), figured in Keibel and Elze's Normentafel, has the same number of primitive somites as the Bulle embryo of Kollmann, yet it is more developed. It was obtained from a hysterectomy and was modelled by Elze. The medullary tube is open in the brain region as well as caudally; but, in addition to the vertex bend, present in the embryo Klb., a nape bend has appeared; there is no indication of the dorsal

---

[7] Schwalbe's Jahresbericht, Jena, 1906, neue Folge, vol. xi, 2 Abt., p. 225 (literature of 1905).

[8] Keibel: Zur Embryologie des Menschen, der Affen und der Halbaffen, Verh. Anat. Ges. (Genf), 1905; also in C. R. Soc. des Anatomistes, 1905.

[9] Compare A. C. F. Êternod: Il y a un canal notochordal dans l'embryon humain, Anat. Anz., vol. xvi, 1899.

[10] Graf Spee: Mitteilungen über den Verein schleswig-holsteinischer Aerzte, vol. xi, article 8, 1887.

flexure. The optic pits were distinct and the auditory epithelium was slightly depressed. The greatest length of the embryo measured 2.6 mm.

The flexure which I have termed the nape bend was very striking in this embryo. If it be normal, it is very doubtful if the nape bend that is found in later stages is comparable with it, and if it does not later disappear before the well-known nape bend of later stages develops. Older embryos of mammals and also of man, such as embryo 3 of His's Normentafel, still lack a nape bend, as does also an orang-outang corresponding to this last embryo.[11]

At this point a great gap unfortunately occurs in our series of human embryos, so that a settlement of the question is at present impossible. The embryo shown in Fig. VI of the Normentafel of Keibel and Elze had already twenty-three pairs of primitive somites; in addition, our ideas as to its external form are based upon a not very successful model, whose head region presents a very improbable form. I shall not, therefore, give a figure of the embryo here, but merely describe it briefly. It shows a well-marked vertex bend, but no distinct nape bend; and it is spirally coiled, so that its tail end comes to lie to the right of the very large belly stalk. The medullary tube is still open at its caudal end. The heart swelling lies entirely in the amniotic cavity, and through its thin wall the heart must certainly have been shadowed. Three branchial arches and as many branchial furrows were recognizable, and dorsal to the second furrow there was the already greatly narrowed opening of the ear vesicle. The extremities have not yet formed.

FIG. 43.—His's embryo M (His's Normentafel, Fig. 5 = Fig. 35e.) × 20.

Embryos 3, 4, and 6 of His's Normentafel, Fig. 34, *c* (3), *d* (4), and *f* (6) I regard as abnormal; *c* (3) and *d* (4) show the much discussed dorsal flexure and *f* (6) seems to me for other reasons to be excluded from the series.

The embryo shown in Fig. 34, *e* (5), seems to me more worthy of confidence; and I repeat it here, more highly magnified, as Fig. 43. It came from an ovum which measured 7.5–8 mm. in diameter and was completely surrounded with villi. The amnion

---

[11] See F. Keibel: in Selenka's Menschenaffen, 9 Lieferung, 1906.

lies close to the embryo and does not yet entirely enclose the heart. The body of the embryo is bent upon itself anteriorly and at the same time twisted about its axis so that the head end is turned toward the left and the pelvic end toward the right. The dorsal curvature is very regular, and the nape prominence is not yet pronounced. The anterior portion of the head is bent ventrally to such an extent that the vertex is formed by the midbrain. Behind the anterior part of the head there is a deep depression, which indicates the entrance of the oral sinus and is continued dorsally in the orbitonasal groove. Behind the mouth cleft is a broad mandibular process, separated by a groove from the second visceral arch; and the posterior boundary of this second arch can also be made out. The study of the entire embryo revealed no clear picture of the third and fourth arches, although their presence was quite evident in sections. The anlage of the heart projected from the ventral surface of the body as a broad transverse swelling; its prolongation on the right side extends forward as the aortic bulb to the edge of the mandibular process. To the atrial portion of the heart belongs an outpouching which is seen ventral to the hinder portion of the head, on the lateral wall. Immediately behind the heart the umbilical vesicle (yolk sack) projects from the umbilicus, which has the form of a longitudinal cleft; the yolk sack was somewhat sunken in and was pyriform in shape.

The pelvic end of the body is curved forward in a hook-like manner and on account of the twisting of the embyro cannot be seen from the left side. In the posterior half of the trunk one sees four parallel longitudinal ridges, two of which, the medullary and somitic ridges, belong to the axial zone, while the other two, the Wolffian and marginal ridges, belong to the parietal zone. No traces of the extremities are yet visible. According to His's estimate there were thirty-five pairs of primitive somites. His gives the following measurements:

Greatest length in a straight line	2.6 mm.
From vertex to behind the mandibular process	0.7 mm.
From vertex to behind the heart	1.4 mm.
Height of yolk sack where it projects from umbilicus	0.6 mm.
Maximal height of yolk sack	1.7 mm.
Length of yolk sack	2.6 mm.
Length of the posterior portion of the body, measured from the point of emergence of the yolk sack	0.6 mm.

The first embryo of Hochstetter's series (Fig. 44), which belongs to Professor Fischel of Prague, presents a very great advance in development. As the figure shows, it is not only very greatly curved upon itself, but it is also strongly twisted spirally. In the head one sees the primary optic vesicles and on the first branchial arch an early indication of the maxillary process. Both upper and lower extremities are recognizable, the former being plate-like. The definitive nape bend is strongly developed. The greatest length of the embryo was 4.02 mm.; it was obtained as an abortion.

The embryo which I would place next in the series is embryo G 31 of the Anatomical-biological Institute of Berlin (Fig. 45) (Fig. VIII of the Normentafel of Keibel and Elze); it stands close to embryo 7 (Fig. 34, *g*) of His's Normentafel. Its greatest length is the nape-breech length (nape line) and is 4.9 mm.; the vertex-breech length is 4.7 mm. It is rather strongly curved upon itself, but more regularly than the preceding embryo; the nape bend is strongly marked, and the spiral twisting is still quite distinct. The tail lies to the right. The upper extremities are plate-like in form, the lower ones ridge-like. The anterior end of the head shows in the middle line a slight depression, and the anlagen of the eyes show through the integument. The region of the later sinus cervicalis is still but little depressed, so that the third and fourth branchial arches are quite easily seen. The atrial and ventricular portions of the heart can be distinguished through the thin wall of the pericardial cavity.

FIG. 44.—The Fischel embryo. × 10. (After Hochstetter: Bilder der äusseren Körperform menschlicher Embryonen, Munich, F. Bruckmann.)

A few words may be said concerning embryo 7 of His's Normentafel (Fig. 34, *g*). This embryo has reached the highest degree of curvature that has yet been observed in the human embryo. The length from the forehead to the tip of the coccyx following the curvature was 13.7 mm.; the straight line from the nape prominence to the twelfth thoracic segment, the nape line (NL), was 4 mm. in length. The tail end was curved forward to the level of the ventricle of the heart and lay upon the left side of this. In the curve which is formed by the embryo from the forehead to the tip of the coccyx there are four regions where the bending is stronger than elsewhere: (1) the region of the mid-brain; (2) the nape prominence; (3) the boundary between the neck and thoracic regions; and (4) the boundary between the abdominal and pelvic regions. The plane of symmetry of the embryo is warped and is twisted in such a way that the head looks to the right and pelvic end to the left. The upper extremities are plate-like, the lower ridge-like.

FIG. 45. — The embryo G 31 of the Anatomical-biological Institute in Berlin. × 10. (From the Normentafel of Keibel and Elze, Fig. VIII, plate 14.)

At the head end the shape of the cerebral hemispheres, the tween-brain, mid-brain, hind-brain, and after-brain, is plainly recognizable, and the boundaries of the fourth ventricle are sharply defined. In a view from the dorsal surface the lateral walls of the fourth ventricle show a series of regular and bilaterally symmetrical transverse folds (neuromeres). The optic vesicles form on each side a circular circumscribed projection measuring 0.35 mm. in diameter, and the auditory vesicles are very evident as oval structures lying at the level of the second visceral groove. In addition to the moderately developed maxillary and mandibular processes the lateral wall of the head shows on each side three visceral arches, the fourth of which is still fully exposed. The distance from the anterior border of the maxillary process to the fourth branchial groove was 1.4 mm.; a line drawn through the ventral ends of all four arches was almost straight and cut the fore-brain some distance in front of the optic vesicles. The anterior borders of these were about 0.55 mm. from the anterior pole of the fore-brain, so that the prominence of the fore-brain characteristic of human embryos in all later stages of development is already present. Immediately behind the ends of the visceral arches is the heart, the three portions of which are plainly visible when the embryo is examined from both sides, with this difference, however, that the atrial swelling is more distinct on the left side and the swelling of the aortic bulb on the right side. No deep cleft yet separates the swelling produced by the aortic bulb from the facial surface of the head. The visceral region of the body lying behind the heart shows on the right side a distinct Wolffian ridge and the transition border of the amnion; on the left side no characteristic elevations are visible.

FIG. 46. — Embryo 112 of Keibel's collection. × 10. (From the Normentafel of Keibel and Elze, Fig. IX, 1, plate 6.)

Near Fig. 8 of His's Normantafel (Fig. 34, *h*) stands the embryo shown in Fig. 46. It was obtained as an artificial abortion. It shows the vertex and nape prominences and is not only strongly curved on itself but is also spirally twisted. The olfactory area is beginning to show a better delimitation dorsally and laterally, and the maxillary process can be seen in a profile view. In the region of the sinus cervicalis which is still widely open, the third and fourth branchial arches are plainly exposed; the heart swelling is very prominent and the atrial and ventricular portions of the heart are recognizable. The liver swelling is still but poorly developed, and the tail is curved in between the heart swelling and the belly stalk. Dorsal to the primitive somites one sees O. Schultze's[12] division of the sclerotomes. The embryo had thirty-six pairs of somites.

FIG. 47.—The Braus embryo. × 10. (From Hochstetter: Bilder der äusseren Körperform menschlicher Embryonen, Munich, F. Bruckmann.)

Between embryos 8 and 9 of His's Normantafel (Fig. 34, *h* and *i*) there is a rather wide interval, into which the embryos shown in Fig. X and Fig. XI of the Keibel-Elze Normentafel fit. The embryo shown in Figs. XII and XIr corresponds fairly well with the Braus embryo shown in Figs. 2 and 3 of Hochstetter's series. For explanation of the figure of this, shown in Fig. 47, a few words will suffice. The olfactory area is beginning to be delimited more sharply dorsally and caudally; the first and second branchial arches have now become relatively large and have begun to be further modified; the triangular area caudal to them, in which the third and fourth arches are situated, is slightly depressed, forming the sinus cervicalis; the upper extremities have passed from the plate-like into the stump-like stage.

Following closely upon this embryo comes embryo 9 of His's Normentafel (Fig. 34, *i*). In it the nape bend is more strongly marked, so that the head is much more bent down upon the heart;

---

[12] O. Schultze: Ueber embryonale und bleibende Segmentierung, Verh. Anat. Ges., 1896, pp. 87–93.

the distinctly circumscribed olfactory pit rests upon the heart. The tips of the anterior extremities have become bent ventrally, and the roots of the extremities are correspondingly angled. In the trunk one sees three tumor-like projections, of which the two situated more cranially and ventrally are produced by the ventricular and atrial portions of the heart, while that lying more caudally and dorsally is formed by the liver. The embryo shows a very distinct external tail. The external configuration of the head is principally determined by the subdivisions of the brain, whose shapes are clearly recognizable through their thin covering. At the base of the fore-brain is the olfactory pit, and a slight distance in front of this is the eye with the lens groove. The smallness of the eye compared with the great development of the fore-brain is characteristic. A prominence behind the eye marks the position of the ganglion of the trigeminus; it lies in the angle between the mid-brain and hind-brain. At the level of the second visceral groove the auditory vesicle, together with the ganglion acusticum lying in front of it, forms a slight elevation. Elevations are beginning to appear on the mandibular process and hyoid arch; the third and fourth branchial grooves lie at the bottom of a triangular depression, which will become the sinus cervicalis.

FIG. 48.—Embryo 304 of Robert Meyer, Berlin. × 10. (From the Normentafel of Keibel and Elze, Fig. XIV, plate 32.)

Embryo 10 of His's Normentafel is comparatively large for the degree of development it presents; it resembles the preceding embryo, and was taken from a uterus.

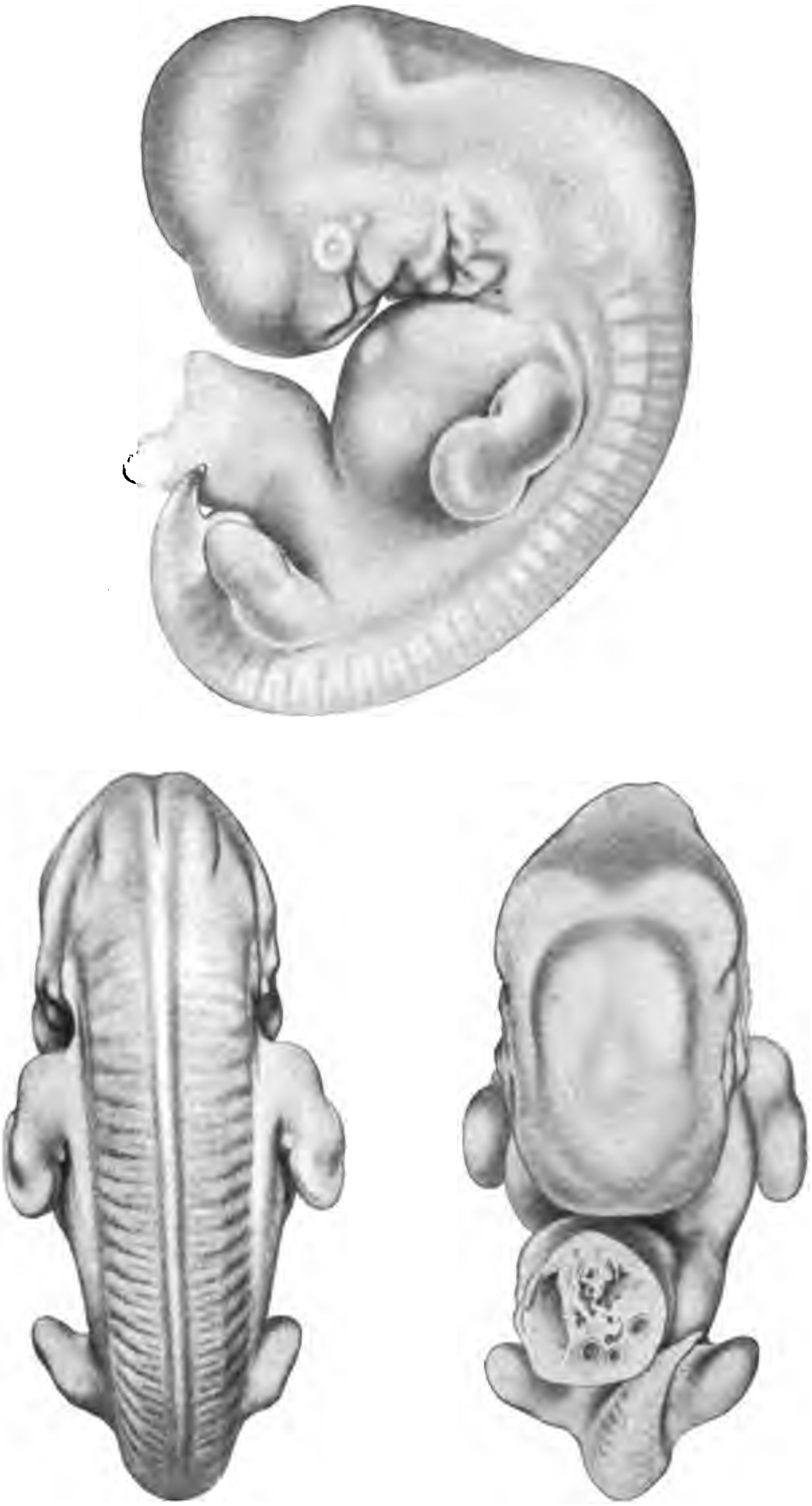

Figs. 49–51.—The embryo Ma. 3 of Hochstetter. × 10. (From the Normentafel of Keibel and Elze, Figs. XVII l XVII d, and XVII v, plate 41.)

Embryo XIV of the Keibel-Elze Normentafel (Fig. 48) is not quite so large, but is more developed. This is shown especially by the condition of the extremities and of the sinus cervicalis. Behind the dorsal part of the hyoid arch one may perceive the entrance into the glossopharyngeal organ (the second branchial groove organ). In the upper extremities the hand plates are distinct. Forty trunk somites were counted, and the last six of these were beginning to be transformed into a tail filament. The embryo was obtained from an artificial abortion.

FIG. 52.—The embryo P. 1 of Hochstetter. × 10. (From the Normentafel of Keibel and Elze, Fig. XIX, plate 45.)

The embryo to which we now come may be considered not only from the left side (Fig. 49) but also from the dorsal (Fig. 50) and ventral (Fig. 51) surfaces. It is the Hochstetter embryo Ma. 3, Fig. XVII of the Keibel-Elze Normentafel and Figs. 7, 8, and 9 of Hochstetter's series. The trunk region has again begun to elongate. The spiral twisting is evident only to a slight extent in the tail region, the tail lying to the left of the belly stalk. The nape bend is almost a right angle; the cerebral hemispheres are recognizable externally; and the cerebellum shows out plainly, especially in the ventral view (Fig. 51). The axes of the upper limbs are almost parallel to the dorsal line; the hand plates are almost circular; the elbows show especially distinctly in the dorsal view (Fig. 50); and in the same view one may perceive, on the surface of the upper limb which looks towards the trunk, a small tubercle. In the lower limb the foot plates are marked off. Dorsal to the row of primitive somites one can clearly distinguish Schultze's segmentation of the sclerotomes. The maxillary processes have come into relation with the median nasal process, the openings of the nasal pits look towards the wall of the pericardium and are no longer to be seen from the side, especially from the left. A distinct sculpturing is present on the mandibular process and especially on the hyoid arch. The entrance into the sinus cervicalis is still visible as a small triangular hole.

In part somewhat more and in part less developed than this are embryos 11, 12, and 13 of His's Normentafel (Fig. 34, *l*, *m*, and *n*); that shown in Fig. 11 (*l*) was taken directly from the uterus. In that shown in Fig. 12 (*m*) a small nape furrow has formed beneath the strong nape prominence and the position of the upper extremities does not seem normal. In that shown in Fig. 13 (*n*) the body is relatively slender and a heart swelling cannot be made out.

FIG. 53.—The embryo Chr. 2 of Hochstetter, × 5. (From the Normentafel of Keibel and Elze. Fig. XX, plate 61.)

The body of Hochstetter's embryo P. 1 (Fig. 52) (No. 10 of Hochstetter's series, Fig. XIX of the Normentafel of Keibel and Elze) is already rather elongated. The elbows have moved out from the body and the forearm makes an acute angle with the dorsal line. The fingers are beginning to become distinct on the hand plates, and the foot plates have become circular. Close to this embryo come those shown in Figs. 14, 15, 16, and 17 of His's Normentafel (Fig. 34, *o*, *p*, *q*, and *r*); in Figs. 15, 16, and 17 the thumbs are distinctly recognizable.

In the lower limbs of Figs. 18, 19, and 20 of His's Normentafel (Fig. 34, *s*, *t*, *u*, and *v*) the anlagen of the toes can be seen. The head is gradually bending to the erect position, and in correspond-

Figs. 54-56.—Rabl's embryo C. ×5. (From Hochstetter: Bilder der äusseren Körperform menschlicher Embryonen, Munich, F. Bruckmann.)

ence with this the neck is forming; the formation of the external ear is also making progress. These stages may be represented here by Hochstetter's embryo Chr. 2 (Fig. 53, No. 15 of Hochstetter's series, Fig. XX of the Keibel-Elze Normentafel), Rabl's embryo C (Figs. 54, 55, and 56, Nos. 16, 17, and 18 of Hochstetter's series) and the embryo No. 302 of Robert Meyer's collection (Fig. 57, Fig. XXI of the Normentafel of Keibel and Elze).

In the embryo Chr. 2 the nape bend is somewhat more than a right angle. The mouth lies in close contact with the pericardium, and the nose has become free from it. The folds of the pinna, the tragus and the antitragus, are formed; the concha is widely open and flat. Behind the nape prominence the contour of the back shows a distinct depression. The fingers have become quite pronounced and the toes are just indicated, but the position of the great toe is already to be recognized. The elbows and knees are evident, and the angle that the axis of the forearm makes with the dorsal line is almost a right angle.

Slightly further developed than this is Rabl's embryo C (Figs. 54, 55, and 56). The nose is more marked off, the eyelids are further advanced, and so also the ear. The finger-tips are distinctly projecting beyond the border of the hand plate. In the ventral view one may note the position of the eyes and of the limbs. Between the foot plates may be seen the physiological umbilical hernia. The tail has become transformed into a coccygeal tubercle. In the dorsal view the sharp slope of the caudal portion of the trunk is striking.

The embryo 302 of Robert Meyer's collection (Fig. 57) shows a distinct depression between the root of the nose and the forehead. The pinna, tragus, and antitragus are evident; and while the concha is still widely open it shows a tendency to deepen. Early indications of the eyelids are to be seen. The nape flexure is still very evident, but it forms an obtuse angle, and the depression of the dorsal line just below it is less marked. The nose and mouth have both separated from contact with the pericardium; the mouth is slightly open and the mandible lies close upon the breast. The shoulder is distinctly marked off from the body, the upper arm makes an angle with the forearm, and the elbow projects strongly. The hand plate is beginning to turn ventrally, and the finger anlagen are very distinct; their tips are becoming free and the thumb is strongly abducted. In the lower limb the knee is very distinct and anlagen of the toes are appearing on the foot plate. The dorsum of the foot is not yet marked off from the crus.

When we pass from embryo 21 (Fig. 34, *v*) to embryo 22 (Fig. 34, *w*) of His's Normentafel, we are passing from the embryonic to the fetal stage. The profile of the latter embryo already shows clearly a nose, upper lip, lower lip, and chin; and the neck is also present. The eyelids are formed, and above the eyes there is a distinct supra-orbital swelling. The upper limb, in which the fingers have become distinct, has increased in length considerably and shows a distinct division into upper arm, forearm, and hand. The shoulder has formed, and the characteristic position of the arms is worthy of note. In the lower limb the foot, crus, and thigh can be distinguished. The anlagen of the toes are not yet separated from one another, but that of the great toe is especially well marked. The nape prominence and nape depression are much reduced, and the coccygeal tubercle still appears as a short stumpy tail.

With the three remaining stages of His's Normentafel, Figs. 23, 24, and 25 (Fig. 34, *x*, *y*, and *z*) the transition from embryo to fetus has been accomplished. In Fig. 34, *x*, one sees the toes separated from each other, and the great toe has a characteristic abducted position, recalling the position of the thumb in the corresponding stage in the development of the hand. In Fig. 34, *y*, the foot is better formed; the legs have undergone a twisting so that the knee looks more upwards and the foot more downwards. Fig. 34, *z*, still shows a slight nape prominence and a very shallow nape depression. The small creature shows a distinctly human character in its features. Some additional figures may complete the story.

FIG. 57. — Embryo 302 of Robert Meyer, Berlin. × 5. (From the Normentafel of Keibel and Elze, Fig. XXI, plate 64.)

The embryo shown from in front in Fig. 58 corresponds somewhat to Fig. 22 (Fig. 34, *w*) of His's Normentafel. The position of the eyes, the broad nose, and the position of the limbs may be noted.

A fetus measuring 25 mm. in its greatest length is shown from the left side and from the ventral aspect in Figs. 59 and 60, reproduced from the Normentafel of Keibel and Elze. It may be regarded as standing between Figs. 24 and 25 (Fig. 34, *y* and *z*) of His's Normentafel. Again I would call attention to the position of the limbs. In Fig. 59 we see touch pads on the sole of the right foot. At the summit of the coccygeal tubercle there is a small knob, as in all well-preserved embryos of this stage, and it is also seen in the ventral view (Fig. 60), in which the physiological umbilical hernia is indicated by the coils of the intestine showing through the wall of the cord.

We may now again pass in review the stages which the human embryo must traverse in order to acquire its human form. The earliest known embryos are flat, shield-like plates which rest upon the yolk sack. At a certain stage a primitive streak extends throughout the entire length of the shield; in front of the primitive streak the embryo is formed, and it grows at the expense of the streak, which retrogresses in a craniocaudal direction. The streak is thus converted into a growth zone, which may be termed at first the trunk bud and later the tail bud. To correctly understand these processes of development we must bear in mind the extent to which the head region predominates in young embryos.

Fig. 58.—Bulius embryo, 13/2. 1907. × 5. (From the Normentafel of Keibel and Elze, Fig. XXII, plate 70.)

Returning again to the primitive streak, during its modification its caudal end becomes bent ventrally; the cloacal membrane had previously formed in this caudal region, and it now comes to lie on the ventral surface. This bending process is associated with the constriction of the embryo from the yolk sack; cranially and caudally, from the right and from the left, the boundary grooves cut inwards and soon convert the yolk sack into a stalked vesicle; in the meantime the dorsal portion of the embryo grows more rapidly than the ventral, a condition caused by the accelerated growth of the medullary anlage. Before the medullary plate is converted into a tube the brain, with its principal subdivisions, becomes distinct at the anterior end, and the optic pits are also formed. By the rapid growth of the brain portion, while the medullary tube is still open, there is produced a bending down of its cranial portion (the vertex bend) and, if the Pfannenstiel embryo III (Figs. 41 and 42) is to be regarded as normal, also the more caudal nape bend. It has been already pointed out, however, on pp. 66 and 67, that a difficulty exists in this particular. Embryos that are properly believed to be older do not show the nape bend distinctly, and these agree with the embryos of other mammals, especially with that of the orang-outang which I described in 1906. There are two possibilities: either the nape bend of the embryo shown in Figs. 41 and 42 was an abnormality; or it is a primary nape bend that normally disappears, the long known nape bend later appearing independently of it. On account of the lack of the necessary stages this question cannot be decided at present; but in any event the entire embryo soon becomes curved on account of the much greater growth of the dorsal surface, and coils itself in a spiral. The spiral turns sometimes to the right and sometimes to the left. While these developmental processes are taking place there has formed from the tail bud a small but unquestionable external tail. In these stages also the head region still predominates to an extraordinary degree, but the embryo no longer consists, as in the stages of the early primitive somites, only of the future head, so to speak. The extensive coiling toward the ventral surface is followed by a very gradual uncoiling; first the trunk straightens out and the nape bend slowly becomes obliterated. These processes are accompanied, perhaps determined, by a rapid growth of the ventrally situated organs, especially of the heart and liver, which produce on the surface of the body the heart and liver prominences. The Wolffian bodies do not play a very important part in this respect in man. With the straightening out of the nape bend opportunity is afforded for the formation of the neck. Originally the face lies closely upon the heart prominence and the ventral portion of the neck is entirely wanting, while its lateral parts are occupied by the branchial or visceral

Figs. 59 and 60.—The Marburg fetus No. 21. × 2.5. (From the Normentafel of Keibel and Elze, Figs. XXV l and XXV v, plate 82.)

arches. The transformation of these interesting structures will be thoroughly described in other places; here the following may suffice. The third and fourth arches—quite transitorily there is also recognizable the anlage of a fifth—remain small in comparison with the first and second, the mandibular and hyoid arches, and consequently the region in which they occur becomes depressed, forming the sinus cervicalis, which becomes covered in by the second or hyoid arch and its opercular process. In the region of the first branchial groove there are formed on the mandibular and hyoid arches a number of elevations and folds from which the external ear is formed; its development will be considered in detail with the sense organs.

In determining the form of the head the brain is at first almost the controlling organ, and its various parts can be distinguished until relatively late stages through the thin walls of the head. Gradually the mesenchyme increases in the walls, and, above all, the face begins to develop in the service of the principal sense-organs and of the respiratory and digestive tracts; its formation will be considered later on.

The ventral wall of the trunk is at first very thin, and the heart with its various parts, the liver, and other viscera may be seen through it. From the right and left the anlagen of the skeleton and the musculature grow into the walls; inhibitions of this growth may occur and produce ectopia cordis and fissura sterni, which depend upon disturbances of this process in the thoracic region. A portion of the intestine normally projects like a hernia into the umbilical cord, in association with the outward growth of the abdominal walls; thus the hernia funiculi umbilicalis physiologica is produced. Normally this hernia disappears with the further formation of the abdominal walls, but occasionally it may persist as an inhibition structure.

On the ventral wall of the body the region from the umbilicus to the end of the trunk is the original primitive streak territory. That portion of the streak which was originally, before it became bent ventrally, the caudal portion, but which is now directed cranially, becomes encroached upon by the developing skeletal and muscle anlagen of the trunk. If inhibitions occur in this region ectopia vesicæ and pelvic clefts may be produced, and epispadias also belongs in this category. The openings of the urogenital sinus and the anus and the intervening perineum arise in the territory of the portion of the cloacal membrane which persists after the formation of the abdominal wall below the umbilicus. For an account of these developmental processes reference may be had to the chapter on the urogenital apparatus.

That a tail occurs in the human embryo has already been noted; embryos of 4–12 mm. NL. have a typical external tail, in which a caudal gut occurs and which possesses more segments and spinal ganglia than persist. This external tail (cauda aperta) becomes transformed in its distal portion into a tail filament, which is knob-like in the human embryo and is later cast off, while the remaining portions become overgrown by the neighboring parts and so disappear beneath the surface; in this situation remains of it may persist, forming what is termed the internal tail (Braun, 1882) or cauda occulta (Rodenacker, 1898).[13]

If one now glances at the body as a whole, one can hardly fail to be struck by the fact that the cranial portion is much more fully developed, up to relatively later stages, than the caudal portion; this is shown very clearly by the dorsal views of embryos, and I would call attention, in this connection, to Figs. 51 and 55.

The extremities first appear as ridges which later are converted into plates, becoming more sharply defined cranially and caudally. The portion which is first formed corresponds essentially to the anlage of the hand or foot; gradually the anlagen of the forearm and crus, and then those of the upper arm and thigh, grow out from the body. The further differentiation of the extremities, as well as that of the face and head, will now be considered more thoroughly, and for this purpose good figures are much more important than extensive descriptions.

The figures showing the development of the face in the first stages of its formation are rather few in number, since the processes cannot be well observed in the human embryo without dissection, and dissection prevents the obtaining of a continuous series of sections. I shall start with a stage that Rabl estimates at nineteen to twenty days; according to the estimate of Bryce and Teacher (see pp. 26 and 27) it would be considerably older. It corresponds essentially to Fig. VI of the Normentafel of Keibel and Elze and to embryo 5 (Fig. 34, *e*) of the His Normentafel. Fig. 61 shows a profile view of it. Three branchial arches are recognizable; on the first the maxillary process cannot be seen in this view, although it is present, as may be seen from the front view (Fig. 62). The optic vesicles, which are directed laterally, show through the wall of the head, and over the second arch are the auditory vesicles, not yet quite closed. In the front view (Fig. 62) one looks into the pentagonal oral sinus; it is bounded above by the frontal process, laterally and above by the maxillary processes, and below by the mandibular processes. Much more developed is the face that I reproduce (also from Rabl) in Fig. 63. It is from an embryo which measured 8.3 mm. in the preserved condition and belonged, according to Rabl's estimate, to the fourth or perhaps the beginning of the fifth week. It corresponds fairly well with Fig. 11

---

[13] Compare Keibel in Hertwig's Handbuch, vol. i, part 2, p. 151.

(Fig. 34, *l*) of His's Normentafel and to Fig. XIV of those of Keibel and Elze. The pentagonal opening of the oral sinus has transformed into a broad mouth-cleft, whose lower border shows a notch between the two adjacent ends of the mandibular processes. The nasal pits are distinct; they are deeper dorsally and are flattened out ventrally. One may also speak of the two nasal processes, that is to say, the ridges which bound the nasal pits laterally and medially. The portion of the frontal process between the medial nasal processes is still very broad.

FIGS. 61 and 62. — Head end of an embryo *en face* and from the left. The embryo corresponds essentially to embryo M of His (here Fig. 43). × 20. (From C. Rabl: Die Entwicklungsgeschichte des Gesichtes, Leipzig, 1902.)

The advance that is to be seen in Fig. 64 (again from Rabl) is quite marked. The figure represents the face of an embryo that corresponds to Fig. 14 (Fig. 34, *o*) of His's Normentafel and to Fig. XIX of those of Keibel and Elze; its nape-breech length was 11.3 mm. and its age was estimated by Rabl at thirty to thirty-one days. In the head the fore-brain region is markedly prominent; below the forehead the area triangularis (His) projects, and below the middle of this there runs what is only a moderately broad groove through the mouth opening into the palate, separating the medial nasal processes, which at their first appearance were so far apart. The two nasal openings are not only relatively but absolutely nearer each other than in the preceding stage, and look directly forward. The lower ends of the medial nasal processes, which are uniting with the maxillary processes, are separated by a slight depression from the lateral processes and are the processus globulares (His). The lateral nasal processes are consequently excluded from the formation of the upper boundary of the mouth, which becomes the upper lip.

FIG. 63. — Head of an embryo of 8.3 mm. NL., seen *en face*. × 10. (From Rabl, *l.c.* It corresponds essentially to Fig. XIV of the Normentafel of Keibel and Elze, here Fig. 48.)

Fig. 65 shows the face of a 15 mm. embryo from in front, after Retzius. The upper lip is still divided, the nasal septum is still somewhat incomplete, and the processus globulares are still visible. From the upper angle of the nose two folds run from above and medially downward and laterally, the medial one passing to the angle of the mouth; these are the *oblique maxillary folds,* that is to say, the *nasolabial* and the *suborbital folds.* The eyes are directed distinctly laterally and are comparatively wide apart; the mouth is very wide; and at the middle of the lower jaw the anlage of the chin is visible, although the lower jaw and chin are as yet very poorly developed.

Fig. 64.—Head of an embryo which corresponds essentially to Fig. XIX of the Normentafel of Keibel and Elze (here Fig. 52). × 10. (From C. Rabl, *l. c.*).

Figs. 66 and 67 show the head of an embryo of 18 mm. *en face* and in profile (after Retzius). The view *en face* appears rather remarkable; Retzius thinks that the embryo may not have been quite normal, but gives no further reason for such a supposition. The description given of the preceding embryo will answer for this one also, if it be added that the nasal septum is now completely formed. In the profile view the position of the ear should be noticed; if the mouth cleft be produced dorsally the ear would lie below it.

Figs. 68 and 69 show profile and *en face* views of the head of a fetus of about eight weeks and 25 mm. in length (after Retzius). The eyelids are in process of formation and supra-orbital folds also occur, in addition to the nasolabial and suborbital. The supranasal groove is strongly marked. The distance between the eyes is still considerable, and they are distinctly directed laterally.

Figs. 70 and 71 represent the head of a fetus 42.5 mm. in its greatest length (ninth week), in profile and *en face.* In the profile view the great development of the forehead region is striking, and below this the root of the nose is deeply depressed. The nose is still low, but the lower jaw and chin are well marked. The eyes are completely closed by the lids, but the distance between the inner angles of the eyelids is very considerable; from medially and above the interpalpebral fissures are directed laterally and downward. The upper eyelid is relatively

Fig. 65. — Head of an embryo of 15 mm., seen *en face.* × 5. (After G. Retzius, *l. c.*, Plate XVI, Fig. 1.)

small and is bounded above by a sharply-marked arched groove and below by the interpalpebral fissure; from the inner angle of the eye a supra-orbital groove extends obliquely laterally and upward. The nose is very broad in proportion to its height (172:100), and the external nares are closed by the epidermal plugs which are continuous with an epidermal thickening on the upper lip.

Figs. 66 and 67.—Head of an embryo of 18 mm., seen *en face* and in profile. × 5. (After Retzius *l. c.*, Plate XVI, Figs. 3 and 4.)

Figs. 68 and 69.—Head of a fetus of 25 mm., seen *en face* and in profile. × 2.5. (After Retzius, *l. c.*, Plate XVI, Figs 5 and 6.)

Figs. 70 and 71.—Head of a fetus of 42.5 mm., seen *en face* and in profile. × 2.5. (After Retzius, *l. c.*, Plate XVI. Figs. 8 and 9.)

Finally, the profile view of the head of a fetus 117 mm. in length may be shown (Fig. 72), and in it I would draw especial attention to the projecting upper lip and the receding chin, to the double lip, and to the shape of the nose. The pinna has almost the position it holds in the adult. With regard to the mouth it may be observed that the vertical median furrow which becomes the philtrum appears in the fourth month. The wall-like projecting margin of the upper lip is separated from the inner portion, which in the fourth and fifth months shows more or less projecting tubercle-like elevations. The middle portion of the margin early becomes the tuberculum labii superioris. In a similar manner the wall-like margin of the lower lip becomes delimited from the inner portion. In the first half of the third month the two lips project about equally, but later the border of the upper lip and the lip itself grow more rapidly, so that in the fourth and fifth months it projects markedly beyond the lower lip; by a stronger growth of the lower jaw and lip this difference is gradually overcome in the sixth to the ninth months, but by a kind of inhibition process the early fetal arrangement may be retained in the adult to a marked degree. Retzius has given especial attention to the time of occurrence of individuality, and comes to the conclusion that in man it is recognizable even in the fourth month of intrauterine life, and becomes more marked in the succeeding months.

Fig. 72.—Head of a fetus of 117 mm., in profile. Natural size. (After Retzius, *l. c.*, Plate XVII, Fig. 10.)

The first phases of the development of the extremities up to the formation of the fingers and toes have already been considered in connection with the development of the entire embryo; an account of the further changes in the hand and foot may now be presented, the descriptions given by Retzius being followed closely.

The hands, after the fingers are formed, early assume their human form and even in the third month have acquired their most important characters; they are then comparatively broad and the fingers are flexed. Of the persistent palmar furrows only the largest, the lines of Venus and Mars, are distinct in the third month. Four distal metacarpal pads (touch pads) appear at the beginning of the third month opposite the interdigital clefts, and in the course of this month they develop into strongly marked elevations. In addition, there is a distinct ulnar marginal pad on the metacarpus and one or sometimes two carpal pads. On the terminal phalanges strongly prominent, hemispherical touch pads develop. These, as well as the metacarpal pads, become relatively lower in the fourth and fifth months, and their boundaries become gradually more indistinct; only in individual cases do they persist in a more evident form with the later half of the fetal period. The feet are always somewhat behind the hands in their development. Even long before the separation of the individual toes by the interdigital clefts the abducted position of the great toe is striking; and very early, even in the second month, the prominence of the heel is recognizable. The great toe is from the beginning somewhat thicker and the little toe somewhat smaller than the other three. The soles, like the palms, are at first directed medially, and consequently are opposed to one another. The dorsum of the foot is relatively very high in the third month, and also broad towards the roots of the toes. Compared with their position in the adult the feet as a whole have now an " oblique " position (the varo-equinus position); the arch of the sole is beginning to develop.

FIG. 73.—The right hand of a fetus of 25 mm., seen from the volar surface. × 10. (After Retzius, *l c.* Plate XXIII, Fig 20.)

FIG. 74.—The posterior end of a fetus of 25 mm., seen from the dorsal surface. × 10. (After Retzius, *l. c.*, Plate XXIII, Fig. 23.)

During this time, at the beginning of the third month, a row of distal metatarsal pads appears as four or five roundish or oval elevations, and one soon sees clearly that they lie opposite the interdigital clefts; it seems as though a shifting toward the lateral (fibular) side occurred. In the next stage, that is to say, in the latter half of the third month, there are four metatarsal pads which correspond to the interdigital clefts, the fifth seems to have shifted proximally on the lateral border of the foot. At this time the four first-mentioned pads are relatively at their highest stage of development, and simultaneously the pads on the terminal phalanges have developed to hemispherical plantar elevations. In the fourth and fifth months the distal metatarsal pads undergo a relative retrogression and their outlines become gradually indistinct; the phalangeal pads remain well marked, although their outlines become less pronounced.

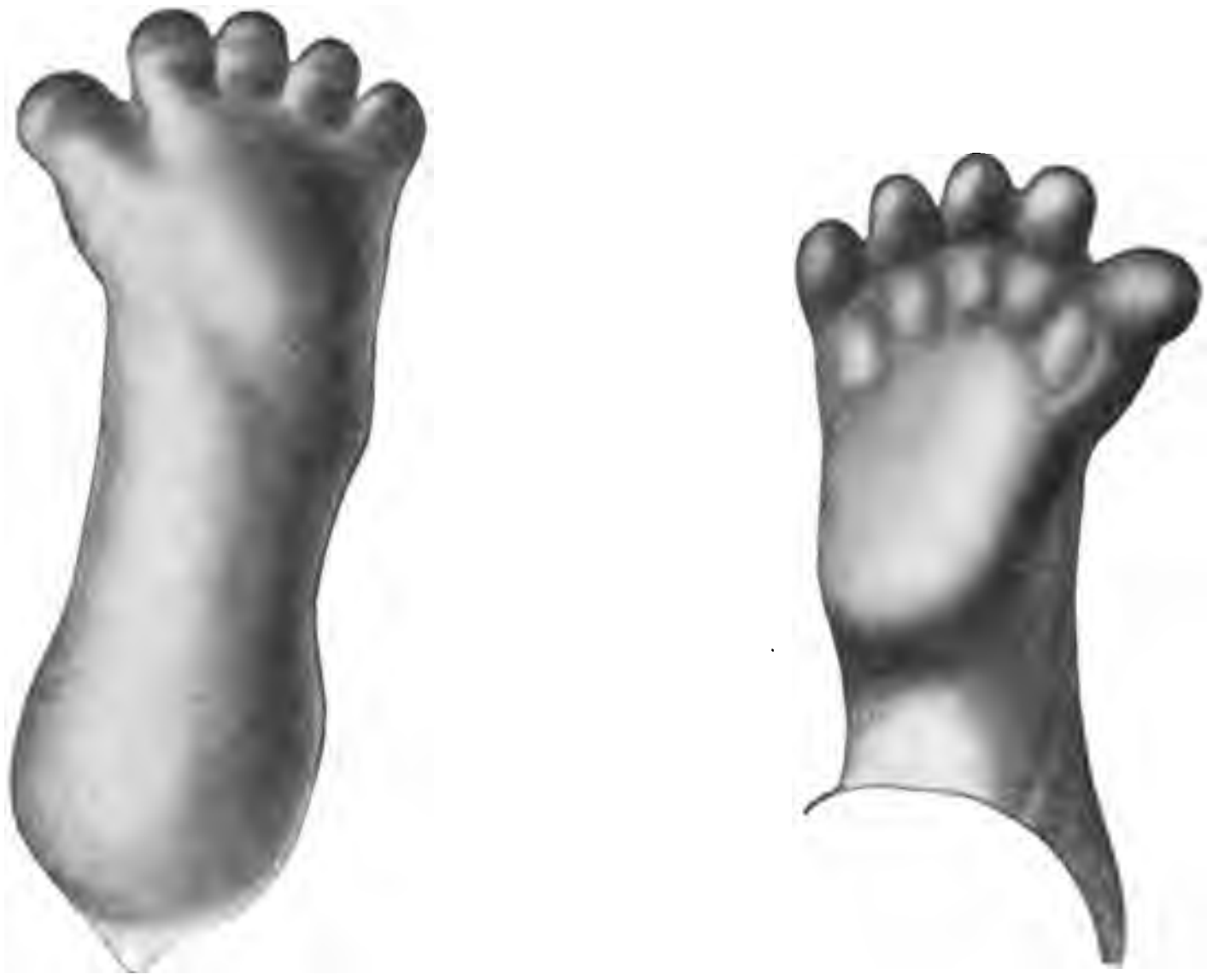

Figs. 75 and 76.—The right arm and foot of a fetus of 25 mm., seen from the dorsal and the plantar surfaces. × 10. (After Retzius, *l. c.* Plate XXIII, Figs. 22 and 20.)

Some figures may make these points clear. Figs. 73–76 represent the extremities of a fetus of 25 mm. Fig. 73 shows the right hand from the volar surface with the touch pads; Fig. 74, the two lower extremities seen from behind and dorsally. The feet are seen from their fibular borders, and their plantar surfaces are turned toward one another. The high dorsum and the malleolar eminences should be noted. Figs. 75 and 76 show the right foot from the dorsal and plantar surfaces; the abducted position of the great toe and the metatarsal touch pads cannot be overlooked.

Fig. 77 shows the sole of the right foot of a fetus of 44 mm. with its touch pads; Fig. 78 represents the middle finger of a fetus of 52 mm. from the side.

In the descriptions of the development of the face, hands, and feet the conditions in the fetal period have already been considered. For the development of the form of the rest of the body reference must be made to Gustav Retzius (*l. c.*).

FIG. 77.—The right foot of a fetus of 44 mm., seen from the plantar surface. × 10. (After Retzius, *l. c.*, Plate XXIV, Fig. 8.)

Retzius has been the first to study thoroughly the proportions of the human body during the fetal period, and a *résumé* of his most important results may bring this chapter to a close.[14] He finds as follows:

1. The entire body length, measured from vertex to heel, increases during the fetal period to a greater extent than the vertex-breech length, that is to say, the lower limbs continually increase in length.

2. The relation of the height of the head to the vertex-breech length, gradually diminishes.

3. A comparison of the length of the entire vertebral column with the height of the head and with the different regions of the column shows that:

a. The height of the head diminishes relatively to the length of the vertebral column.

b. In general, only a slight change can be observed in the ratio of the cervical vertebræ to the entire column, although there is a certain tendency towards a relative shortening of the cervical vertebræ in the earlier stages.



FIG. 78.—The middle finger of the right hand of a 52 mm. fetus, seen from the right side. × 10. (After Retzius, *l. c.*, Plate XXIV, Fig. 9a.)

c. Scarcely any change, apart from individual variations, can be seen in the relation of the thoracic vertebræ to the entire column.

d. The relation of the lumbar vertebræ to the entire column shows no appreciable change.

e. The relation of the sacrococcygeal vertebræ to the entire column also shows no material change; individual variations are, however, especially great, and the difficulties in the way of making exact measurements are worthy of note.

4. The relation of the circumference of the head to the body length diminishes from the earlier stages.

5. As regards the relation of arm length to body length, it was found that during the second and third months the arm grows to such an extent that often even in the third month, and more certainly in the fourth and beginning of

---

[14] Compare also Chapter VIII.

the fifth, it reaches its greatest relative length for the fetal period, its first maximum (37–42 per cent. of the body length).

6. As regards the relation of the upper extremity to the lower and of the leg length to the body length, it may be said that the lower limb grows more slowly than the arm during the fetal period; at the end of that period it is scarcely as long as the arm, but after birth it soon surpasses it. The relative maximum of length for the fetal period (36–39 per cent. of the body length) is acquired by the leg at about the fifth month.

7. A comparison of the arm length with the lengths of the upper arm, forearm, and hand shows that:

a. During the period from the third to the tenth month the upper arm is about 39–42 per cent. of the entire arm length.

b. In the relation of the arm length and that of the entire distal part of the arm (forearm and hand) there are no perceptible changes either of progression or regression during the fetal period.

c. Also the arm length compared with the forearm length (without the hand), and

d. The arm length compared with the hand length show no noteworthy changes of proportion during the fetal period.

8. The relations of the length of the lower limb to those of the three portions of which it is composed may be stated as follows:

a. The relation of the thigh length to the leg length shows no noteworthy changes from the third to the tenth month.

b. In the relation between the leg length and that of the crus (omitting the height of the foot), a slight relative elongation of the crus is evident about or before the middle of the fetal period.

c. In the relation of the length of the foot to the leg length there is a definite relative elongation of the foot, especially from the sixth to the eighth month.

9. In the relation of the breadth of the iliac crests to the body length no actual change occurs during the fetal period from the third to the tenth month.

10. As regards the proportions of the head and face during the fetal period, Retzius' results are as follows:

a. Ratio of head length to head width: In the first months, while the cerebral hemispheres are still developing posteriorly, no measurements can be obtained that allow satisfactory comparison. Notwithstanding that Retzius worked with Swedish embryos and that the Swedes are a typically dolichocephalic race, it seems that there is a strong tendency to brachycephalism and, indeed, to a quite high degree of it.

b. Ratio of head length to head height: This index is very high in the early months (112.5, 111.1, 100, etc.); it is still high in the third month (108.5, 104.2, etc.); but toward the end of this month it sinks (86.0, 81.6), and remains at about the same level from the fourth to the seventh months, with only a few individual variations upwards. If the figures given above are interpreted according to the standard employed for adult skulls they all denote hypsicephalism (75.1 and over).

c. Ratio of head length to head circumference: In general, the circumference of the head is about or almost three times as great as the length. The index, which at first is smaller, increases during the third month to this value and remains about the same, with individual variations, to the seventh month.

d. Ratio of head width to head height: This index shows a definite tendency to diminish, apart from individual variations.

e. Ratio of head circumference to face height: The figures show no regular change until the seventh month; it is remarkable that during these stages almost the same values recur.

VII.

THE DEVELOPMENT OF THE EGG MEMBRANES AND THE PLACENTA; MENSTRUATION.

BY OTTO GROSSER, PRAGUE.

I. INTRODUCTION.

THE difficulties in the way of a comprehensive description of human placentation have been mentioned so often that a detailed re-enumeration of them is unnecessary here. The first stages, so necessary for the understanding of all the later ones, are lacking, just as they are in the case of the formation of the germinal layers, and, as in this case, must be conjectured by deduction and analogy. In the following description an endeavor will be made to state what has been determined with certainty, and, in connection with this, to call attention to disputed questions and to the probable significances of the phenomena described.

A statement of our knowledge in the field of comparative placentation may also be dispensed with, since it has repeatedly been given in detail within recent years.[1] The position which man occupies among the Mammalia on the basis of the structure of the placenta may, however, be indicated; and, in connection with this, the nomenclature employed in placental classification and the general morphological and histological processes involved in the formation of the placenta may be described.

Placentation is (in mammals) the intimate union (apposition or fusion) of the mucous membrane of the uterus with the outer layer of the ovum, the chorion, which becomes vascularized from the allantois [2] for the purpose of providing for the respiration and nutrition of the embryo and for carrying away its waste products.

---

[1] O. Schultze: Grundriss der Entwicklungsgeschichte, 1897; Strahl: Embryonalhüllen der Säuger und Placenta, in Hertwig's Handbuch, 1902; Bonnet: Lehrbuch der Entwicklungsgeschichte, 1907, and, most recently, O. Grosser: Vergleichende Anatomie und Entwicklungsgeschichte der Eihäute und der Placenta, Lehrbuch für Studierende und Aerzte, Wien, 1909. From this last work the majority of the illustrations of this chapter have been taken. A very complete list of the literature on human placentation is to be found in the work of F. Keibel and C. Elze: Normentafel des Menschen, Jena, 1908.

[2] In some mammals also from the yolk sack. According to the view of Hubrecht (see especially Resink, Tijdschrift Ned. Dierk. Vereen, 1903, 1905: Hubrecht, Quart. Journ. Micr. Sc., 1909), however, the chorion possesses from the beginning a vasifactive mesoderm. Compare Grosser's Lehrbuch.

Since the union of the chorion and the uterine mucous membrane is either an apposition or a fusion, the expulsion of the chorion sack after birth either may take place without injury to the uterine mucous membrane or a portion of the latter, the *decidual membrane* (*membrana decidua*)[3] may be expelled with it; hence the old division of the Mammalia into the lower *Adeciduata* and the higher *Deciduata.* But tissue destruction frequently takes place during pregnancy in the former, and, on the other hand, in many highly organized forms the placenta contains no considerable quantity of maternal tissue, if the maternal blood be disregarded, so that in these it is hardly proper to speak of decidua (Strahl). Accordingly, Strahl[4] has employed the relations of the maternal blood as a basis of classification and has designated these placentæ "in which post partum the spaces of the placenta which carry maternal blood are separated and expelled" *complete placentæ* or *placentæ veræ;* while those simpler placentæ, in which during and after birth the maternal blood-spaces remain intact, are termed *half placentæ* or *semiplacentæ.* The classification proposed by Robinson (1904) is practically the same, since his "apposed placentæ" include those in which there is merely an apposition of the chorion to the uterine mucous membrane, while those in which there is fusion of the two he terms "conjoined placentæ." In the same way the two groups proposed by Assheton (1906), that of the *placentæ plicatæ* with simple, non-proliferating chorionic epithelium, and that of the *placentæ cumulatæ* with a greatly proliferated and thickened chorionic epithelium, traversed by lacunæ for the maternal blood, agree essentially with the two divisions of Strahl.

The idea of placental types which the author[5] has conceived takes its origin from another standpoint. The nutritive material which passes from the maternal blood into that of the fetus in the lowest types of placentæ passes in succession through maternal endothelium, connective tissue, uterine epithelium, portions of the uterine cavity, the chorionic epithelium, chorionic connective tissue, and the endothelium of the chorionic vessels. At the commencement of development all the maternal walls are present in the highest types of placentæ also. But while the fetal layers are always retained, or, in the highest types, are gradually formed,

---

[3] As a rule, however, the term decidua is not only applied to the superficial layer which is expelled, but also includes the entire thickness of the mucous membrane. This is the case with its application to the human placenta.

[4] In Hertwig's Handbuch, 1902, and recently in a fuller somewhat modified statement in Der Uterus puerpuralis von *Erinaceus europæus,* Verhandl. K. Ak. Wetensch., Amst., 1907.

[5] Verh. morph. Gesellsch., Wien, 1908; Zentralblatt für Physiologie, 1908; and Lehrbuch.

during the early stages of development, the maternal partitions disappear one after the other in the course of the phylogenesis or ontogenesis, the chorionic epithelium penetrating farther and farther toward the source of its nutrition, the maternal blood. But the blood spaces themselves, those of the mother on the one hand and those of the fetus on the other, remain sharply separated under all circumstances. The penetration of the fetal tissue may halt at any stage and so determine the structure of the mature placenta and also the name which may be applied to it, this indicating the maternal tissue which is in immediate contact with the chorionic epithelium. At the beginning of the series stand placentæ such as those of the pig, in which all the maternal partitions are retained; the uterine and chorionic epithelia are in contact; and the placenta is a *placenta epitheliochorialis.* If the maternal epithelium disappears, at least to a considerable extent, as in the ruminants, the chorionic epithelium comes into contact with the connective tissue and a *placenta syndesmochorialis* is formed. If the connective tissue also disappears, so that the chorionic epithelium is in contact with the endothelium of the maternal blood-vessels, as is the case in the Carnivora, according to Schoenfeld, then the placenta is to be termed a *placenta endotheliochorialis.* And, finally, if the endothelium disappears, so that all the maternal partitions have vanished and the maternal blood directly bathes the chorionic epithelium, then the highest possible stage of placentation has been reached and the placenta is a *placenta hæmochorialis.* Thus the most important morphological character of a placenta is directly indicated by its name.

The further subdivisions may, following Strahl, be based on the form of the placenta. Thus there may be recognized a *placenta diffusa,* in which the chorionic proliferations or villi are uniformly distributed; a *placenta multiplex,* with the villi arranged in groups; a *placenta zonaria,* in which they have a girdle-like arrangement; and a *placenta discoidalis,* in which they are aggregated to form a disk-like structure. The last group, which includes the highest types of placentæ (the hæmochorial of the classification given above), may be divided, again following Strahl (1905), into *labyrinth placentæ,* with narrow capillary-like channels for the maternal blood, and *bowl placentæ* (*placentæ olliformes*), in which the maternal blood has the form of a large sinus, the floor of the space (bowl) being formed by decidua and the roof by the chorion, from which the villi project into the space.

The human placenta is a placenta vera (conjugata, cumulata) discoidalis olliformis, or, according to my nomenclature, a *placenta hæmochorialis discoidalis olliformis.* It represents the highest development of its type, a development which even the placentæ of the anthropoid apes have not quite reached.

The nutrition of the embryo takes place, in general, in two ways: on the one hand, by the transference of nutritive material from the blood of the mother to that of the child; and, on the other, by the direct absorption by the chorionic epithelium of products of the maternal mucous membrane, these products frequently being subjected to a kind of digestive process before they pass into the embryonic circulation. These maternal substances are partly products of secretion, partly waste products, together with extravasated maternal blood, and have been included by Bonnet under the term *embryotrophe* and by English authors have been designated *pabulum*. In the lower types of placentæ the embryotrophe plays an important rôle throughout the entire duration of pregnancy; in hæmochorial placentæ, and therefore in man, we find (as has been noted, for instance, by Pfannenstiel and Jung), at the beginning of development, up to the establishment of a definite circulation in both the maternal and fetal blood spaces, a very distinct absorption of embryotrophe consisting of degenerated maternal tissues, while later, embryotrophe is entirely wanting, at least in the region of the placenta.[6] In hæmochorial placentæ, therefore, two phases or stages may be distinguished: an *embryotrophic phase,* at the commencement of development; and a later *hæmotrophic phase,* not sharply distinguished from the former in time, but during which the nutritive material is received from the maternal blood exclusively.

This absorption of material cannot, however, be regarded as a simple process of diffusion. This could be the case only with crystalloid substances at the most; colloids, on the other hand (such as the albumins, for instance), are taken from the maternal blood by a process of resorption, associated with a partly constructive and partly destructive activity on the part of the epithelium of the villi; and certain highly complex substances, such as many immunity substances, cannot pass the placenta at all. The chorionic villi of the placenta have a certain similarity to the intestinal villi (Hofbauer), the maternal blood corresponding to the digested food material. Up to the present the wandering of fat, glycogen, and iron, the last as hæmoglobin or its derivatives, has been followed histologically from the maternal blood through the chorionic epithelium into the fetal vascular system. The fat, which penetrates into the chorionic epithelium in a state of solution (saponification), is reconverted into fat globules within the epithelium at the bases of its cells.[7] The hæmoglobin comes from

---

[6] A modification of this statement is necessary in connection with the maternal blood. See below.

[7] Holsti (1908) lays special weight upon fatty degeneration of the decidua, upon fat formation in the glands, and upon the transportation of fat from other organs by leucocytes; this fat is directly absorbed by the chorionic epithelium up to the close of pregnancy.

the maternal blood-corpuscles which degenerate in the placenta itself, perhaps in contact with the chorionic epithelium. Oxygen is set free from the oxyhæmoglobin of the mother, probably by ferment action (for further consideration consult Hofbauer and Kehrer). The maternal blood, therefore, often assumes in later stages, even in placentæ of the highest type, the rôle of the embryotrophe, although not in a manner easily recognizable histologically; and also for this reason the term hæmotrophic phase is justifiable.

In placentation many cytological phenomena occur that are not observable elsewhere. The most striking are those that lead to the formation of multinucleated masses of protoplasm. Bonnet (1903) has brought order into the exceedingly confused nomenclature of these structures; he designates (Lehrbuch, 1907) as *syncytia,* "deeply staining nucleated masses of protoplasm formed by the fusion of originally separate cells; *plasmodia,* on the other hand, arise by repeated nuclear division unaccompanied by corresponding cell division. . . . Syncytia and plasmodia are always living and active formations, endowed with especially energetic metabolism, together with histolytic or phagocytic properties, and also with the power of amœboid movement. . . . They may subsequently split again into separate cell territories. . . . Quite different are the deeply staining nucleated masses produced by the confusion of originally distinct cell boundaries and by aggregation, *but which show unmistakable signs of commencing degeneration.*" Such masses are termed *symplasmata.*

Syncytia and plasmodia are chiefly formed by fetal tissues, namely, by the chorionic ectoderm; symplasmata, on the contrary, arise from the maternal tissues. Yet, for a precise definition of the structure, mention should be made of its origin; so we speak of a syncytium fetale epitheliale, of a symplasma maternum conjunctivum, etc. If the masses in question remain relatively small they are known as *multinuclear giant cells* or simply as giant cells; the above classification is applicable to these also. *Mononuclear giant cells,* which, however, never reach a special development in the human placenta, are merely greatly enlarged cells, usually derived from the fetal epithelium.

While extensive histological modifications may affect almost all the constituents of the maternal mucous membrane and find expression there in the formation of the decidua mentioned above, these modifications affect only the chorionic epithelium among the fetal tissues, the chorionic connective tissue and vessels showing great uniformity of condition. The chorionic epithelium has been termed the *trophoblast* by Hubrecht; this distinguishes the ectoderm of the chorion from that of the embryo and that of the amnion. In the region of all placentæ belonging to the higher types it shows, at least in parts, active proliferation phenomena. Where it comes into relation with the maternal tissues it usually becomes transformed at its surface into a syncytium (according to Hubrecht's terminology, a plasmodium), and this portion has been termed the *plasmoditrophoblast* (Vernhout, the *plasmodiblast* of Van Beneden), now more properly the *syncytiotrophoblast;* while those portions in which the cell boundaries are still retained form the *cytotrophoblast* (the *cytoblast of* Van Beneden).

The trophoblast in Hubrecht's sense is a morphological concept, based upon the views of that author as to the phylogenesis of the Mammalia; it occurs in all of this group and covers the entire ovum: it may also enter into entirely passive relations with the maternal mucous membrane. The term is not used in Hubrecht's sense when it is applied to the proliferating trophoblast, as frequently happens in the literature.[8] This proliferating portion of the trophoblast, which is provided with histolytic properties and especially makes possible the formation of placentæ of the higher types, is quite different from the portion known as the inactive trophoblast, and has been termed by Minot the trophoderm. Only in man (and the anthropoid apes) do the two ideas coincide, since in these cases the entire trophoblast undergoes lively proliferation and is, therefore, converted into trophoderm.

Finally, as regards the position of the ovum in the uterus, different types are recognizable (Bonnet, 1903). The union of the ovum with the mucous membrane is known as the *implantation* or *nidation.* If the ovum remains in the main cavity of the uterus, the implantation is termed a *central* one. This is the most frequent type (*Adeciduata, Carnivores,* the rabbit, the lower apes, etc.). If, however, the ovum becomes implanted in a furrow or diverticulum of the uterus and subsequently is shut off from the uterine lumen by a fusion of the lips of the furrow or diverticulum, then the implantation is of the *excentric* type (hedgehog, mouse). Finally, if the ovum penetrates into the mucous membrane by producing a destruction of the uterine epithelium and develops in the mucous membrane after the closure of the point of entrance, that is to say, outside the cavity of the uterus, as in the guinea-pig and in the rodent *Geomys,* then the implantation is of the *interstitial* type. In man the occurrence of this last type has now been almost certainly proved.

In the last two types of implantation the ovum is separated from the uterine cavity by a layer of maternal tissue, the *decidua capsularis.* It arises in the first case by a fusion of the margins

---

[8] Hubrecht, however, in his earlier works (Placentation of the Hedgehog, 1890) employed the expression to denote only the proliferating chorionic ectoderm. Compare Hubrecht, Science, 1904, and foot-note 2.

of the walls of the furrow or of the lips of the diverticulum; in the second case, by the fusion of the lips of the implantation cavity; and, in later stages, when the ovum bulges out toward the lumen of the uterus, it covers like a shell the part of the ovum turned away from the placenta.

II. MENSTRUATION.

Menstruation, which occurs at regular periodic intervals in man and the apes, is the expression of changes in the uterine mucous membrane which are associated with preparations for the reception of a fertilized ovum. A consideration of it is therefore necessary as an introduction to an account of placentation.

The mucous membrane of the corpus uteri has, in general, a very simple structure. A single-layered, cylindrical or cubical surface-epithelium, with varying amounts of ciliation (Mandl, 1908), simple or sparingly branched tubular glands varying considerably in number in different individuals (Hitschmann and Adler), a stroma with fine connective-tissue fibrils which are difficult to demonstrate by ordinary histological methods (Bjorkenheim, Hitschmann, and Adler), and, finally, the entire absence of a submucosa—these are its most important characteristics. The ends of the glands frequently penetrate to between the irregularly defined innermost layers of the muscularis and so obtain for the mucous membrane a firm adhesion to the muscularis and a well-protected position for their basal portions, a circumstance of considerable importance both *intra* and *post partum.*

Hitschmann and Adler[9] have shown by their comprehensive, recently published observations, upon which are based the statements that follow, that this mucous membrane is never in a completely resting condition in a fertile female. Growth and degeneration alternate regularly and form together a menstrual cycle of normally twenty-eight days. The cycle may be divided into certain more or less clearly marked periods or phases. The longest of these is the *interval* (between two menstruations) or the *intermenstrual* period, which lasts for about fourteen days, during which the mucous membrane is almost at rest and only undergoes a very gradual increase in thickness. Upon this follows, without a sharp limitation, the *premenstrual period,* which lasts about six or seven days and is characterized by intensive proliferation and swelling of the mucous membrane, finally leading to hemorrhages. These last for about three to five days, the *period of menstruation,* during which the mucous membrane again decreases in thickness and undergoes extensive degeneration. In the remaining period of the cycle, the *postmenstrual period,* of about four or six days duration, the mucous membrane is regenerated.

---

[9] These authors cite the literature of the question.

The mucous membrane during the interval is in the condition usually described as normal (Fig. 80). The mucosa is, on the average, about 2 mm. thick; in the fresh condition it is grayish red

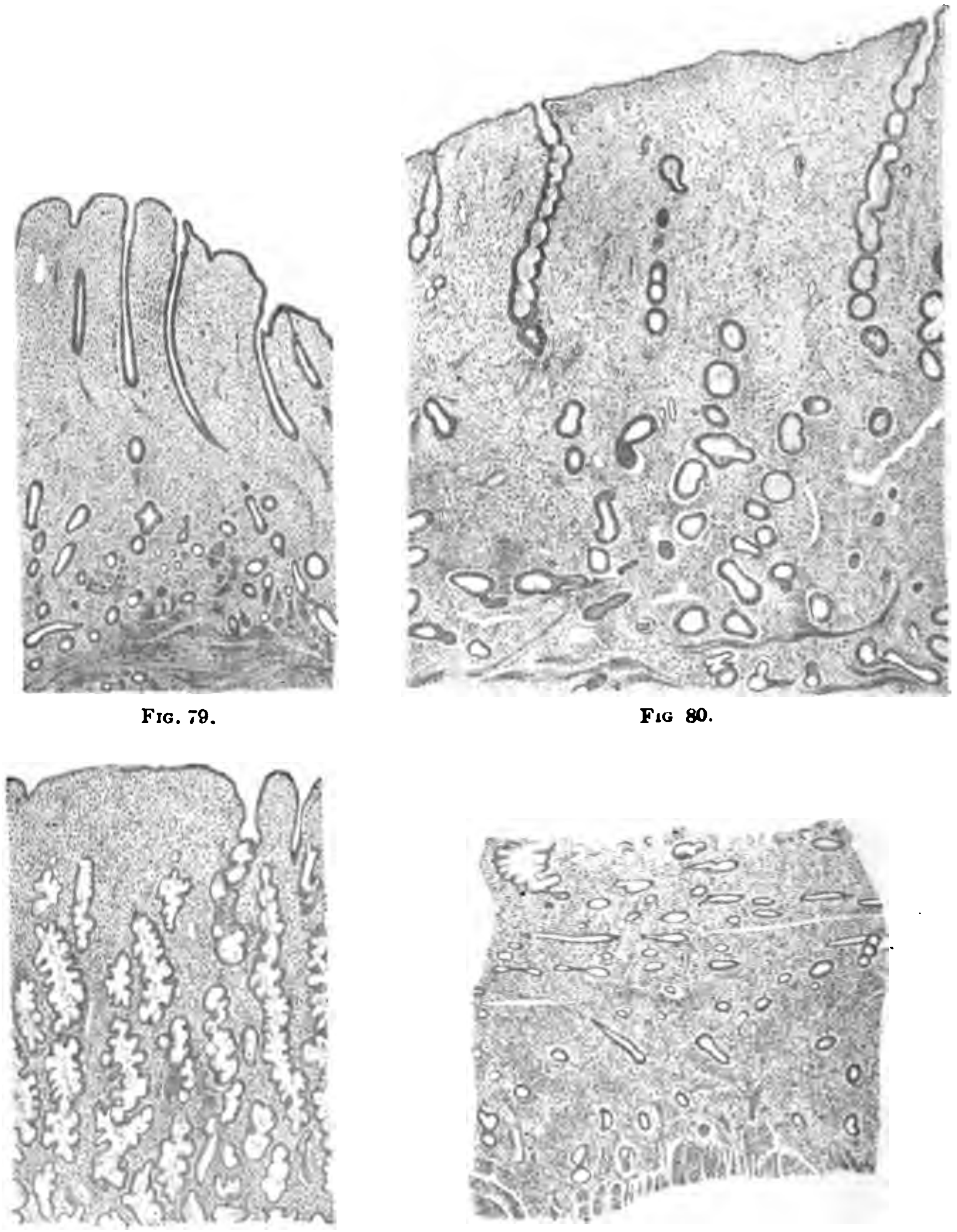

FIG. 79. FIG 80.

FIG. 81. FIG. 82.

FIGS. 79–82.—Figures of the uterine mucous membrane in the various phases. Fig. 79. Postmenstrual mucous membrane, one day after menstruation. Fig. 80. The condition during the interval. Fig. 81. Premenstrual condition. Fig. 82. Condition on the third day of menstruation, showing separation of the superficial layer. (After Hitschmann and Adler.)

and rather smooth. The glands have a slightly spiral course and, for the most part, are directed obliquely to the surface, their lower ends being, as a rule, bent upon themselves. Their lumina are circular in transverse section and at first empty. The gland cells are at first small with closely-set nuclei; but in the second half of the period they become enlarged, their plasma becoming homogeneous and acidophilous. The stroma cells (Fig. 89) are fusiform or stellate, with large nuclei, richly provided with chromatin, and possess but little plasma, so that the tissue resembles adenoid or embryonic connective tissue. Lymphocytes and small lymph-nodes occur in it.

Fig. 83.

Fig. 84.

Fig. 85

Fig. 86.

Fig. 87.

Figs. 83–87.—The form of the glands in the different phases of menstruation under the same magnification. Fig. 83. A postmenstrual gland, small and elongated. Fig. 84. A gland from the interval period, spirally coiled and enlarged. Fig. 85. A premenstrual gland, wide, with secondary alveoli and in secretion. Fig. 86. Glands at the third day of the menstrual period, one still of the premenstrual type, the other contracted and degenerating. Fig. 87. Gland from a young decidua, wide, with secondary alveoli and in secretion. (After Hitschmann and Adler.)

Already toward the close of the interval the gland cells begin to produce secretion granules (Fig. 84), which are also expelled into the lumina of the glands; and the stroma begins to show a diminution in compactness and some œdematous infiltration.

In the premenstrual stage (Fig. 81) the mucous membrane rapidly thickens to two or three times its previous thickness. This depends partly upon an increase of the œdema, and partly upon an enlargement of the individual elements. This shows itself in the gland cells (Fig. 85) by a swelling of the nuclei and of the plasma and by abundant secretion, which produces a frayed appearance on the inner surfaces of the cells; the secretion, which is also to be found in the lumen of the uterus, is now clearly recognizable histologically as a mucous secretion and contains flakes of the older, still acidophilous secretion. The enlargement of the cells produces, on the one hand, a formation of folds and outpouchings of the walls of the glands, the stroma projecting like papillæ into the folds of the mucous membrane; on the other hand, in conjunction with the secretion, a great enlargement of the lumina of the glands results. In consequence, the walls of neighboring glands are brought nearer together, the stroma being compressed between them; and an appearance as if there was an increase in the number of the glands is produced. The glandular changes are most striking in the deepest layer of the mucous membrane; in the superficial layer the stroma cells enlarge (Fig. 90) and become roundish or polygonal with a clear, feebly staining plasma and large, also feebly staining nuclei; they represent a *preliminary stage of decidual cells* (Fig. 91). By the localization of the glandular changes, on the one hand, and those of the stroma

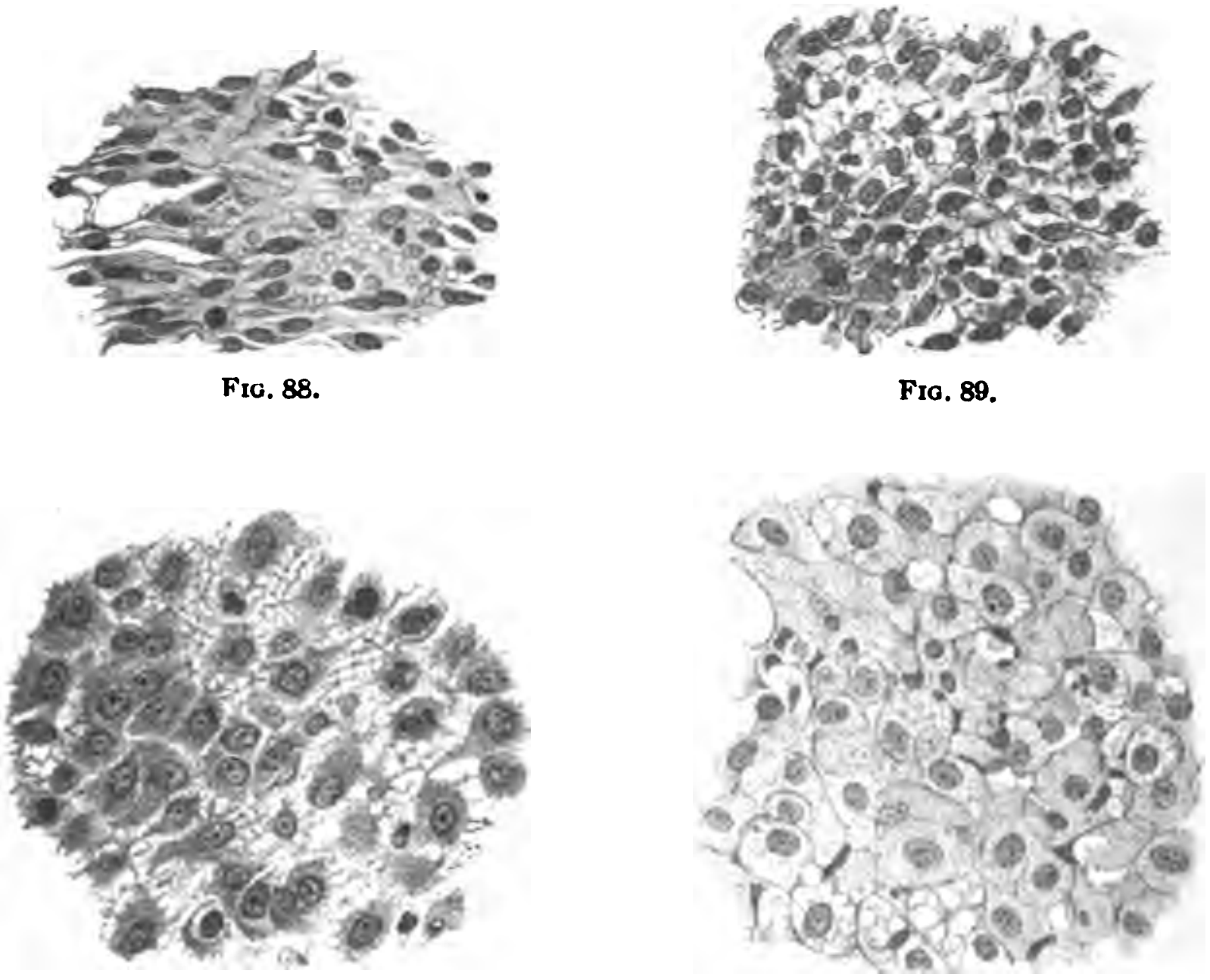

Fig. 88. Fig. 89.

Fig. 90. Fig. 91.

Figs. 88–91.—The cyclic changes of the stroma cells of the uterine mucosa. Fig. 88. Postmenstrual condition. Fig. 89. The condition occurring in the interval. Fig. 90. Premenstrual condition (five to six days before the menstruation). Fig. 91. Condition immediately before menstruation. (After Hitschmann and Adler.)

cells, on the other, the mucosa is differentiated into two layers, which, as in the case of the mucous membrane of the gravid uterus, are designated, the deep one as the *spongy* and the superficial one as the *compact* layer (compare also Fig. 92). The former acquires a spongy consistency as the result of the great enlargement of the glands, and the latter is characterized by the closely packed, decidua-like stroma cells and the straighter course of the glands.

FIG. 92.—The uterine mucous membrane in the first day of menstruation. *Bl.*, hemorrhage into the compacta; *Co.*, compacta; *H.*, hæmatoma under the epithelium; *M.*, muscularis; *Po.*, gland of the postmenstrual type; *Pr.*, gland of the premenstrual type; *Sp.*, spongiosa. (From Hitschmann and Adler.)

Toward the end of the premenstrual phase there occurs an engorgement and dilatation of the blood-vessels; and the mucous membrane, which at first was pale, becomes bright red in color.

Small hemorrhages occur at the same time; these become confluent and destroy the continuity of the tissue, subepithelial hæmatomata are formed, portions of the epithelium are torn away, blood makes its way to the surface of the mucous membrane, and the actual menstruation begins.

With the onset of this there is an effusion of blood and of the œdema fluid, on the one hand, and an expulsion of the glandular secretion, on the other, whereby a rapid shrinkage of the mucous membrane occurs. Frequently, but not always, there is also a desquamation of the glandular epithelium. The outpouchings of the glands rapidly disappear and these assume an almost straight form with narrow or collapsed lumina (Figs. 82, 86, and 92); the emptied cells become low and small. Of the stroma cells those that have been most profoundly altered break down and are expelled or carried away by leucocytes; the rest again diminish in size. The surface epithelium may be for the most part retained, or, even in normal menstruation, may be expelled together with the greater part of the compact layer (Fig. 82), painful contractions of the musculature aiding in the separation of this rigid swollen layer; yet the epithelium is in all cases regenerated before the close of the menstruation.

In the postmenstrual stage the mucous membrane is thin, with almost straight glands (Fig. 83) and long, narrow, fusiform, closely packed stroma cells (Fig. 88); little remains of the hemorrhages, and even these remnants quickly disappear. After a few days the glands again become larger and begin to assume a wavy outline, the stroma cells become more succulent, and the mucous membrane returns to the relatively quiescent stage of the interval; nevertheless, in the first half of the interval numerous mitoses are to be found in the glandular epithelium.

The similarity of the premenstrual mucous membrane to that of the decidua indicates that the premenstrual changes (the loosening up of the tissue, enlargement, increased glandular activity, swelling of the stroma cells, formation of two layers in the mucosa) are a ripening process, a preparation for the reception of a fertilized ovum, and that they are physiologically the most important part of the entire cycle, while menstruation itself is only a secondary process, a degeneration of the mucous membrane, which from a failure of pregnancy has not been able to fulfil its purpose.

As to the relation of menstruation to "heat" of animals, as well as concerning the question of the occurrence of regular cyclical changes in the genital mucous membranes, see, for example, W. Heape: "The Sexual Season of Mammals and the Relation of the 'Procœstrum' to Menstruation," Quart. Journ. Micr. Science, vol. xliv, 1906; M. Van Herwerden: "Bydrage tot de Kennis van den menstrueelen Cyclus, Tijdschr. Nederlandsche Dierkundige Vereeniging, Deel, x. 1906; and the auto-abstract of the author: "Beitrag zur Kenntnis des menstruellen Zyklus," Monatsschrift für Geburtshilfe und Gynäkologie, vol. xxiv, 1906.

Bryce and Teacher (1908) lay special weight upon the possibility of an implantation in any portion of the intermenstrual cycle (compare Sect. III), and so reach the conclusion that the "menstrual decidua" is not a preparation for the reception of an ovum and that menstruation cannot be regarded as "the abortion of an unfertilized ovum." The object of menstruation is merely to maintain the endometrium at all times ready for the formation of a decidua; the premenstrual tumidity and decidua are by chance similar, but actually are merely degenerative phenomena of an over-ripe mucous membrane. Both periods, the menstrual and the premenstrual taken together, are compared by these authors, in agreement with Heape, to the phase of animal "heat" that the latter author has termed the "procestrum." During this the vulva is swollen and red, blood and mucus exude from the vagina, but the animal is not capable of conception. The time for conception, the "œstrus," corresponds to the postmenstrual period, with its somewhat increased libido, observable also in the human species; while the interval is equivalent to the resting stage in animals, the "metœstrum." This view of the matter is difficult to reconcile with the histological phenomena of menstruation; see also later, Section III.

III. OBSERVATIONS ON YOUNG OVA.

(*Implantation, the Embryotrophic Phase of Placentation, and Transition Stages.*)

Ova which, indeed, do not directly reveal the processes of implantation, but are young enough to permit definite conclusions concerning it, are that of Bryce and Teacher (1908) and then that of Peters (1899) and that of Leopold (1906). These preparations show, on the one hand, the so-called implantation opening,[10] and, on the other, the extensive proliferation of the chorionic ectoderm or trophoblast which precedes the development of true chorionic villi containing mesoderm. They do not suffice, however, for a certain solution of all the questions which suggest themselves.[11] Thus confirmation, based upon the study of older ova, is much needed of the views regarding the mode of development of the extensive intervillous space and of the formation of a double-layered epithelium on the villi. Of modern, well-described preparations the thoroughly studied and very beautiful ovum of Jung

---

[10] The implantation opening is also evident in some older ova (Graf Spee, Beneke); in others, some of which are very young (such as that of Jung), it is no longer so.

[11] The ovum of Leopold is undoubtedly extensively altered, so that while it is of value for the confirmation of ideas derived from other ova, it is in itself of little significance; the Peters ovum, whose discovery has effected a revolution in our ideas of placentation, and the more recent ovum of Bryce and Teacher are the most important sources of our information concerning the beginning of human development. That the ova described by older writers (Breuss, Allen Thomson, and especially the celebrated ovum of Reichert) were younger, as Stratz, for example, supposes, is very improbable, since the measurements of their egg capsules were much greater. The methods by which these ova were studied were too imperfect to allow wide-reaching conclusions; and the ova themselves need not be further considered here. Furthermore, as regards the Reichert ovum, Kölliker and later Hofmeier (1896) have, on sufficient grounds, reached the conclusion that it was not normal. (See also note, p. 104.)

(1908) is the most important; then the equally well-preserved ovum of Siegenbeek van Heukelom, the first that was described under the influence of the newer ideas concerning implantation and placentation; and the preparation of Frassi (1907 and 1908), the study of which has led to conclusive information concerning many of the processes succeeding implantation. Other important objects are the young ova which Graf Spee (1905) and Beneke (1902) exhibited at Congresses, but concerning which only quite brief notices exist; and, further, the thoroughly described preparations of Friolet (1904), Rossi Doria (1905), and Cova (1907), as well as those of Pfannenstiel (1903) and Marchand (1903). A very young, but unfortunately poorly preserved, ovum is that of Stolper (1906). For a number of questions the older preparations of Merttens (1894), Graf Spee (1896), and Leopold (1897) are of interest.[12]

The preparations considered here are arranged according to their size in the appended table. Certain difficulties, however, become apparent in the arrangement, since the measurements employed by the authors are not identical.[13]

Author.	Dimensions in mm.	Remarks.
Bryce-Teacher	0.63 (×0.77)	Exclusive of epithelium (trophoblast).
Peters	1.6×0.9×0.8	Internal space of the egg capsule (exclusive of trophoblast).
Leopold	1.4×0.9×0.8	Diameter of cavity.
Stolper	2.5×2.2×1.0	Diameter of egg capsule.
Graf Spee	2.5×1.5	
Jung	2.5×2.2 (×1.1)	Exclusive of epithelium (trophoblast).
Beneke	4.2×2.2×1.2	Measurement of cavity of ovum.
Siegenbeek	5.5×4.5	Including epithelium between the bases of the villi, but excluding the villi themselves.
Rossi Doria	6 ×5	
Frassi	9.4×3.2	Diameter of the cavity.
Friolet	11–12×9	
Cova		Embryo with open auditory vesicles, anlagen of liver, hypophysis, etc.

---

[12] The number of young ova described in the literature is much greater. Of well-preserved ova there may be mentioned especially those of Eternod and Hitschmann and Lindenthal (figures of the latter in Schauta: Lehrbuch der gesamten Gynäkologie; and in the Lehrbuch by the author, already mentioned); but of these thorough descriptions have not yet been published. The numerous ova described before the publication of the works of Siegenbeek and Peters, few of which were observed *in situ*, the majority being aborted or separated from the egg capsule, are for the most part of little interest in connection with the questions under discussion here, since up to that time the problems were imperfectly understood. A mention of these ova would occupy too much space; compare the comprehensive reviews of Peters, Pfannenstiel, and Frassi.

[13] The determination of any measurements from the figures is hardly ever possible; the authors almost never state the magnification. A statement of the objective and ocular, which is generally preferred, is worthless, since for determination of the enlargement the tube length, the height of the stage, and the kind and dimensions of the drawing apparatus are also necessary.

Finally, some preparations of the attachment of the ovum in atypical situations, such as tubal and ovarian pregnancies, are of importance, since they offer opportunities for observing, as in an experiment, the development under modified external conditions and for separating fetal and maternal derivatives. To this group belong, for example, the tubal ova of Füth (1898), Pfannenstiel (1903), etc., and the ovarian ova of Freund and Thomé (1906), Busalla (1907), and Bryce, Kerr, and Teacher (1908; this also contains literature references).

A. REVIEW OF THE DESCRIPTIONS OF YOUNG OVA OBSERVED IN SITU.

The youngest known human ovum, that of Bryce and Teacher, was already imbedded in the mucous membrane. It consisted of a loose, almost spherical mass of mesoderm, averaging 0.63 mm. in diameter, with wide intercellular spaces, but no cœlom; in this mass were two small epithelial cavities (probably the medullo-amniotic and yolk-sack cavities) and it was enclosed by a thick investment of tissue, which is probably to be regarded as chorionic ectoderm only, the trophoblast shell (Fig. 93). This shell, the blastocyst wall, consists (see *Verh. Anat. Gesellsch.*, 1908) (1) of an inner lamella in which the cell outlines are not sharply defined, the nuclei are very irregular in size, and many cells show double, treble or even multiple nuclei; (2) of an extremely irregular formation which has definitely plasmodial characters. These two layers differ very markedly in the characters of the nuclei and in the staining reactions of the protoplasm, but they clearly form parts of one formation. The cellular layer we name, after Hubrecht, the cytotrophoblast, and the plasmodial layer, the plasmoditrophoblast. The cytotrophoblast is confined to the immediate wall of the blastocyst, and there is no sign of

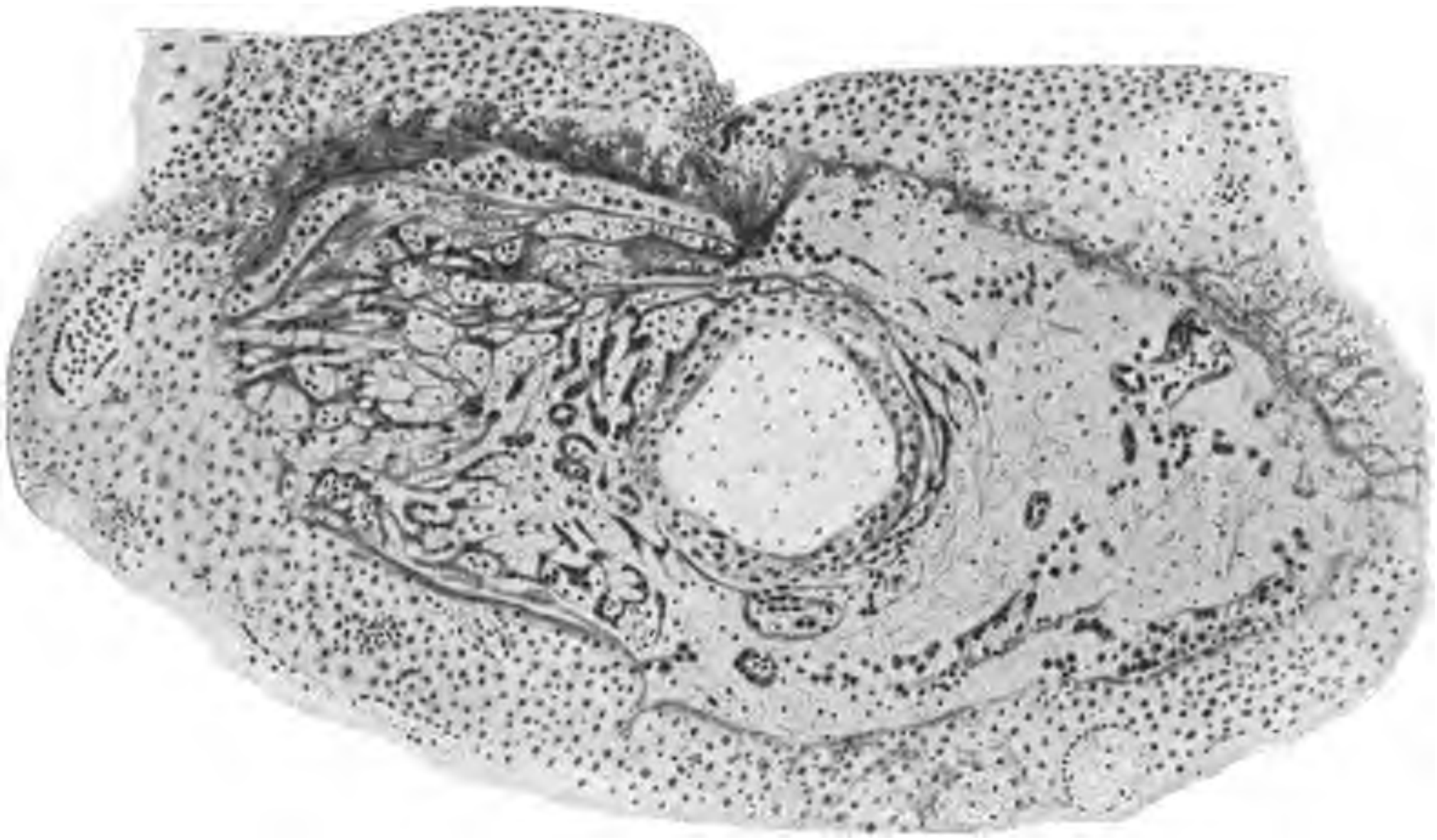

FIG. 93.—Transverse section of the Bryce-Teacher ovum (Verh. Anat. Ges., 1908) magnified 60 diameters. The section shows "the point of entrance, with a conical mass of fibrinous material below it, pointing to blastocyst; the implantation cavity is bounded by a necrotic decidua layer and is filled with maternal blood, which bathes a very extensive and irregular plasmodial formation."

protrusions of the cellular layer into the strands of the plasmodium, although at one or two points a minute bud of cytotrophoblast is seen extending outwards.

"The plasmodium[14] forms an extremely irregular network, the spaces of which are filled with maternal blood (Fig. 94). Isolated masses of the formation show all stages of vacuolation, from multiple small vacuoles to a spun-out reticular condition. This vacuolation of the plasmodium is probably produced by the secretion of a fluid containing digestive ferments, which cause coagulation necrosis followed by solution of the decidua, thus leading to enlargement of the implantation cavity. As the vacuoles enlarge the plasmodium is reduced to fine strands, and when these break through, the maternal blood takes the place of the secretion in the spaces of the mesh-work."

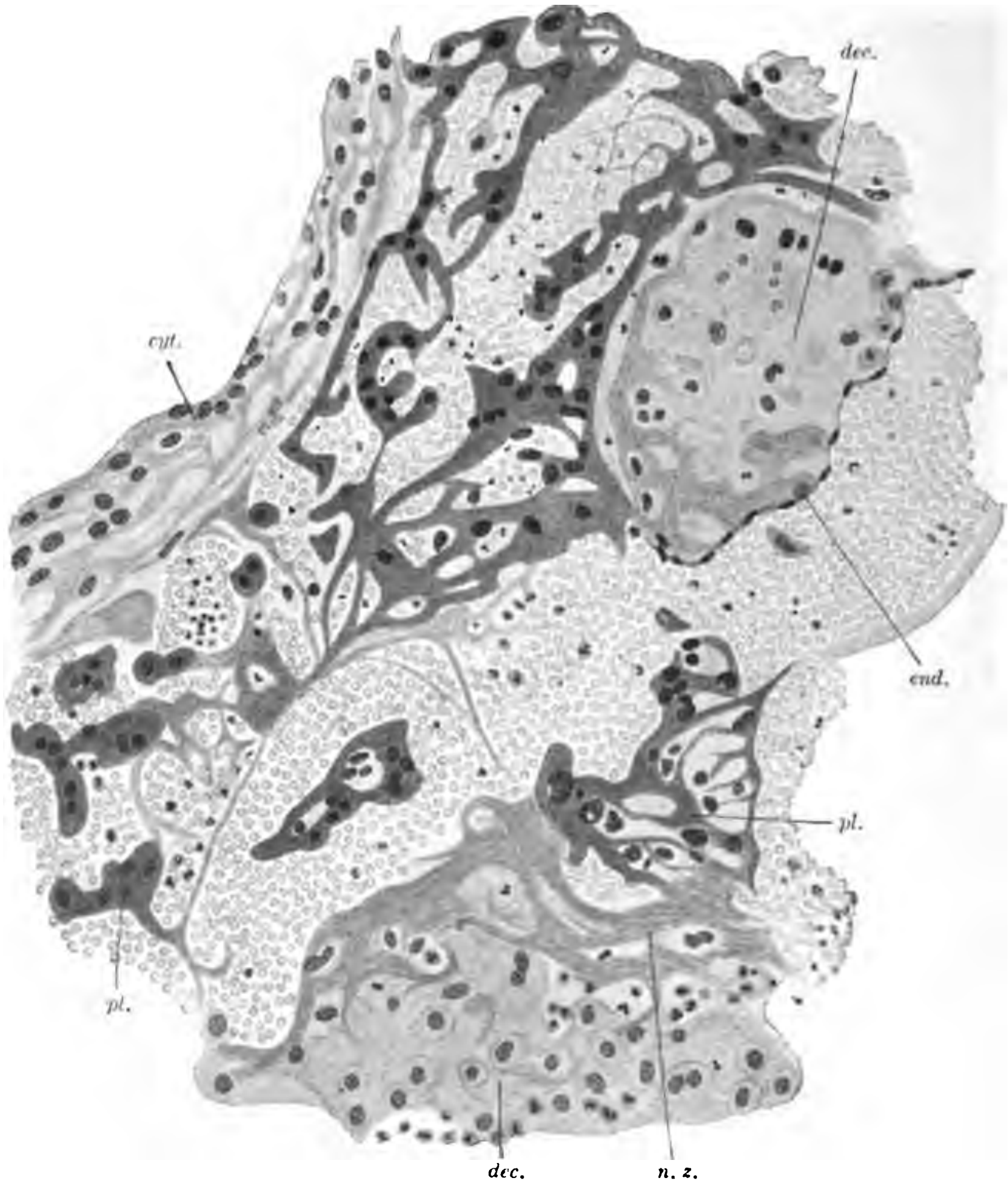

FIG. 94.—Blastocyst wall with cytotrophoblast and syncytium, decidua, and opening of a dilated sinus-like capillary in the implantation cavity. *cyt.*, cytotrophoblast; *dec.*, decidua; *end.*, endothelium of a maternal capillary; *n. z.*, necrotic zone of the decidua; *pl.*, plasmodium (syncytium). × 250. (From Bryce-Teacher, Plate V.)

The oval cavity of the decidua, in which the ovum lay, had diameters of

---

[14] Corresponds to the syncytium of Bonnet (p. 95), since it contains no nuclear divisions.

1.9 × 0.95 × 1.1 mm. A small opening, closed by fibrin, and about 0.1 mm. in diameter, placed the cavity in communication with the lumen of the uterus; the opening was not covered by a blood-clot. The wall of the implantation cavity, except at points where maternal vessels opened into the cavity, was formed of necrotic decidua and fibrin deposits. Only at individual points did the plasmodium quite reach the wall. The glands were enlarged and filled with blood, their epithelium having separated; and the greatly dilated vessels form, especially beneath the ovum, a regular cushion. The decidua is traversed by numerous leucocytes, and all the portions of the uterine mucous membrane that were examined showed decidual changes. In the necrotic decidua zone around the ovum and also lying free in the blood-containing implantation cavity was an almost continuous peripheral layer of large, mostly mono-nucleated cells (Fig. 95), which are perhaps to be regarded as degenerating decidua cells set free by the breaking up of the necrotic zone.[15]

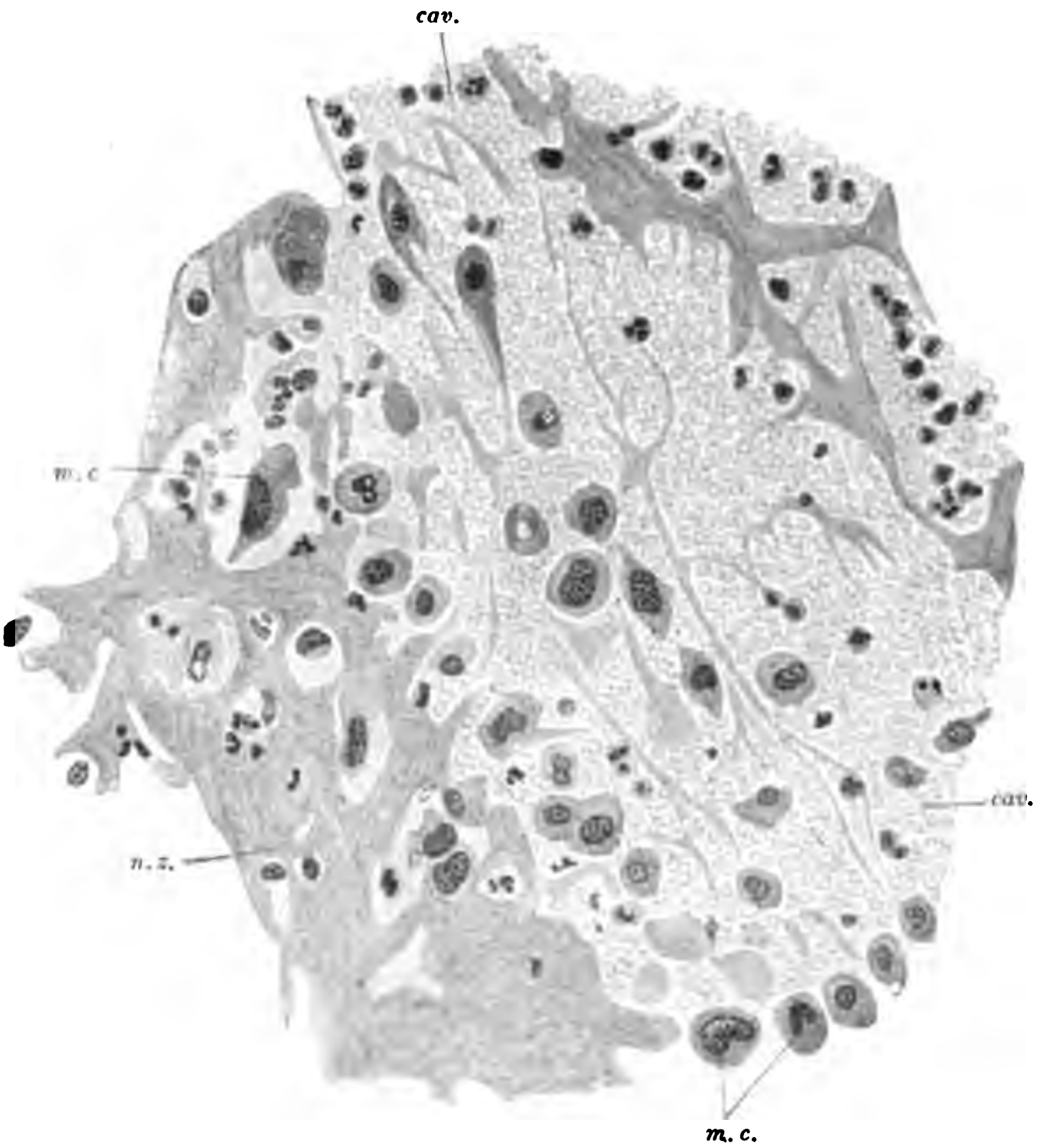

FIG. 95.—A portion of the necrotic zone of the decidua and the large cells situated on its inner surface. *n. z.*, necrotic zone of the decidua; *m. c.*, large, probably maternal, degenerating cells; *cav.*, implantation cavity filled with blood. × 350. (From Bryce-Teacher, Plate VI.)

---

[15] The comparison of these cells with a layer of fetal cells which occurs upon the surface of the placental anlage in the guinea-pig, a comparison drawn by the authors on the basis of a demonstration by Graf Spee, does not seem to be justified, since the cell layer in question (Duval's ectoplacental entoderm; see also the author's Lehrbuch) owes its existence to the greatly modified inversion of the germinal layers in the guinea-pig.

The preparation was obtained from an abortion which occurred sixteen and a half days after the only cohabitation that needs consideration and ten days after the failure of the expected menstruation. The microscopic picture is very strange and striking and cannot be compared with any stages of placenta formation known in animals;[16] it is however, as the authors state, quite reconcilable with the newer theoretical deductions concerning implantation and the commencement of the placenta formation. Among the most striking peculiarities in comparison with what is found in older preparations are: (1) the structure of the trophoblast shell; (2) the smallness of the implantation opening; (3) the necrotic character of the wall of the egg chamber and the absence of a mutual penetration of the fetal and maternal elements. Whether the preparation can be regarded as

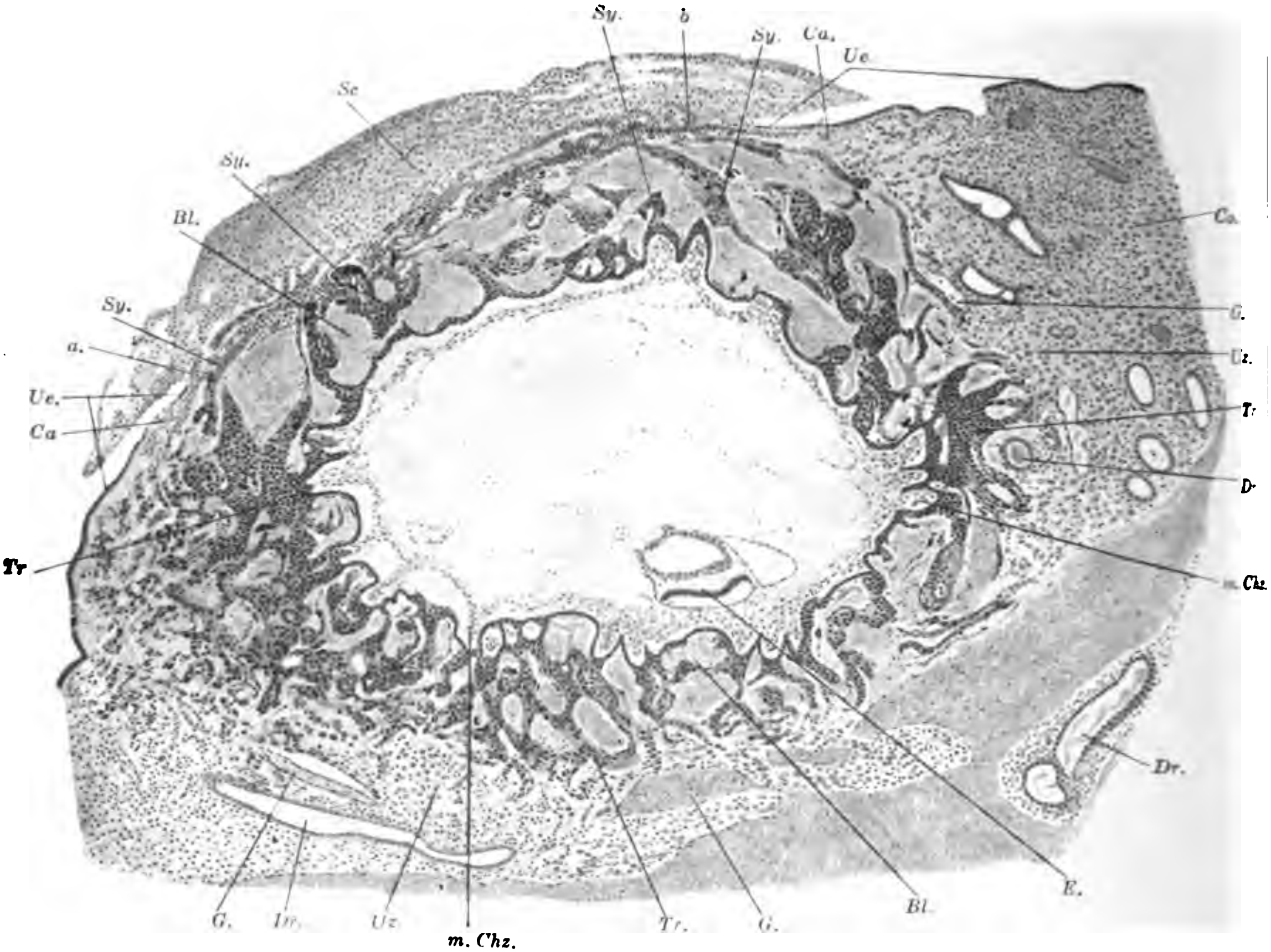

FIG. 96.—A section through the Peters ovum and the surrounding portions of the uterine mucous membrane. *Bl.*, blood lacunæ; *Ca.*, capsularis; *m. Chz.*, mesodermal axis of the first chorionic villi; *Co.*, decidua compacta; *Dr.*, glands; *E.*, embryo; *G.*, maternal vessels; *Sc.*, closing coagulum (Peters's fungoid tissue); *Sy.*, syncytium; *Tr.*, trophoblast; *Ue.*, uterine epithelium; *Uz.*, zone of enclosure. The opening in the capsularis extends from *a* to *b*. × 50. (After Peters, 1899. Compare also Fig. 97.)

---

[16] Whether the extensive syncytial formation described by Strahl (1906) in young stages of *Myrmecophaga, Dasypus, Dendrohyrax,* and *Aluata,* and by Duckworth (1907) in *Macacus,* is comparable with that in the human ovum cannot be determined, since Strahl gives no figures and those of Duckworth concern a somewhat later stage.

absolutely normal must provisionally be left undecided; it comes, on the one hand, from an abortion, and, on the other, it was preserved only after having remained for twenty hours in a mixture of urine and blood serum. Nevertheless, mitoses are still distinguishable in the cytotrophoblast cells, and the general impression furnished by the preparation, which was demonstrated at the Congress of Anatomists at Berlin, 1908, is distinctly favorable. In the absence of other equally young ova our views concerning placentation must, for the time being, be brought into harmony with this preparation.

The conditions in the Peters ovum are quite different. The cavity of the ovum contains the magma reticulare with the anlage of the embryo and the body cavities[17] (Figs. 96 and 97), and has diameters of 1.6 × 0.9 × 0.8 mm.; external to the chorionic mesoderm is a layer of closely packed cells, which is

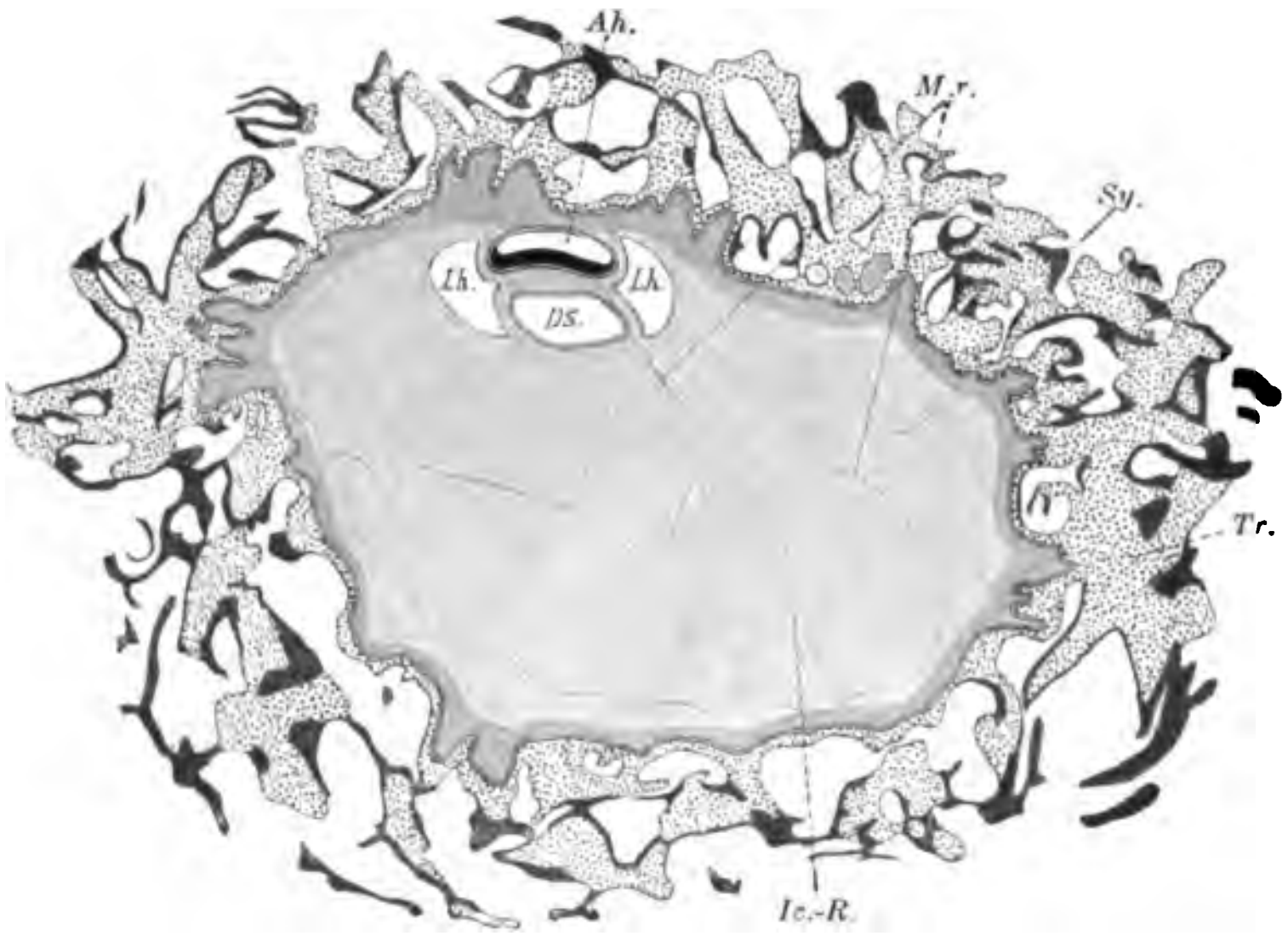

FIG. 97.—Cytotrophoblast and syncytium of the Peters ovum. The embryonic structures are shown diagrammatically. *Ah.*, amniotic cavity; *Ds.*, yolk sack; *Ic.-R.*, intercellular cavities of the mesoderm; *Lh.*, body cavities (*cf.* Grosser: Lehrbuch); *M. r.*, magma reticulare; *Sy.*, syncytium; *Tr.*, (cyto)trophoblast. (From Peters, Plate I, copied under control of the preparation itself.)

traversed by wide blood spaces and surrounds the entire ovum like a shell or mantle having a thickness of 0.5 mm. or more. Into this cell mantle, which is thicker toward the muscularis than toward the surface of the mucous membrane, there project everywhere short, stout processes of the mesoderm, the anlagen of the mesodermal axes of the villi. The cell mantle, on account of its relation to the mesoderm of the ovum, can hardly be interpreted otherwise than as the chorionic ectoderm, trophoblast, and trophoderm.[18]

Peripheral to this trophoblast shell lies a layer of tissue which Peters terms the *transition zone* and which contains, imbedded in an œdematous stroma, a confused mass of maternal, and apparently also of fetal, cells, together with a large number of free blood-corpuscles. The entire ovum, without projecting beyond the level of the mucous membrane, lies beside a fold of the membrane,

---

[17] For details concerning the formation of the body cavities of the Peters embryo consult Grosser's Lehrbuch.

[18] Compare, however, the ovum of Beneke described below, and Disse's interpretation of it.

imbedded in the decidua compacta, which over the dorsal surface, the summit of the ovum, is defective over an area of about 1 mm.; throughout this region the uterine epithelium, elsewhere well preserved, is wanting. The egg does not project through this defective area freely into the uterine lumen, but is separated from it by a fibrin clot that closes the opening in the compacta and spreads out laterally like a fungus growth (Figs. 96 and 98). This clot is termed by Peters the *fungoid tissue* or blood-fungus, and later by Bonnet the *closing coagulum.*

The decidua over the entire surface of the uterus is high and swollen, and is divided by furrows into distinct areas; its separation into compact and spongy layers is distinct only in the neighborhood of the ovum, for, although enlarged glands with epithelial papillæ occur elsewhere, yet these occupy almost the entire thickness of the mucous membrane, so that a superficial compact layer is not distinct. Typical decidua cells cannot be found, although some large cells of irregular shape and with large, deeply staining nuclei occur in the vicinity of the ovum; the significance of these is, however, obscure. The entire mucous membrane, in which very greatly enlarged blood-vessels occur, especially in the neighborhood of the ovum, shows signs of œdematous infiltration, which increases in distinctness nearer the ovum; in this region extravasated red and white blood-corpuscles also occur. A new formation of blood-vessels occurs especially in the zone of tissue which intervenes between the ovum and the uterine lumen. The glands in the neighborhood of the ovum curve around this and open near it upon the surface of the uterus; beneath the ovum are closed glandular spaces filled with blood, which show no connection with the egg capsule.

FIG. 98.—Summit of the Peters ovum. *Bl.*, blood lacunæ; *Ca.*, capsularis; *Sc.*, closing coagulum; *St.*, its stalk; *Sy.*, syncytium; *Tr.*, trophoblast; *Ue.*, uterine epithelium; *Ue. R.*, the crumpled border of this; *a.*, trophoblast nucleus in the syncytium; *b.* and *c.*, preparatory stages of the syncytium (wreath-like deposit in a blood lacuna.) (From Peters, 1899.)

A number of important points are still to be noticed concerning the trophoblast layer. The principal part of the layer consists of completely separated cells with pale protoplasm and large, deeply staining, round or oval nuclei. On account of the size and staining properties of the nuclei the entire trophoblast shell appears dark even under weak magnification. Throughout its entire extent it is traversed by blood lacunæ, some large and some small, which are continuous one with the other; these lacunæ, some of which approach so closely to the chorionic mesoderm as to be separated from it only by one or two layers of cells, are everywhere completely filled with well-preserved maternal blood. At various places they are in connection with venous vessels, which possess an endothelial wall only in the transition zone; the opening of arteries or capillaries into the lacunæ cannot be made out. "The most peripheral lacunæ are, for the most part, separated from the decidual tissue by a thin covering of ectoblast arranged in concentric layers; but in places diverging tracts of trophoblast stream out into the compacta, and the blood spaces lying between these lack the ectodermal covering on their peripheral surfaces." In the most central portions of the trophoblast cells are to be found with feebly staining and distended nuclei, with vacuoles, nuclear fragments, and flakes. More peripherally the distention and degeneration of the nuclei increases, the cell boundaries vanish, and there are formed very irregular, large, vacuolated masses of protoplasm, with numerous, irregularly contoured, and exceedingly large nuclei (Figs. 99 and 102). These masses constitute the syncytium of the Peters ovum, which is, accordingly, united by all possible transitions with the cellular trophoblast; it is never separated from this by a limiting membrane. Prickle processes cannot be seen; at most there is "a delicate and thin, strongly refractive deposit, slightly frayed at the edges, on the surface of the syncytium." The syncytium completely clothes, except at a few places, the blood lacunæ with a thin layer; indeed, according to Peters, the formation of the syncytium seems to be produced by the contact of the trophoblast with the maternal blood. Furthermore, it would seem, according to his ideas, that degenerating red and white blood-corpuscles may be "transformed" into a syncytium, which applies itself to that formed by the trophoblast, so that the blood with its own structural elements may be concerned in the formation of the syncytium (compare Fig. 98, "wreath-like

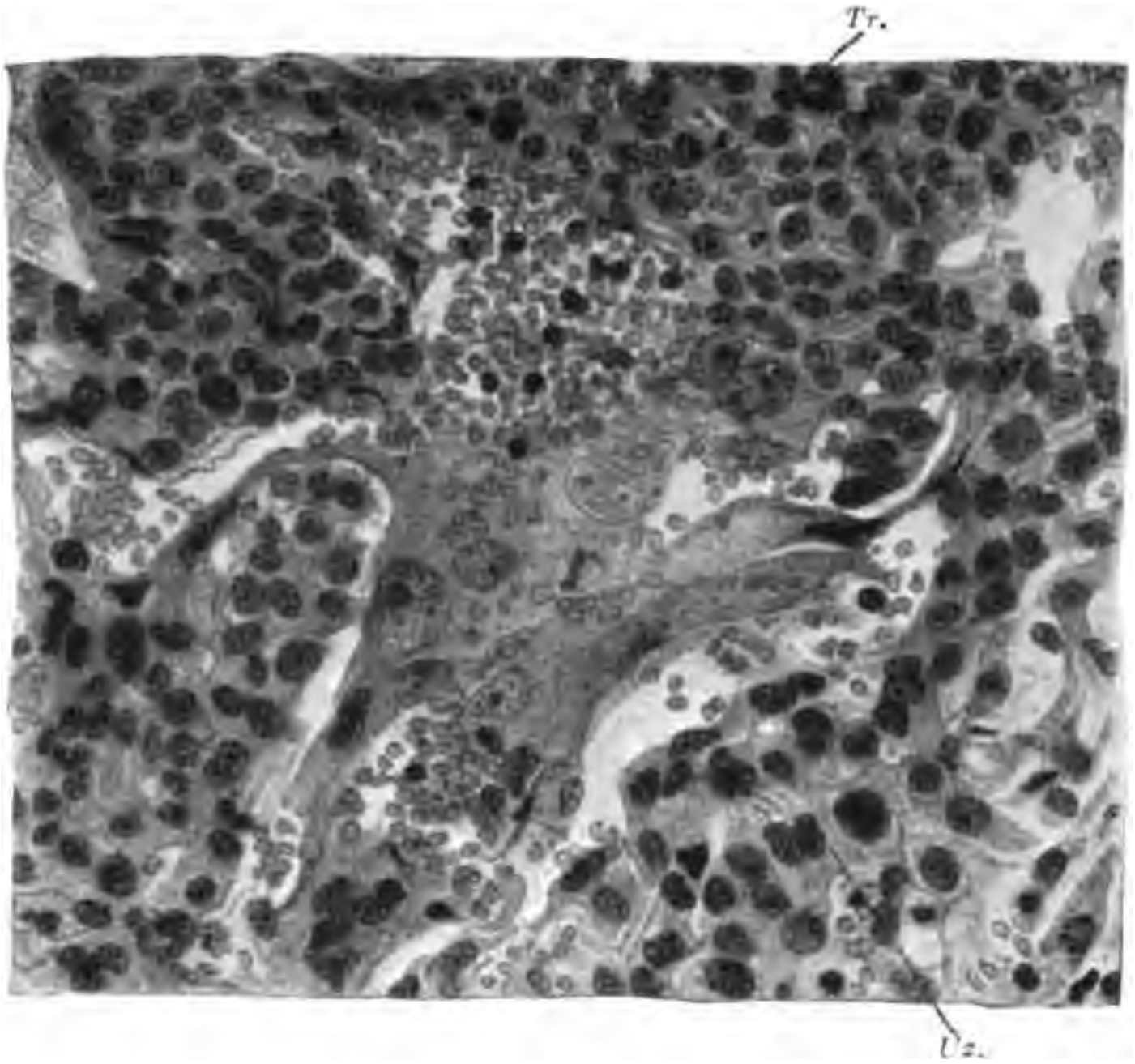

FIG. 99.—A portion of the periphery of the trophoblast shell of the Peters ovum. Degenerating patches of syncytium with greatly enlarged nuclei; the blood-corpuscles, for the most part, only resting upon the syncytium. *Tr.*, cytotrophoblast; *Us.*, enclosing zone. × 350.

deposits in the lacunæ representing preliminary stages of the syncytium").[19] The syncytium occurs, as a rule, only at regions where there is contact with the maternal blood. Trophoblast and syncytium are frequently mingled with elements of the maternal tissues in the transition zone, and, like these, undergo degeneration in that region, since free maternal and fetal nuclei can be found in it; the trophoblast and syncytium also frequently replace the wall of a gland and project into its lumen, and they may form the walls of the maternal blood-vessels in the peripheral portions of the trophoblast shell—sometimes by forming one wall of the vessel while the opposite one remains formed by normal epithelium, sometimes in that over the entire wall only the epithelium, either intact or in fragments, separates the syncytium from the cavity of the vessel (Fig. 100). A transition between the endothelium and the syncytium is never recognizable.

Peters's preparation was obtained from the uterus of a suicide, poisoned by caustic potash on the third day after the omission of a menstrual period. The mode of death may not have been without influence on the blood engorgement of the uterine mucous membrane. Peters estimates the duration of the pregnancy at from three to four days; details concerning this are given elsewhere. The preservation of the ovum (the autopsy was performed a few hours after death) with the exception of the caudal end of the embryonic anlage, was very good, even although mitoses are not recognizable in the trophoblast cells.

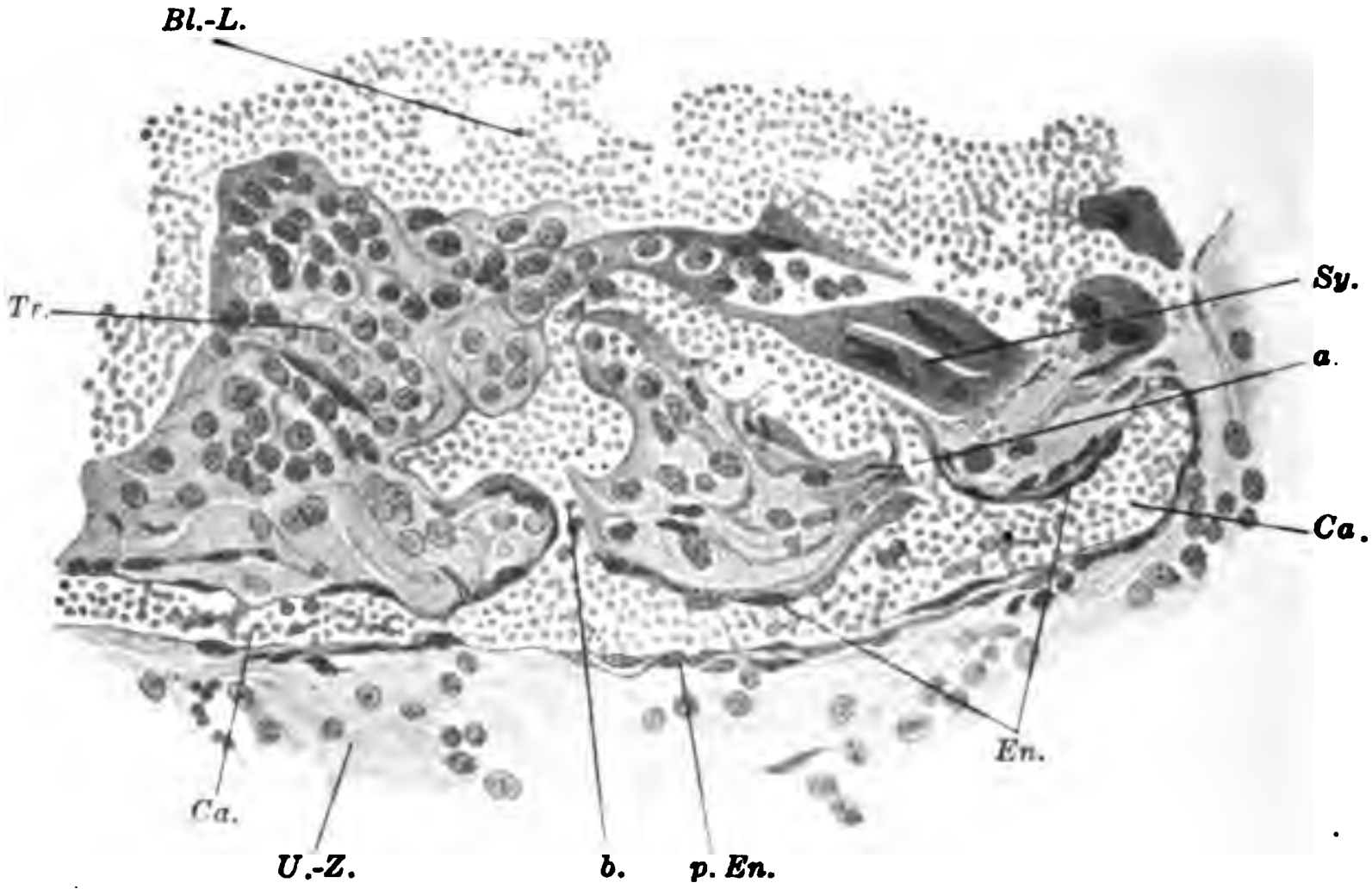

FIG. 100.—Formation of the intervillous spaces in the Peters ovum. "The capillary still possesses an epithelial wall on the side towards the trophoblast; the blood from the lacuna seems to have broken through at two places (*a* and *b*). *Tr.*, trophoblast; *U.-Z.*, enclosing zone; *Ca.*, capillary; *p. En.*, peripheral endothelium; *En.*, endothelium of trophoblastic side of capillary; *Bl.-L.*, blood lacuna; *Sy.*, syncytium." (After Peters, 1899.)

The Leopold ovum, which was obtained from a case of phosphorus poisoning, concerning which further data are not available, differs in several points from that of Peters. Thus, the trophoblast growth was less extensive; and the blood lacunæ, which were in open connection with the neighboring capillaries, were unusually wide. The trophoblast cords were, for the most part, reduced to one or two layers of cells, and were to a large extent covered by syncytium. In addition to the ovum, separated portions of the syncytium were also to be found in the decidua,

---

[19] Peters, in a private communication, now regards these and similar structures as rather the expression of embryotrophic processes.

having evidently wandered into it; but, on the whole, there was less syncytium than in the Peters ovum, and its individual parts were smaller. It was everywhere clearly distinguishable from the vascular endothelium. The contents of the trophoblast shell, the mesoderm of the ovum, were irregularly shrunken and contained maternal blood-corpuscles; an embryonic anlage could not be distinguished (it had probably been already destroyed). The internal diameters of the cavity of the ovum were 1.4 × 0.9 × 0.8 mm. This ovum was also imbedded, somewhat superficially, in the mucous membrane in the neighborhood of a furrow, but a differentiation of the mucous membrane into compacta and spongiosa was not distinct. The regions surrounding the ovum were very rich in glands, which curved around the ovum. Dorsal to the ovum the decidua, in contrast to that of the Peters ovum, is closed except for a small opening, so that a decidua capsularis is present. Extending outward from the opening upon the surface of the mucous membrane is a clot, consisting of blood and fibrin, which corresponds to the fungoid tissue or closing coagulum and is termed by Leopold the fibrin cover.

On account of the absence of the embryonic anlage the stage of development cannot be accurately determined; the measurements are not sufficient for this purpose, since, as has been pointed out, the contents of the ovum were shrunken and the blood lacunæ enormously distended. The relatively scanty growth of the trophoblast may indicate, as Bryce and Teacher remark, that the ovum was younger than that of Peters; the small size of the opening in the capsularis may also have the same significance (see below, p. 117). However, definite conclusions cannot be drawn from the preparation.

The ovum described by Stolper (1906) seems to represent a very young stage, but it had evidently died some time before its abortion. The diameters of the egg capsule (2.5 × 2.2 × 1.0 mm.) are, at all events, smaller than in the two ova to be described next, but for which the corresponding measurements are not given. The embryo was macerated. The ovum is characterized by a very extensive development of syncytium. Wide blood spaces, probably intended for a diminution of the blood pressure in the communicating vessels, are regularly arranged around the intervillous space.

The results obtained by Graf Spee (1905) from a young ovum studied by him have been stated only briefly, and until a thorough study of the ovum and figures are available, a comparison with the ova already mentioned cannot be made. The ovum was obtained from a case of oxalic acid poisoning; the mucous membrane of the uterus "showed the areas, divided by furrows, that are characteristic of pregnancy," and in one of these at a point marked by a slight depression of the surface was the ovum. "Beneath about two-thirds of the free surface of the prominent area of mucous membrane, imbedded in a cavity in the interglandular connective tissue of the uterine mucosa, was an ovum measuring 1.5 × 2.5 mm. in its greater diameters, poorly provided with villi, and with very small embryonic structures in the anterior. Between the surface of the chorion and the uterine tissue were here and there small quantities of blood from open blood-vessels. The walls of the egg chamber consist throughout of elements of the interglandular connective tissue of the uterus. The lumina of all the glands open into the uterine lumen; none into the egg chamber. The portion of the mucous membrane (serotina) intervening between the ovum and the muscularis holds a large mass of blood (just as in the ovum of Peters) contained in enormously enlarged endothelial canals and apparently stagnant even in life; it may very well have furnished nutrition to the ovum and at the same time have served as a rampart protecting the parts of the mucous membrane near the muscularis from the destructive contact action of the ovum. The walls of the egg chamber, separating the ovum from the lumen of the uterus, consisted of a thicker or thinner layer of the interglandular connective tissue next the ovum and a single-layered epithelial covering next the uterine cavity. Only in the region of the surface depression is the uterine tissue interrupted by an opening, which may be regarded as the point of entrance of the ovum into the uterine mucous membrane, the implantation opening; it is closed only by a flat expanded blood-clot (fibrin with enclosed leucocytes and red blood-corpuscles). The conditions are, accordingly, very similar to those occurring in the human ovum described by Peters.

"The implantation opening, at this stage 0.8 mm. in diameter at the most, has probably increased somewhat in size from what it was when first produced by the ovum by stretching and growth, and perhaps also by histolysis of the chamber wall, for I imagine that the ovum during the seven days which probably intervene between fertilization and implantation cannot have increased much in diameter and therefore cannot have measured much over 0.2 mm."

Among these data the most striking are the small amount of blood in the immediate neighborhood of the ovum and the small number of villi. Nothing is stated concerning the character of the chorionic epithelium, the syncytium, and the intervillous space. The ovum, nevertheless, does possess villi and in this respect is further developed than Peters's preparation. It is questionable, however, if it is to be regarded as quite normal.

The ovum described by Jung agrees excellently in its general character with that of Peters. It was obtained from a curetting, and, completely surrounded with mucous membrane, was preserved, while still fresh, in 80 per cent. alcohol. Its age was not determined.

The egg capsule was completely separated from the lumen of the uterus, but was situated somewhat superficially. The somewhat compressed but uninjured cap of the ovum was composed of coagulated blood and tufts of fibrin, together with numerous leucocytes and degenerating decidua cells, and passed gradually over into the transition zone. The diameter of this necrotic cap was 1.7 mm.; it corresponds, according to the opinion of the author, to the closing coagulum of other ova and its extent indicates that of the distended implantation opening.[30] The diameter of the ovum exclusive of the chorionic epithelium was 2.5 × 2.2 (× 1.1) mm.

The mesoderm of the chorion had already sent processes, the mesodermal axes of the villi, into the extensively developed trophoblast (Jung avoids the use of the term trophoblast and speaks only of ectoblast). The ovum was completely surrounded by rudiments of villi, all of about the same length; and on the chorion membrane and at the roots of the villi was an epithelium, consisting of two layers, a basal and a covering layer. The basal layer, composed of distinctly defined cells, passed over into stout columns of cells, which frequently united and so formed the shell around the ovum. Only occasionally did free cell-columns occur, the representatives of free villi. In the peripheral portions the individual cells were somewhat larger and clearer, but everywhere abundant mitoses could be observed and there were no signs of degeneration in the peripheral elements. Individual mitoses were so placed that one of the daughter cells passed into the covering layer, this, the syncytium, showing no mitoses although the nuclei were, for the most part, well preserved. The protoplasm of the covering layer presented, in general, a foamy structure; prickle processes projected toward the intervillous space, at least in certain places. Only at certain regions of the periphery was the covering layer, which frequently streamed into the maternal tissues, in degeneration and forming a symplasma syncytiale in Bonnet's sense, perhaps as the result of the action of maternal leucocytes. The vacuoles of the covering layer at places contained what seemed to be altered maternal blood, but everywhere

---

[30] In this case the capsularis would not actually be closed. The gradual transition of the cap into the transition zone on the lateral portions of the ovum seems to be opposed to Jung's view. It is possible that the capsularis had at one time been complete, but was again undergoing degeneration.

a continuity of the syncytium with the maternal tissues, that is to say, with endothelium, was lacking. The boundary between the maternal and fetal tissues was almost everywhere easily recognizable, with some difficulty only in the regions where symplasma structures occurred.

Between the trophoblast columns, that is to say, the anlagen of the villi, there was a very irregular intervillous space; this was abundantly filled with blood, was in continuity with the maternal vascular system by means of gaps in the sieve-like trophoblast shell, and was lined by maternal tissue (endothelium) only in the neighborhood of these gaps. The communications with the maternal vessels were always narrow and the circulation must have been very slow. In the transition zone, situated outside the trophoblast shell, degenerating maternal tissue occurred, partly associated with the formation of symplasmata, but always without signs of active proliferation; also no new formation of blood-vessels could be found. Around the ovum was a strip of fibrin of varying thickness, produced by degeneration of the maternal tissue (stroma, endothelium, gland epithelium). Leucocytes occurred abundantly in the transition zone, but not in the fetal tissues. The glands were frequently destroyed by the trophoblast, but appeared to withstand its attacks for a longer time than the rest of the decidua; none of them opened into the intervillous space, but they took a curved course around the ovum. External to the transition zone a separation of the compacta and spongiosa had taken place. The former was œdematous, beset with numerous lymphocytes, and its gland ducts were contorted; typical decidua cells and hemorrhages were wanting, although the glands frequently contained clotted blood. The representatives of the later decidua cells showed numerous mitoses. No œdema occurred in the spongiosa.

The ovum of Beneke was obtained from a curetting twenty-five days after the omission of a menstrual period and was fixed in alcohol. It contained an embryo measuring 1.86 mm. in length, and had a cavity of 4.2 × 2.2 × 1.2 mm., surrounded by a trophoblast measuring 0.4–1.0 mm. in thickness. "As regards the structure of the trophoblast the author can only confirm in general the observations of Siegenbeek, Peters, Marchand, and others.[21] The syncytial giant cells are throughout of fetal origin and symplasma formation is not recognizable. The syncytia had encroached upon the endothelium of the decidual vessels and also upon the epithelium of the glands; by the development of extensive clefts in the interior of the giant cells the intervillous blood spaces are being formed. Scattered giant cells with prickle processes occur in the chorionic connective tissues of the investment of the ovum; they wander to a certain depth into the decidual tissue, where they may be recognized by their characteristic nuclei and by containing glycogen. The decidual cells, extensively swollen, take part in the formation of the so-called transition zone to a greater extent than has been supposed by Peters, for example. The closing 'tissue plug' which fills the opening in the reflexa corresponds in general in its histological constituents, blood, fibrin, leucocytes, etc., with what Peters has described."

The measurements of Siegenbeek's ovum (4.5 × 5.5 mm.) were not made directly, since the ovum had been opened by a tear at one spot and was collapsed, but were estimated from the perimeter. It was obtained from a woman who had met an accidental death from burning; the entire uterus was preserved in formalin fourteen hours after death. The ovum was completely covered with villi, those on the basal surface being stronger than the peripheral ones, and those about the equator of the ovum the strongest of all. Free villi occurred; the majority were continued into cell columns (ectoblastic trabeculæ), which united

---

[21] Disse, who has subsequently studied the specimen, regards the entire trophoblast of the ovum as maternal tissue and also transfers this same interpretation to the Peters ovum.

together peripherally and formed an ectoblast shell traversed by large and small spaces, and varying in thickness in different regions. In general it was thicker on its peripheral than on its basal side. The ectoblast cells situated near the maternal tissue were larger than those having a more central position and frequently showed degenerating nuclei, but mitoses occurred in all portions of the ectoblast shell. The boundary between the fetal and maternal tissues was difficult to make out in certain regions. The intervillous space was formed by blood-filled lacunæ which were lined only by cellular ectoblast or by syncytium; the endothelium was also frequently wanting in the blood-vessels at their communication with the intervillous space. In the space were very many leucocytes and perhaps also special nucleated elements of the maternal blood. The syncytium was only to be found in the region of the blood paths; it showed no prickle processes and no cuticula on the side next the ectoblast. The derivation of the syncytium from maternal tissues (endothelium, epithelium, or connective tissue) was excluded, but its continuity with the cellular ectoblast could not be made out, so that the origin of the tissue could not be determined.

The ovum lay in the compacta, whose basal portion had the same structure as the capsularis (reflexa), except as regards the occurrence of glands. The capsularis, for the most part, lacked an epithelium and contained in its interior fibrin striæ. Basally there were greatly distended glands filled with blood; around the periphery of the ovum the glands were arranged concentrically, and the glandular epithelium did not form syncytia. Characteristic decidual cells were nowhere present. A sharp separation of the compacta and spongiosa had not yet occurred in the decidua vera; the compacta was œdematous.[22]

The ovum of Rossi Doria was obtained from an abortion. It was injured by a tear and does not seem to have contained an embryo. The egg membranes were rather well preserved. The theoretical considerations of the author will be discussed in note 23. Frassi's ovum was obtained from an operation fourteen days after the omission of a menstrual period; the unopened uterus was preserved in formalin. The ovum of Friolet was also obtained from an operation and fixed in the unopened uterus. Both ova already showed, for the most part, a two-layered epithelium over the villi; a criticism of the observations made upon these ova will follow in the *résumé.*

The ova of Peters, Jung, Beneke, and Siegenbeek, with their extensive development of the trophoblast, form a single harmonious group, which may be derived from conditions such as Bryce and Teacher have described. To the older stages, on the other hand, a natural and easy transition is formed by the Siegenbeek ovum.

B. RÉSUMÉ OF THE FIRST PROCESSES OF DEVELOPMENT UP TO THE FORMATION OF THE VILLI AND THE APPEARANCE OF THE INTERVILLOUS SPACE.

From the foregoing the course of the first stages of development may, with a good deal of certainty, be concluded. Especially is this so with regard to the implantation of the ovum. Of the types of implantation mentioned in the introduction the interstitial is the only one that concerns us here; as in the guinea-pig, so in the human species, the ovum penetrates like a parasite, through an opening that it forms for itself, into the mucosa and

---

[22] The ovum has more recently been studied by Veit (1905); the author has not been able to accept the idea of an active penetration of the ectoderm into the maternal tissues.

develops there (Berry Hart, Graf Spee, Von Herff, Peters[23]). It must at this time be very small, since otherwise such a penetration of the entire ovum could not be readily understood. The opening in the surface of the mucous membrane had a diameter of 0.1 mm. in the Bryce-Teacher ovum, in that of Leopold its margins were in contact, in that of Peters its diameter was 1 mm., and in that of Graf Spee 0.8 mm. It is probably enlarged very quickly by the growth of the ovum, and the diameter of the ovum at the time of implantation is probably about 0.2 mm. (Graf Spee). The formation of the mesoderm cannot have begun, and it is questionable if at this time even the cavities of the ovum (the blastocœl, medullo-amniotic cavity, cavity of the yolk sack) have appeared. The ovum of the guinea-pig forms at the moment of implantation a solid cell mass (Graf Spee). A marked growth of the ovum is dependent on favorable conditions of nutrition, and these are furnished only after implantation. The ovum does not undergo implantation in a furrow,[24] but at any portion of the smooth mucous membrane where perhaps a special thickening or an extravasation of blood, which may serve as an embryotrophe, facilitates implantation. The spot is usually on either the anterior or posterior wall of the uterus, and determines the situation of the placenta. The implantation usually occurs between two glands, and the glands are later forced apart by the growth of the penetrated ovum, so that they bend around it in curves. Implantation in a gland is not probable, since the diameter of the ovum is always greater than that of the lumen of a gland. During the implantation the superficial epithelium and connective tissue are dissolved and probably serve the ovum as embryotrophe; the solution of the maternal tissues may perhaps be produced by the action of ferments secreted by the ovum, and to this Bryce and Teacher refer the vacuolation of the syncytium seen in young stages. The penetration of the ovum is not determined by gravity, since the minuteness of the ovum places this out of the question and, furthermore, the implantation takes place just as often contrary to the

---

[23] Rossi Doria believes in a kind of combination of penetration and circumvallation, since the ovum observed by him projected, for the most part, beyond the level of the mucous membrane. The ovum was, however, much too old to settle the question. He had to do, apparently, with a superficially implanted ovum.

[24] The mucous membrane of the non-gravid uterus never shows, even at the greatest development of the premenstrual swelling, a formation of furrows and elevations (compare Hitschmann and Adler); consequently the idea, frequently expressed, that the implantation takes place in a furrow, as in the hedgehog, fails. The formation of furrows is actually a symptom of pregnancy (Graf Spee) and as such may direct the attention to the possibility of a young pregnancy in autopsies, at a time when the ovum itself can scarcely be recognized. The furrows are not preformed, but are produced as foldings of the continually thickening mucous membrane.

direction of gravity as in accordance with it on either of the opposite walls of the uterus. Nor can the action of an internal pressure by the uterus (Pfannenstiel) be assumed, since the ovum floats in a quantity of detritus which it produces and which cannot flow away on account of the swelling of the mucous membrane, but is rather increased in quantity by the flow of additional material from neighboring tissue spaces. There remains then only the supposition of an active penetration on the part of the ovum which may be due to an amœboid activity of the superficial cell layers of the trophoblast (Peters), in favor of which evidence has been obtained within recent times. Indications of an active penetration by the ovum have also been furnished by young tubal pregnancies (Füth, Aschoff, and others), in which the ovum has completely destroyed the thin mucous membrane and has penetrated into the muscularis. The fact that the tube is open at one extremity is ample evidence of the non-existence of an internal pressure which could force the ovum into the muscularis. The duration of the implantation process, which in the guinea-pig is about eight hours, may be estimated at about one day in man (Graf Spee).

As to the behavior of the ovum before implantation we rely solely on conjecture based on a comparison of what occurs in animals. The fertilization of the ovum set free from its follicle probably takes place, as a rule, in the pars ampullaris tubæ, to which the spermatozoa penetrate and where they may remain capable of fertilization for days or perhaps for weeks (see, for example, His: "Anatomie menschlicher Embryonen," vol. ii). The fertilized ovum then wanders down the tube and through the uterus until it reaches the place of implantation; this movement is a passive one on the part of the ovum, being caused by the action of the cilia of the surface of the tube and uterus. During this time the ovum loses its corona radiata[25] and zona pellucida, and passes through the first stages of development, that is to say, the segmentation; it obtains the necessary oxygen from the serum which moistens the mucous membrane and perhaps employs the secretions of the membrane as embryotrophe (p. 119). The passage through the tube to the implantation region is by no means rapid; even in the white mouse, where the distance to be traversed is very short, it occupies five or six days (Sobotta, Melissenos), in the guinea-pig seven days (Graf Spee), and in larger animals, such as the cat, dog, pig, and sheep, from eight to ten days (Bonnet). Taking into account the length of the human tube, the assumption that the wandering of the human ovum occupies eight or ten days is quite reasonable, notwithstanding that the human ovum is relatively small and the rapidity of the wandering increases, in general,

---

[25] The theory of Hofmeier that the corona radiata is retained and becomes transformed into the syncytium is of only historical interest.

with the smallness of the ovum (Minot places the wandering period at eight days, Graf Spee at seven days, Pfannenstiel at from five to seven days, and Bryce and Teacher at seven days).

Of the various phases of the menstrual cycle, the premenstrual is the most important for implantation; at least so the study of the phenomena of menstruation seems to indicate. The premenstrual loosening of the tissues would favor the penetration of the ovum, the secretion of the glands would serve as embryotrophe until the completion of implantation, and the mucous membrane of the uterus in the cases of Peters, Leopold, Jung, and Siegenbeek resembles much more a premenstrual membrane than a decidua. The connective-tissue cells are, in Peters's case, for example, less plainly altered toward the decidual condition than they are normally immediately before the appearance of the menses, and this even although the time of menstruation was several days overdue.[26] Indeed, even in older ova, such as that of Frassi, typical decidual cells occur only in the neighborhood of the ovum; and among all the young ova a distinct decidual alteration is to be found only in that of Bryce and Teacher. We must assume that the implantation exercises an inhibiting effect on the premenstrual changes, for otherwise menstruation would not be omitted during pregnancy; and the delaying of the decidual changes in the uterine connective tissue may be regarded as the visible expression of this inhibition. Yet a certain amount of time must be granted the ovum for the development of this inhibitory action; an ovum implanted immediately before menstruation may well be sacrificed to this process; and such menstruations would then perhaps be abundant in quantity. Normally (typically) therefore the implantation must take place several days before the time for the appearance of the menses, but whether two or five days previously cannot at present be determined. Perhaps two days is too short an interval to allow the inhibitory action to become efficient.

If the times required for the passage through the tube, the implantation, and the inhibition of menstruation be added together, it follows that the expulsion of the ovum from its follicle and its fertilization must normally occur at a minimum of about from eleven to fourteen days before the date of the expected menstruation. But this entire interval has been almost always neglected in gynæcological literature, in accordance with the tables established by His, and the age of the ovum has been determined from the

---

[26] The decidual cells are in any event to be derived from the stroma cells of the uterine mucous membrane, and the various older theories (derivation from perivascular cells, the now almost forgotten "perithelia," or leucocytes, etc.) are negligible. Concerning the mitoses observed by Jung in the preparatory stages of the decidual cells it is to be remarked that they furnish an explanation of the at first rapid increase of the decidua.

estimated time of appearance of the omitted menstruation. Consequently nearly always the age estimates have been too low by the amount given above. The interval between implantation and the beginning of the expected menstruation has been considered by Peters and Leopold, for instance, but they neglected the time required for the passage through the tube. If one reckons from the moment of fertilization, the Peters ovum must have been at least fourteen days old (and implanted for about five days).

Implantation may, however, be possible in other phases of the menstrual cycle than the premenstrual, and it may be that the stimulus arising from the ovum may also have the property of accelerating the occurrence of the premenstrual changes. Perhaps certain pathological phenomena may be associated with precocious implantation (see Grosser "Lehrbuch").

The view stated here is, however, scarcely in agreement with the age estimates that have so far been published of various young human ova. Bryce and Teacher, on the basis of an analysis of twelve cases, reach conclusions quite at variance with that given above,—namely, that menstruation is actually without influence on conception and implantation; that, indeed, the latter may take place on the day immediately before or after the calculated date for the first omitted menstruation; and that, accordingly, it is not the implantation that is responsible for the inhibition of the approaching menstruation, but the fertilization which has already taken place in the ampulla of the tube. These authors, however, start with the assumptions that fertilization occurs, on the average, twenty-four hours after coition, and, secondly, they base their calculations on a series of aborted ova as well as upon some others which were obtained by operative interference necessitated by pathological conditions of the uterine mucous membrane. If one considers, on the one hand, how much uncertainty exists regarding the time relations of the processes of fertilization and, on the other hand, the fact that only two cases of normal pregnancies terminated by extrinsic causes (Peters, Reichert) occur in their tables, it may seem venturesome to set aside as without significance the relationship of the premenstrual mucous membrane to the decidua, which is capable of being directly observed. Cases in which a spontaneous abortion occurred or in which there was a catarrh of the mucosa which called for curetting and which, if longer continued, would have produced a spontaneous abortion, may, indeed, be associated with an implantation in an improperly prepared mucous membrane. The occurrence of typical decidua in the Bryce-Teacher ovum is strange when compared with other results (see p. 119). But at all events these authors have rendered the service of having thrown full light upon the obscurity which prevails concerning the course of the phenomena under discussion.

The normal period of ovulation is also still quite uncertain. Ovulation may take place at any time; the prevailing view is that it coincides with menstruation[27] (see Nagel: "Handbuch der Physiologie"), while Ancel and Villemin (1907), on the ground of their observations of freshly ruptured follicles, suppose that it occurs, on the average, twelve days before the beginning of menstruation. The latter period is in excellent agreement with the view that the premenstrual phenomena are preparations for pregnancy; this can hardly be said of the former one.

The ovum ceases its penetration in the decidua compacta; the implantation opening is closed by the coagulation of the tissue fluids exuding from the mucous membrane, and the product of this coagulation is the closing coagulum (fungoid tissue, fibrin cover) which occurs in a whole series of young ova (Peters, Leopold, Beneke, Graf Spee) and, consequently, can hardly be regarded, as Pfannenstiel would wish, as an abnormal occurrence. In the Bryce-Teacher ovum the coagulum is wanting and the authors suppose that it is first formed after the ovum has increased in size and the implantation opening enlarged. The implanted ovum begins to grow rapidly and presses further into the mucous membrane, so that it divides this into a superficial and a deep layer (Fig. 101). The superficial layer becomes the covering of the ovum on the side toward the cavity of the uterus, it becomes the *decidua capsularis,*[28] which at first bears the implantation opening,

---

[27] According to Leopold and Ravano (Archiv f. Gyn., vol. lxxxiii, 1907) ovulation coincides with menstruation in about two-thirds of the observed cases, but in one-third of them it occurred quite independently of it; conception is possible at any time. The authors estimate the period of ovulation from the condition of the corpus luteum; but this estimate must necessarily be uncertain, since, in view of the uncertainty of the time of ovulation, a basis for a thorough knowledge of the time required for the development of the corpus luteum is lacking. Also the observations of H. Bab (Deutsch. med. Wochenschr., 1908) indicate that impregnation, and consequently also ovulation, takes place some days before menstruation; nevertheless, it is as yet hardly possible to draw conclusions as to the time of impregnation from the size of the embryo, as this author does. Compare, for instance, the data furnished by Bab concerning his first two cases with those given by Tandler (Anat. Anz., vol. xxxi, 1907) concerning an almost equally developed embryo. The discussion whether the ovum belongs to the first omitted (Löwenhardt-Sigismund) or the last completed menstruation, a discussion in which Bab declares himself in favor of the former idea, arises from the old notion that ovulation and menstruation, on the one hand, and fertilization and implantation, on the other, coincide. The latter coincidence has been disproved; the former is improbable, or at least requires demonstration.

[28] The decidua capsularis is the decidua reflexa of the older terminology. The latter name is an expression of the older theories (W. Hunter, Reichert) of its origin, to the effect that the mucous membrane was reflected or curved over the ovum and fused over it. Since, however, young stages are opposed to this view and older ones show no conditions that cannot be explained as well or even better as the results of interstitial implantation, this theory, which up to ten years ago was the only prevailing one, is now regarded as disposed of.

but later completely closes (see below). The deep layer, or what remains of it, forms the basis of the later placenta and is the *decidua basalis* (the decidua serotina of the older nomenclature); lateral to the ovum is the *decidua marginalis,* whose fate is of great importance for the later stages of development. The remaining mucous membrane forms the *decidua vera,* recently very appropriately termed the *decidua parietalis* by Bonnet.

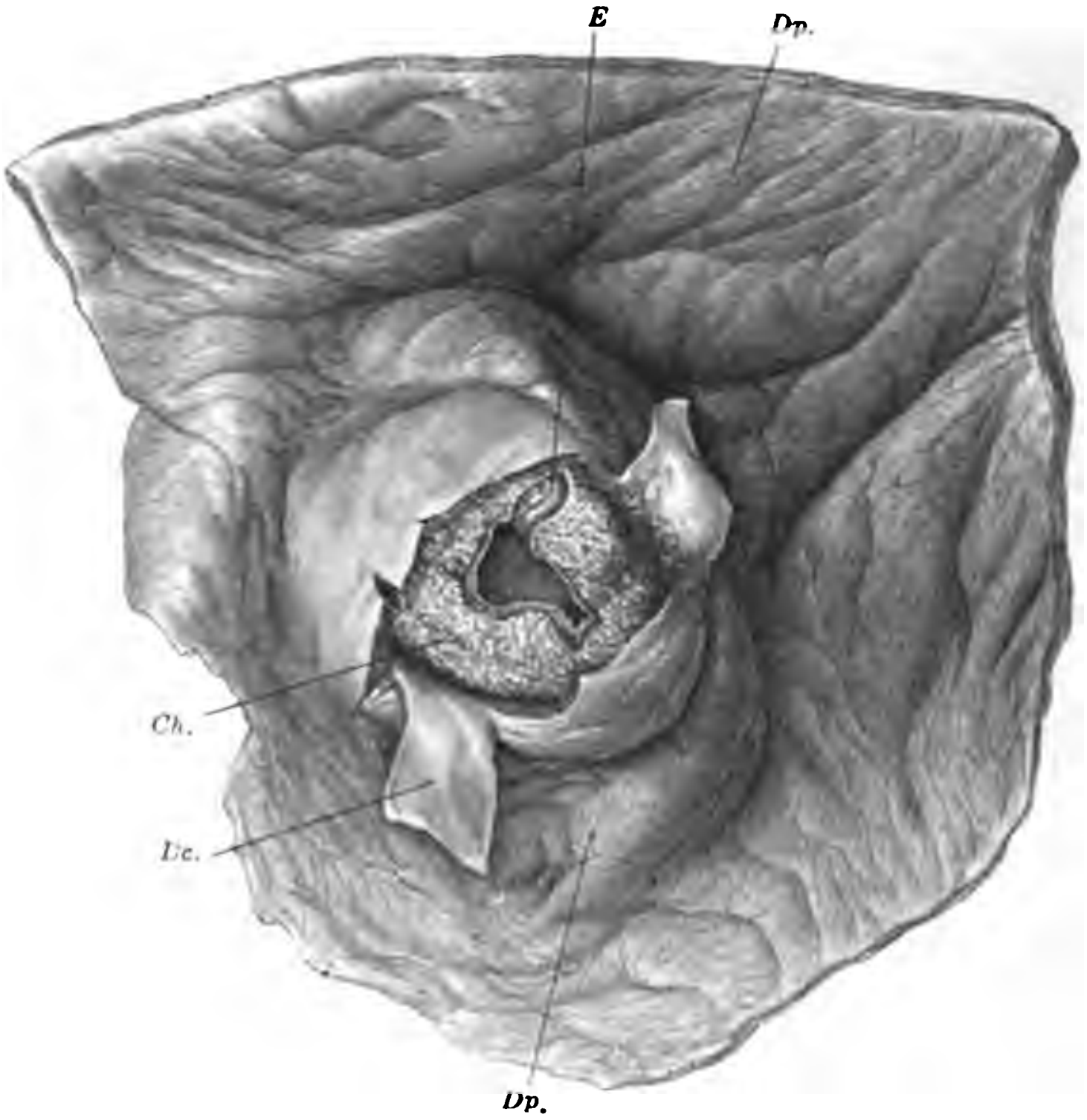

FIG. 101.—Pregnancy of the first month. The ovum expelled with the entire decidua; the decidua capsularis and chorion have been cut through and the intervillous space and extra-embryonic body-cavity opened. *Ch.*, chorion; *Dc.*, decidua capsularis; *Dp.*, decidua parietalis; *E.*, embryo in amnion. × 1¼.

There are four structures that still require thorough discussion: the trophoblast shell, the syncytium, the blood lacunæ, and the transition zone.

The *trophoblast shell* is to-day regarded unanimously, if we neglect Disse's view, as embryonic ectodermal tissue, as trophoblast (cytotrophoblast, trophoderm).[29] To it is also generally ascribed the power of dissolving and absorbing the maternal tis-

---

[29] The view advanced at one time by Langhans, but since relinquished, that the layer of separate cells upon the surfaces of the villi, arising from the trophoblast, was derived from the fetal mesoderm and that only the syncytium corresponded to the chorionic ectoderm has recently (on the last occasion in 1904) been revived by Van der Hoeven, but without sufficient evidence.

sues. Also analogies for the fact that it surrounds the ovum as an extensive growth are to be found among animals, namely, in the hedgehog.[30] That during its growth toward the maternal tissues portions of the trophoblast also are destroyed,[31] and that a zone of mutual penetration by the tissues, a transition zone, occurs, are also phenomena frequently to be observed in animals. The trophoblast shell usually develops more extensively on the basal side of the ovum, where the nutrition is best (Peters), and there, for the same reason, are formed the embryonic anlage and, later, the placenta [32] (Von Franqué, Peters).

The *syncytium* and the *blood lacunæ* are associated topographically and perhaps genetically also. The former has been the most disputed tissue in the whole field of histology, and even to-day it is not yet thoroughly understood. Of the different opinions as to its origin that have been advanced from time to time only two need further consideration; [33] the one derives the syncyt-

---

[30] The investigation of the hedgehog we owe to Hubrecht and his school. In the literature only the first work on this animal, that by Hubrecht himself (1890), is generally known. According to this certain important differences exist between the hedgehog and man, but more recent observations made by Resink under Hubrecht's direction (1903) have corrected a number of inaccuracies and thereby revealed a greater resemblance to the human conditions. For instance, the tissue formerly termed the trophospongia and derived from the decidua is now assigned to the trophoblast. (See also Grosser: Lehrbuch.)

[31] Jung, in agreement with Langhans, will not admit, at least in young stages, the occurrence of a destruction of the peripheral portions of the trophoblast shell, described especially by Peters. This author's results are regarded as post-mortem phenomena.

[32] This superiority of the basal growth is not always pronounced; apart from the Bryce-Teacher ovum, which showed an especially strong equatorial development of the syncytium, there was in the Jung ovum an almost equal development of the trophoblast shell, in the Spee ovum villi occurred on the peripheral surface, and in the Siegenbeek ovum there was again a superiority in the equatorial villi. A purely equatorial villous girdle, such as the frequently figured Reichert ovum (1873) showed, cannot be regarded as normal, since it can hardly be reconciled with the idea of interstitial implantation. The occurrence of variations within certain limits is, however, not unthinkable, since they may be produced by factors extrinsic to the ovum, such as the distribution of the embryotrophe, local pathological changes in the mucous membrane, etc.

[33] So long as the mechanism of implantation was unexplained, speculation concerning the origin of the syncytium had free rein. The early view, supported by the most prominent investigators (Langhans and his school, Strahl) and which assigned its origin to the uterine epithelium, is irreconcilable with interstitial implantation. Also the glandular epithelium need hardly now be considered as a possible source. For a consideration of the early views consult, for example, the well-known account of Waldeyer, also Peters and Strahl. Directly opposed to the idea of its origin from the uterine epithelium are cases of pathological implantation, such as are seen in ovarian pregnancies, for in these the villi have a typical syncytial covering.

ium from the trophoblast, the other from the endothelium of the maternal vessels.[34]

The trophoblastic origin of the syncytium is upheld by all supporters of Hubrecht's views and especially by all recent students of the problem. The Bryce-Teacher ovum is especially illuminating in this connection: in it a connection of the syncytium with the cytotrophoblast is, on the one hand, clear; and, on the other hand, an anchoring of the ovum to the maternal tissues, that is to say, a direct contact of syncytium and decidua, is wanting. Peters, Leopold, and Jung expressly mention the occurrence in their preparations of gradual transitions between the cytotrophoblast and the syncytium (for example, the passage of nuclei from the former into the latter, Jung) and the absence of similar transitions between the syncytium and the endothelium. These facts overthrow the opposed view of Pfannenstiel, based upon older preparations. which view brings him into accord with a number of older authors and for support of which he relies upon one uterine ovum which he himself investigated and one tubal ovum; at the same time other authors, such as Frassi and Bonnet, find no support from older ova for an origin of the syncytium from the endothelium, but declare themselves in favor of its fetal origin. The figures given by Pfannenstiel, which seem to speak for a derivation of the syncytium from the endothelium, are, apparently, capable of another interpretation (Frassi).

But although the fetal origin of the syncytium is no longer doubtful, the beginning of its formation has not yet been sufficiently studied. Hubrecht, Marchand, Bonnet, and others suppose that the syncytium is the expression of a special vital energy and is produced by the penetration of the trophoblast into the maternal tissues. Peters, however, is of the opinion that the syncytium is formed from the cytotrophoblast by a kind of degeneration process influenced by the maternal blood. The syncytium of both the Bryce-Teacher and the Peters ovum[35] is undoubtedly materially different from that of later stages, which forms a layer of almost even thickness over the chorionic villi. In the Bryce-Teacher ovum there is a thick spongy syncytium shell resting upon a thin layer of cytotrophoblast; in the Peters preparation there is a great quantity of cytotrophoblast and a very irregular distribution of the syncytium. This forms often large masses, which frequently

---

[34] Graf Spee does not express himself definitely on the question, but from the remarkable occurrence in one instance of a cuticle between the syncytium and the cell layer he is rather inclined to accept a maternal origin for the syncytium, deriving it eventually from the giant marrow cells of the mother. This idea is no longer tenable.

[35] The author is greatly indebted to Professor Peters for permission to study and make use of this valuable preparation.

project freely into the blood, and at many places are provided with relatively few, but greatly enlarged, nuclei, so that, as Peters points out, they give the idea not of a progressive but of a regressive form of tissue and according to Bonnet's terminology deserve to be termed symplasmata (Figs. 99 and 102). Only at certain places does the syncytium form a lining for the blood lacunæ, so as to recall well-known figures. In the Leopold ovum, on the other hand, it has many more of the usual characters; still more pronounced, perhaps, is this condition in the Jung ovum, in which degenerating syncytium, termed symplasma syncytiale by the author, can be observed only locally. Following a view similar to that of Bryce and Teacher, and assuming that their ovum was quite normal, we may suppose that two generations, so to speak, of syncytium are formed. The first is associated with the implantation and with the intense histolysis which leads to the formation of the cavity of the egg capsule; it is represented by the syncytial shell of the Bryce-Teacher ovum. Later this syncytium degenerates, for the most part, and the cytotrophoblast assumes largely the function of breaking down the decidua. In this way the appearance of the syncytium of the Peters ovum may be explained; as a matter of fact, one finds in this ovum in some regions what is almost entirely degenerating syncytium, and in others a syncytial system of trabeculæ with enclosed blood-containing lacunæ, comparable to those of the Bryce-Teacher ovum (Fig.

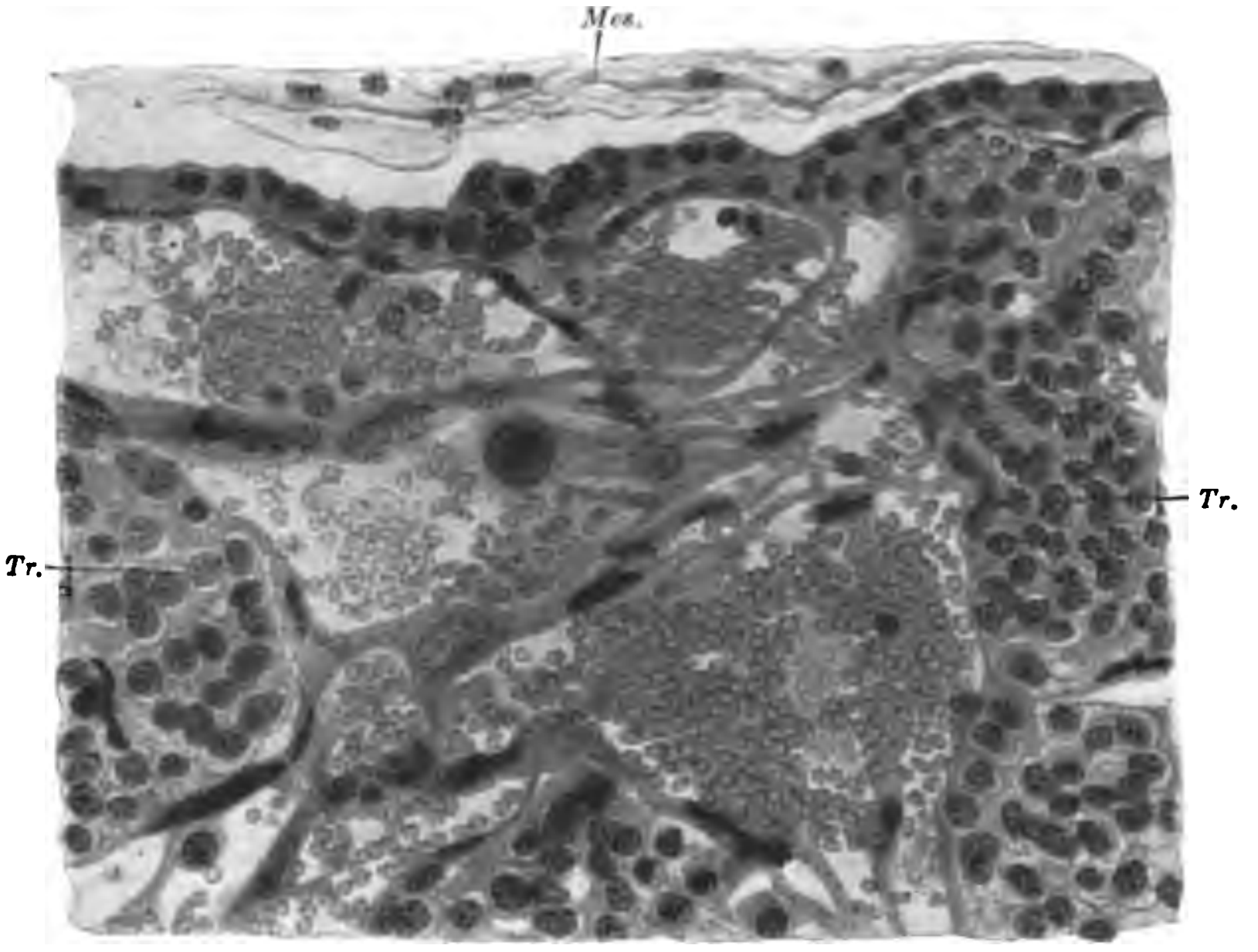

FIG. 102.—A portion of the trophoblast shell of the Peters ovum. The syncytium has a mesh-like arrangement, blood occupying the spaces. *Mes.*, chorionic mesoderm; *Tr.*, cytotrophoblast. × 350.

102). Also the absence of prickle processes on the syncytium of both the youngest ova is perhaps referable to these conditions. With the gradual development of a circulation in the blood lacunæ the syncytium—perhaps a new, second generation of it—assumes the task of extracting nutrition from the blood stream. Then one finds the syncytium almost exclusively in contact with the maternal blood (Jung, Siegenbeek), and only later can one again perceive an active penetration of the syncytium into the maternal tissues (Voigt, 1905, also in the formation of syncytial giant cells; see p. 148). The absorbing syncytium then possesses prickle processes.

At all events the syncytium has one very important peculiarity; it prevents, just like living vascular endothelium, a coagulation of the blood in contact with it and so makes possible a circulation of blood in the lacunæ. Yet this peculiarity is assumed also by the cytotrophoblast, at least at the time of the opening of the maternal capillaries, since (as, for example, in the Peters ovum) this tissue forms in part the boundaries of the lacunæ. Hofbauer suggests that the prevention of coagulation depends upon a layer of albumose deposited on the syncytium.

As regards the formation of the *blood lacunæ,* Bryce and Teacher are of the opinion that large vacuoles form in the syncytium, which at first contain a ferment destined for the solution of the decidua, but later, when this is expelled, the cavities of the vacuoles become filled with maternal blood. In this way the sponge-like infiltration of the syncytium mantle with blood is explained. Peters supposes them to be formed by the blood streaming out under pressure from the vessels opened by the trophoblast and excavating for itself, as it were, channels in the trophoblast; since, according to his views, contact with the blood determines the formation of the syncytium, it is easy to understand why the cytotrophoblast remains uncovered by it only at a few places. However, an active separation of the trophoblast cells and a subsequent filling of the lacunæ so formed is possible, as Frassi points out, and such an idea receives support from what occurs in animals (*e.g.,* in the rat). In the preparations of Peters and Leopold the lacunæ are gorged with blood, but this may be the result of the mode of death, since in the Jung ovum the amount of blood is not excessive; at all events blood is to be regarded as the normal contents of the lacunæ. They are the advance stages of the subsequent *intervillous space,* which may be defined as a vascular cavity bounded by fetal elements but filled with circulating maternal blood.[36] The lacunæ break up the trophoblast shell into indi-

---

[36] Remains of maternal tissue, as for example the peripheral endothelial walls of the opened capillaries, occur only on the outer sides of the space; see also Fig. 100.

vidual trabeculæ and cords, which give the entire chorion a villous appearance and may be termed *primary villi.*[37]

Concerning the *transition zone* the following may be said, briefly: The name was first employed in connection with the human ovum by Peters, being borrowed from the description of the processes occurring in the placentation of Carnivora (Strahl). In early stages (Bryce-Teacher) the zone is wanting; the ovum forms a place for itself by fermentative solution of the maternal tissues.[38] Only later, in association with the disappearance of the syncytial shell, already described (p. 125), does the phagocytic activity of the trophoblast become pronounced, and the fetal cells penetrate between the maternal ones and form the frequently incomprehensible complication that authors have described. In the transition zone fibrin [39] also first appears. Bryce and Teacher describe a zone of coagulated, necrotic fibrin around their ovum; in Peters's preparations actual fibrin is completely wanting; only the degenerating syncytium frequently resembles placental fibrin and occurs frequently in striæ near the transition zone. Such transitions of the syncytium into "fibrin" are also described by Marchand (1903) in young ova. Jung speaks of a distinct streak of fibrin which he compares to the Nitabuch stria (see p. 151); but in somewhat older stages such streaks are not typically present (compare Frassi). Necroses of the transition zone occur at first, accordingly, in rather variable amounts, and typical fibrin striæ probably occur only after the cessation of the phagocytic activity of the trophoblast.

C. THE STAGES FROM THE APPEARANCE OF THE VILLI TO THEIR COMPLETE FORMATION.

With the development of the blood lacunæ means are provided for the nutrition of the embryo from the maternal blood; the purely embryotrophic stage gives place to a transition stage that will lead to the hæmotrophic stage. At the same time the ovum undergoes a very considerable enlargement. The processes occurring in the transition stage which require further consideration are, chiefly, the mode of enlargement of the egg chamber, the closure of the decidua capsularis, the further fate of the trophoblast shell, and the transformation of the blood lacunæ into the intervillous space, together with the formation of the secondary villi which goes hand in hand with this.

The *enlargement of the egg chamber* is produced by two fac-

---

[37] As to the use of this term by other authors, see p. 130, note.

[38] Analogous are the early stages in the development of the egg chamber in, for example, the guinea-pig (Graf Spee).

[39] Concerning the use of this term see p. 151 *et seq.*

tors, both of which are already recognizable in the youngest ova. One is a dilation caused by the growth of the ovum; it finds expression in the curved course of the glands at the periphery of the egg chamber. The other factor is the splitting up of the marginal decidua, which shows itself even in the youngest ova in the growth of the margins of the opening of implantation over the ovum. But this very splitting of the marginal decidua is a much disputed point in the history of placentation and is intelligible only by ascribing vital properties to the trophoblast. This continues to penetrate into the maternal tissues, opens vessels and glands, destroys portions of the glands entirely, and so divides them into a portion pertaining to the decidua basalis and a portion pertaining to the capsularis. And since with the extension of the trophoblast the intervillous space also enlarges, the lumina of the glands open, at least temporarily, into the latter (Fig. 103); and, on the other hand, before their complete destruction, remnants of their epithelium are to be found in the wall of the space (Fig. 104). Since the destruction of the maternal tissue may be due in later stages to fermentative solution in addition to phagocytosis, the openings in the walls of the glands, for example, need not necessarily be filled up by penetrating masses of trophoblast, but the mere juxtaposition of such masses may be sufficient for the solution of the wall of the gland. Such a condition is shown indisputably, as it would seem, by Frassi. The "opening of glands into the intervillous space," as it was formerly described, has been regarded by a number of authors (Gottschalk, Hofmeier) as most

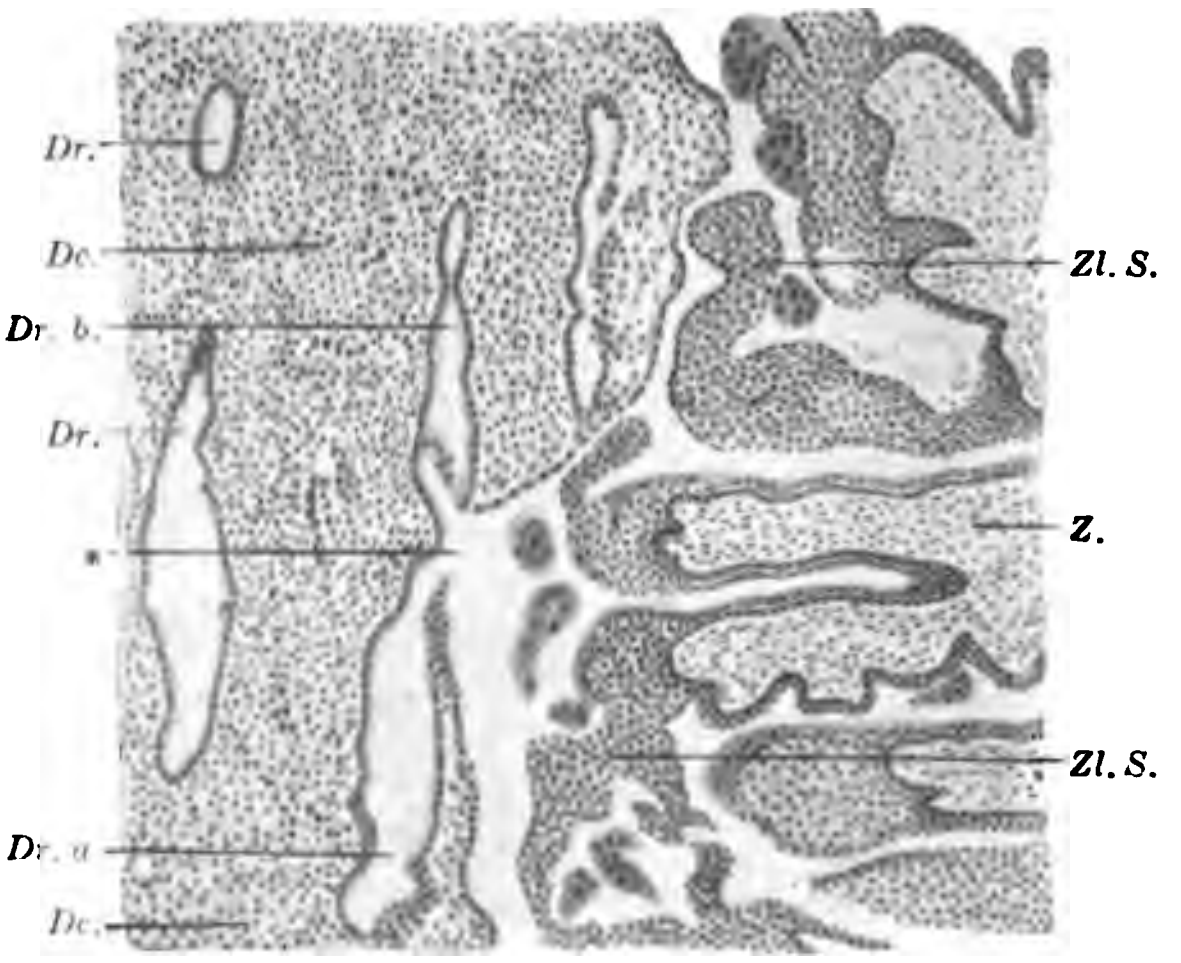

FIG. 103.—A part of the marginal portion of the decidua. To the left the decidua with glands, one of which at * is in communication with the intervillous space. *Dr. a.*, the portion of this gland directed away from the lumen of the uterus; *Dr. b.*, the portion of it turned toward the lumen of the uterus. To the right are chorionic villi and cell columns; *Dc.*, decidua; *Dr.*, glands; *Z.*, chorionic villi; *Zl. S.*, cell columns. × 50. (From Frassi, 1907.)

certain, but by others it has been just as definitely denied; its occurrence has been advanced as evidence in support of the older theory of implantation, according to which the ovum adhered superficially to the mucous membrane and became surrounded by a wall formed from the membrane (decidua "reflexa"). Frassi has been able several times to observe directly in serial sections the lateral openings of the glands and their free communication with the intervillous space which was thus effected (Fig. 103). Hofmeier had already described similar conditions. By these openings blood naturally passes from the intervillous space into the lumina of the glands and may greatly distend them, and thus the frequently repeated observation of greatly enlarged glands filled with blood in the neighborhood of the ovum becomes intelligible. The opening of the glands into the space is in any event a very transitory condition, since the trophoblast, blood-clots, and desquamation of the epithelium soon close the openings and the glands are then completely divided. But one always finds beneath the ovum, in the decidua basalis, large glands, usually filled with blood, which have lost their terminal portions. The blood which has filled them may in later stages serve as embryotrophe.

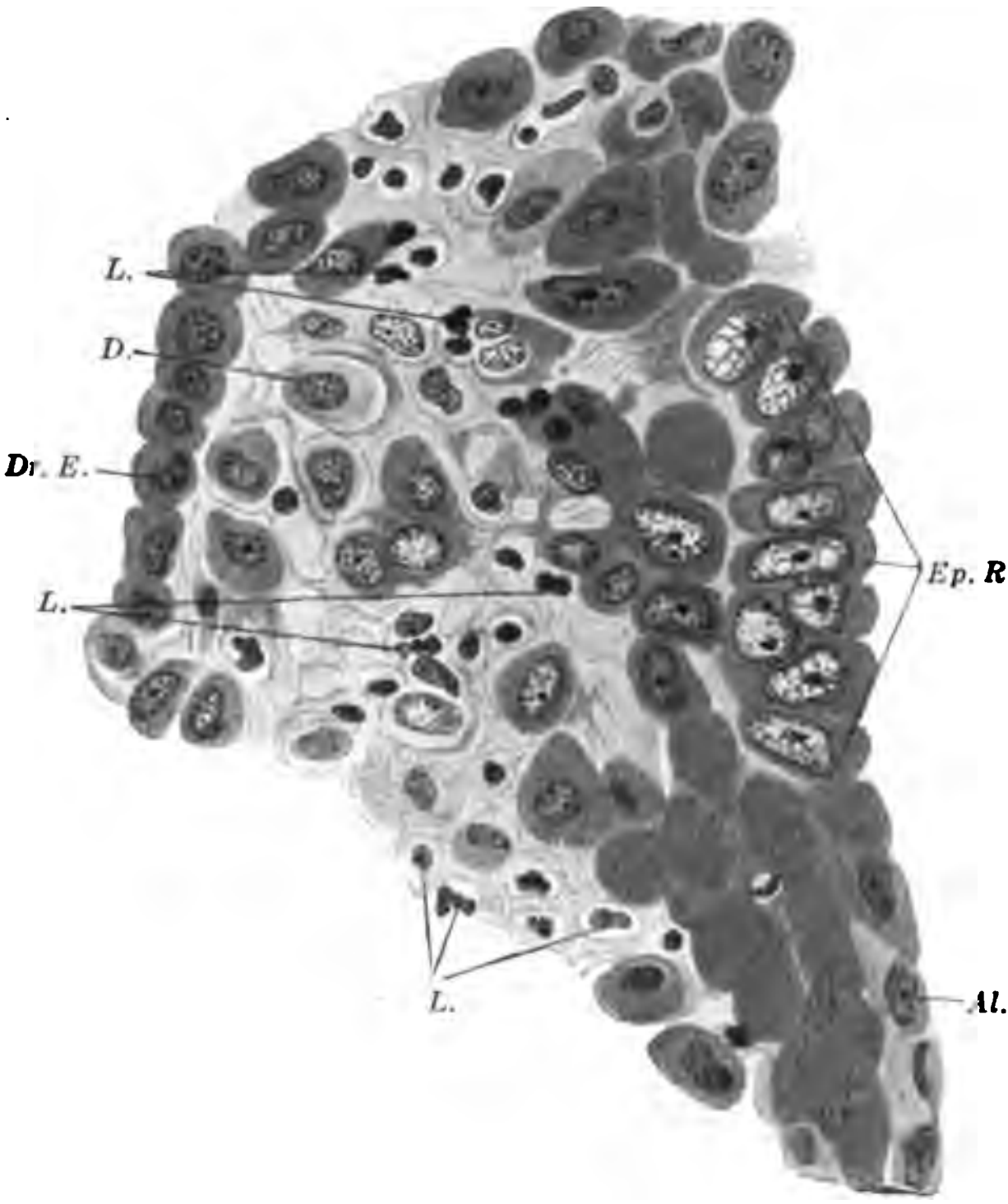

Fig. 104.—To the right, an epithelial remnant (*Ep. R.*), derived from a destroyed gland, and the lining layer (*Al.*) of the wall of the intervillous space. To the left, glandular epithelium (*Dr. E.*) Between, decidua (*D.*) with leucocytes (*L.*). × 300. (From Frassi, 1908.)

Epithelial remnants in the wall of the intervillous space (Fig. 104) have also been frequently observed (for example, by His); but they have usually been regarded as having been derived from the surface epithelium of the uterus and have been accepted as bearing on the implantation question in the same way as the "open gland communications." Frassi has also made clear the relations of these epithelia to the destroyed glands.

The *decidua capsularis* is completely closed in all ova older than that of Beneke. This closure must be effected by growth processes—either by the growth of tissue from the margins of the implantation opening, or by the organization of the basal portion of the closing coagulum, the protruding portion of this being thrown off. In the Frassi ovum, for example, the capsularis covers the entire ovum as a smooth, almost evenly thick layer. It still possesses uterine epithelium in its marginal portions and in patches even up to the upper pole, and glands occur at its margin; their occurrence over the summit is impossible from the mode of development of the membrane. Fibrin, partly in streaks, occurs throughout the whole extent of the capsularis, and most distinctly at its summit; but no trace of the implantation opening is visible in later stages. In the majority of ova in this stage of development there is at the summit a tissue rich in fibrin and poor in cells or even entirely without cells; this is Reichert's scar (for example, Hofmeier; older ova of Leopold, Graf Spee, and Peters; also Pfannenstiel, Rossi Doria, Cova, etc.). The scar either denotes the complete, organic closure of the capsularis, or, what is more probable, it is the first sign of what is later a complete degeneration of the capsularis, which becomes more and more stretched by the growing ovum, but is only very incompletely nourished on account of its possessing no blood-vessels of its own.

The *changes in the trophoblast shell* which occur during the first stages of development concern partly the arrangement of its cell materials, partly the cells themselves. By the ingrowth of connective tissue (chorionic mesoderm) into the trophoblast cords —a process which has already begun in the Peters ovum—these cords, which have previously been termed primary villi, become transformed into *secondary villi*, the true *chorionic villi*. These secondary villi are, therefore, preformed by the primary villi, but soon show independent growth.[40] The trophoblast, whose

---

[40] The terms primary and secondary villi have been employed in the literature variously and with a somewhat different sense from that given them above. Marchand (1903) speaks of primary villi up to the time of the penetration of the fetal blood into the mesodermal axes of the villi; Hitschmann and Lindenthal (1902) and Pfannenstiel (1903), until the formation of the typical two-layered epithelium. According to Hitschmann and Lindenthal the primary villi are characterized by their power of active penetration.

superficial layer is transformed into syncytium, becomes divided and spread out over the villi, until there remains only a single layer of distinct cells, over which is a layer of syncytium, also, as a rule, with a single row of nuclei. Both layers together constitute the *epithelium of the villi.* Very early the villi send out lateral branches and assume a dendritic appearance. The blood lacunæ between them expand, unite together to a greater extent than formerly, and completely surround the villous growths; the lacunæ thus become transformed into the intervillous space, which continues to extend toward the ovum until at length its mesoderm is covered only by a two-layered covering of epithelium. This covering and the mesoderm of the chorion now form the *chorionic membrane* or *plate,* which, as is characteristic for a placenta olliformis (p. 93), closes the intervillous space on the side towards the ovum.

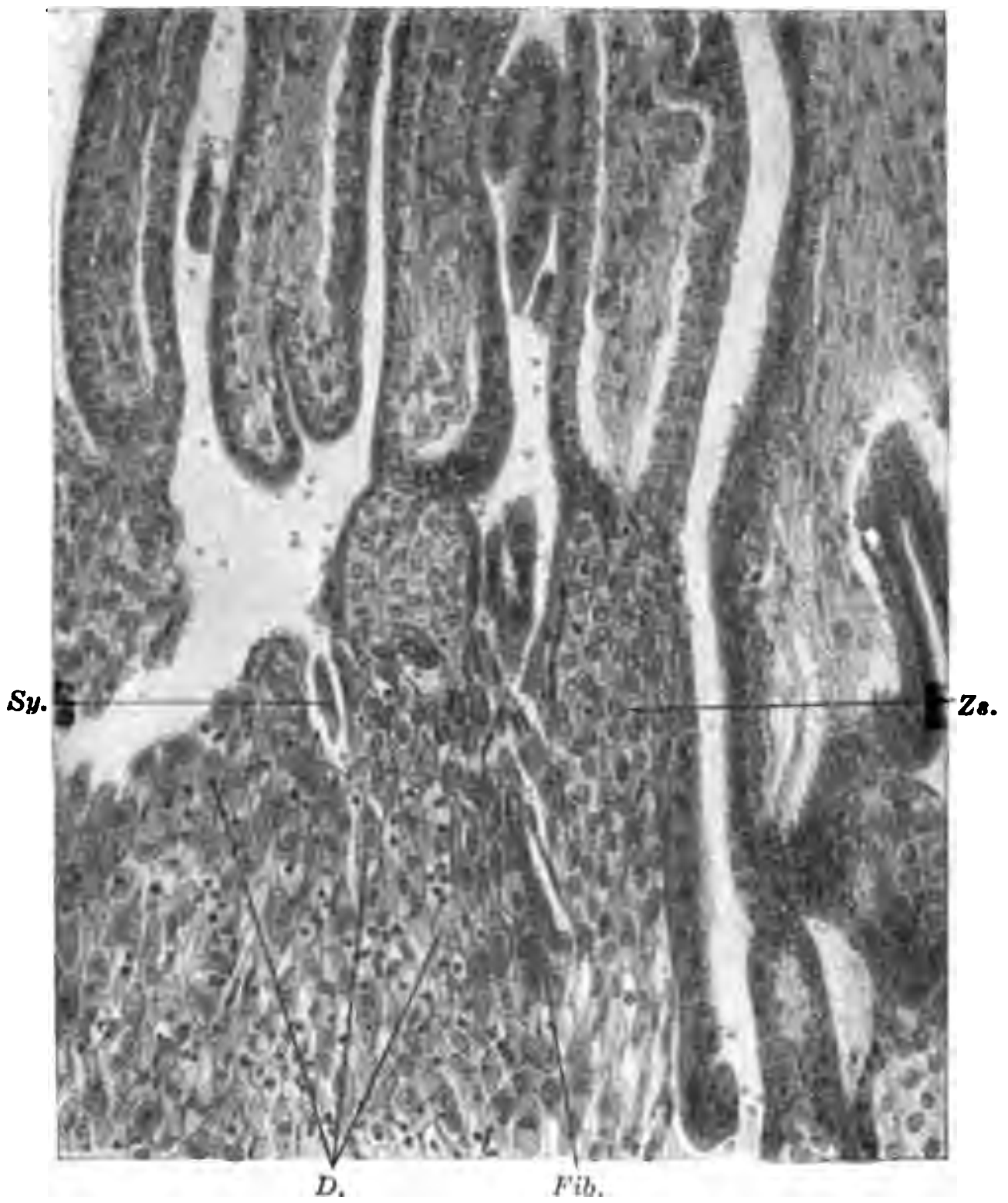

FIG. 105.—Cell columns (*Zs.*) on the wall of the intervillous space in the second month. *D.*, decidua; *Fib.*, fibrinoid; *Sy.*, syncytium. × 200. (From the same ovum as Fig. 118.)

But the entire trophoblast is not used in the covering of the villi. It also gives rise to the cell columns, the cell islands, and the basal ectoderm (the covering layer).

The *cell columns* (Fig. 105) are remains of the primary villi into which the mesoderm has not yet penetrated, and they unite the tips of the branches of the villi (the *anchoring villi,* in contrast to the ends of the lateral branches, which float freely in the intervillous space, the *free* or *absorbing villi*) with the wall of the intervillous space. They consist of cellular trophoblast with a superficial layer of syncytium or with the covering layer to be described later. At first they are of considerable length; and since they contain no connective tissue the fixation of the ovum is at first a rather loose one, so that in an abortion or by the manipulation of a preparation young ova may comparatively readily be separated entire from the capsule (Fig. 106). It is principally from the cell columns that the activity of the trophoblast, the splitting up of the decidua, proceeds. Yet the cell columns continually diminish in length, the trophoblast is used up, and the mesodermic stroma of the villi extends out to the outer wall of the intervillous space. At the end of the second month the cell columns have vanished, the villi are firmly anchored, an abortion produces a separation of the decidua, and the splitting of the marginal decidua has ceased (Hitschmann and Lindenthal).

FIG. 106.—Aborted ovum from the beginning of the second month, expelled entire. × 1½.

The *cell islands* or *cell nodes,* also termed *large-celled islands* (Figs. 107 and 108), are also masses of trophoblast which have not been distributed over the villi (Langhans, Rossi Doria, Schickele, etc.). They are, it is true, attached to the ends of the villi, but otherwise lie free in the intervillous space. The indi-

Fig. 107.—Section through the chorion of an aborted ovum of one month. (Greatest length of the embryo, 9 mm.) *Chp.*, chorionic plate; *Zi.*, *Zi. 1.*, cell islands.

Fig. 108.—Detail of Fig. 107: the cell island indicated by *Zi. 1*. *Fib.*, fibrinoid; *Sy.*, syncytium; ***f. Sy.***, "free" syncytium; ***Tr.***, masses of trophoblast (decidua-like); ***Zs.***, connective-tissue stroma of villi. × 100.

vidual trophoblast cells are remarkable for their size and their swollen appearance, and have on these accounts been frequently taken for decidual cells; nevertheless, the occurrence of true decidual islands is at least doubtful.[41] The occurrence of vascular remains in the islands, which would determine their nature, has been described by Franqué and Vassmer, but denied by Giese (1905), their supposed presence being based on an error of observation. The derivatives of the trophoblast, syncytium and "fibrin" (see pp. 151 *et seq.*), are of constant occurrence in the

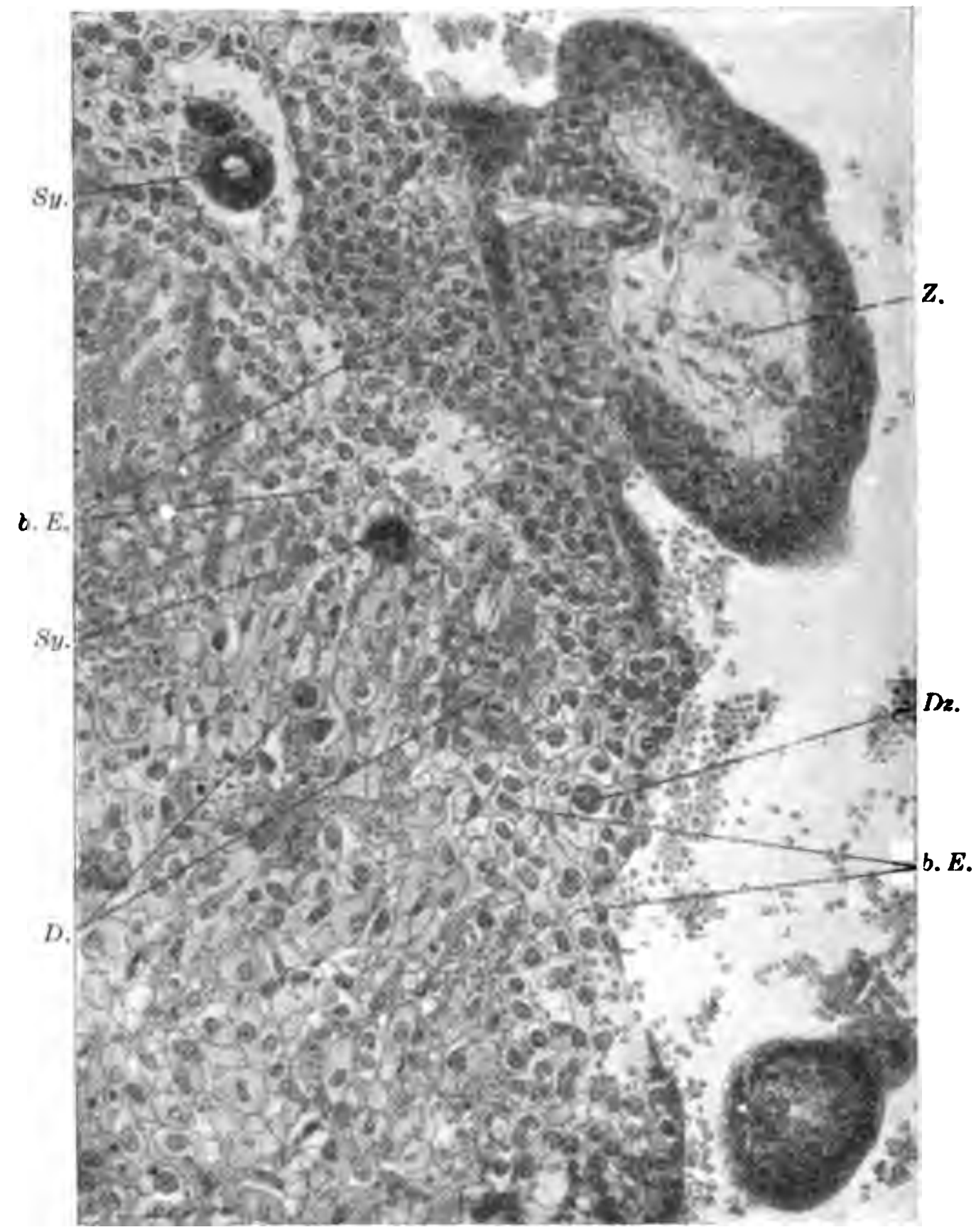

FIG. 109.—Basal ectoderm (*b. E.*) on the wall of the intervillous space in the second month; detail of Fig. 118 (on the right side of the decidual pillar). *D.*, decidua; *Dz.*, decidual cell surrounded by trophoblast; *Sy.*, syncytium; *Z.*, villus. × 200.

---

[41] The so-called decidual columns (Deciduabalken, Leopold) will be discussed later with the decidual pillars. Happe (1907), like Pfannenstiel (1903) and Webster (1906), regards the islands as formed principally of trophoblast, but also maintains that they contain decidual tissue (more spindle-shaped cells, loosely connected together and partly with a finely granular intercellular substance).

islands, which disappear in the course of the first months, being for the most part converted into "fibrin."

The *"basal ectoderm"* is a term applied by Langhans and his school to that portion of the trophoblast which occurs on the outer wall of the intervillous space; in somewhat older ova it there forms a stratified layer (Fig. 109) and is frequently retained until the end of pregnancy, if not as a continuous stratum, at least in masses of cells arranged in groups (Figs. 129–132). Its relations in younger stages, at the commencement of the formation of a continuous intervillous space, have been studied by Frassi. In such cases there is found upon the outer surface of the intervillous space the "covering layer," a simple layer of cells, resting as an almost continuous sheet upon the decidua. "The nuclei of these elements are larger and take the stain more deeply and regularly (than the nuclei of the decidual cells). With strong magnification a distinct difference can be perceived between the endonuclear substance of such cells and that of the decidual cells." The covering layer is everywhere one-layered in Frassi's preparations; it is in places separated from the decidua by fibrin and is lacking only in a few places. It occurs here and there between the cell columns or forms an external covering for these (Fig. 110). Transitions into decidua are absolutely wanting, but, on the other hand, they occur into the syncytium, so that the covering layer is of fetal origin.

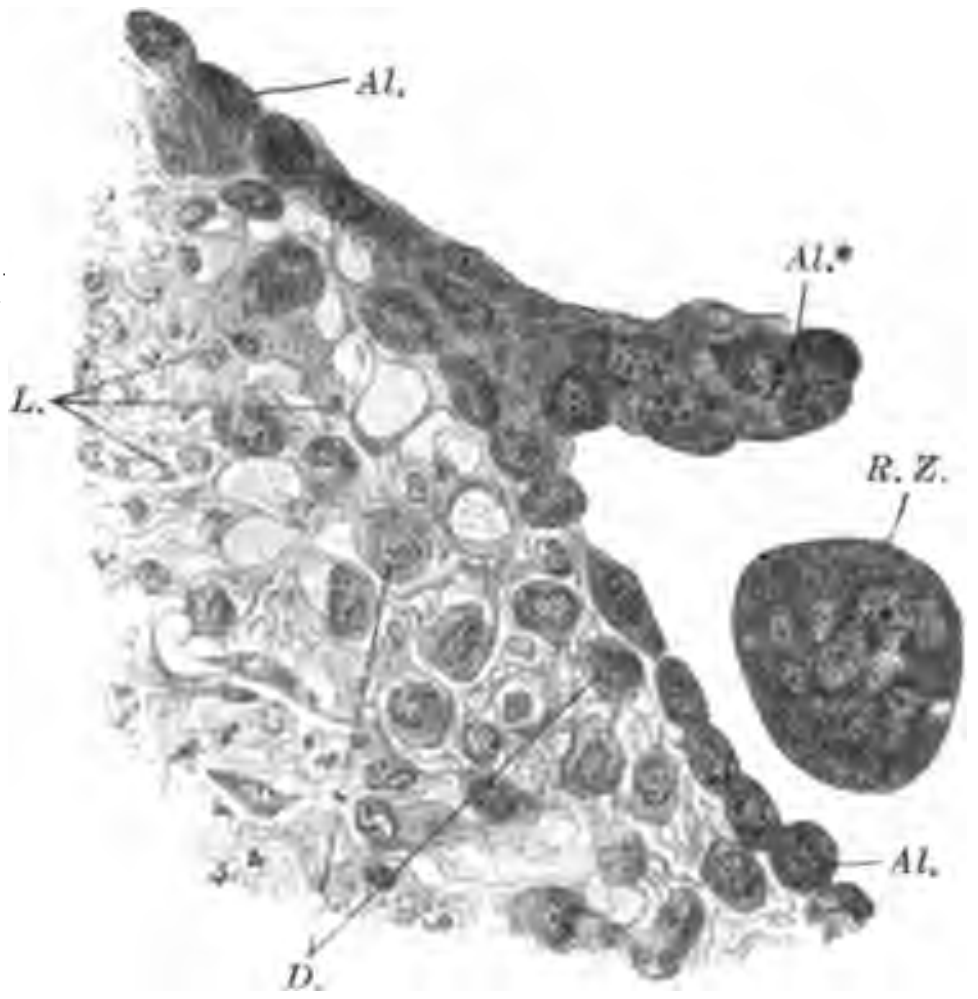

FIG. 110.—Covering layer of the ovum capsule (*Al.*) at its transition into a cell column (at *Al.**); *R. Z.*, giant cell; *D.*, decidua; *L.*, leucocytes. × 300. (From Frassi, 1908.)

The boundary between the fetal and the maternal elements is not always easy of determination; assistance is rendered in this connection, according to Frassi and Jung, by the leucocytes which occur abundantly and are always to be found in the neighborhood of the ovum. It would appear that they cannot pass beyond the boundary of the ovum, which penetrates like a parasite into the mucous membrane, and consequently they make possible the determination of that boundary.

The term transition zone indicates that the boundary is not a sharp one. Bonnet (1904), in the cases of older ova (those containing an embryo 3 mm. in length), preferred to speak of a detritus zone between the chorionic villi and the decidua. In association with it are symplasma formations of the decidual cells and enlarged glands and in the lumen exudations of secretion, blood, and leucocytes.

The *intervillous space* has also received different interpretations from different investigators. According to the older implantation theory, which held that the ovum became attached to the mucous membrane only superficially and that the uterine epithelium was retained, transformed into syncytium, the space was necessarily regarded as a portion of the cavity of the uterus enclosed between the ovum and the surface of the uterus; the occurrence of blood within it was only accidental, or, at most, a regular phenomenon only in later stages of development, its place being taken in young stages by a secretion of the mucous membrane, a kind of uterine milk. As a matter of fact the space was usually found to be empty in aborted ova (Fig. 107) and even in those obtained by operation and observed *in situ* (Fig. 118). These observations were taken as evidence opposed to a regulated circulation in the intervillous space; and the condition occurring in the Peters ovum, for instance, in which the lacunæ were engorged with blood, was explained as the result of the action of the poison taken by the mother. Frassi, who also found the space empty in his ovum, although open communications with maternal blood-vessels could be determined at various places, rightly maintained, on the contrary, the existence of a regulated circulation, and pointed out that, after the inflow of blood had ceased as a result of the cessation of the heart-beats of the mother or of the ligation of the arteries during operation, an outflow of blood through the veins was still quite possible and, furthermore, would be aided by the final contractions of the uterine musculature. Such contractions, indeed, occurring as they do, though to a lesser degree, throughout the whole period of pregnancy, may form an important accessory factor in promoting a circulation, which at the best must be difficult and slow, through the very irregular space (Von Herff).

The views of Pfannenstiel regarding the formation of the intervillous space will be considered later (p. 167).

With the formation of the intervillous space and the gradual disappearance of the trophoblast shell the ovum passes from the embryotrophic into the hæmotrophic phase of placentation.

IV. THE FORMATION OF THE PLACENTA; RELATIONS OF THE EMBRYONIC MEMBRANES UP TO THEIR MATURITY.

(*Hæmotrophic Phase of Placentation.*)

a. DIFFERENTIATION OF THE CHORION; CHORION LÆVE, DECIDUA PARIETALIS, AND CAPSULARIS.

At first the trophoblast shell completely surrounds the ovum and villi are formed over the entire surface of the chorion; the entire chorion is at first a *chorion frondosum.* As the ovum increases in size and projects more and more beyond the general level of the mucous membrane, the decidua capsularis, which covers it and is only poorly supplied with nourishment, is gradually distended more and more, the circulation in the intervillous space over the convexity of the ovum becomes more and more difficult, and the villi on the surface directed toward the capsularis finally atrophy, so that the convexity of the chorion becomes smooth, becomes a *chorion læve,* while the basal portion of the chorion frondosum becomes the placenta fetalis.

According to the observations of Pfannenstiel (1903) ova of the fourth week (from the cessation of menstruation) already distinctly show a bare spot at the capsularis pole, and even at the end of the second week this pole may be almost destitute of villi. Ova of the second to the fourth week project beyond the general level of the mucous membrane to very varying extents, either as far as the equator or even further. This condition is referred by Pfannenstiel to varying depths of implantation; the shallower the implantation the more the ovum later projects beyond the level of the mucosa. The depth of the implantation, on its part, depends upon the intensity of the original growth of the trophoblast and its action on the maternal tissues. Concerning the relation which probably obtains between the depth of the implantation and certain abnormal forms of placenta (placenta marginata, reflexa, accreta) see Grosser's "Lehrbuch." The further fate of the chorion læve will be considered in connection with that of the decidua capsularis.

The *decidua parietalis* (vera), in accordance with its premenstrual relations, is already more or less distinctly differentiated into a pars compacta and a pars spongiosa at the time of implantation.[42] The former is essentially the region of stroma changes while the latter shows characteristic gland forms. But both layers during the first weeks of pregnancy still present the

---

[42] Peters did not observe the compact layer and believed that it develops later, and Siegenbeek notes the lack of a distinct boundary between the two; nevertheless it must be remembered that in this respect variations occur also in the premenstrual mucous membrane. In the Jung ovum the layers are separated.

premenstrual type, in accordance with the inhibitory effect exercised by the implanted ovum upon the changes of the mucous membrane (p. 119); in the stages now under consideration (Fig. 111) they are differentiated.

The decidua compacta (Fig. 112), in addition to the straighter terminal portions of the glands and greatly enlarged blood-vessels, also contains *decidual* cells, which are formed from stroma cells by the continuation of the changes that are characteristic of the end of the premenstrual stage. They are large, clear, vesicular cells, as much as 50 μ in diameter, and are round or, from mutual pressure, polygonal, resembling epithelial or epithelioid cells. The changes by which they are produced do not occur simultaneously in all the stroma cells; and even at the height of the formation of the decidua one may find here and there stroma cells but slightly altered and showing division and growth phenomena, so that Marchand (1904) recognizes two types of decidual cells, large and small. The mature (large) decidual cells show, at the most, only

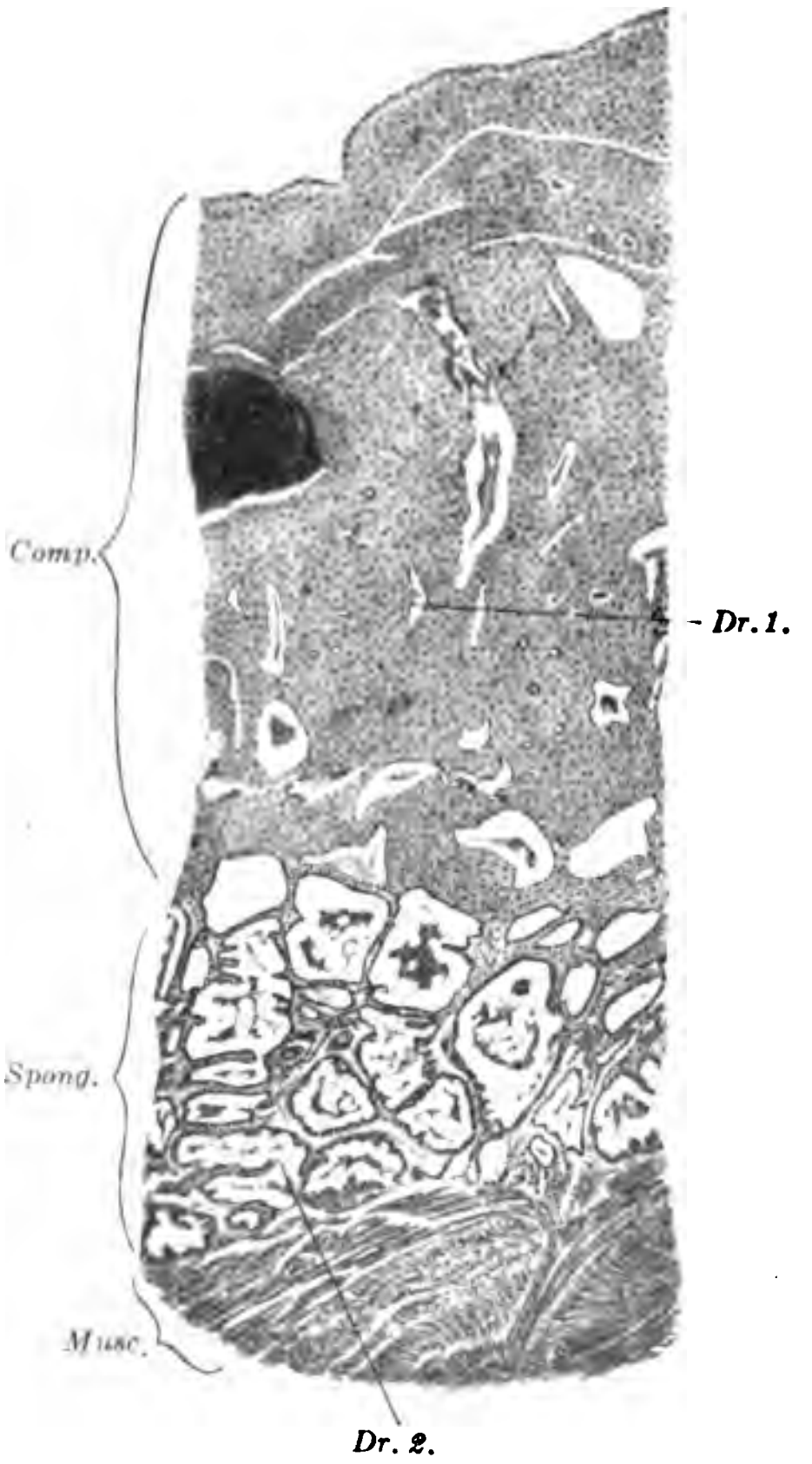

FIG. 111.—Decidua vera (parietalis) of the second month. *Comp.*, decidua compacta; *Spong.*, decidua spongiosa; *Musc.*, muscularis uteri. For *Dr. 1.* and *Dr. 2.* see the detail, Figs. 112 and 113. × 12.

direct nuclear division (they contain frequently two nuclei and indications of a cell boundary between the nuclei) and, as fully differentiated cells, are capable of no further progressive or regressive development. Many of them degenerate during the second half of pregnancy and are disposed of by leucocytes; but the majority are thrown off either during or after birth. After the fourth month they all become smaller again and more spindle-shaped and are arranged parallel to the surface (Pfannenstiel). According to Wederhake (1906), Unna plasma-cells also occur in the decidua, and transitions between these and typical decidual cells.

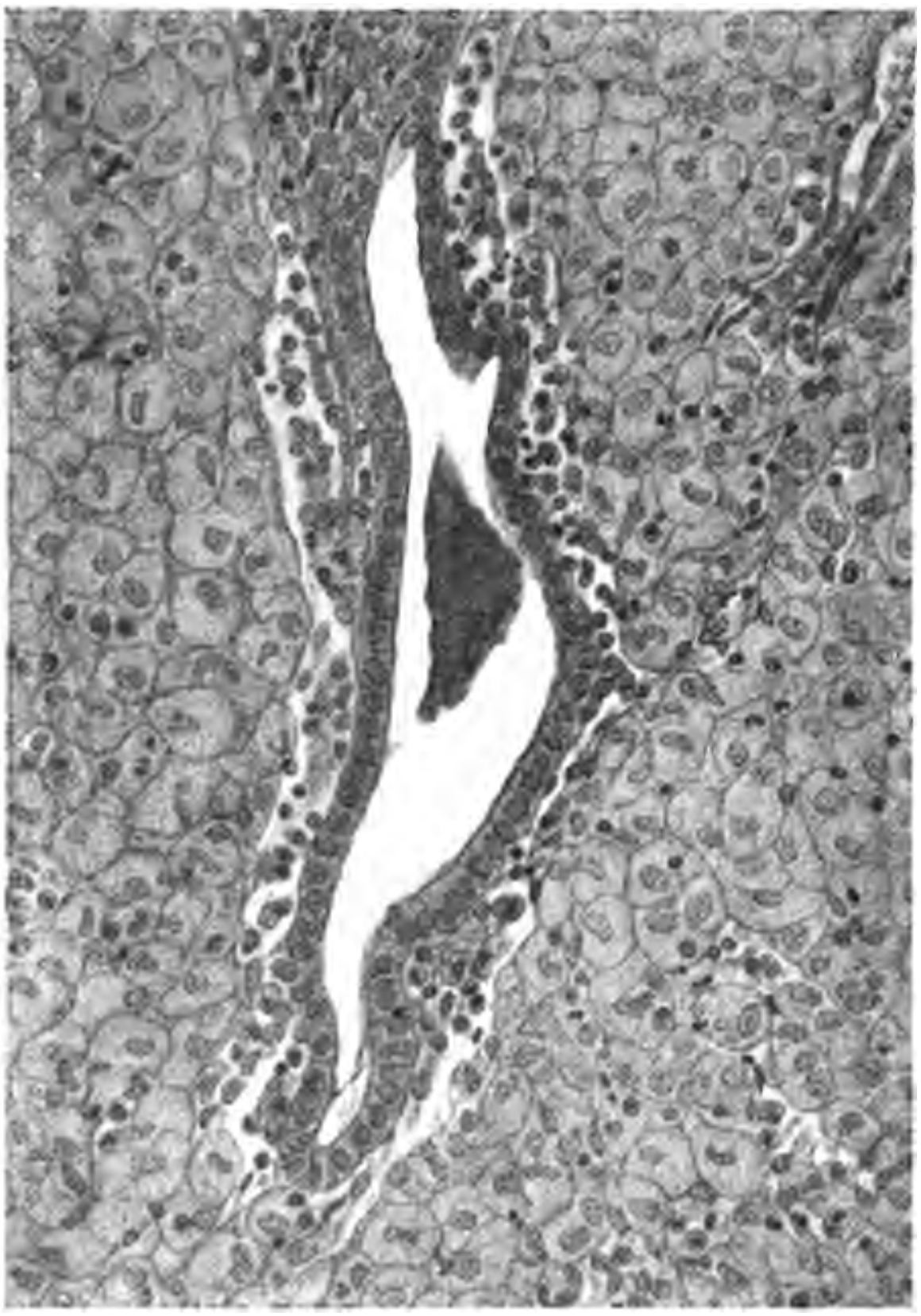

FIG. 112.—Detail of Fig. 111; the gland duct there indicated by *Dr. 1.* in the decidua parietalis compacta of the second month. The gland contains secretion and around it are typical decidual cells and a few leucocytes. × 350.

The significance of the formation of the decidual cells lies, according to Marchand, in the storing up of glycogen;[43] the ma-

---

[43] Driessen (1907), who recently has again taken up the older observations of Langhans on the occurrence of glycogen in the decidua, finds that substance chiefly in the glandular epithelium of the spongiosa; it is not always recognizable in the decidual cells. In the second half of pregnancy it gradually disappears.

jority of other authors see in their formation a provision against the too intensive penetration of the ovum into the mucous membrane, without furnishing sufficient evidence for such a view. According to Marchand, spindle-shaped epithelial cells grow out as wandering epithelial cells from the degenerating glands of the compacta into the stroma and may there fuse to form multinucleated masses.

In the decidua spongiosa are to be found at first the *glands of pregnancy,* also characterized by the further development of the premenstrual changes (Figs. 87 and 113). They are greatly enlarged and tortuous, irregular in section, and filled with secretion. The enlarged epithelium projects into the lumen in the form of papillæ borne upon small elevations of the stroma; it is composed of high cylindrical cells, with clear marginal zones filled with secretion. Between the glands are very small connective-tissue septa with scattered decidual cells; only near the larger vessels are the septa broader. After the second month the epithelial papillæ disappear and the cavities of the glands become low and broad as a result of the stretching of the entire decidua, due to the increase in size of the uterus. The epithelial cells continue to grow broader and lower (Fig. 114) until, finally, they resemble an endothelium and are lacking in places. The cavities of the glands then appear as small, elongated clefts, with thin intervening walls, resembling in mass an empty venous plexus

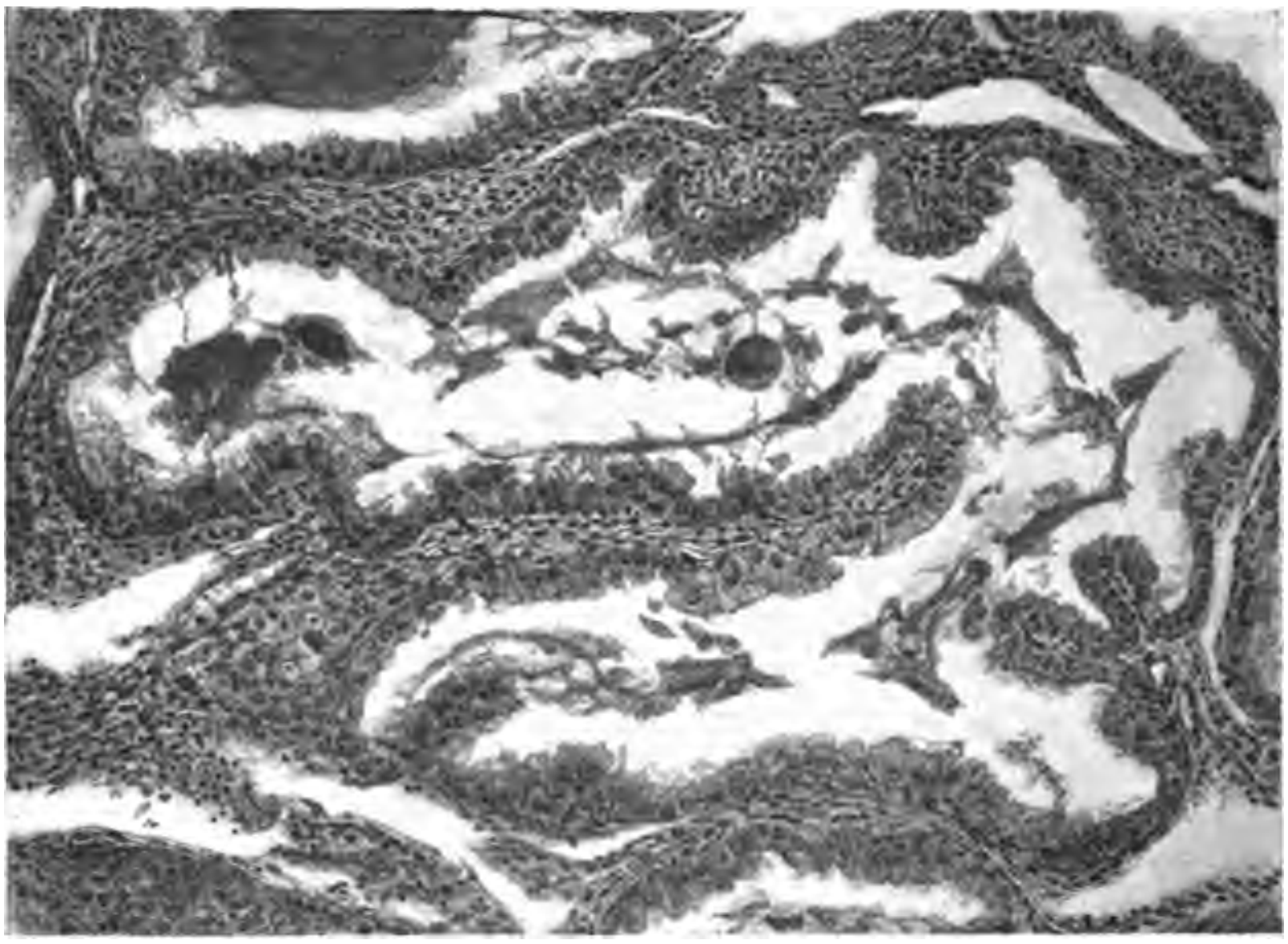

FIG. 113.—Detail of Fig. 111; the gland of the decidua parietalis spongiosa there indicated by *Dr. s.* Papillæ in the wall of the gland-bearing epithelium, secretion in the lumen. × 150.

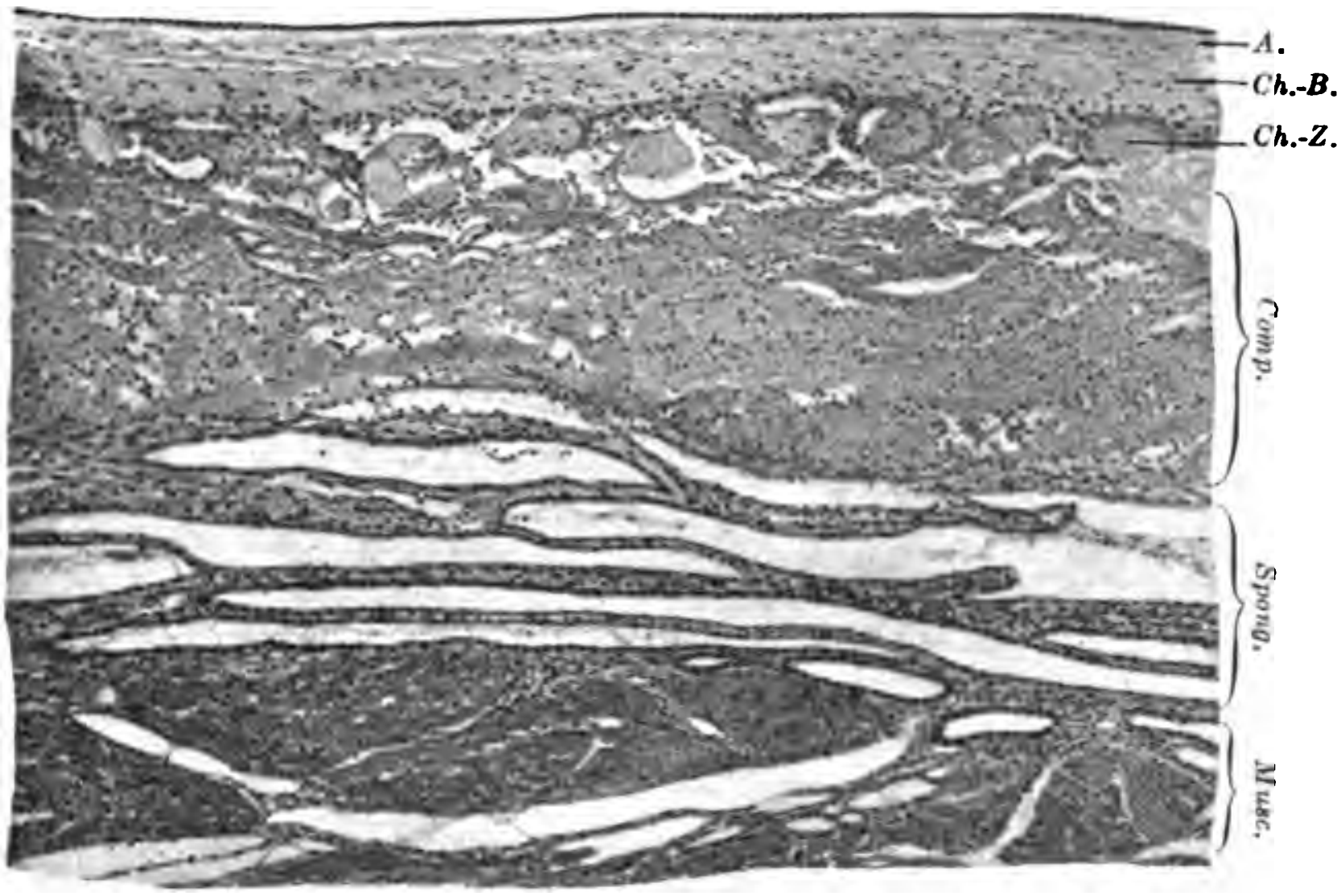

FIG. 114.—The egg membranes and uterine wall opposite the placenta in the fourth month; from the same case as Fig. 130. (Embryo 13½ cm. in vertex-breech measurement.) *A.*, amnion; *Ch.-B.*, chorionic connective tissue; *Ch.-Z.*, degenerated chorionic villi; *Comp.*, decidua parietalis compacta and capsularis; *Spong.*, decidua parietalis spongiosa; *Musc.*, muscularis uteri. For detail see Fig. 115. × 80.

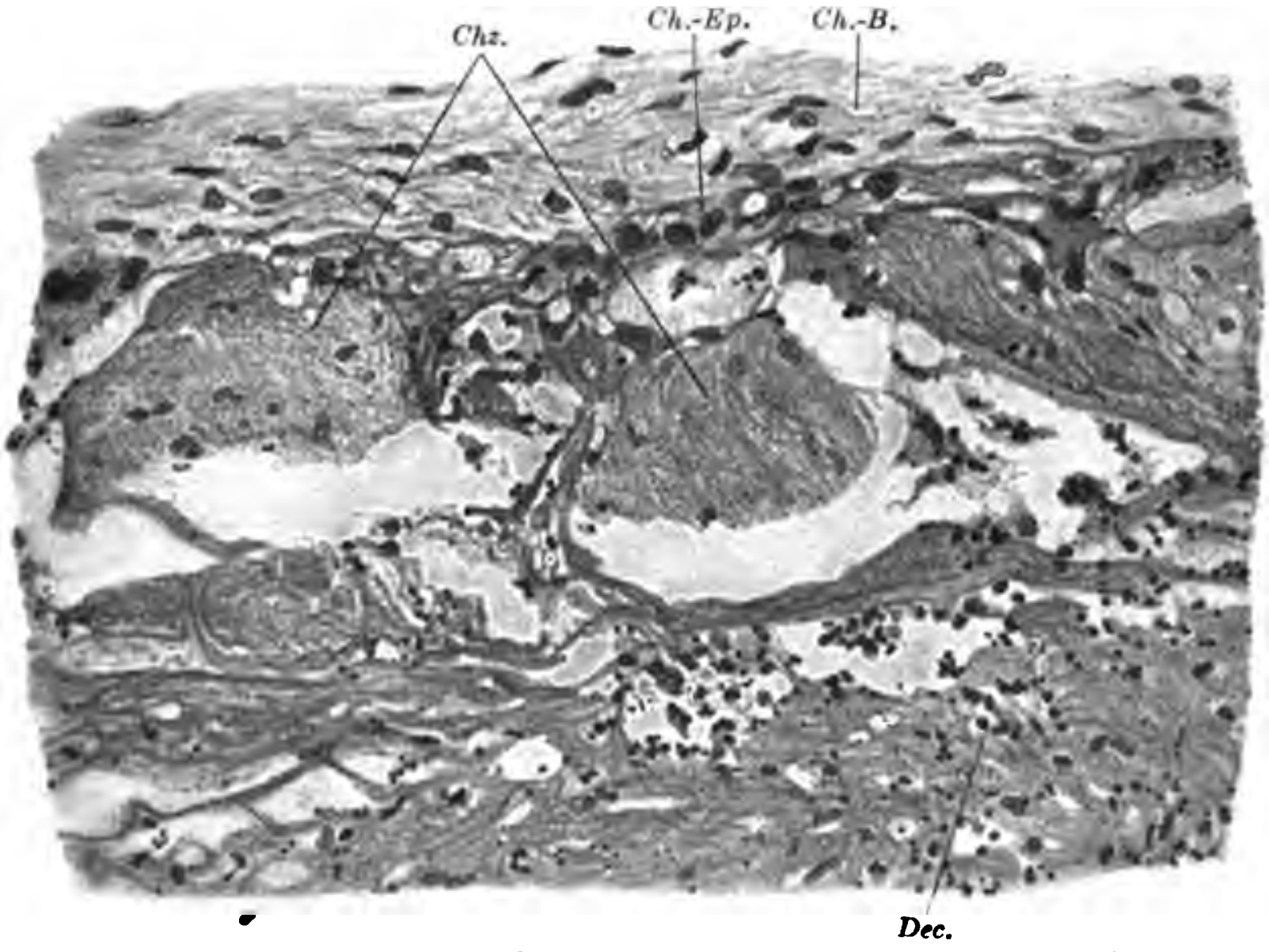

FIG. 115.—Detail of Fig. 114. The degenerated villi of the chorion læve in the fourth month (the villi have shrunken somewhat during the preparation of the object). *Chz.*, chorionic villi; *Ch.-Ep.*, chorionic epithelium; *Ch.-B.*, chorionic connective tissue; *Dec.*, decidua capsularis and parietalis compacta, with leucocytes. × 300.

(Fig. 117). The separation of the decidua in an abortion or at birth can therefore take place easily in the spongiosa. Only the deepest portions of the glands (the boundary layer of His), which lie between the irregularities of the surface of the muscularis, retain their cubical epithelium and form the starting point for the post-partum regeneration of the mucous membrane.

The surface epithelium becomes flattened and loses its cilia (according to Marchand); furthermore, fat globules are formed in the cells and symplasmic formations occur, and toward the end of the third month the epithelium has practically disappeared. At the same time the cavity of the uterus, the *perional space* (the space surrounding the ovum (ὠόν): Webster), which has at this time only a potential existence, disappears as the capsularis comes into contact with the parietalis. The capsularis (Figs. 114 to 117), by stretching and by degeneration as well, has become greatly reduced and its remains now fuse with the decidua parietalis. The view that it remains recognizable as a streak of cells up to the close of pregnancy is probably based on an error, the chorionic

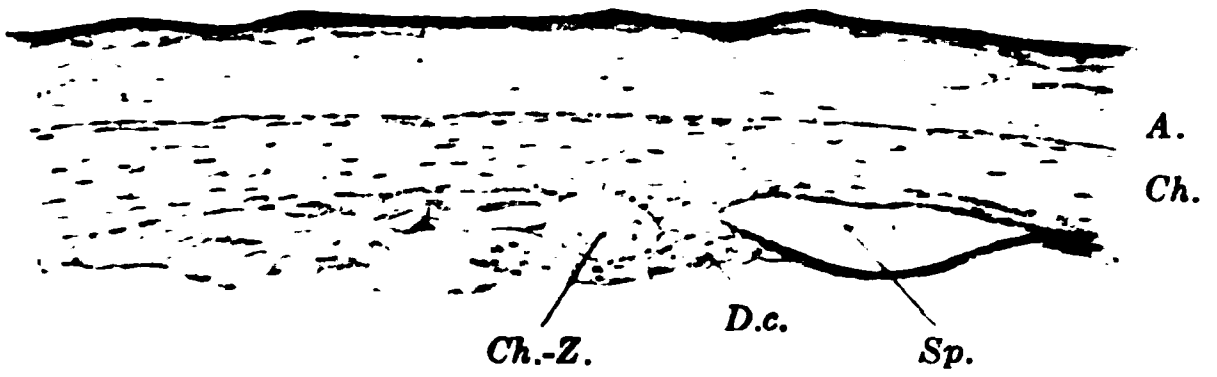

FIG. 116.—Egg membranes and decidua capsularis at the fourth month of pregnancy, from the region over the internal os uteri (from the same case as Fig. 118). *A.*, amnion; *Ch.*, chorion læve; *Ch.-Z.*, degenerated chorionic villus; *Sp.*, cleft (remains of the intervillous space?). × 70.

FIG. 117.—Section through the mature egg membranes with the adhering decidua, expelled spontaneously. *Amn.*, amnion; *Ch.-B.*, chorionic connective tissue; *Zw.*, intermediate zone (chorionic epithelium, remains of the villi, decidua capsularis, and decidua parietalis compacta); *D. sp.*, decidua parietalis spongiosa; *Dr.*, glandular remains. × 90.

epithelium being mistaken for it. The degeneration of the capsularis can be demonstrated beyond question in the region of the internal os uteri, where its fusion with the decidua parietalis is impossible. Even at the fourth month the capsularis (Fig. 116) consists in that region of only a very thin layer of flattened elements with some elongated clefts, probably remnants of the intervillous space. The *chorion læve* also shows extensive degenerative changes. The epithelium of the villi disappears, their stroma undergoes hyaline degeneration (Figs. 114 to 116), and between the hyaline masses so formed one finds the detritus of cells and leucocytes. At the summit of the ovum even these hyaline remains of the villi vanish (Fig. 117), but they persist in the neighborhood of the placenta. The epithelium of the chorionic membrane itself is, however, usually recognizable in the mature egg membranes; external to it is a zone of detritus with the remains of the villi, the capsularis, and the decidua parietalis compacta, in which also hyaline degeneration, as well as fusion and destruction of the cells, has occurred (Fig. 117). Still more externally are the remains of the spongiosa, which at the close of pregnancy is reduced to a thickness of 1–2 mm., but which still contains remains of the gland cavities. The fatty degeneration of the decidua parietalis, which was formerly regarded as the rule, occurs at most only in exceptional instances.

b. THE PLACENTA.

In the formation of the placenta the chorion frondosum and the decidua basalis participate, the former constituting the placenta fetalis and the latter the placenta materna.[44]

The *placenta fetalis* consists of the chorion plate and the chorionic villi; both contain a mesodermal stroma and an ectodermal (trophoblastic) epithelium.

The *stroma of the villi* is at an early period distinctly fibrillar and provided with fusiform cells in the principal stems and in the chorion plate; in the lateral branches it is at first formed of stellate cells with wide intercellular spaces, but even in these portions it soon assumes a fibrillar character. In the meshwork of the connective tissue there frequently occur in young ova lymphocyte-like structures and some especially large cells, with highly vacuolated plasma and large nuclei (Fig. 119), to which Hofbauer has called attention and which he brings into relation with the plasma cells. Their significance is, however, still uncertain. The capillaries of

---

[44] This latter term has varied somewhat in its significance. Kölliker terms the entire basalis the placenta materna and divides it into a *pars non caduca* seu *fixa*, which corresponds to the spongy portion, and a *pars caduca*, which is expelled at birth and is usually known as the basal plate. However, the latter alone is frequently termed the placenta materna.

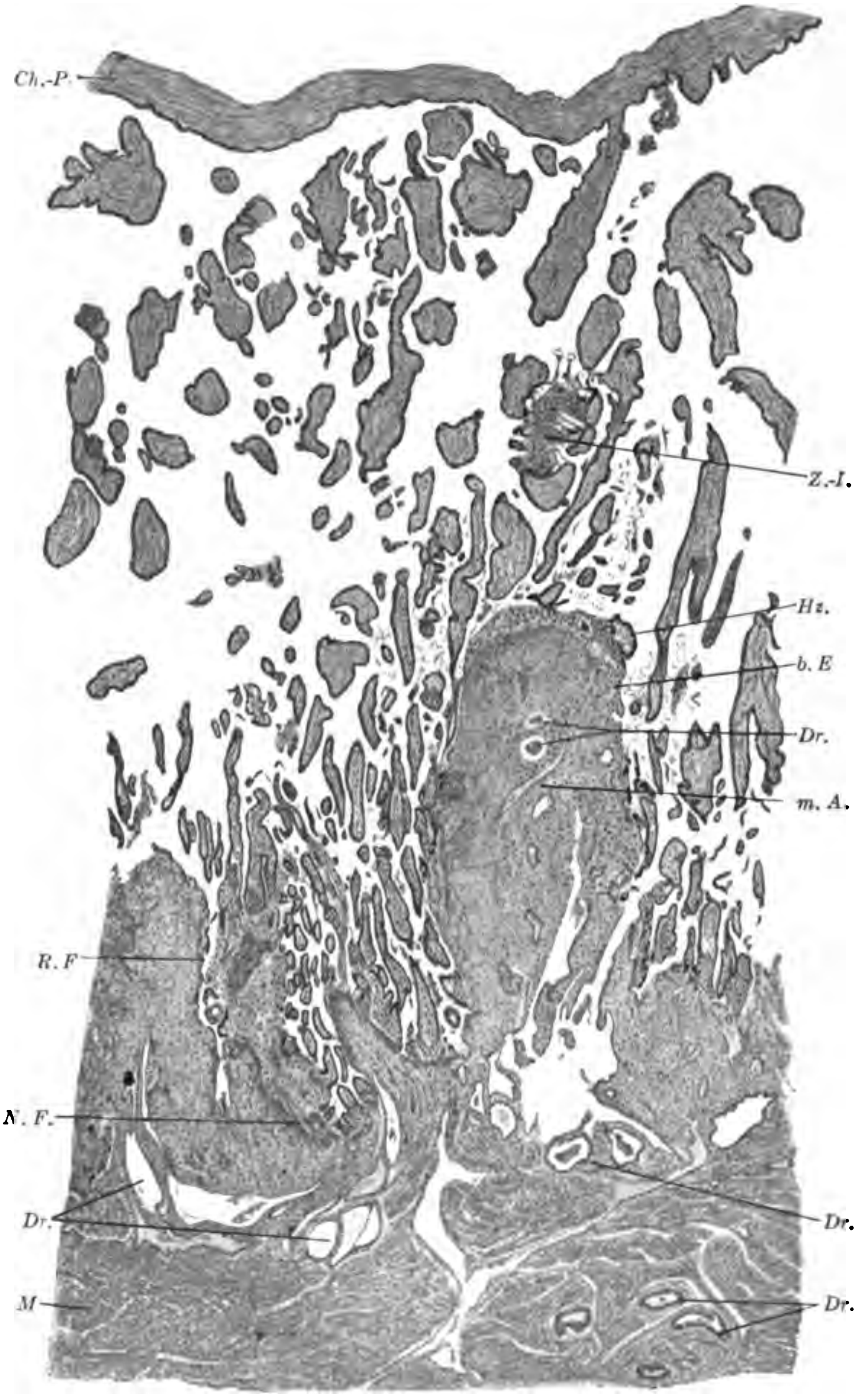

FIG. 118.—Anlage of the placenta from the second month. From a uterus obtained *per operationem*. The embryo had a vertex-breech length of 28 mm. The same case as is shown in Figs. 111, 119, and 136. *Ch.-P.*, chorion plate; *Dr.*, glands; *b. E.*, basal ectoderm; *Hz.*, anchoring villi; *M.*, muscularis uteri; *m. A.*, maternal artery in a placental septum (decidual pillar); *N. F.*, Nitabuch's fibrin stria; *R. F.*, Rohr's fibrin stria; *Z.-I.*, cell island. × 15.

the fetal vascular system lie, for the most part, near the surface of the villi. According to Bonnet (1903) lymph-vessels also occur in the stroma of the villi and can be followed to larger vessels in the chorionic membrane. Nerves are not recognizable in the

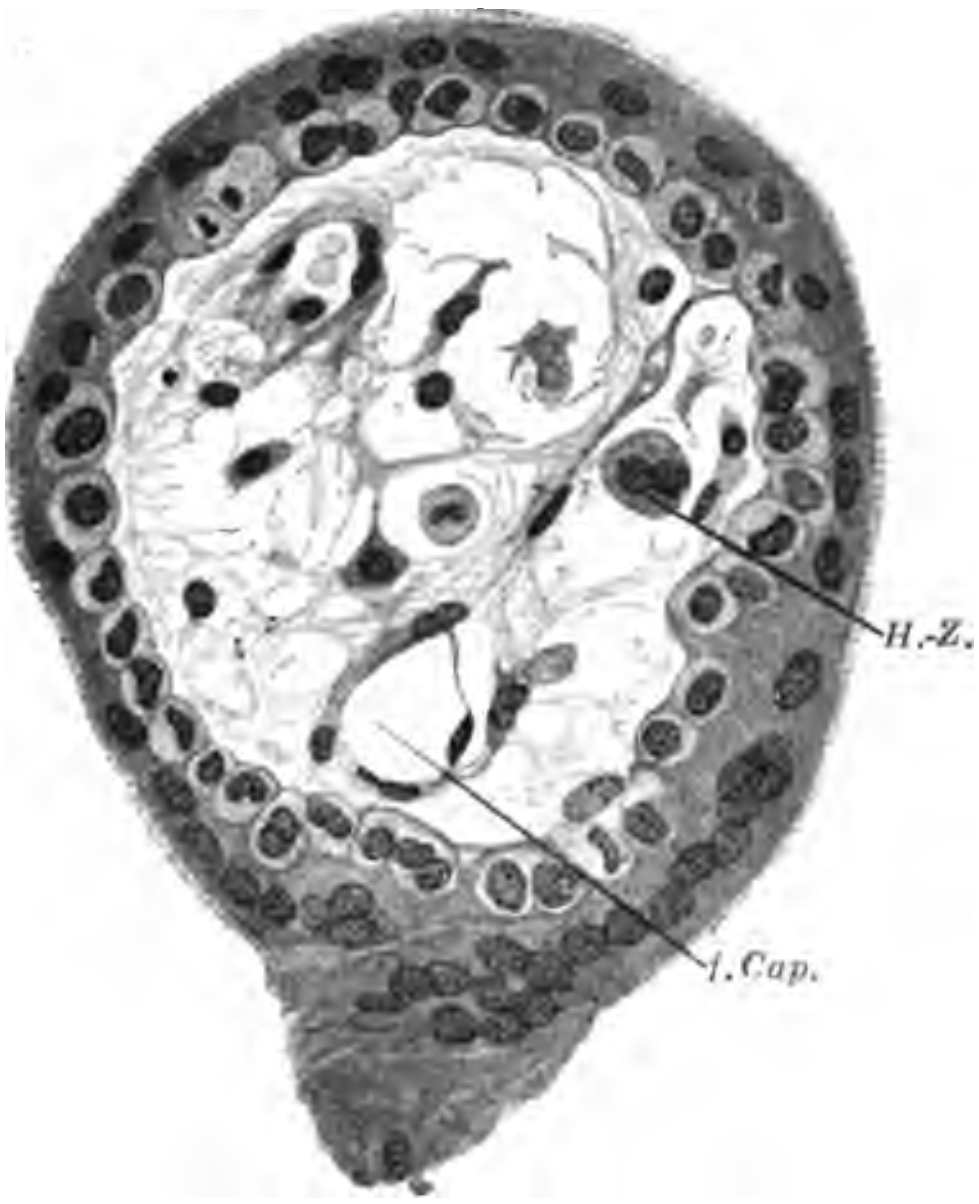

Fig. 119—Detail from Fig. 118. Chorionic villus from the second month; the syncytium provided with prickle processes. *f. Cap.*, fetal capillary; *H.-Z.*, Hofbauer cell. × 400.

Fig. 120.—Villi from a mature human placenta, injected with carmine and teased out in the fresh condition. × 30.

placenta (Bucura). Fossati has described a network of fibres, characterized by special histological peculiarities, as occurring around the chorionic vessels. In the stroma of the chorion plate

Langhans has described a more superficial subchorial vascular layer and a deeper fibrillar one, which shows no sharply defined boundary from the cœlom. These layers become distinguishable only at about the third month. Glycogen is found in young ova chiefly in the connective tissue of the chorion plate and of the larger villi (Happe, Driessen). (For further particulars concerning the stroma of the villi see Happe, 1907; and regarding elastic fibres consult Fuss, 1906.)

Fig. 121.—Injected villi from the mature human placenta; arteries dark, veins light. The apparently free endings of the vessels due to incomplete injection. Fresh preparation. × 350.

The *form of the villi,* which is determined largely by the stroma, changes during pregnancy in that, on the one hand, the branchings of the villi become continually more numerous and the villous trees larger, and, on the other hand, the branches themselves become more slender and longer (Fig. 120); yet even in the mature placenta variations in this respect occur. In each villus one or two arteries occur and one or two somewhat stronger veins, the two sets of vessels being connected by a capillary network lying immediately beneath the epithelium (Fig. 121). (Concerning the form of the villi see Minot, 1889, and Happe, 1907.)

The *chorionic epithelium,* as has already been stated, is two-layered after the formation of the villi (Fig. 129). The deeper layer, which is composed of distinctly separated cells, is usually named from its discoverer the *Langhans layer,* but is also termed the *cell layer.* The superficial layer is termed simply *syncytium* or also *syncytial layer* or *covering layer.*[45] The two layers together form the diplotrophoblast of Hubrecht. As a rule, the cells of the Langhans layer are arranged in contact with each other in an epithelial manner, but frequently the syncytium extends between the cells (Fig. 119) to the basement membrane of the epithelium (Bonnet, 1903). As a result of this it appears in places as if the cells were arranged in separate cell territories enclosed in a ground substance and with a kind of capsule or bounding layer. This condition is regarded as the rule by Happe (1907) among recent authors. The syncytium generally forms a layer of almost the same thickness as the cell layer and has but a single layer of nuclei. Vacuoles, that are so striking in the syncytium in early stages, are also to be seen at later periods and may be the expression of degeneration or of the absorption of material. On its outer surface it is provided with a delicate membrane, which proves to be composed of prickle processes, stiff hairs or rodlets, stereocilia (Graf Spee, Von Lenhossek, Bonnet). This membrane is perhaps existent only under certain functional conditions and cannot always be perceived; the rudimentary basal bodies described by Lenhossek as occurring in the cilia have not been found again by Bonnet. Indications of absorption in the form of fat globules, basophile granules, and mitochondria occur in the syncytium, and it takes up hæmoglobin in a soluble form. On its outer surface it frequently bears irregular, multinuclear elevations or buds (proliferation nodes; Fig. 122), which occasionally become separated and may be carried in the circulation far from the intervillous space (the deportation of syncytial elements of Veit). They are probably indications of amœboid activity which, in all probability, occurs in the syncytium.[46] Degeneration (the formation of symplasma syncytiale with spiny nuclei and the dissolving of the plasma into clouds or drops) may be observed, according to Bonnet, in the syncytium in younger stages; in older stages it takes on other forms (see p. 151).

---

[45] To the two layers of chorionic epithelium have been ascribed by different investigators very various and somewhat remarkable significances. For a review of the different origins suggested for the epithelium, which have been copied in a number of papers, see Waldeyer, 1890.

[46] Also entire villi may be torn away by the blood stream and enter the maternal vascular system.

Glycogen occurs in the cytotrophoblast (in the cell columns and cell islands, less regularly in the Langhans cells); it is lacking in the syncytium. It disappears completely with increasing maturity of the placenta (Driessen, Happe, 1907).

Mitoses occur only in the Langhans layer; in the syncytium only direct division occurs, and it is rare (Van Cauwenberghe). The direct passage of a cell from one layer into the other has not yet been observed in older stages and occurs only occasionally in younger ones (see p. 114). Nevertheless, the distribution of the nuclear divisions must be taken as evidence that even in later stages the cell layer is the source of the syncytium and adds to it. The older opinion of Kastschenko, which has recently been revived by Happe (1907), to the effect that the cell layer arises from the syncytium, seems to be overthrown by this. Between the syncytium and the cell layer there is, according to Graf Spee and Van Cauwenberghe, frequently but not regularly a cuticula or deep syncytial membrane, which, however, is believed by most other authors to be an artefact; beneath the cell layer is a basement or hyaline membrane. (For details concerning the epithelium of the villi see Marchand, Friolet, Van Cauwenberghe, Happe.)

FIG. 122.—From a mature placenta (after birth). Formalin. *f. G.*, fetal chorionic vessel; *m. B.*, maternal blood-corpuscles in the intervillous space; *Sy.*, syncytium; *Sy.-Sp.*, syncytial process (proliferation node). × 250.

In addition to the occurrence of proliferation nodes there is also another phenomenon that speaks in favor of amœboid activities in the syncytium; this is the relation of the *basal* (serotinal) or *syncytial giant cells* (Figs. 123 and 124). In the decidua basalis one finds even in young stages multinucleated masses of protoplasm which cannot be distinguished histologically from syncytium and are of great importance in connection with the significance of the syncytium. In the Frassi ovum they are throughout (except at one doubtful spot) in connection with the syncytium of the villi, but in the preparations of Beneke, Pfannenstiel, and Friolet, for example, free masses of syncytium occur in the decidua basalis—indeed, even in the superficial layers of the muscularis and frequently in the neighborhood of vascular endothelium. They are most frequent at about the middle of pregnancy, when they may reach a very considerable size (Fig. 123) and may penetrate far into the muscularis (Fig. 124); nevertheless their abundance is subject to rather great individual variations. Toward the end of pregnancy they diminish in number. Pfannenstiel finds support, in their occasional topographic relations to the vascular endothelium, for the derivation of the entire syncytium from the endothelium; but syncytial growths arising from endothelia are denied by Friolet and Frassi. Friolet leaves the possibility of their origin from the connective tissue an open question; Pels Leusden, Webster, Frassi, and others regard them as derivatives of the (fetal) syncytium, that penetrate individually into the maternal tissues,[47]

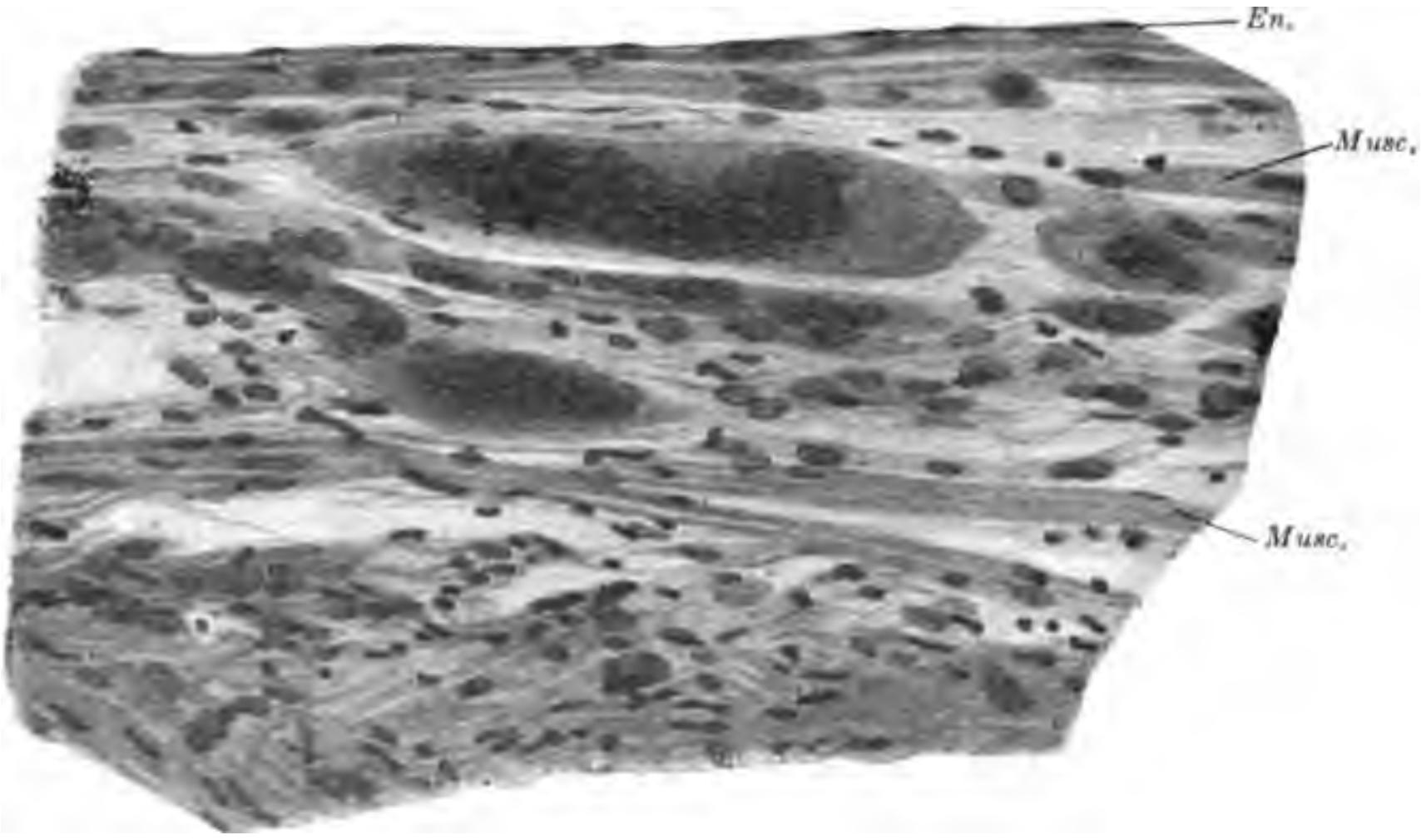

FIG. 123.—Giant cells beneath the placenta in the muscularis uteri in the fourth month. *En.*, endothelium of a vein of the muscularis; *Musc.*, smooth muscle bundle. × 300. From the same case as figs. 130 and 131.

---

[47] That they may also penetrate toward the centre of the ovum is indicated at present only by the very definite statement of Beneke (p. 115). Siegenbeek also records the remarkable occurrence of a syncytium mass between the chorionic epithelium and connective tissue, but considers it to have occurred by active immigration into the ovum through a tear in its wall, which he assumes to have occurred during life.

and this view is certainly the most probable. The fact, also, that they degenerate post partum, without taking any part in the regeneration of the mucous membrane, is in favor of this view (Wormser).

FIG. 124.—Placenta *in situ* from the second half of pregnancy, with numerous subplacental syncytial giant cells. *D.b.*, decidua basalis; *Dr.*, glands; *Gef.*, maternal vessels; *Hz.*, anchoring villi; *Musc.*, muscularis uteri; *N. Fs.*, Nitabuch's fibrin stria; *s. Rz.*, syncytial giant cells; *V.*, larger uterine vein. × 27.

Even in the fourth month the cell layer is present only in patches, the syncytium resting, for the most part, directly on the stroma of the villi. Toward the end of pregnancy individual Langhans cells are still to be found beneath the syncytium, according to Van Cauwenberghe, yet this is certainly a by no means frequent occurrence. The layer is partly spread out and stretched over a constantly increasing area by the growth of the villi and is partly used up in the formation of syncytium (Fig. 122). The syncytium also frequently shows signs of degeneration; it becomes greatly attenuated and may even be wanting at many places on the surface of the villi. In such cases so-called placental fibrin occurs on the villi.

This "fibrin" has also frequently been the object of investigation and of controversy. In quite young ova (Peters, Leopold) it does not occur; in older ones, in which the intervillous space has formed, it first appears usually as a stria situated some distance from the space in the basalis or even in the capsularis.

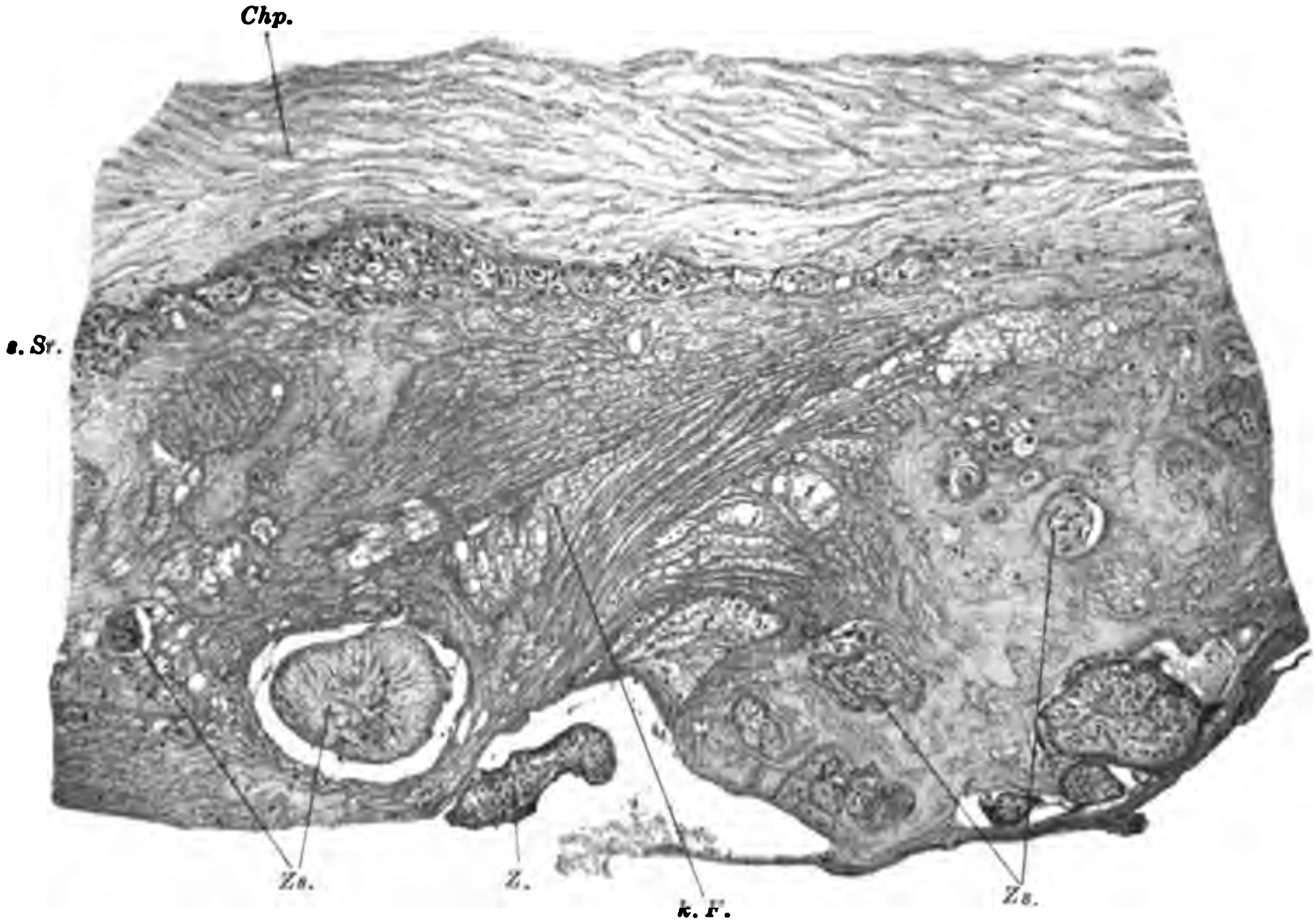

FIG. 125.—Chorion plate with subchorial closing ring and "canalised fibrin," from a mature placenta. *Chp.*, chorion plate; *k. F.*, canalised fibrin; *s. Sr.*, subchorial closing ring; *Z.*, villus; *Zs.*, connective-tissue stroma of degenerating villi. × 80.

The time of its appearance does not seem to be constant (see p. 127); but having once appeared it persists until the close of pregnancy. It was first described in a dissertation written by one of Langhans' pupils and was named, from the authoress of the paper, *Nitabuch's fibrin stria.* A second stria also occurs, though not constantly, immediately in the wall of the intervillous space and has been termed *Rohr's stria*[48] (Fig. 118). In addition, there is a third stria which is constant in its occurrence close beneath the chorion plate; it appears, however, later, only in the second half of pregnancy, and is known as *Langhans' stria.* In the same region is to be found especially the *"canalized fibrin"* of Langhans (Fig. 125), and, finally, quantities of fibrin occur everywhere

---

[48] Rohr himself names this the *upper stria,* terming Nitabuch's the *lower stria.*

in the mature placenta and between the villi; these fibrin masses are, for the most part, microscopic in size, but frequently increase to extensive structures. The small ones are termed *fibrin nodes,* and the larger are known as white *infarcts.* The latter may occasionally form almost half the mass of the placenta.

Langhans and his pupils regard the Nitabuch stria as marking the boundary between the maternal and fetal tissues. It is certain that it occurs in the transition zone and that the maternal tissues that may be between it and the ovum quickly degenerate. Jung derives the stria from the boundary zone of the maternal tissue (see p. 115). It is at all events basal to typical decidual tissues, and is between the ovum and the basal ectoderm and degenerating tissue, whose origin cannot always be certainly ascertained. It is traversed by maternal (uteroplacental) vessels. That it is practically the boundary between the mother and the ovum is also

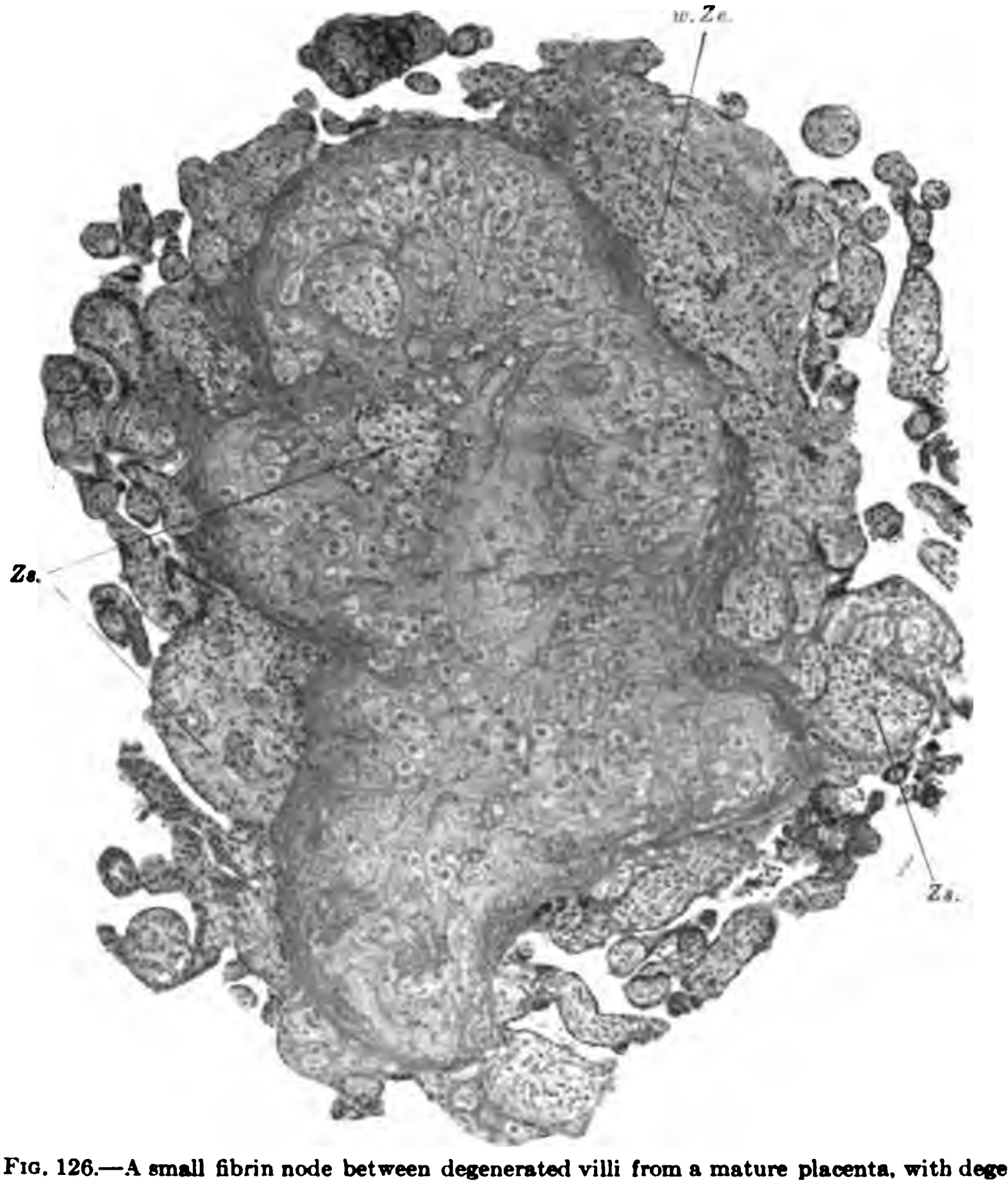

FIG. 126.—A small fibrin node between degenerated villi from a mature placenta, with degenerating masses of trophoblast. *w. Ze.*, proliferating epithelium of villi; *Zs.*, connective-tissue stroma of villus. × 90.

shown by its relations to the leucocytes; these, as a rule, do not pass beyond the stria. The fibrin of the Nitabuch stria is apparently the first to appear in the placenta, yet the methods for detecting the material in other portions of the placenta are insufficient. In general this so-called fibrin is by no means typical blood-fibrin, it shows only occasionally the histological reactions of fibrin. Hitschmann and Lindenthal believe that the fibrin reaction is shown only at the commencement of its formation, and that it later alters with age. It would be better, therefore, to designate the substance by some indifferent term, such as *fibrinoid* or fibrinoid substance. At all events, the stimulus for the formation of fibrinoid is afforded by degenerative changes, those occurring in the decidua and chiefly in the region of the basalis being responsible for the formation of the Nitabuch stria and the smaller basal fibrin masses; yet the amount of participation of the individual tissues of that region cannot as yet be strictly defined. At other places the trophoblast must be regarded as the seat of the fibrin formation; for very large quantities of fibrin are found at places where the decidua is wanting, as, for instance, beneath the chorion and between the villi. The maternal blood may also participate, forming true fibrin; examples of this are shown in places where the fibrin contains red and white blood-corpuscles. It is also possible that the blood fibrin may become so altered in course of time that it can no longer be detected by the usual histochemical methods. It may be such fibrin that occurs in the decidua basalis and in the white infarcts, deposited as the result of the disturbances in the circulation produced by the degeneration of the epithelium of the villi and the fusion of these structures, or as a result of the imperfect outflow of blood from the intervillous space produced by villi being carried into the maternal veins, as Giese suggests. The subchorial "canalized fibrin" also presents a peculiar layered structure (Fig. 125), which may be explained as the result of the deposition of successive layers of blood fibrin, especially since the blood stream is undoubtedly greatly retarded in the roof of the intervillous space.[49]

The derivation of fibrinoid from the trophoblast is based upon the study of the formation of fibrin nodes on the villi; and it is also supported by what can be seen in the formation of the Langhans stria. In the villi one finds the first stages of fibrinoid formation partly between the syncytium and the connective-tissue stroma, partly where the epithelium of the villi has almost disappeared, as it does in every mature placenta. The occurrence of the fibrinoid between the syncytium and the stroma points to the cell layer as the seat of its formation, and this indication becomes

---

[49] Langhans spoke of the canalized fibrin as a tissue; but this conception of it is incorrect, since it cannot be considered as living material.

stronger in regions where the villi are closely packed together at the time when the fibrin formation begins. One can then observe how the formed masses of fibrin produce a cohesion of the villi and how the Langhans cells occur between the fibrinoid and the stroma of the villi; also in the mature placenta the Langhans cells, practically wanting elsewhere, may be seen at the surface of the villi (Fig. 127), usually in a continuous and sometimes in a double row; and, furthermore, these cells occur free in the formed fibrinoid, where they become vesicular in appearance and gradually lose their staining properties, persisting for some time as "ghosts" of their former selves and eventually becoming completely converted into fibrinoid. The process of conversion cannot be termed a direct necrosis of the cells; it has great similarity to what is seen in the

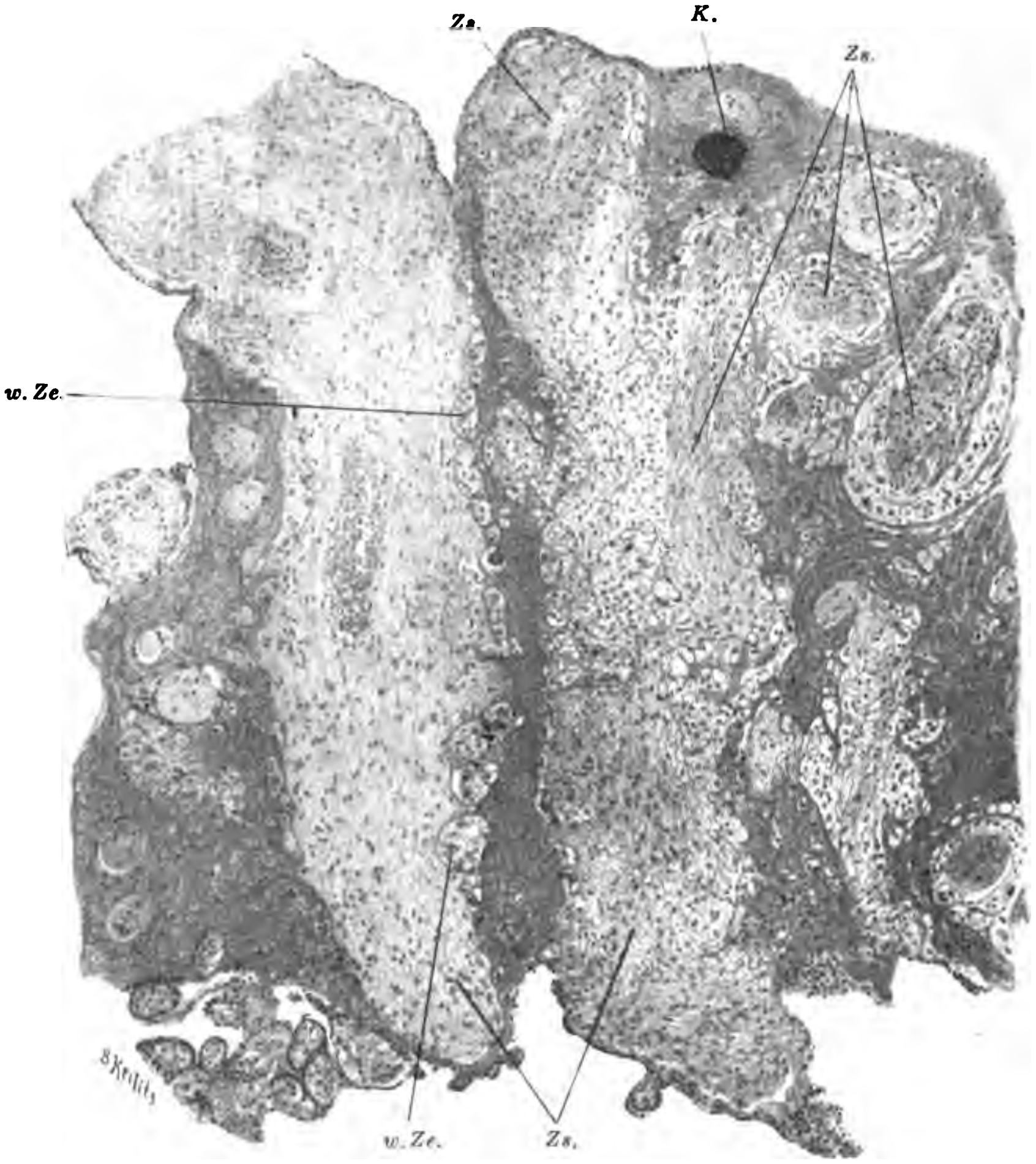

FIG. 127.—The formation of fibrin between fused villi of the mature placenta, with proliferation and degeneration of the epithelium of the villi (trophoblast). *K.*, calcareous deposit; *w. Ze.*, proliferating epithelium of villi; *Zs.*, connective-tissue stroma of villi.

formation of the matrix of many kinds of connective tissue, as, for instance, when cells and even whole cell territories become transformed into matrix in some kinds of cartilage. It is a process apparently intermediate between secretion and the direct transformation of the peripheral portions of the cells, and by the continuation of it the entire cell becomes transformed. The fibrinoid so formed lacks the property that inhibits coagulation and that is possessed by the living epithelium of the villi, and so the mass of the fibrin node is increased by the formation of fibrin from the blood. Whether the syncytium also takes a direct part in the formation of fibrinoid, or degenerates, or, perhaps, first divides into separate cells which are then transformed into fibrinoid, has not yet been determined. The degenerating stroma of the villi later undergoes a very similar (hyaline) transformation and disappears in fibrinoid.

The chorion plate is the seat of formation of the Langhans fibrin stria. In it even in the fourth month a partial transformation of the epithelium into fibrinoid can be detected, and in the sixth month the epithelium in the middle of the placenta is replaced by the fibrin stria. The lack of epithelium, on the one hand, and the retarded blood flow, on the other, then produce blood coagulation in layers, the result being canalized fibrin.

An important source of fibrinoid is to be found in the cell islands, that are so frequent in the first month and later disappear. In these also the beginning transformation into fibrinoid is evident very early (Fig. 108). Possibly these trophoblast masses give a stimulus for the formation of the larger fibrin masses.

The description of fibrin formation given above resembles closely that given by Schickele. The derivation of the fibrin from the trophoblast, in part at least, has also been maintained, among others, by Kermauner, Hitschmann and Lindenthal, and Giese. These authors advocate even more strongly than has been done above the occurrence of disturbances in the circulation and the formation of fibrin from the blood. Steffeck (1890) has derived all the fibrin from proliferated decidua, a view that is to-day untenable; he has apparently throughout mistaken the swollen degenerating trophoblast cells for decidua cells.

The transformation of the trophoblast may, however, be carried even further and produce a liquefaction of the formed fibrin; thus arise the *placental cysts* which are of very frequent occurrence in mature placentæ. Superficially situated cysts, occurring in the Langhans stria, may reach the size of a hazel-nut or even larger; more frequently are small microscopic cysts in the middle of the tissues (Fig. 128). They are always enclosed within a mantle of fibrinoid containing degenerating trophoblast cells and are frequently lined by a flattened, endothelium-like layer of these cells (Giese).

The white infarcts form, as the result of a combination of fibrinoid and blood-fibrin formations, larger solid masses, which may enclose large villi, causing the degeneration and death of their connective tissue, which eventually becomes unrecognizable as such. The destruction of the connective tissue and chorionic vessels in the infarct is, however, a secondary process, and not primary, as Ackermann supposed, since the villi are nourished from the intervillous space and not by the chorionic vessels (see p. 164).

Red infarcts, which are of much rarer occurrence and owe their name to their color, are due to mass coagulation of the blood in the intervillous space.

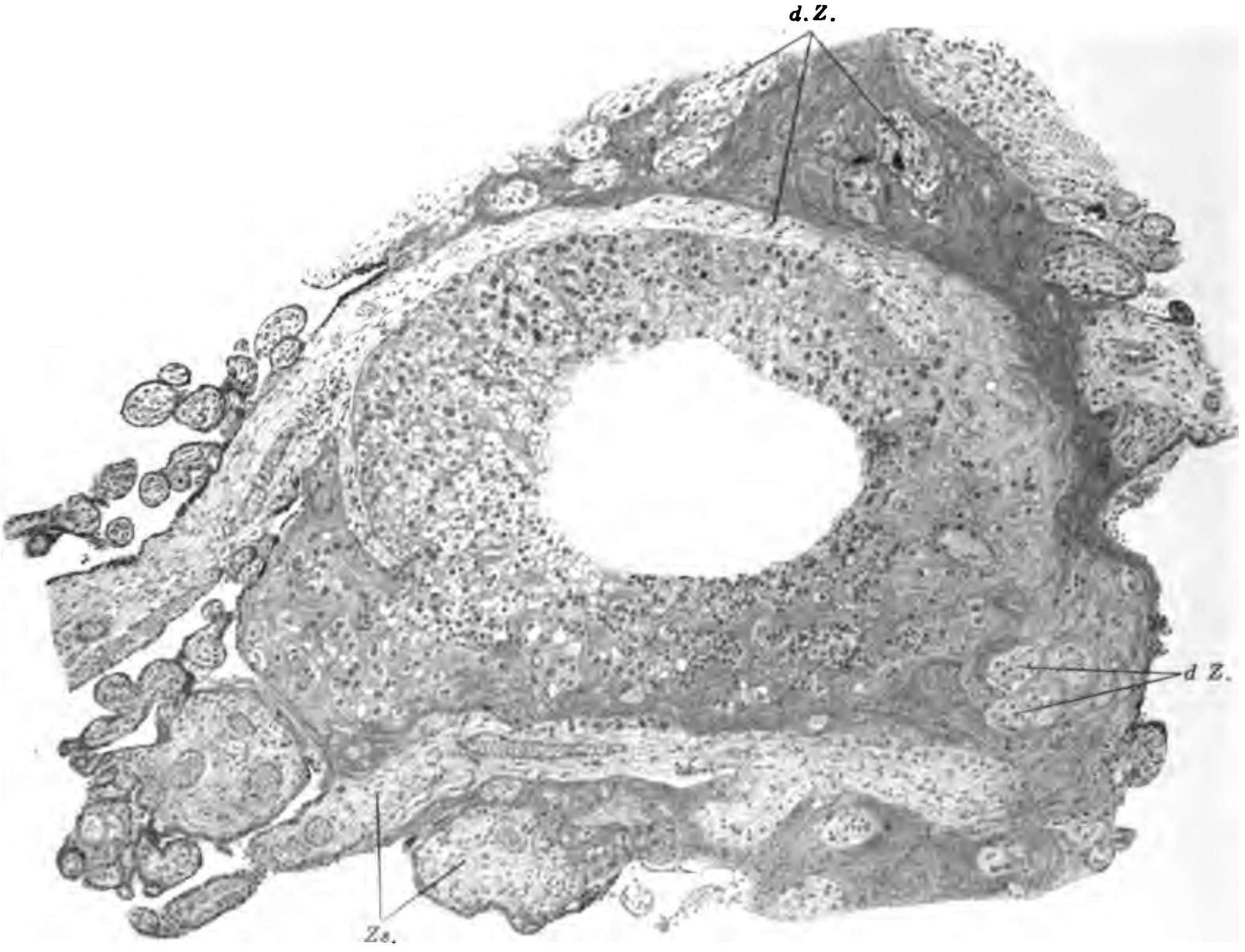

Fig. 128.—Small cyst in a fibrin node, from a mature placenta. Around the cyst are degenerating masses of trophoblast. *d. Z.*, degenerating villi; *Zs.*, connective-tissue stroma of villi. × 90.

It is generally supposed that the cytotrophoblast, with the exception of some scattered Langhans cells lying beneath the syncytium of the villi, has entirely disappeared in the mature placenta; in speaking of the formation of fibrinoid, however, attention has been called to the occurrence of isolated trophoblast cells, and they are to be found rather constantly in two other situations: in the floor of the intervillous space, their occurrence in this region will be discussed in connection with the description of the decidua basalis; and in the region of the *subchorial closing ring* (Waldeyer). In this region they form a cell plate of varying breadth, circular, in correspondence to the margin of the placenta, and often wanting; when present, however, it lies between the chorionic connective tissue and the Langhans fibrin stria, extends inwards from the margin for about 1–2 cm. and laterally passes over insensibly into the epithelial layer (p. 143) which persists on the outer surface of the chorion læve (Fig. 125). The closing ring is the remains of the epithelium of the chorion plate, which further in has completely disappeared, that is to say, has become completely transformed into fibrinoid, and at the margin of the placenta has, it is true, lost its syncytium and has formed fibrinoid, but yet has largely persisted or has even become many-layered as the result of proliferation. In these cells, even in the mature placenta, the transformation into fibrinoid can be observed, and the cell plate is usually not continuous, but shows local defects (Fig. 129).

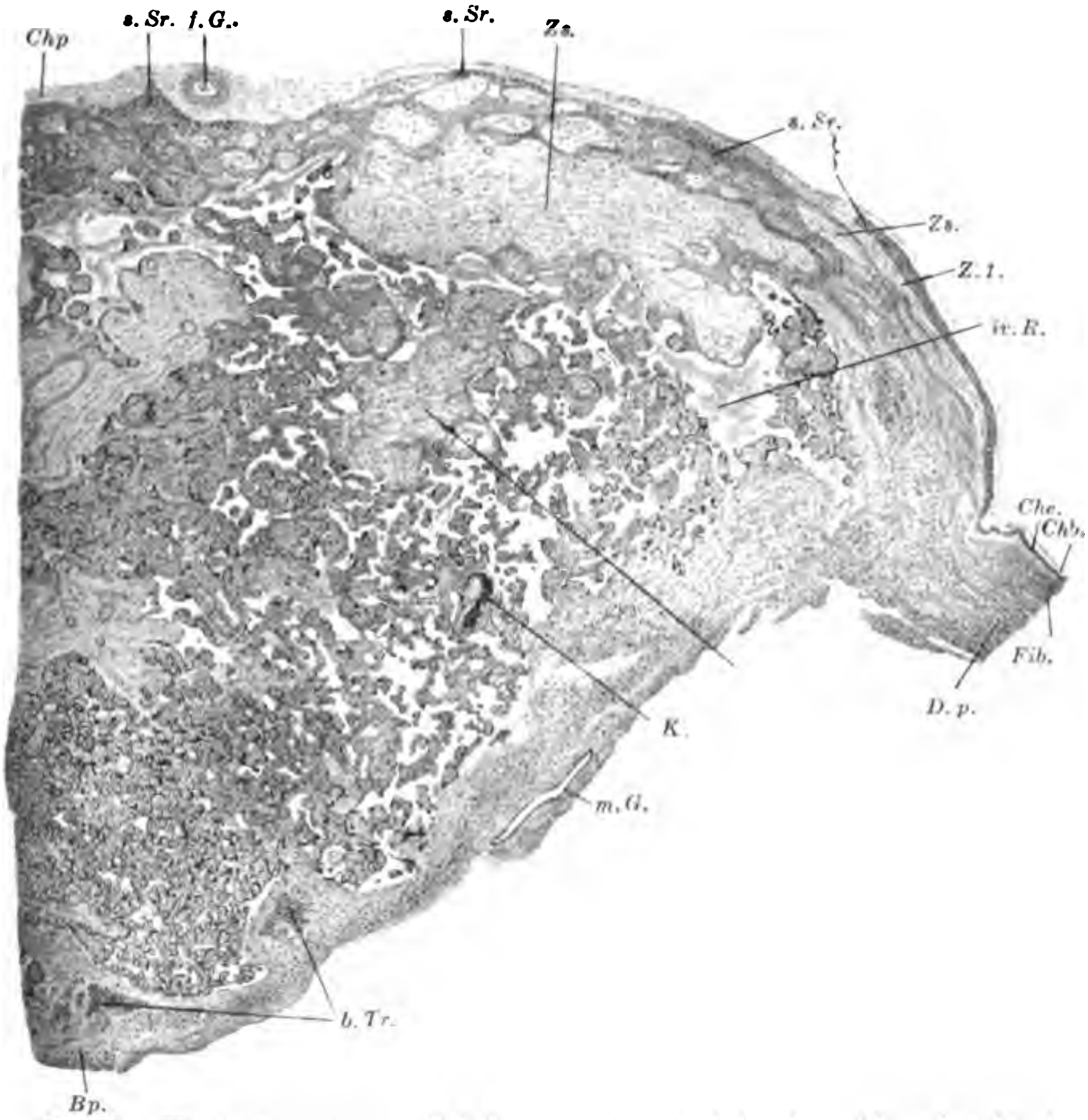

FIG. 129.—Margin of a mature expelled placenta. A marginal sinus has not formed at this place. **Bp.**, basal plate; *Chb.*, *Che.*, chorionic connective tissue and epithelium belonging to the chorion læve; **Chp.**, chorion plate; *D. p.*, decidua parietalis (and capsularis); *Fib.*, fibrin; *f. G.*, *m. G.*, fetal and maternal vessels; *I.*, infarct; *K.*, calcareous deposit; *iv. R.*, intervillous space; *s. Sr.*, subchorial closing ring, frequently interrupted; *b. Tr.*, remains of basal trophoblast; *Z. 1.*, villus which traverses the subchorial closing ring; *Zs.*, connective-tissue stroma of villi. × 17.

Winkler originally described a continuous plate of cells as existing beneath the connective tissue of the chorion plate, naming it the *closing plate* and deriving it from the decidua. Kölliker pointed out that a complete plate does not exist and speaks of a *decidua subchorialis* occurring at the margin of the placenta, and by this name the tissue is now generally known. Pfannenstiel endeavors to explain it as produced by an undermining of the marginal decidua by the marginal villi. The idea of a decidual origin for the layer is based upon the pale and swollen appearance of the cells, but this, as has already been several times noted, is not a proof of its origin. Langhans in 1877 expressed doubts as to the decidual nature of the layer and later (1891) decided in favor of an ectodermal origin; Hitschmann and Lindenthal agree with him in this. In the mature placenta the closing ring is occasionally broken through by villi (Fig. 129), which are usually atrophic and belong to the portion of the chorion which is transitional between the chorion frondosum of the placenta and the chorion læve, and this fact is sufficient in itself to overthrow the idea that one has to deal with an undermined marginal decidua. There remains, therefore, for consideration only the assumption of an active growth on the part of the decidua cells of the placental margin towards the middle of the placenta, a supposition which has little probability on account of what has already been said as

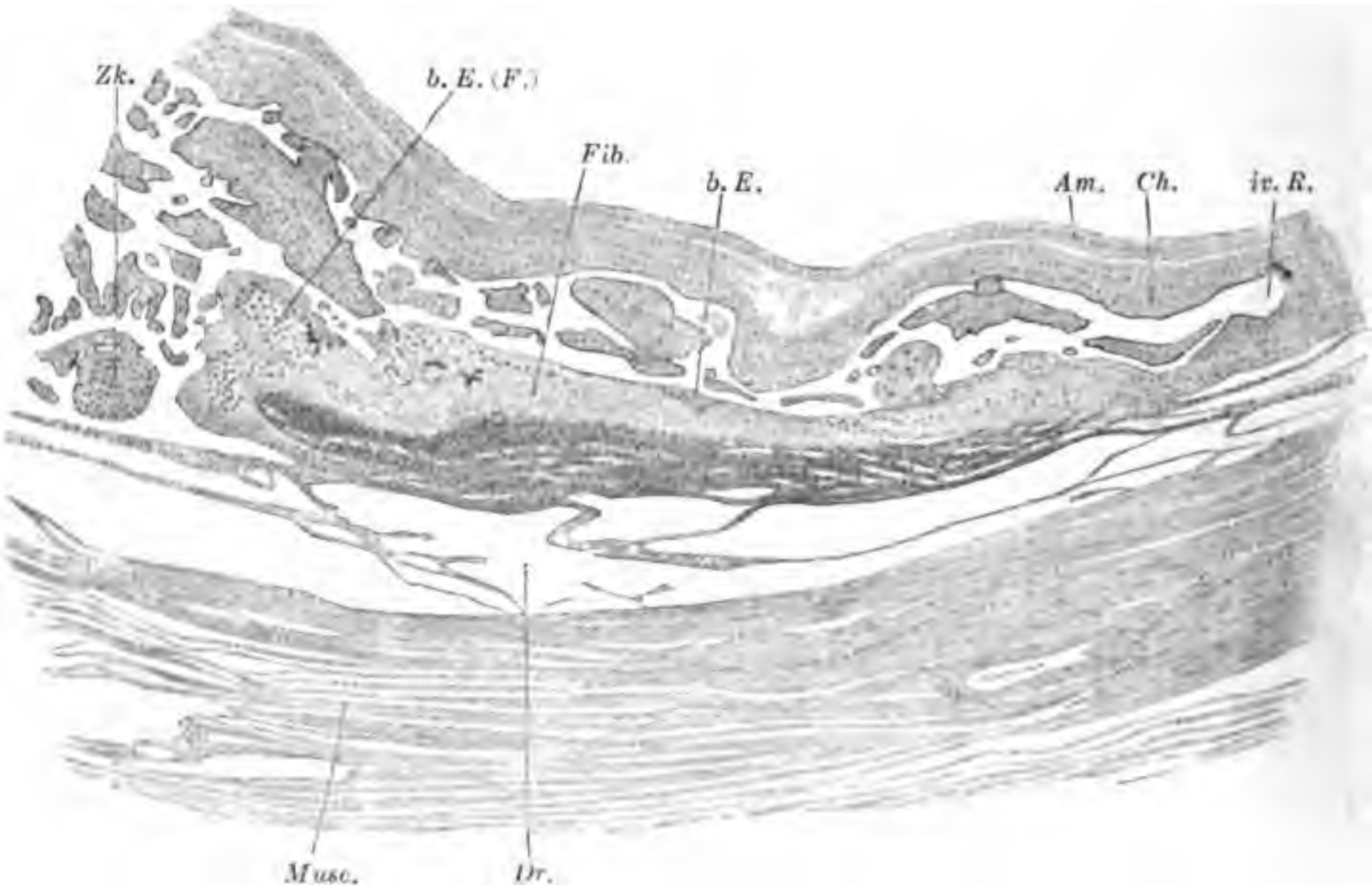

FIG. 130.—Margin of a placenta of the fourth month (vertex-breech length of the embryo 13½ cm.). A decidua subchorialis is wanting. The gland cavities of the spongiosa (*Dr.*) have been separated in the preparation. *Am.*, amnion; *Ch.*, chorion; *b. E.*, basal ectoderm; *b. E.* (*F.*), basal ectoderm in process of transformation into fibrinoid; *Fib.*, fibrinoid; *Musc.*, muscularis; *iv. R.*, intervillous space; *Zk.*, cell nodes. × 18.

to the degeneration of the decidua in the later stages of pregnancy. But in addition this possibility is also excluded by the study of the margin of the placenta in different months of pregnancy. This shows (*cf.* Fig. 130) that the transition of the placenta into the chorion læve during the progress of pregnancy is a gradual one and the two structures are first sharply marked out towards the end of it. Normally a proliferation of the marginal decidua or an undermining of it is never to be seen; but, on the other hand, such preparations directly show the gradual degeneration of the epithelium of the chorion plate in the middle of the placenta and its transformation into the subchorial closing ring at its margin.

Perhaps a portion of this epithelium may persist throughout the entire extent of the placenta, just as it does at its margin; at least this would explain cases such as that described by Steffeck, in which an actually complete subchorial epithelial plate is said to have been present, and which was identified by that author as decidua. The conditions in a placenta marginata are quite different, for this may well owe its origin to an actual undermining of the marginal decidua (*cf.* Pfannenstiel, 1903, and Grosser, "Lehrbuch").[50]

The *decidua basalis* (*placenta materna*) is divisible in later stages of pregnancy into a compact layer, the *basal plate* of the placenta, and a spongy layer. The former, which closes the intervillous space on the basal side, is formed from the portion of the premenstrual compacta that is not destroyed by the ovum during implantation; the latter is formed from the premenstrual spongiosa. This shows (Figs. 118 and 124), in general, the same changes as the decidua parietalis spongiosa; only the layer is thinner, and the gland spaces appear to be less frequent, perhaps because some of the glands, which in the early stages of the development were filled with blood, have degenerated; between the glands are the syncytial giant cells already mentioned. The basal plate (Figs. 131 and 132) consists of decidua, which toward the end of pregnancy again contains more fusiform cells, and also of the fibrin striæ already described and of the remains of trophoblast derived from the basal ectoderm and the cell columns of the anchoring villi. These trophoblast remains, again, are partly syncytial in character and partly appear as large, swollen, mononuclear cells (mononuclear giant cells) similar to those found in the early stages of fibrinoid formation in other places; these cells

---

[50] Sfameni takes a different view of the origin of the placenta marginata. He refers it to a lack or insufficiency of pressure within the ovum and to insufficient stretching of the wall of the uterus. Compare also Krömer (1907) and Liepmann (1906), as well as the polemic of these authors in Centralbl. f. Gynäk., vol. xxxii, 1908.

lie, sometimes singly and sometimes in groups, in degenerating tissue and in later stages may extend peripherally beyond the Nitabuch stria. The trophoblast masses are no longer, however, in direct connection with the anchoring villi; the tips of the latter usually dip into masses of fibrinoid, which extend to the stroma of the villi. Frequently this is more or less degenerated, as it is in the infarcts.

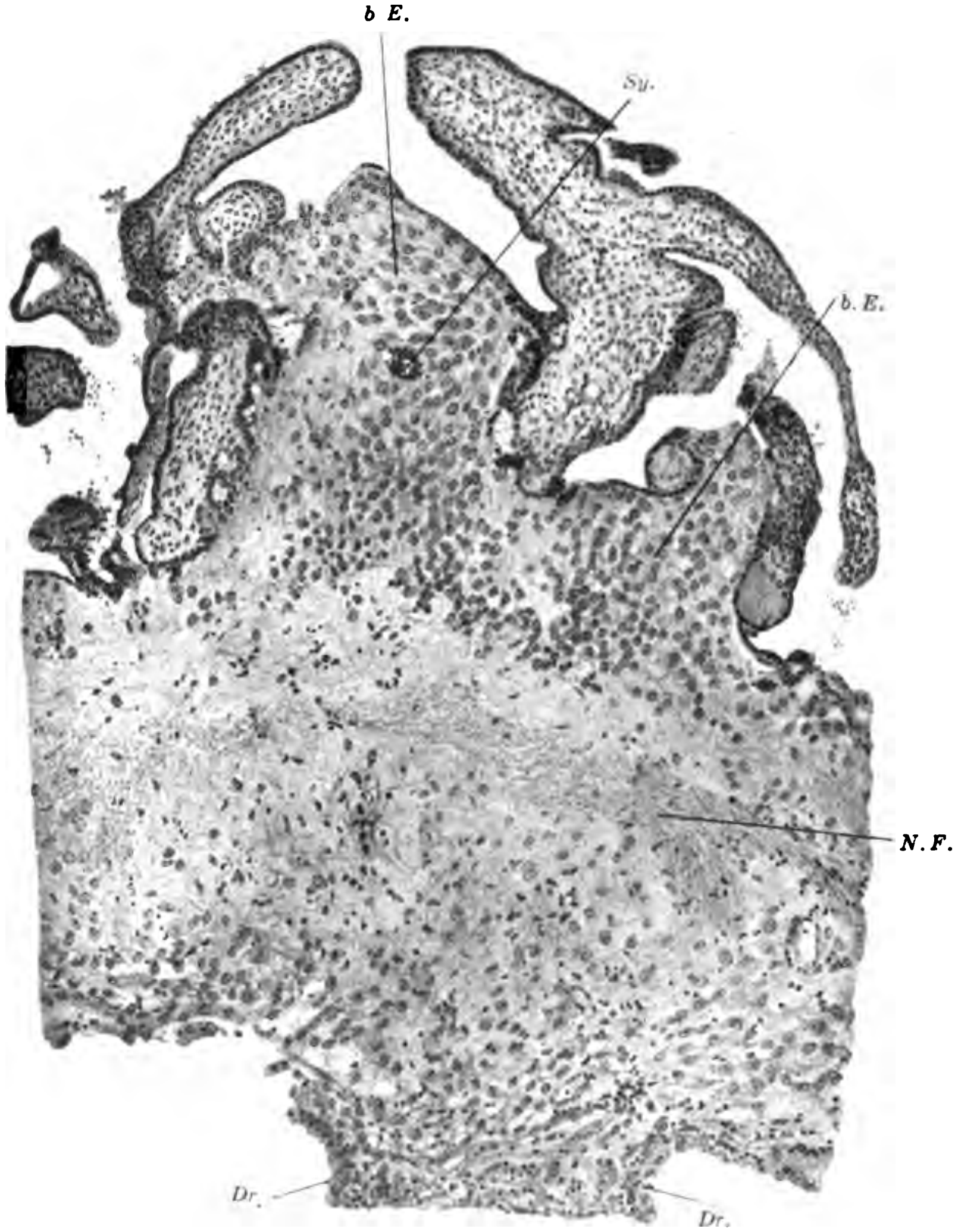

Fig. 131.—Anchoring villi and basal plate of the placenta in the fourth month. From the same case as Fig. 130. (Vertex-breech length of embryo, 13½ cm.) *b. E.*, basal ectoderm; *Dr.*, glands; *N. F.*, the Nitabuch fibrin stria; *Sy.*, syncytium × 80.

In the basal plate there also occur the so-called *choriodecidual vessels* (Ruge). They are relatively large stems, visible to the naked eye in the expelled placenta, provided that they are well filled with blood, or, better, injected from the vessels of the villi; they pass out from the villi, and either terminate in the basal plate or enter the stem of a villus ascending from the basal plate. This fact indicates that the villi concerned have come into contact with the basal plate and have lost their epithelium and stroma by degeneration, while their vessels have persisted and have become enlarged by the blood-pressure, partly on account of degeneration in their walls. Usually remains of trophoblast and of the stroma of villi (Fig. 133) are to be found in the neighborhood of the vessels, provided their entire surroundings have not been transformed into a fibrinoid mass.

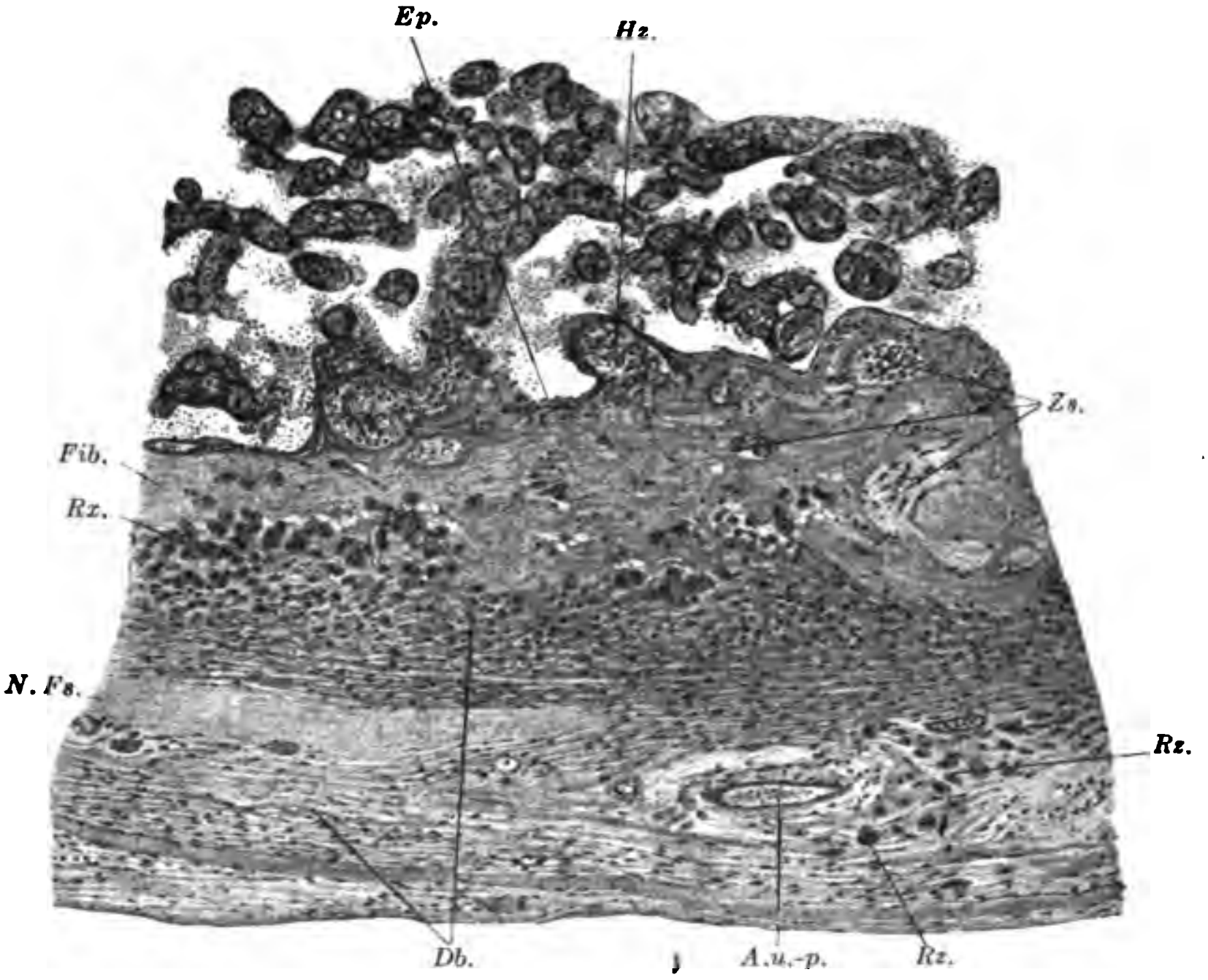

FIG. 132. — Basal plate of mature expelled placenta. *A.u.-p.*, arteria uteroplacentalis; *Db.*, decidua basalis; *Ep.*, epithelial remains in the floor of the intervillous space; *Fib.*, fibrin; *Hz.*, anchoring villus; *N. Fs.*, the Nitabuch fibrin stria; *Rz.*, mononuclear giant cells (remains of trophoblast); *Zs.*, connective-tissue stroma of villi enclosed by fibrin. × 70.

Ruge believed that his discovery of these vessels indicated a vascularization of the decidua, that is, of maternal tissues, by fetal vessels; the explanation given above has already been advocated by W. Wolska, working under Langhans' directions, and has been confirmed by other authors. The statement, which has appeared in some articles, to the effect that Ruge has described an anastomosis of fetal and maternal vessels, is erroneous.

From the basal plate there extend towards the intervillous space the *decidual pillars,* which represent the *septa placentæ* of later stages. The decidual pillars (Fig. 118) are to be regarded as portions of the decidua basalis compacta which have been spared during the penetration of the trophoblast. In structure they resemble the basal plate. As regards their number and arrangement in young stages adequate investigations are as yet lacking. Occasionally, but certainly not frequently, the pillars seem to project for a considerable distance into the intervillous space, even to near the chorion plate, and, in sections, appear to have no connection with the basal plate, so that they seem to be "decidua islands" or *decidual trabeculæ* (Leopold). (That free decidua islands do not, in all probability, occur has already been noted.) The septa placentæ in later stages and at the close of pregnancy divide the placenta into separate lobes or cotyledons, which do not, however, represent closed areas, since the septa in the middle of the placenta are very low and even at the margin reach the chorion plate only in small part. The original formation of these septa from decidua cells is almost always very difficult of determination in the mature placenta (Fig. 134). The decidua cells have, for the most part, degenerated and disappeared, and in their place there remains only an empty mesh-work, into which the trophoblastic anchoring villi penetrate. These frequently grow completely through the septa, so that again fibrinoid formation and also the inclusion of neighboring villi, together with their stroma, may be found in the septa. Many septa at the close of pregnancy seem to be composed entirely of fetal elements.

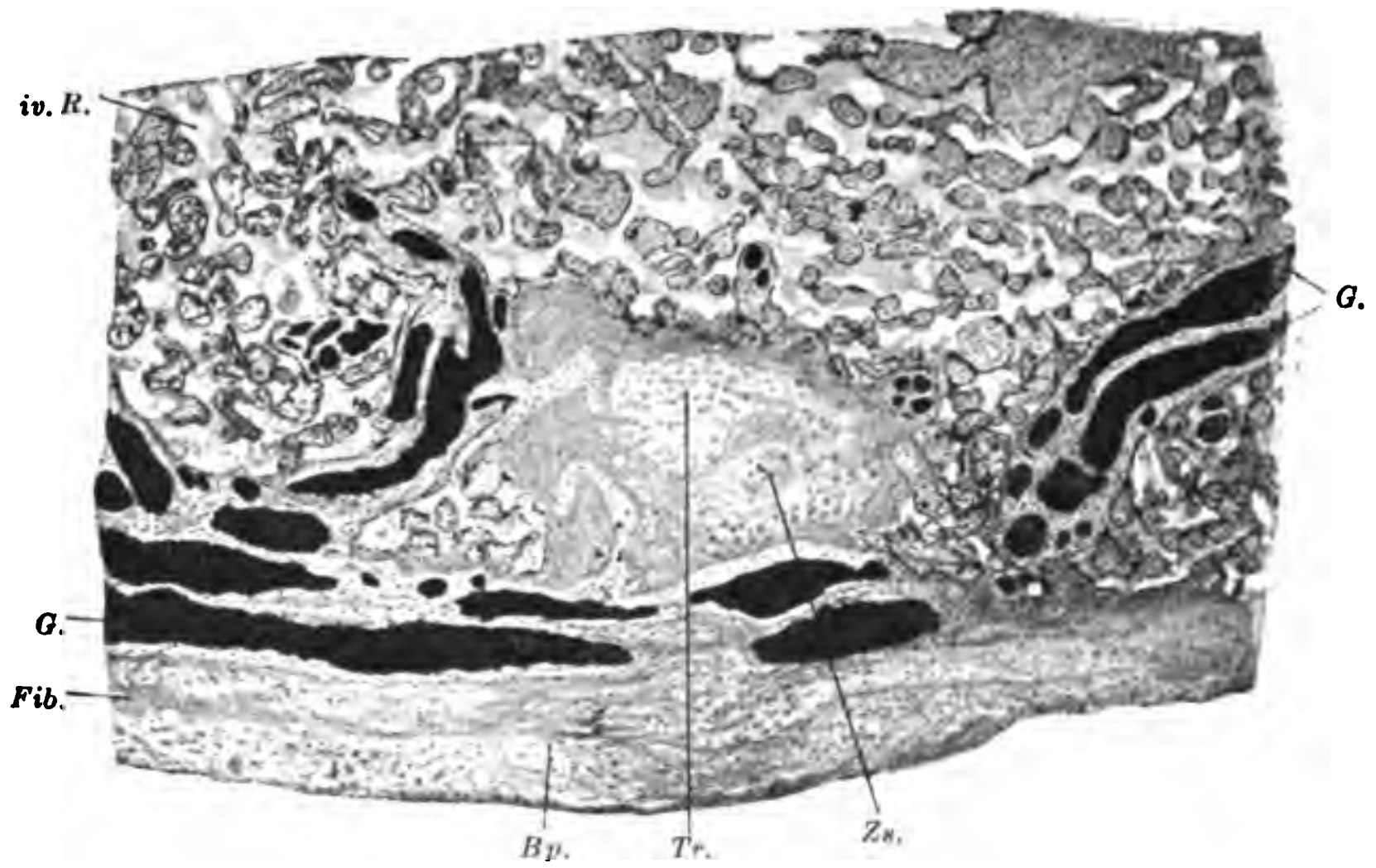

FIG. 133.—Choriodecidual vessels injected from an umbilical artery, in a mature expelled placenta. *Bp.*, basal plate; *Fib.*, fibrin stria; *G.*, choriodecidual vessels; *iv. R.*, intervillous space; *Tr.*, basal degenerating trophoblast; *Zs.*, degenerating connective-tissue stroma of villus. × 40.

The basal plate is traversed by maternal or uteroplacental vessels, destined for the intervillous space. Arteries and veins

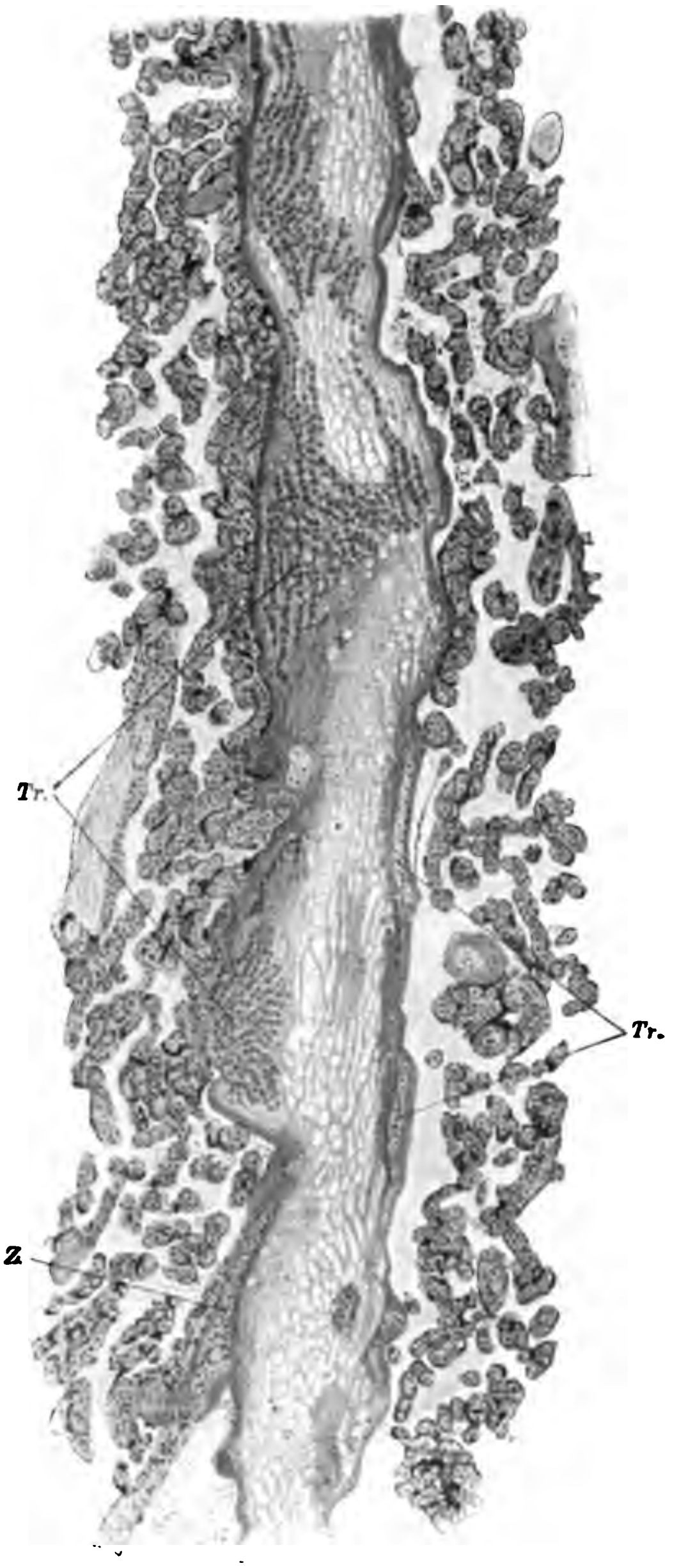

Fig. 134.—Septum of a mature expelled placenta. ***Tr.*****, trophoblast;** ***Z.*****, stroma of villus that has fused with the septum. × 50.**

pass through the plate in sinuous courses, but at their entrance into it they lose their muscularis and are represented by channels lined only by endothelium. And even this is usually lost[51] when

---

[51] The opinion of Waldeyer that the endothelium is continued for some distance upon the wall of the intervillous space, though in accordance with the older views, has not been confirmed by later investigators.

the vessels pass through the fibrin layers of the plate. The arteries generally open in the region of the septa or close beside them, while the veins arise rather towards the middle of the cotyledons. This arrangement favors, to a certain extent, the intervillous circulation. Both arteries and veins, as a rule, traverse the wall of the intervillous space obliquely, yet villi are frequently sucked into the veins or they may, as has already been mentioned, be torn away and, passing into the veins, close them, thus producing disturbances in the circulation.

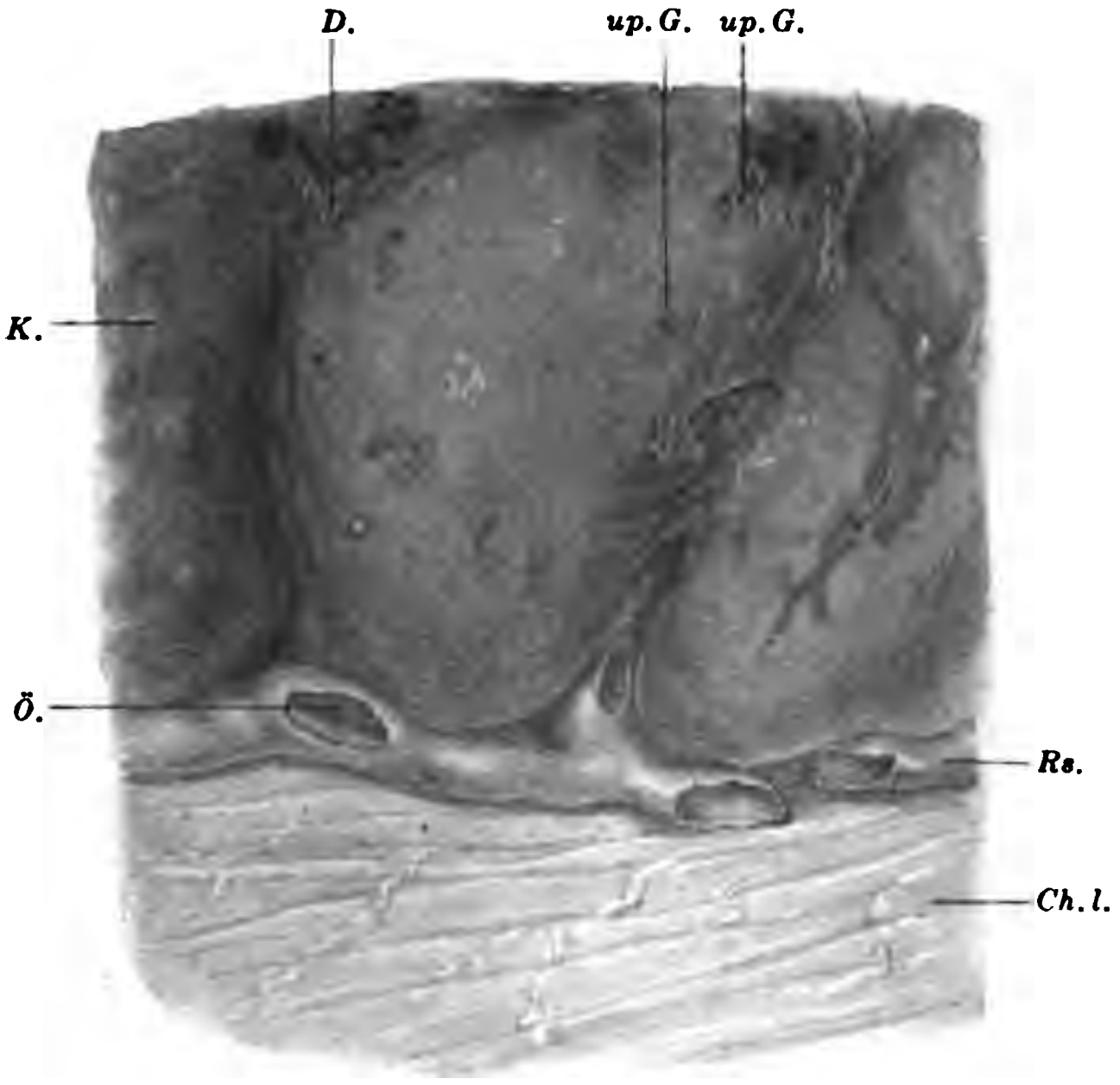

FIG. 135.—Marginal portion of a mature expelled placenta with well-developed marginal sinus distended with air. *Ch. l.*, chorion læve; *D.*, fragments of decidua; *up. G.*, uteroplacental vessels; *K.*, superficial calcareous deposit; *Ö*, opening into the marginal sinus (a tear, produced at birth by the division of a uterine vein), villi, which project into the marginal sinus, being seen through the opening; ***Rs.***, marginal sinus. × 1½.

The conditions of the circulation in the placenta are quite peculiar and are found nowhere else in the body. The arteries open into a wide, very irregular space, extending throughout the entire placenta and limited only by fetal elements (and by fibrinoid). The space is formed from trophoblast lacunæ and is filled with blood by the erosion of maternal vessels; these at first are of merely capillary size or but little greater. With the increasing importance of these afferent and efferent vessels they become gradually larger. Originally the opening of the vessels occurs in the region of the transition zone, and even later the union of the vessels with the intervillous space is still characterized by the fact that their endothelium has no continuity with any of the cellular elements that line the space (syncytium, basal ectoderm). The intervillous space is both the functional and the nutritive vascular space of the placenta; from it the villi derive their nourishment, the fetal circulation playing merely a subordinate rôle in this respect. Even after the death of the embryo the placenta may persist for a considerable time and may continue to grow, although only in an atypical manner.

One of the efferent channels of the placenta is the *marginal sinus, Meckel's blood-channel,* the *sinus circularis;* it is situated in the angle between the margin of the placenta and the chorion læve (Fig. 135), and does not encircle the entire placenta (it is wanting at the region shown in Fig. 129), but only about one-quarter, or at most seven-eighths, of the circumference (Budde); occasionally it can scarcely be recognized. It is not to be regarded as a con-

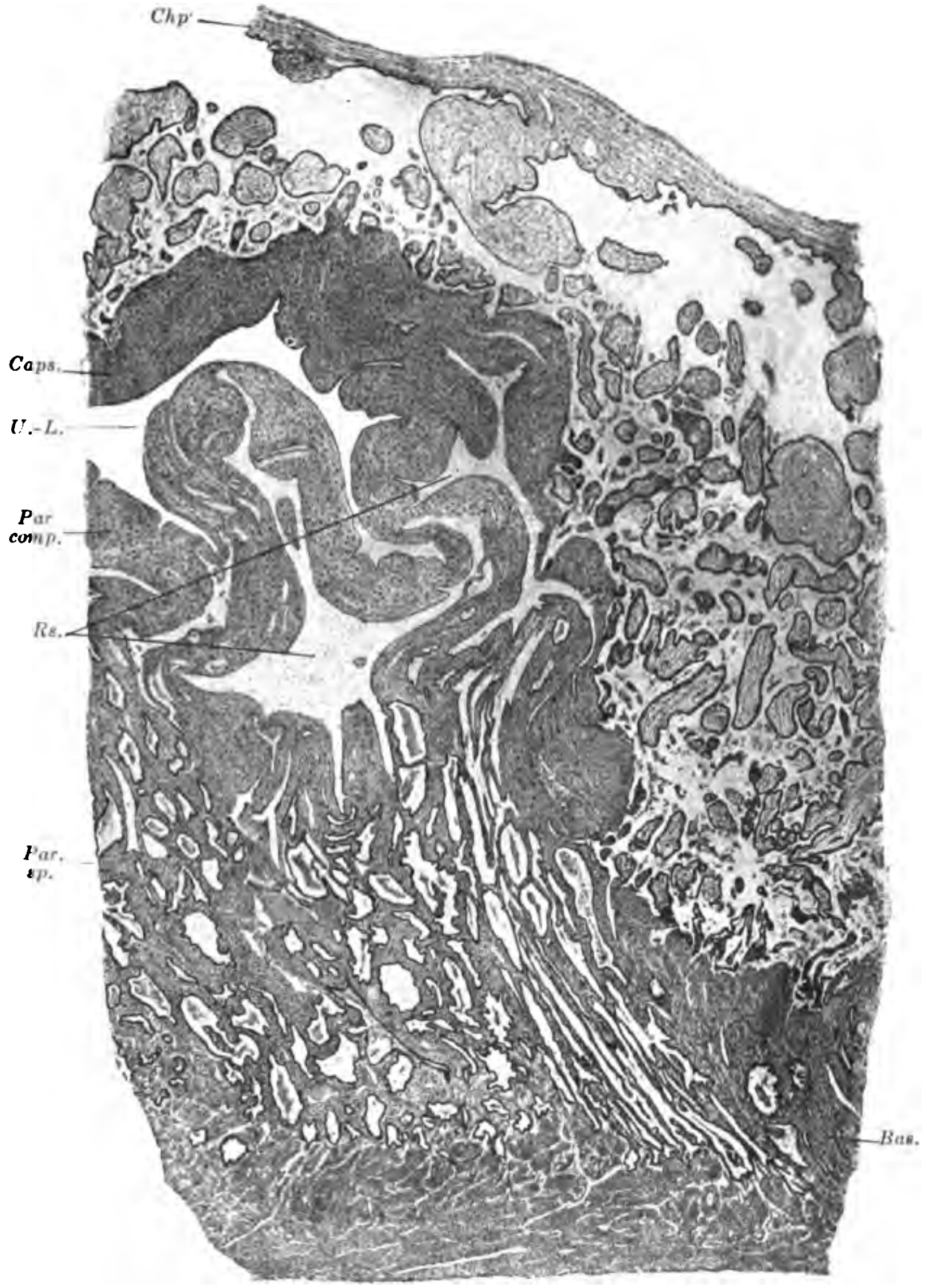

FIG. 136.—Margin of the placenta in the second month. From the same case as Fig. 118. *Bas.*, decidua basalis; *Caps.*, decidua capsularis; *Chp.*, chorion plate; *Par. comp.* and *Par. sp.*, decidua parietalis compacta and spongiosa; *Rs.*, marginal sinus; *U.-L.*, lumen of the uterus. × 15.

tinuous, regular vessel, but as a rather irregular space of varying diameter, which presents peripherally gaps and openings, corresponding to uterine veins that have been torn away; and gaps of varying size also occur on its inner wall through which bunches of villi project and by which it is in communication with the intervillous space (Figs. 135 and 137). Budde agrees with earlier authors in regarding the entire sinus as the marginal portion of the intervillous space, its inner wall, so far as it is formed, being produced by cohesion of the marginal villi and by the formation of fibrin. This explanation does not seem to suffice for all cases; in younger ova greatly enlarged veins occur, which have a circular course and have been regarded as the marginal sinus (*e.g.*, by Friolet and in the case shown in Fig. 136), and in the mature

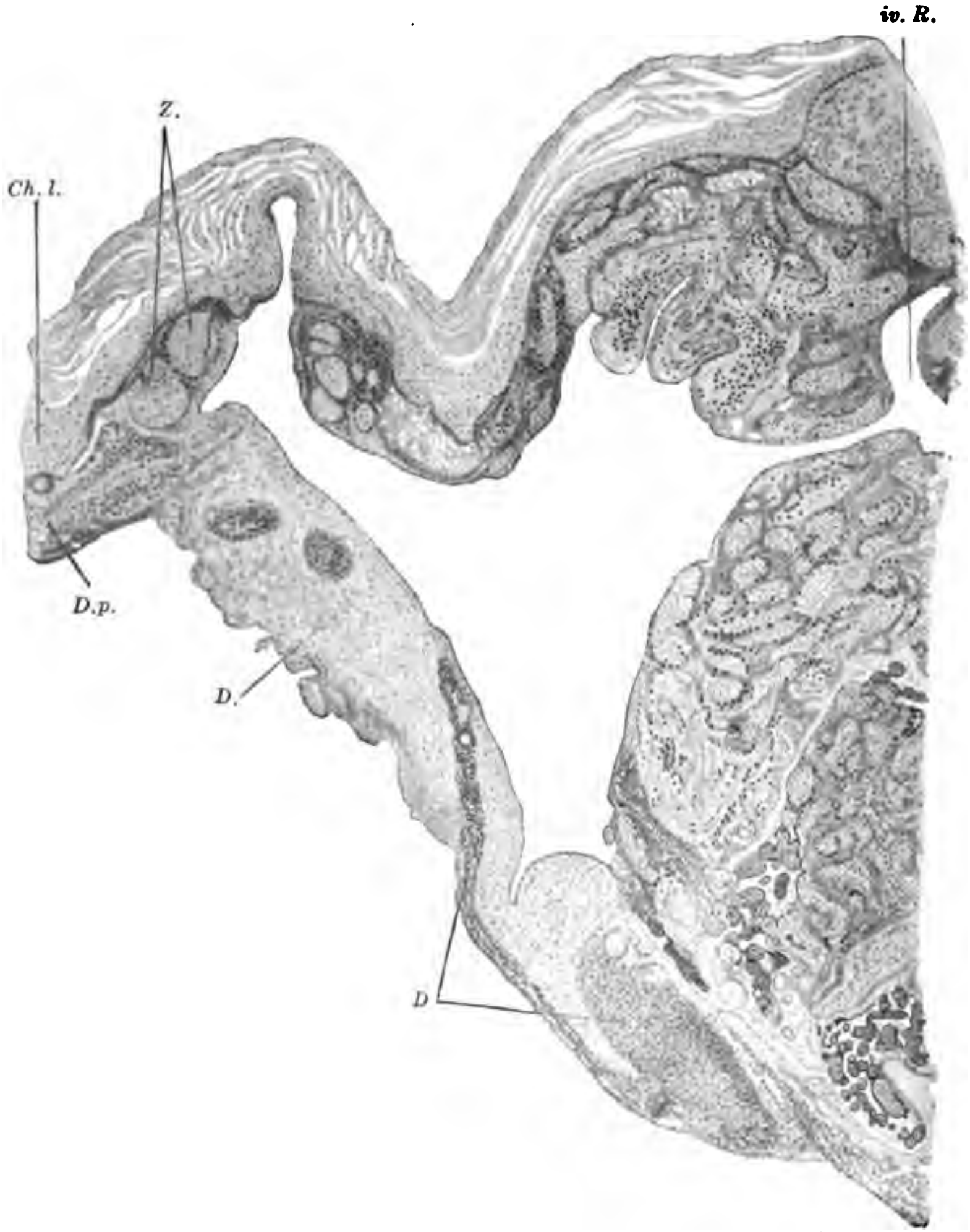

FIG. 137.—Marginal sinus of a mature expelled placenta with an endothelium-like lining. *Ch. l.*, Chorion læve; *D.*, decidua parietalis; *iv. R.*, intervillous space; *Z.*, remains of villi. × 18.

placenta a complete endothelium-like lining is occasionally found in the sinus (Fig. 137). Nevertheless, this endothelium rests upon a necrotic substratum resembling an infarct and containing degenerating villi, and it is not impossible that the flat cells are derived from the epithelium of villi; the question, however, needs further investigation.

The relations of the circulation in later stages are not essentially different from those that obtain in younger ova; in the mature expelled placenta also the intervillous space is, as a rule, but incompletely filled (Fig. 122) or almost empty (Fig. 129). Placentæ fixed *in situ* are usually gorged with blood (Bloch, 1889). The circulation is determined, on the one hand, by the arrangement of the uteroplacental vessels, already described, and on the other, by the pregnancy pains already referred to (p. 136). The poverty in blood of the expelled placenta is further evidence of a comparatively well-determined circulation.

In considering the growth of the placenta a distinction must be made between growth in thickness and growth in area. The *growth in thickness* is chiefly due to an elongation of the villi and the associated separation of the chorion plate from the basal plate.

Somewhat different from this is the view of Pfannenstiel (1903). As has already been pointed out, this author derives the syncytium from the endothelium of the maternal blood-vessels and regards the first-formed blood lacunæ as greatly enlarged capillaries; he terms them the *primary intervillous space.* This space then enlarges by the veins which open on its floor and into which bunches of villi project, enlarging as the result of a degeneration of their walls, this degeneration extending as far as the arteries which open between the veins; the tissue surrounding the arteries, however, persists to form the decidual pillars, that is to say, the septa placentæ. The new space so formed is termed the *secondary intervillous space.* The projection of villi into the veins is incontestable (see p. 164); the process assumed to occur by Pfannenstiel cannot, however, have any important significance, since, firstly, anchoring villi are at that time attached to the basal plate in the neighborhood of the openings of the veins and their attachment would be broken by such a degeneration, without the possibility of forming a new attachment after the destruction of the cell columns. Secondly, the basal plate is not thicker in the early stages of development than it is later, and such a melting away of the portion of it that is in relation to the intervillous space would require a very intensive proliferation of the decidua basalis for the replacement of the lost layers. But there is no histological evidence of the occurrence of such a proliferation.

The question of the *growth in area* of the placenta presents great difficulties, apart from that which occurs during the embryotrophic stage of placentation. The most important factor in this latter growth is the splitting of the marginal decidua, and the occurrence of this process makes it intelligible how the ovum, at first a mere dot but later increasing enormously in size, forms for itself a capsule, which projects beyond the level of the mucous membrane as far as the equator of the ovum or even beyond it and fills a considerable portion of the uterus. But the growth in area of the placenta is not confined to the embryotrophic period; the placenta reaches its greatest relative extent at about the fourth month (Von Herff), at which time it occupies almost the half of the inner surface of the uterus. At this time it is depressed in a cup-like manner, at the centre, in correspondence with the almost even curvature of the uterus. Later its growth is relatively less rapid than that of the uterus and it becomes flatter in correspondence with the stretching of the pregnant uterus and the slight flattening of its anterior and posterior walls.

This, at first, rapid enlargement of the placenta has been regarded by Hitschmann and Lindenthal as the result of a gradual inclusion in the placenta of the decidua capsularis and the portions of the chorion frondosum opposite to it, there being at the same time a stretching of the summit of the capsularis and of the chorion læve—in other words, it is due to a kind of unrolling and stretching of the chorion frondosum; but no evidence that such a process occurs is forthcoming. The possibility of a shifting of the margin of the placenta, as a result of unequal growth, is also worthy of consideration. Similarly, the later relative diminution of the placenta may be due to two different causes; either there is a degeneration of its marginal portions or there is again a shifting of the margin as the result of unequal growth.

Pfannenstiel chiefly inclines toward a shifting of the margin, which has, indeed, the greater probability; yet the process cannot be a simple one on account of the manifold connections between the placenta and the subjacent tissues by means of the blood-vessels. The decidua basalis spongiosa with its large gland cavities forms, it is true, a very adaptable substratum. But an obliteration of the marginal portions in later stages is also very probable, since younger placentæ (Fig. 130) show a relatively gradual transition into the chorion læve and only later does a distinct placental margin appear. A solution of the problem may perhaps be obtained in the following manner: Villi are probably formed only in early stages by the ingrowth of mesoderm into the trophoblast shell (Hitschmann and Lindenthal); after the formation of the chorion plate and its two-layered epithelium the new-formation of villi must cease. The destruction of smaller villi in the subchorial fibrin stria is probable, but the larger ones must persist until the mature placenta, in which, as a rule, a villus corresponds to each cotyledon. An enumeration of the basally directed villi at different stages would show whether the placenta was enlarged by taking into its territory new portions of the chorion and later diminished by excluding them again, or whether a certain constancy in the numbers occurred. Such enumerations have not, however, as yet been attempted.

The situation of the placenta, which is determined at implantation, is just as frequently upon the anterior as upon posterior wall of the uterus; more rarely it is lateral, in which case it may cover the opening of a tube.[52] According to Holzapfel (1898), in 107 cases the placenta was situated on the anterior wall in forty-two, on the posterior wall in forty-five (both inclusive of cases of extramedian positions and extension upon the fundus), in a tubal angle in fourteen, laterally below the opening of a tube in five. One case was a placenta prævia (covering the os internum uteri), but this condition is of rare occurrence, since according to Schauta but one case occurs in 1500–1600 pregnancies. It may result from a persistence of a portion of the capsularis with its intervillous space and supply of villi (placenta reflexa), or from an abnormally low implantation of the ovum, near the ostium internum, or perhaps from a double implantation on both walls of the uterus at the same time, as has occasionally been observed (Graf Spee) in guinea-pigs (Hitschmann and Lindenthal).

V. THE MATURE AFTERBIRTH; THE AMNION, ALLANTOIS AND YOLK SACK UP TO MATURITY.

The immediate causes of birth are still unknown, yet it may be said that in general the placenta is so altered at the close of pregnancy by the continued modifications of the epithelium of the villi, the disappearance of the Langhans layer and syncytium, the formation of fibrinoid and infarcts, that it can no longer perform its function of affording nourishment to the child, or can do so at best only insufficiently. The trophoblast and syncytium have a limited span of life and its close is reached with the close of pregnancy.

The *plane of separation* of the afterbirth lies in the region of the decidua spongiosa, in which preparations for it have been made by anatomical conditions (the thin gland partitions) (Langhans); nevertheless, local separations occur also in the compacta, and, indeed, are regarded as the rule by Webster. The placenta, chorion læve, and decidua compacta possess a certain amount of firmness and are actually separated from the spongiosa by any diminution of the inner surface of the uterus; the result of this is the formation of a *retroplacental hæmatoma,* which begins to be formed at the first rupture of the vessels.

The expelled placenta is, as a rule, disk-shaped and has a diameter of 16–20 cm., a thickness of 2½–3 cm., and an average weight of something over 500 Gm. Variations are not rare in all dimensions and do not stand in any accurate relation to the

---

[52] The covering of an opening of a tube is evidence in favor of the splitting of the decidua marginalis during the growth of the ovum.

development of the child. The maternal or outer surface (Fig. 135) after the removal of the adhering blood-clots appears dark reddish gray, frequently with small, somewhat pale spots; is divided by furrows into 15–20 irregular lobes (cotyledons); and is, in general, rather smooth, except for occasional adhering shreds of tissue (portions of the spongiosa). The paler spots correspond to anchoring villi and the bunches of villi which surround them, and the darker areas between them are caused by the blood of the intervillous space; yet these differences of color are evident only when the basal plate is relatively thin and the maternal blood has been retained in considerable quantity. Furthermore, small white scales (calcareous deposits), very variable in number, are usually to be seen; they usually occur in fibrin nodes (Figs. 127 and 129) and are usually near the basal plate. Larger white or yellowish masses projecting above the general surface are caused by the white infarcts. The uteroplacental vessels traverse the basal plate usually as greatly contorted canals (Bumm, Klein); the veins have a greater calibre and more delicate walls than the arteries. In each cotyledon there are about two or three veins situated centrally and from three to five peripheral arteries (see also p. 162). (Concerning the visibility of the choriodecidual vessels see p. 160.) The cotyledons are incompletely separated by the septa placentæ, which extend from the furrows of the outer surface and by manipulation of the placenta, or even by birth-trauma, may be readily separated into two layers, so that the furrows appear markedly deepened.

The fetal inner surface is whitish, and at first is covered by the amnion; after this is removed it is rather smooth, with the fetal vessels projecting from the surface. A marking of the surface, usually visible, consisting of paler spots on a darker background, is due to the same causes as the corresponding marking of the outer surface, but is dependent, as regards its visibility, on the thickness of the subchorial layer of fibrin. From the surface project occasionally the placental cysts (p. 155) filled with a clear fluid. On section the fresh placenta is dark red and shows a spongy structure; the septa as well as the basal plate are more grayish-red.

The arrangement and size of the cotyledons are determined chiefly by the chorionic villi. In general, each cotyledon corresponds to a villus, which, with its branches, fills the cavity of the cotyledon and is attached by numerous anchoring villi to the basal plate and the septa. Close to the origin of the villus from the chorion plate branches are given off, which divide immediately beneath the plate and are frequently included in the Langhans stria and the canalized fibrin. Small or rudimentary villi occur on the chorion plate only in the region of the placental margin.

The chorion (chorion læve) forms with the placenta a sack, which is opened in the afterbirth by a slit, often irregular or triradiate, and corresponding to the lower pole of the ovum. It is a grayish- or yellowish-red, easily torn membrane, whose outer surface is rough and has attached to it shreds of decidua and blood-clots. Its microscopic structure, and also that of the placenta at birth, has been described in Section IV.

Hyrtl describes in the chorion læve, close to the margin of the placenta, occasionally occurring arteriovenous anastomoses between fetal placental vessels of the size of a needle or more. The vessels which occurred in the chorion læve when it still possessed villi have completely disappeared at birth, so that the membrane is non-vascular; yet occasionally some weak stems occur in the marginal parts of the mature membrane.

The amnion is fused with the placenta and chorion, but may be separated from these as an independent, transparent, glistening membrane. After its separation its outer surface, and also the inner surface of the chorion, has a fibrillar appearance, as delicate connective-tissue strands which connect the two membranes have been torn by the separation. The amnion consists of a connective-tissue stroma and a cubical or cylindrical epithelium, in which Lönnberg finds fat granules of frequent occurrence. Rarely (and principally in the placental region) the epithelium presents irregular whitish growths, the *amniotic villi* (Fig. 138) (Ahlfeld), structures which are of normal occurrence in ungulates. The epithelium over them is many-layered and the cells undergo cornification and desquamation. Blood-vessels are wanting in the amnion.

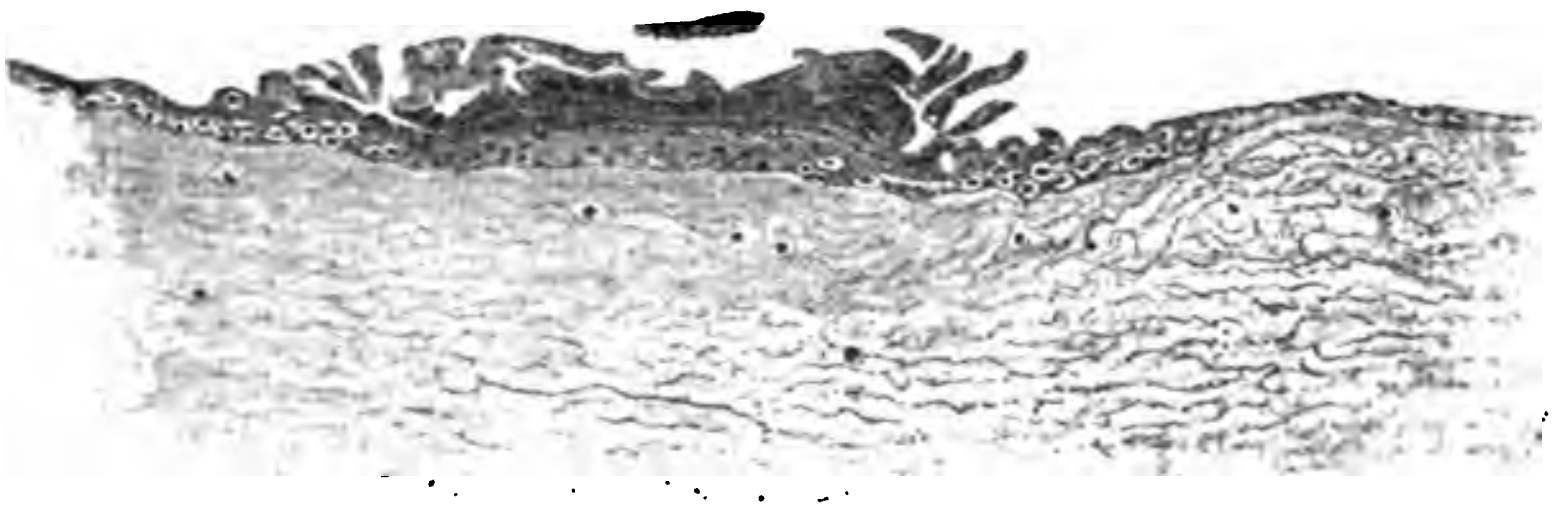

FIG. 138.—Amniotic villi from a mature human afterbirth. × 100.

The fusion of the amnion and chorion is secondarily produced by the disappearance of the extra-embryonic cœlom towards the end of the second month (Strahl), as the result of the rapid growth of the amniotic sack. The amniotic epithelium is at first quite low and endothelium-like, and becomes cubical only in the second half of pregnancy (Bondi). (Compare also Figs. 96, 114, and 117.) Granules appear in the cells after the third month and Bondi also describes granules in the mature amnion that stain with neutral red. Stomata he could not find.

The *liquor amnii,* whose quantity amounts to about a litre at the end of pregnancy, is a secretion of the amniotic epithelium (Mandl, Bondi, Kreidl and Mandl). The evacuations of the fetal urinary bladder have no noteworthy significance in its production (compare also Wargaftig, 1907).

The *umbilical cord* (funiculus umbilicalis) is a cord which is usually twisted anti-clockwise (to the left); it is normally about the same length as the child, but may be reduced almost to nothing or may reach three times the normal length. The twisting depends upon the unequal growth of the two umbilical arteries, and this again is associated with the slight difference which exists in the diameters of the two arteries from the beginning and with the difference of blood-pressure in the arteries as a result of the difference in frictional resistance (Neugebauer). The embryo, which floats freely in the amniotic fluid and is almost sustained by it, is passively rotated as the result of the gradual twisting of the cord, and local growths of the arteries produce the *false nodes* which occur in this. The angle at which the cord is inserted into the placenta varies between 0° and 90° and is greatest in cases where the insertion is central; when the attachment is at an acute angle there occurs between the cord and the placenta what is known as *Schultze's amniotic fold,* produced by the incomplete apposition of the amnion to the cord and placenta, owing to the persistence of the yolk sack and its vessels.

Microscopically there may be distinguished upon the surface of the cord the single-layered cubical or flattened amniotic epithelium, in which, according to Köster, stomata occur; the connective-tissue layer of the amnion is not distinguishable as a separate sheet. The stroma of the cord consists of a gelatinous tissue, *Wharton's jelly,* which is characterized by possessing stellate cells, resembling embryonic cells, a scanty development of fibrillæ, and wide intercellular spaces. At the periphery and in the neighborhood of the vessels the tissue is arranged in concentric layers (Fig. 139). The vessels, especially the arteries, show stout longitudinal muscle-bundles beneath the circular musculature, and these, when contracted, form strong projections which facilitate the complete closure of the vessels when the cord is severed (Henneberg, Bucura). Vasa vasorum can be distinctly injected in the veins, according to Gönner, and while they cannot be injected in the arteries yet their origins can be distinguished when the arteries are laid open. Nerves can be followed from the abdominal cavity of the child only to the umbilicus or a short distance beyond it; they do not occur in the free portion of the cord (Bucura). Finally, remains of the allantoic duct occur in the mature cord.

The *allantoic duct* is, according to Löwy, still hollow throughout its entire length in embryos with a greatest length of 8 mm., but has a very variable diameter, and in embryos of 9 mm. its lumen is partly obliterated toward the peripheral end, while in those of 14 mm. it is open only in a small portion of its extent and that portion is irregularly expanded; even in the fourth month remains of the duct are still to be found in the neighborhood of the embryo with a lumen and cubical epithelium (Fig. 139); and in the mature cord there are to be found occasional epithelial pearls and occasionally coils and lateral outpouchings as remnants of the duct.

The *yolk stalk* becomes divided shortly after the closure of the umbilicus. In the umbilical cord remains of it may be found up to the third month, but at maturity these remnants have probably completely vanished. Portions of the omphalomesenteric vessels, occasionally filled with blood, are also to be found in the third month and, rarely, they persist until the close of pregnancy (Lönnberg).

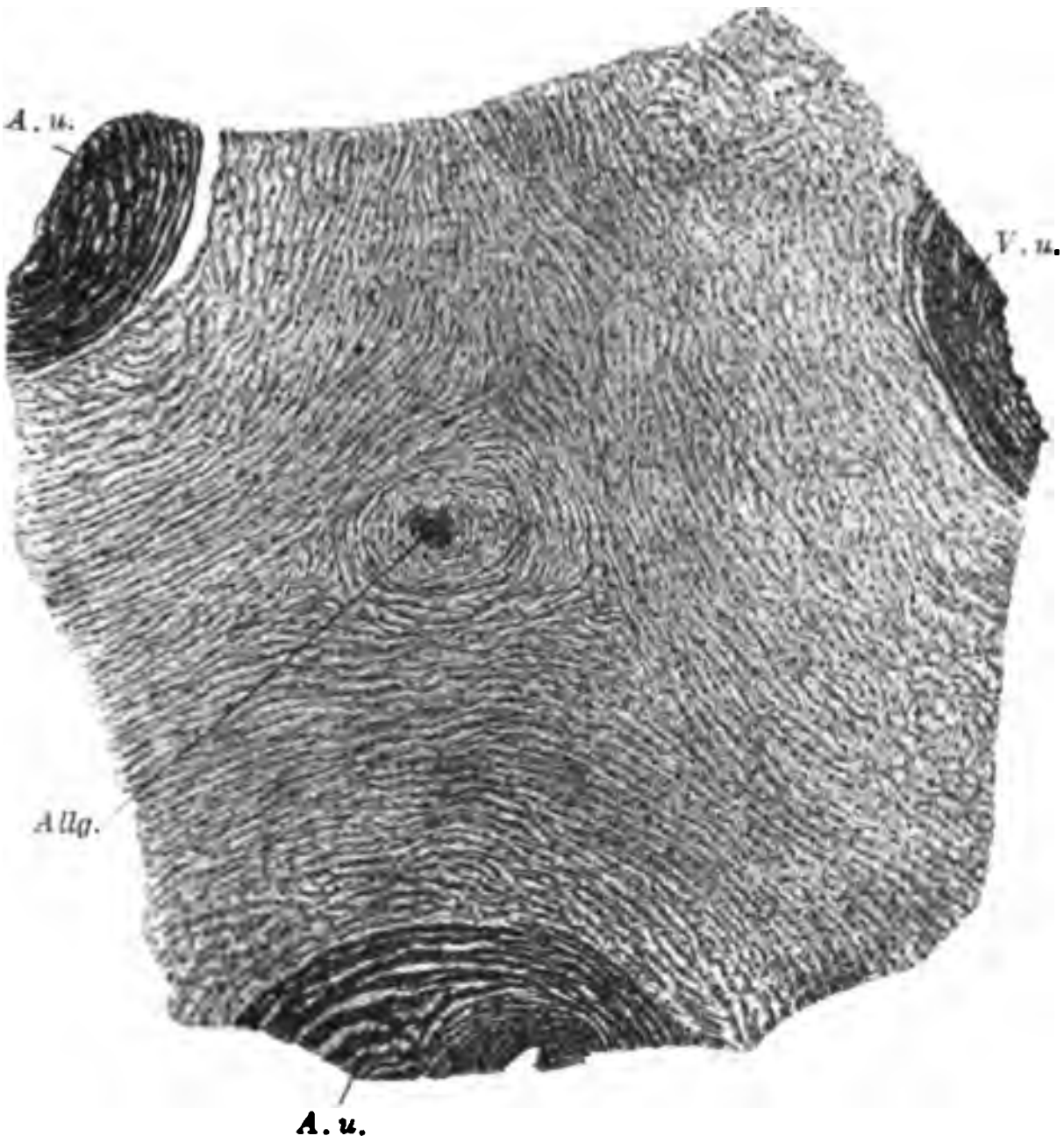

FIG. 139.—Central portion of a transverse section of an umbilical cord of an embryo of the fourth month (vertex-breech length 13½ cm.). The Whartonian jelly is arranged in concentric layers. *A. u.* and *V. u.*, umbilical vessels; *Allg.*, allantoic duct. The yolk stalk has disappeared. × 30.

The *yolk sack* (vesicula umbilicalis) is a normal constituent of the mature afterbirth (B. S. Schultze), but on account of its minuteness and the irregularity of its situation it is readily overlooked. It occurs between the chorion and amnion, on the placenta or the chorion læve, or even at the opposite pole of the ovum; very rarely it even appears to lie in the umbilical cord itself (Lönnberg). Its variability in position is due to the length of the yolk stalk and the width of the exocœlom. The Schultze amniotic fold may serve as a guide to it, but between the direction of the fold and the connecting line between the sack and the umbilical cord there may be a divergence of even 90° (Lönnberg). Macroscopically the mature yolk sack is usually a round or oval, flattened, white or yellow body with a diameter of 1–5 mm.; microscopically it presents a mesodermal investment and its contents are flake-like and partly calcified, but no epithelium can be detected.

At the commencement of its development the yolk sack shows a certain amount of differentiation. The blood and the vessels of the ovum first appear in its wall and, later, for a considerable time it is a region of blood formation and consequently richly vascular (Fig. 140). Its epithelium forms gland-like invaginations (Graf Spee) or intra-epithelial cysts, produced by cell degeneration (Fig. 140). (Compare also Branca.) Graf Spee also describes the occurrence of giant cells in the epithelium of younger stages and regards them as associated with the blood formation. According to Meyer and Jordan there occur at the end of the first month epithelial buds, solid or hollow outgrowths, which project into the mesoderm, yet these structures are rather variable in their occurrence. Later the epithelium becomes flat and, finally, degenerates with the thickening up of the contents of the vesicle.

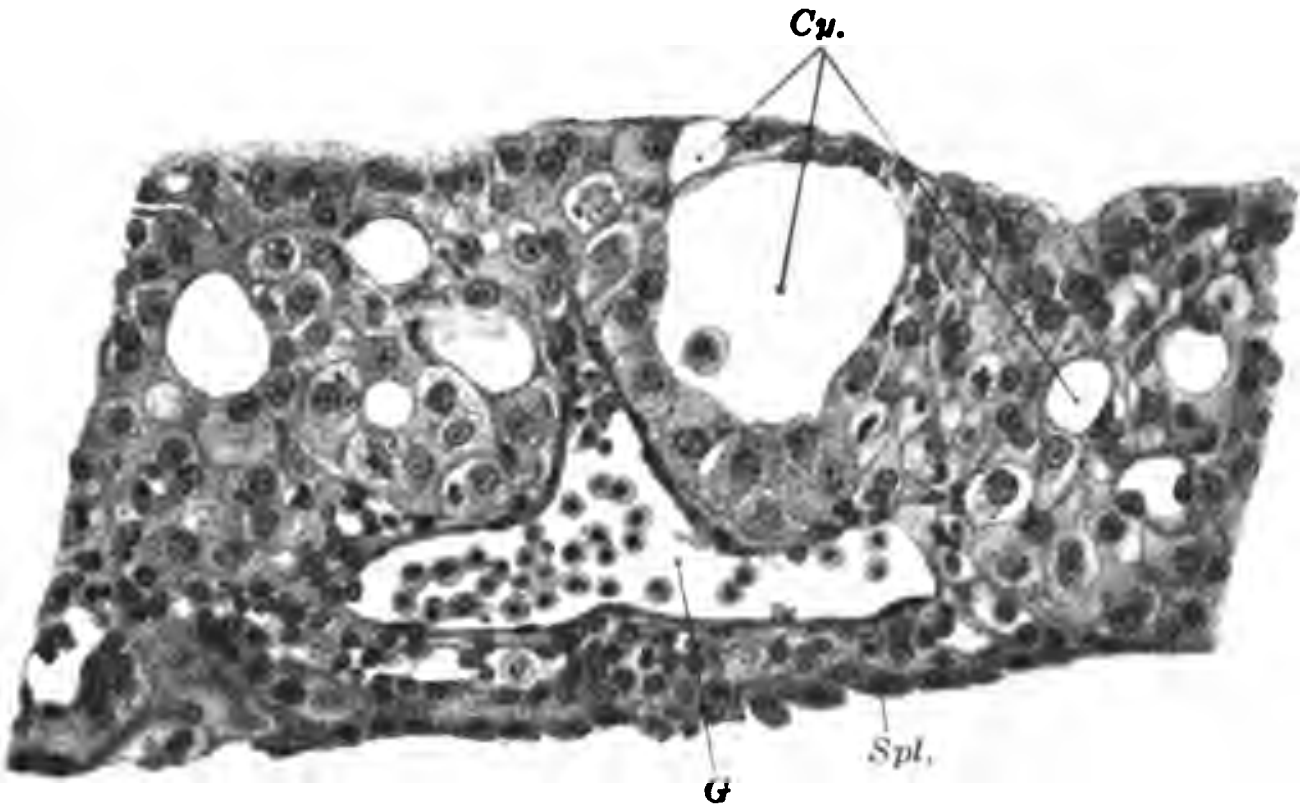

Fig. 140.—Wall of the yolk sack from a human embryo of a greatest length of 9 mm. ***Cy.*****, intra-epithelial cysts;** ***G.*****, blood-vessel;** ***Spl.*****, splanchnopleure. × 300.**

VI. THE UTERUS POST PARTUM.

Since the plane of separation of the afterbirth passes through the decidua spongiosa, the numerous flattened gland cavities of the latter are opened at birth. In the region of the placenta the spongiosa is somewhat thinner than elsewhere (see p. 159). Hemorrhage from the opened vessels is prevented by the compression of the vessels within the contracted muscularis and the compressed mucosa, but blood-serum exudes for a considerable time from the opened tissue spaces. The epithelium of the superficial gland cavities, which Langhans believes is responsible for the renewal of the superficial epithelium of the mucous membrane, has little significance in this respect,[53] having undergone extensive modifications during pregnancy (p. 140). The regeneration is rather from the deepest gland zone, the limiting layer of His; but since this is exposed only in spots, the more superficial layers of the spongiosa and the persisting remains of the compacta must be destroyed by coagulation necrosis and be expelled. Previously to their expulsion they form a whitish-yellow layer resting upon the mucous membrane and have been usually regarded as necrosed compacta.

The line of demarcation between the necrotic and persisting layers "is formed by the basal surfaces of all the gland cavities occurring in its neighborhood, which thus later become the surface" (of the mucosa) (Wormser). This line becomes distinct on the second day after birth; the expulsion of necrotic tissue begins on the fifth day and is completed everywhere on the tenth to the twelfth day after birth. The gaps between the gland cavities are covered over after the expulsion "by lateral shifting, flattening, and amitotic increase" of the epithelium; mitoses seem to be at first entirely wanting. As the epithelium grows out from the deeper portions of the glands many-layered zones of epithelium and multinuclear masses of protoplasm are formed, and, at the same time, degenerations occur everywhere in the epithelium; the formation of vacuoles, shrinkage of the nuclei, and degeneration of cells and nuclei are frequently to be found at the surface. Mitoses first appear about two weeks after delivery, and, finally, probably only those epithelial cells persist which have been newly formed by the mitotic process. Leucocytes wander in rather large numbers through the mucous membrane. The decidua cells degenerate in the vicinity of the line of demarcation, probably by a fatty degeneration; and the connective tissue scaffolding thus persists as an empty mesh-work. This process Wormser terms areolar degeneration, and he imagines the meshes to be eventually reoccupied by inwandering connective-tissue cells; this idea, however, is rather improbable. The decidual modifications which have occurred in the deeper layers of the mucous membrane disappear, the syncytial giant cells degenerate and vanish, and in two or three weeks after birth the regeneration of the mucous membrane, accompanied by an increase in its thickness, is so far completed that stroma, tubular glands, and a surface epithelium are

---

[53] The account given here is principally based on the observations of Wormser (1906).

already present; nevertheless, the epithelium continues to show degenerations and regenerations for some time.

The *mucous membrane of the cervix uteri* becomes looser during pregnancy and shows serous infiltration and an increase in the glands, while after birth it presents zones of traumatic hemorrhages, the epithelium, however, being retained. Leucocytes also wander out through this mucous membrane in considerable numbers.

The *muscularis uteri* increases during pregnancy to about twenty-four times its original size, partly by hypertrophy (the formation of new fibres by the division of those already present) and partly by hyperplasia of the individual fibres (Kölliker). The reduction is produced by a diminution of the size of the fibres and perhaps also by the complete degeneration of some of them (Von Ebner).

The peritoneal covering of the uterus and of the parts in its neighborhood shows here and there during pregnancy decidua-like growths (Schmorl), and similar growths occur in the tunica albuginea of the ovaries (Lindenthal). The tubes, with the exception of increased blood-supply and some serous infiltration, are but little altered.

BIBLIOGRAPHY.

AHLFELD, F.: Ueber die Zotten des Amnion, Archiv f. Gynäk., vol. vi, 1874.
Zur Genese der Amnionzotten, *ibid.*, vol. vii, 1875.

BAB, H.: Konzeption, Menstruation u. Schwangerschaft, Deutsche med. Woch., 1908.

BENEKE: Ein sehr junges menschliches Ei. Deutsche med. Wochenschr., Jahrg. 30, 1904; also Monatsschr. f. Geb. und Gyn., vol. xix, 1904.

BLOCH: Ueber den Bau der menschlichen Placenta, Beitr. z. path. Anat., vol. iv, 1889.

BONDI, J.: Zur Histogenese des Amnionepithels, Zentralbl. f. Gynäk., Jahrg. 29, 1905.

BONNET, R.: Ueber Syncytien, Plasmodien und Symplasma in der Placenta der Säugetiere und des Menschen, Monatsschr. f. Geb. und Gyn., vol. xviii, 1903.
Lehrbuch der Entwicklungsgeschichte, Berlin, 1907.

BRANCA, A.: Sur l'endoderme ombilical de l'embryon humain, Bibl. Anat. Supplément, 1908 (C. R. Ass. Anat.).

BRYCE, T. H., and TEACHER, J. H.: An Early Ovum Imbedded in the Decidua; also conjointly with J. M. MUNRO KERR, An Early Ovarian Pregnancy, under the title: Contributions to the Study of the Early Development and Imbedding of the Human Ovum, Glasgow, 1908.

BUCURA, C.: Ueber den physiologischen Verschluss der Nabelarterien und über das Vorkommen von Längsmuskulatur in den Arterien des weiblichen Genitales, Zentralbl. f. Gynäk., Jahrg. 27, 1903.
Ueber Nerven in der Nabelschnur und in der Placenta, Zeitschr. f. Heilkunde, vol. xxviii, 1907. (See also Zentralbl. f. Gynäk., vol. xxxii, 1908.)

BUMM, E.: Ueber Uteroplacentargefässe, Archiv f. Gynäk., vol. xxxv, 1889.
Ueber die Entwicklung des mütterlichen Blutkreislaufes in der menschlichen Placenta, Archiv f. Gynäk., vol. xliii, 1893.

BUSALLA: Beschreibung und histologisches Untersuchungsergebnis eines neuen Falles von Eierstocksschwangerschaft, Archiv f. Gynäk., vol. lxxxiii, 1907.

COVA, E.: Ueber ein menschliches Ei der zweiten Woche, Archiv f. Gynäk., vol. lxxxiii, 1907.

DISSE, J.: Die Eikammer bei Nagern, Insektivoren und Primaten, Ergebnisse d. Anat. und Entw., vol. xv for 1905, Wiesbaden, 1906.

FOSSATI, G.: Ueber Nerven in der Nabelschnur und in der Placenta, Zentralbl. f. Gynäk., vol. xxxi, 1907.

FRANQUÉ, O. v.: Die Entstehung der velamentösen Insertion der Nabelschnur, Zentralbl. f. Gynäk., 1901.

FRASSI, L.: Ueber ein junges menschliches Ei in situ, Archiv f. mikrosk. Anatomie, vol. lxx, 1907.

Weitere Ergebnisse des Studiums eines jungen menschlichen Eies in situ, *ibid.*, vol. lxxi, 1908.

FRIOLET, H.: Beitrag zum Studium der menschlichen Placentation, Beiträge z. Geburtsh. u. Gynäk., vol. ix, 1904; also Dissert., Basel.

FUSS, S.: Die Bildung der elatischen Faser, Arch. f. pathol. Anat., vol. clxxxv, 1906.

GIESE, H.: Histologische Untersuchungen über den weissen Infarkt der Placenta, Dissert., Halle, 1905.

GOENNER, A.: Ueber Nerven und ernährende Gefässe im Nabelstrang, Monatsschr. f. Geburtsh. u. Gynäk., vol. xxiv, 1906.

GROSSER, O.: Vergleichende Anatomie und Entwicklungsgeschichte der Eihäute und der Placenta mit besonderer Berücksichtigung des Menschen, Lehrbuch für Studierende und Aerzte, Wien, 1909.

HAPPE, H.: Beobachtungen an Eihäuten junger menschlicher Eier, Anat. Hefte, vol. xxxii, 1906.

HENNEBERG, B.: Beiträge zur feineren Struktur, Entwicklungsgeschichte und Physiologie der Umbilicalgefässe des Menschen, Anat. Hefte, vol. xix, 1902.

HERFF, O. v.: Beiträge zur Lehre von der Placenta und von den mütterlichen Eihüllen, Zeitschr. f. Geb. u. Gyn., vol. xxxv, 1896, and vol. xxxvi, 1897.

HITSCHMANN, F.: Die Deportation der Zotten und ihre Bedeutung, Zeitschr. f. Geb. u. Gyn., vol. liii, 1904.

HITSCHMANN, F., and LINDENTHAL, O.: Ueber das Wachstum der Placenta, Zentralbl. f. Gynäk., 1902.

Ueber die Haftung des Eies an atypischem Orte, *ibid.*, 1903.

Der weisse Infarkt der Placenta, Archiv f. Gynäk., vol. lxix, 1903.

HOFBAUER, T.: Grundzüge einer Biologie der menschlichen Placenta mit besonderer Berücksichtigung der Fragen der fetalen Ernährung, Wien u. Leipzig, 1905 (literature).

Die menschliche Placenta als Assimilationsorgan, 1907.

HOFMEIER, M.: Die menschliche Placenta, Wiesbaden, 1890.

HOLL, M.: Ueber die Blutgefässe der menschlichen Nachgeburt, Sitz-Ber. k. Akad. Wiss., Wien, vol. lxxxiii, 1881.

HOLSTI, O. N.: Weitere Beiträge zur Kenntnis der Embryotrophe, II. Ueber die Fettzufuhr zum menschlichen Ei, Anat. Hefte, vol. xxxiii, 1908.

HOLZAPFEL, K.: Ueber den Placentarsitz, Beiträge z. Geburtsh. u. Gynäk., vol. i, 1898.

Zur Pathologie der Eihäute, Beitr. zur Geburtsh. und Gynäk., vol. viii, 1903. (The author regards the amniotic villi as transplanted embryonic epidermis.)

HYRTL, J.: Die Blutgefässe der menschlichen Nachgeburt in normalen und abnormen Verhältnissen, Wien, 1870.

IWASE, Y.: Ueber die zyklische Umwandlung der Uterusschleimhaut, Zeitschr. f. Geburtsh. und Gynäk., vol. lxiii, 1908.

JORDAN, H. E.: The Histology of the Yolk-sac of a 92-mm. Human Embryo, Anat. Anzeiger, vol. xxxi, 1907.

JUNG, PH.: Beiträge zur frühesten Ei-Einbettung beim menschlichen Weibe, Berlin, 1908.

Kastschenko, N.: Das menschliche Chorionepithel und dessen Rolle bei der Histogenese der Placenta, Archiv f. Anat. u. Phys., Anat. Abt., 1885.

Kehrer, E.: Der placentare Stoffaustausch in seiner physiologischen und pathologischen Bedeutung, Würzburger Abhandl., vol. vii, parts 2 and 3, 1907 (literature).

Klein, G.: Mikroskopisches Verhalten der Uteroplacentargefässe, in Hofmeier: Die menschliche Placenta, Wiesbaden, 1890.

Zur Entstehung der Placenta marginata und succenturiata, *ibid.*

Kollmann, J.: Kreislauf der Placenta, Chorionzotten und Telegonie, Zeitschr. f. Biologie, vol. xlii, 1902.

Langhans, Th.: Zur Kenntnis der menschlichen Placenta, Archiv f. Gynäk., vol. i, 1870.

Untersuchungen über die menschliche Placenta, Archiv f. Anat. u. Phys., Anat. Abt., 1877.

Ueber die Zellschicht des menschlichen Chorion, Festschr. f. Henle, Beiträge z. Anat. u. Embryol., Bonn, 1882.

Syncytium und Zellschicht, Beiträge z. Geburtsh. u. Gynäk., vol. v, 1901.

Leopold, G.: Uterus und Kind, mit Atlas, Leipzig, 1897.

Ueber ein sehr junges menschliches Ei in situ, Leipzig, 1906.

Leopold and Ravano: Neuer Beitrag zur Lehre von der Menstruation und Ovulation, Archiv f. Gynäk., vol. lxxxiii, 1907.

Lönnberg, J.: Studien über das Nabelbläschen an der Nachgeburt des ausgetragenen Kindes, Stockholm, 1901 (literature).

Mandl, L.: Histologische Untersuchungen über die sekretorische Tätigkeit des Amnionepithels, Zeitschr. f. Geb. u. Gyn., vol. liv, 1905.

Weitere Beiträge zur Kenntnis der sekretorischen Tätigkeit des Amnionepithels, *ibid.,* vol. lviii, 1906.

Marchand, F.: Beobachtungen an jungen menschlichen Eiern, Anat. Hefte, vol. xxi, 1903.

Beitrag zur Kenntnis der normalen und pathologischen Histologie der Decidua, Archiv f. Gynäk., vol. lxxii, 1904.

Merttens, J.: Beiträge zur normalen and pathologischen Anatomie der menschlichen Placenta, Zeitschr. f. Geb. u. Gyn., vol. xxx, 1894, and vol. xxxi, 1895.

Meyer, A. W.: On the Structure of the Human Umbilical Vesicle, Amer. Journal of Anatomy, vol. iii, 1904.

Minot, Ch. S.: Uterus and Embryo, Journal of Morphology, vol. ii, 1889 (literature).

The Implantation of the Human Ovum in the Uterus, New York Med. Journ., vol. lxxx, 1904.

Neugebauer, L. A.: Morphologie der menschlichen Nabelschnur, Breslau, 1858.

Nitabuch, R.: Beiträge zur Kenntnis der menschlichen Placenta, Dissert., Bern, 1887.

Peters, H.: Ueber die Einbettung des menschlichen Eies und das früheste bisher bekannte menschliche Placentationsstadium, Leipzig and Wien, 1899 (literature).

Zum Kapitel: Langhans'sche Zellschicht, Zentralbl. f. Gynäk., 1900.

Beitrag zur Kasuistik der Vasa prævia und Gedanken zur Theorie der Insertio velamentosa, Monatsschr. f. Geb. u. Gynäk., vol. xiii, 1901.

Pfannenstiel, J.: Die ersten Veränderungen der Gebärmutter infolge der Schwangerschaft, — Die Einbettung des Eies, — Die Bildung der Placenta, der Eihäute und der Nabelschnur, — Die weiteren Veränderungen der genannten Gebilde während der Schwangerschaft, in Winckel: Handbuch der Geburtshilfe, vol. i, Wiesbaden, 1903 (literature).

Reinstein-Mogilowa, A.: Ueber die Beteiligung der Zellschicht des Chorions an der Bildung der Serotina und Reflexa, Virchow's Archiv, vol. cxxiv, 1891.

ROHR, K.: Die Beziehungen der mütterlichen Gefässe zu den intervillösen Räumen der reifen Placenta, speziell zur Thrombose derselben (weisser Infarkt), Virchow's Archiv, vol. cxv, 1889.

ROSSI-DORIA, J.: Ueber die Einbettung des menschlichen Eies, studiert an einem kleinen Ei der zweiten Woche, Archiv f. Gynäk., vol. lxxvi, 1905.

RUGE, C.: Die Eihüllen des in der Geburt befindlichen Uterus, Bemerkungen über den Ort und die Art der Ernährung des Kindes in demselben, in:

SCHROEDER, K.: Der schwangere und kreissende Uterus, Beiträge zur Anatomie und Physiologie der Geburtskunde, mit Atlas, Bonn, 1886.

SCHICKELE, G.: Die Chorionektodermwucherungen der menschlichen Placenta, ihre Beziehungen zur Entstehung der Cysten und Fibrinknoten der Placenta, Beitr. z. Geb. u. Gyn., vol. x, 1905.

SELLHEIM, H.: Physiologie der weiblichen Geschlechtsorgane, in Nagel, Handbuch der Physiologie, vol. ii, 1907.

SIEGENBEEK VAN HEUKELOM: Ueber die menschliche Placentation, Arch. f. Anat. u. Phys., Anat. Abt., 1898.

SPEE, F., GRAF: Ueber die menschliche Eikammer und Decidua reflexa, Anat. Anzeiger, vol. xiv, Suppl., 1898.

Neue Beobachtungen über sehr frühe Entwicklungsstufen des menschlichen Eies, Arch. f. Anat. u. Phys., Anat. Abt., 1896.

Epidiaskopische Demonstration eines jungen Stadiums der menschlichen Eieinbettung, Verhandl. Deutsch. Ges. f. Gynäk., xi Meeting in Kiel, 1905, Leipzig, 1906.

STEFFECK, P.: Der weisse Infarkt der Placenta, in Hofmeier: Die menschliche Placenta, Wiesbaden, 1890.

STOLPER, L.: Zur Physiologie und Pathologie der Placentation, Monatsschr. f. Geb. u. Gyn., vol. xxiv, 1906.

STRAHL, H.: Die menschliche Placenta, Ergebnisse d. Anat. u. Entwickl., vol. ii, 1893 (literature).

Neues über den Bau der Placenta, *ibid.*, vol. vi, 1897 (literature).

Placentaranatomie, *ibid.*, vol. viii, 1899 (literature).

Die Embryonalhüllen der Säuger und die Placenta, Hertwig's Handbuch der vergl. u. experiment. Entwicklungslehre, vol. i, part ii, Jena, 1906 (published 1902) (literature).

Der Uterus post partum, Ergebnisse d. Anat. u. Entw., vol. xv, 1906 (literature).

VAN CAUWENBERGHE, Recherches sur le rôle du syncytium dans la nutrition embryonnaire de la femme, Archives de Biol., vol. xxiii, 1907 (literature).

VOIGT, J.: Ueber das Verhalten von mütterlichen und kindlichen Elementen an der Einnistungsstelle jüngerer menschlicher Eier, Zeitschr. f. Geburtsh. u. Gynäk., vol. liv, 1905.

WALDEYER, W.: Ueber den Placentarkreislauf des Menschen, Sitz.-Ber. k. preuss. Akad. Wiss., 1887.

Bemerkungen über den Bau der Menschen- und Affenplacenta, Archiv f. mikr. Anat., vol. xxxv, 1890 (literature).

WARGAFTIG, GR.: Der augenblickliche Stand der Lehre von der Herkunft, der Physiologie und Pathologie des Fruchtwassers, Diss., Freiburg, i. Br., 1907.

WEBSTER, J. C.: Human Placentation, Chicago, 1901.

Die Placentation beim Menschen, Transl. by Kolischer, Berlin, 1906.

WEDERHAKE, J.: Ueber Plasma- und Deciduazellen, Monatsschr. f. Geburtsh. u. Gynäk., vol. xxiv, 1906.

WOLSKA, W.: Ueber die von Ruge beschriebene fetale Vaskularisation der Serotina, Dissert., Bern, 1888.

WORMSER, E.: Die Regeneration der Uterusschleimhaut nach der Geburt, Archiv f. Gynäk., vol. lxix, 1903 (literature).

VIII.

DETERMINATION OF THE AGE OF HUMAN EMBRYOS AND FETUSES.

By FRANKLIN P. MALL of Baltimore.

It would be relatively easy to determine the age of human embryos were it possible to fix with certainty the time of conception, that is, the time at which the spermatozoön enters the ovum. However, this question, which is directly associated with that of the duration of pregnancy, and must be discussed with it, has been a most important one in anatomy for ages, and it appears to be gradually approaching a satisfactory solution.

In ancient times it was generally believed that the duration of pregnancy in man, unlike that in lower animals, was of very uncertain length; and it was not until the seventeenth century that it was more accurately fixed, by Fidele of Palermo, at forty weeks, counting from the last menstrual period. In the next century Haller found that if pregnancy is reckoned from the time of a fruitful copulation it is usually thirty-nine weeks, and rarely forty weeks in duration. In general these results are fully confirmed by the thousands of careful data collected during the nineteenth century.

The difficulties encountered in determining the age of an embryo are due to the impossibility of determining the exact time of fertilization, for this does not necessarily follow immediately after copulation, and it is related only in a loose way with menstruation, the error in calculation in the second case often being a full month; but to the present time it has been most convenient, and probably most nearly correct, to rate the age of an embryo and the duration of pregnancy from the last menstrual period. However, from thousands of records it is found that the mean duration of pregnancy varies in first and second pregnancies, is more protracted in healthy women, in married women, in winter, and in the upper classes. As in lower animals, it varies very much in individual cases independently of any assignable cause. In general, it is longer when the new-born infants are over 50 cm. long, the mean difference being, according to Issmer, fifteen days between those that are 48 cm. and those that are 53 cm. long. Furthermore, it is well known that other mammalian embryos of the same age vary much in size, and, although we have a variety of data which bear upon the time of conception and the age of young human embryos, none are of more value, as Von Baer has pointed out, than those obtained from comparative embryology. The first step toward the solution of the problem was made by Von Baer when he discovered the human ovum. Next it was proved by Bischoff that ova are usually liberated periodically during the menstrual period, independently of copulation, and that the Graafian follicles of the ovary which contained these are converted into corpora lutea. Thus the first step was taken, for it had been shown that a recent ovulation is marked by a fresh corpus luteum and that in turn this usually takes place during the menstrual period.

The excellent work of Bischoff on fertilization in the rabbit and dog demonstrated that soon after copulation the spermatozoa pass through the uterus into the tube, where the ovum is usually met. When copulation takes place during the period of rut the ovum is usually fertilized within twenty-four hours, and in case the ovum is not fertilized upon the surface of the ovary or in the upper end of the tube it soon degenerates. However, this second point is not well established for mammals, but it is known that unfertilized hen's eggs can not be fertilized in the lower part of the oviduct. Since segmentation takes place in the mammalian ovum while it is in the uterine tube it is highly improbable that a human ovum could be fertilized after it has reached the uterus, but instead is probably always fertilized upon the surface of the ovary or in the upper part of the tube, as the frequency of tubal pregnancies indicates.

In 1868 Reichert obtained a very small human ovum measuring 5.5 by 3.3 mm. from a woman who commited suicide exactly two weeks after her menstrual period failed to appear. This ovum was studied with great care and described at great length by Reichert, and has become the classic specimen upon which to reckon the age of young human ova as well as to fix the time of fertilization. In one ovary there was found a well-developed corpus luteum with but very little blood in its centre. Reichert then studied the condition of the ovaries during menstruation and found that in nineteen specimens out of twenty-three the Graafian follicles had ruptured in the beginning of the period, while in four they were still unruptured. From these observations he concluded that, as a rule, ovulation takes place just before menstruation and that in case the ovum is fertilized menstruation is missed. This view changed the entire aspect of the question at once. Formerly it was believed that the ovum came down the tube slowly and was fertilized some days or weeks later, and now Reichert was led to believe that ovulation and fertilization took place but a few days before menstruation and that the presence of a microscopic fertilized ovum in the upper end of the tube arrested entirely the menstrual hemorrhage which was about to appear. With great force he discussed the whole question and decided that his specimen must be two weeks and not six weeks old. Already Von Baer had noted that the human ovum was precocious in its early development, but Reichert's conclusion made it much more so. However, it was easier to believe that Reichert's ovum was two weeks than six weeks old and there seemed to be no other possibility.

The theory of Reichert regarding the time of conception was accepted by His as the most probable, and accordingly he gave the probable age of embryos up to 35 mm. long. Due to his great influence the Reichert theory has been generally accepted and the most remarkable distortions have been made to fit individual specimens into it. The best known case is the Peters ovum, a specimen 1.6 × 0.9 mm. which was obtained thirty days after the last period, and Peters estimates its age to be three or four days. According to Weysse a pig's ovum of the same size is from nine to eleven days old, and according to Bischoff and Bonnet a dog's ovum 2 mm. in diameter is from twelve to fourteen days old. Unfortunately Peters does not describe the condition of the corpus luteum in this specimen, at present the only reliable index by which we can hope to determine the age of young ova. It is imperative that we standardize the corpus luteum of the first weeks of pregnancy and that in all cases when embryos are obtained at autopsy the ovaries should be carefully described and sections of the corpus luteum should be made and pictured.

The ovum of Merttens, 3 × 2 mm., was obtained from a uterine scraping twenty-one days after the last period. Here there was no lapsed period, and twenty-one or fewer days does not seem to me to be an unreasonable age for a human ovum 3 mm. in diameter. That the Peters ovum was older than four days is indicated by the morning sickness that preceded the lapsed period, and, if I am not mistaken, morning sickness is sometimes the first sign of pregnancy.

Among the records of embryos under 5 mm. long I have been able to find thirty-six with menstrual history given (Fig. 147). According to the Reichert-His theory about twenty-five days would have to be subtracted from the ages of twenty-seven of them to make them correspond with the remaining nine. In other words, His would rate nine of them from the last period and twenty-seven from the first lapsed period. We are evidently dealing with two groups of young embryos which correspond with ovulations of two menstrual periods, but which two is still uncertain. Must we add twenty-eight days to each of the group of nine or subtract twenty-eight days from the group of twenty-seven?

The investigations of Bischoff, Dalton, Williams, Reichert, Arnold, Leopold, Leopold and Mironoff, and Leopold and Ravano have shown conclusively that ovulation and menstruation are usually synchronous, but menstruation often occurs without ovulation and sometimes ovulation takes place in the intermenstrual period. In Leopold and Mironoff's forty-two cases ovulation occurs thirty times with menstruation, once without, and ten times there is menstruation without ovulation. The ninety-five selected cases of Leopold and Ravano show that ovulation and menstruation coincide in fifty-nine and are independent of each other in the remaining thirty-six cases. In other words, the connection between ovulation and menstruation is very loose and the two coincide in only two-thirds of the cases. Furthermore, ovulation occurs frequently during pregnancy. [Ravano.]

The data of the other investigators give a similar distribution of ovulations, and there is no marked evidence that ovulation precedes menstruation, as is required if Reichert's theory is true. It is to be hoped that this subject will be carefully studied in some large clinic where many normal ovaries are examined in abdominal operations. Then the age of corpora lutea could be standardized and subsequently applied to autopsy and other cases in which young ova are found in the uterus. In the recent work of Leopold and Ravano only the estimated age of the corpus luteum is used to determine the time of ovulation in relation to menstruation. At the present time their determination of the age of the corpus luteum is the best which we possess, but I believe that it is possible to standardize better the corpus luteum of the first week, that is, those which are formed during menstruation. This must be studied first, then that of the second week, and so on. Through this method we can determine with much greater precision the probable age of a corpus luteum.

At any rate, the separation of young human embryos of the same size into two groups to correspond with two previous menstrual periods indicates that pregnancy usually takes place in the neighborhood of menstrual periods, and facts regarding the duration of pregnancy bear this out. Leuckart tabulated 110 cases of births during the first ten months of married life and found that the maximum number were on the two hundred and seventy-fifth day, after which they fell off and increased again to a second maximum on the two hundred and ninety-third day. He believes that in those cases which came in the first maximum the ovum was obtained from an ovulation which preceded marriage and those that fell in the second maximum belonged to the first menstruation after marriage. He was able to collect eight cases in which the menstrual history was given. In four of them, in which marriage occurred during the third and fourth week after the beginning of menstruation, the women menstruated once after marriage. In the remaining four, in which the marriage followed immediately upon the cessation of menstruation, three did not menstruate again and one menstruated but once before pregnancy. In the second case, where newly-married women do not menstruate at all, we must assume that the ovulation of the last period gave rise to the pregnancy; that ovulation delivered the ovum into the upper end of the tube and soon became fertilized. In the first case the spermatozoa reach the ovary and there await the ovum from the ovulation which takes place with the first menstruation after marriage. It follows from the above that a fertilization immediately before menstruation does not cause the period to lapse, which contradicts the main proposition in the Reichert-His theory. In fact women quite frequently menstruate more than once after the beginning of pregnancy, and at present there are no data to show that a woman who has not copulated since the last menstruation cannot be pregnant. Some additional light is thrown upon the question of the time of conception by a study of the duration of pregnancy as estimated from the last menstrual period as well as from the time of copulation. According to the more recent statistics of Issmer the average duration of pregnancy, in 1220 cases, is 280 days when estimated from the first day of the last menstrual period, and, in 628 cases, 269 days when estimated from the fruitful copulation. In general these two figures correspond with those of Ahlfeld, Hecker, and Hasler, who also collected about 500 cases in which the time of fruitful copulation was given. So in a group of about 1200 cases the duration of pregnancy is fully ten days longer when reckoned from the last period than when from the time of copulation. It may be noted that the data regarding fruitful copulation must be taken with the greatest reserve, for many of them are from unmarried women and in but few of them does the fruitful copulation precede the menstrual period. However, it is remarkable that the results of the different observers are practically the same, each time giving a difference of a week or ten days. Ahlfeld further classified the cases, giving the time of copulation in relation to menstruation.

	On last day of menstruation.	First twelve days after beginning of menstruation.	First seven days after end of menstruation.
	Per cent.	*Per cent.*	*Per cent.*
Married women	35.55	88.44	88.88
Unmarried women	25.49	70.98	70.58

Similar figures are given by Issmer.

Time of copulation.	No. of cases.	Average duration of pregnancy.
First week of menstrual period	172	277 days
Second week of menstrual period	164	279 days
Third week of menstrual period	72	287 days
Fourth week of menstrual period	45	285 adys

From these figures it is seen that most pregnancies take place during the first week after menstruation and that the duration of pregnancy is longer if copulation takes place towards the end of the intermenstrual period. And this is explained if we assume that in the first week, especially the first few days after the cessation of menstruation, the ovum is in the upper end of the tube awaiting the sperm and that conception immediately follows copulation. When the fruitful copulation takes place in the latter two weeks of the month the opposite is usually the case; the sperm wanders to the ovary and there awaits the ovum; and, therefore, on an average, pregnancy is prolonged in this group of cases, when determined from the time of copulation. This explanation fits all the facts but opposes the Reichert-His theory.

We have finally the argument given by comparative embryology. Why should the human ovum be precocious in its early growth? We have good data upon the rabbit, dog, pig, and sheep; and, in general, if we apply the Reichert-His theory, the growth of the human ovum is at first far more rapid than any of them, and is then overtaken by the rabbit when the embryo is 5 mm. long, by the pig at 15 mm., and by the dog at 20 mm. The duration of pregnancy in the rabbit is 30 days; in the dog, 63; in the pig, 120; in the sheep, 154;—why should these animals grow slower at first than man? If the age of human embryos is estimated from the last menstrual period or a few days later, a curve of growth is obtained which corresponds fairly well with that of lower animals.

Possibly it may be allowable to compare early human development with that of the dog. According to Marshall ovulation in the bitch occurs after bleeding from the external opening has been going on for some days, or when it is almost or quite over. It takes place quite independently of coition. Up to this time the bitch will not copulate and unless the act is repeated fertilization does not always take place. Usually the ova are fertilized in the upper end of the tube, and segmentation is practically completed before they enter the uterus.

According to Bischoff the growth of the dog's ovum is as follows:

Diameter of ovum in mm.	0.15	0.14	0.14	0.16	0.16	0.18	0.20	0.21
Age in days	1	2	3	4	5	6	7	8

Diameter of ovum in mm.	0.28	0.30	1.0	2.0	3.0	4.0	5.0	5.0	6.0
Age in days............	9	10	11	12	13	14	15	16	16½

Twelve days after copulation are required before the ovum is as large as Peters's and thirteen days before it is as large as Merttens's. When it is recalled that Merttens's ovum was scraped out of the uterus twenty-one days after the beginning of the last period we are inclined to believe that sixteen to twenty-one days represents its true age. Peters's ovum, on the other hand, must be over "three or four days old"; fifteen is much more nearly its correct age.

In determining the age of human embryos it is probably more nearly correct to count from the *end* of the last period, for all evidence points to that time as the most probable at which pregnancy takes place. The group of cases from which His did not subtract twenty-eight days in forming his curve (for instance, Hensen's embryo, which is 4.5 mm. long and was aborted on the twenty-first day) are probably much older than His thought. They belong to those cases in which women menstruated once after becoming pregnant.

Having determined the time at which pregnancy probably occurs, it is necessary to fix that at which it ends. Not only is it necessary to determine the day but also the probable size of the child, for there is as much variation in the size as in its age. Issmer gives the following figures:

Size of child in cm.	No. of cases.	Age in days, from the beginning of the last menstrual period.
48	203	271
49	272	278
50	252	277
51	211	282
52	123	283
53	34	286
54	18	290

The mean length of the child at birth is 49.5 cm. Hecker found it to be 51.2 cm. in 985 cases, and Ahlfeld a little over 50 cm. If a week is allowed to elapse between the beginning of menstruation and conception then the mean new-born child is 271 days old and is 50 cm. long.

Having fixed the probable relation between ovulation and menstruation it is next necessary to relate each embryo and fetus first to the first day of the last menstrual period and then correct the same to correspond with the probable time of conception. In order to do this it is necessary to establish some standard measurements of the embryo and, if possible, to determine their deviations when expressed in time.

It is known that embryos of other mammals of the same age vary considerably in size unless they are from the same litter, when they are usually very much alike. Undoubtedly there are variations in different animals, and this must be taken into account in comparing human embryos with one another. Also we must not forget that in early abortions there are many pathological specimens, and even if the embryo is normal in appearance pathological conditions are usually the cause of the abortion. This being true the menstrual periods are also far from normal, and it is not unlikely that ovulation is more irregular than normal in these cases. Thus it is often difficult to determine accurately the last period, for it may be complicated by more or less continuous hemorrhage. With all these uncertain factors before us it is certainly remarkable that the specimens can be arranged as well as they are, especially their falling into two sharply defined groups during the first two months of pregnancy.

Until quite recently no serious attempt has been made to determine the age of embryos; it was usually estimated. In order to do this with some precision Arnold measured embryos from head to breech and Toldt from the crown to the soles of the feet (His, 1904). Although this second measurement is called an uncertain one I think that my measurements show that it varies no more than Arnold's (Figs. 145 and 146). These two measurements I consider the best that have been proposed. The first—the crown-rump, vertex-breech, or sitting height—and the second—the vertex-heel, crown-heel, or standing height—are standard ones used by anthropologists in measuring the body after birth. In addition to these, His has introduced a measurement for very young embryos from the elevation on top of the back of the head to the breech, the *Nackenlinie;* but this is of little value in measuring older embryos, and easily leads to confusion. In measuring my own specimens, as well as all those I have found suitably pictured in the literature, my attention was called to the neck-breech measurement and its meaning. As it is usually taken it is of value from the time the embryo is well curled upon itself until the neck is fairly well developed, that is, from the fourth to the seventh week. During this period this measurement is the longest, or is as long as any other, that can be made upon the embryo without stretching the legs. In later stages it equals practically the length of the vertebral column.

In order to make satisfactory measurements upon the bodies of young embryos it is necessary to measure them from more fixed points than is usually done. According to the position of the head the upper end of the longest measurement of an embryo may fall over any portion of the brain, and from a study of numerous specimens I find that the middle of the mid-brain is usually just below the highest point of the head; but whenever this is not the case, as it is found to be in young embryos, I think the measurement should still be taken from a point immediately over the mid-brain, as is shown in Fig. 141, *C.* The other point which I suggest as a desirable one to measure from lies in the mid-dorsal region just above the first cervical nerve, as shown in Figs. 141 and 142, which have the outlines of this nerve drawn in. In Figs. 143 and 144 this point is marked by passing a straight line from the middle of the lens through the external auditory meatus to the back of the head. In both of these specimens this line passes between the atlas and the occipital bone. This gives an upper point, between the skull and the vertebral column, which is below the one from which His drew his *Nackenlinie* and above the depression in the neck from which a number of embryologists make their neck-breech measurements.

I have found from numerous measurements of embryos, fetuses, infants, and adults that a line drawn from the middle of the eye through the middle of the ear and extended to the back of the neck always passes just below the foramen magnum, or slightly higher. For practical purposes it cuts the skull from the body, and according to our knowledge of the position of the eye and ear this should be the case. This line, which I have termed the *oculo-auricular,* or eye-ear line, is of fundamental importance in measuring the length of the spinal column in embryos. Anthropologists obtain the same point between the skull and vertebral column by extending the plane between the two rows of teeth to the back of the head; while art anatomists determine it by projecting a horizontal line through the nasal spine, just below the nares, to the

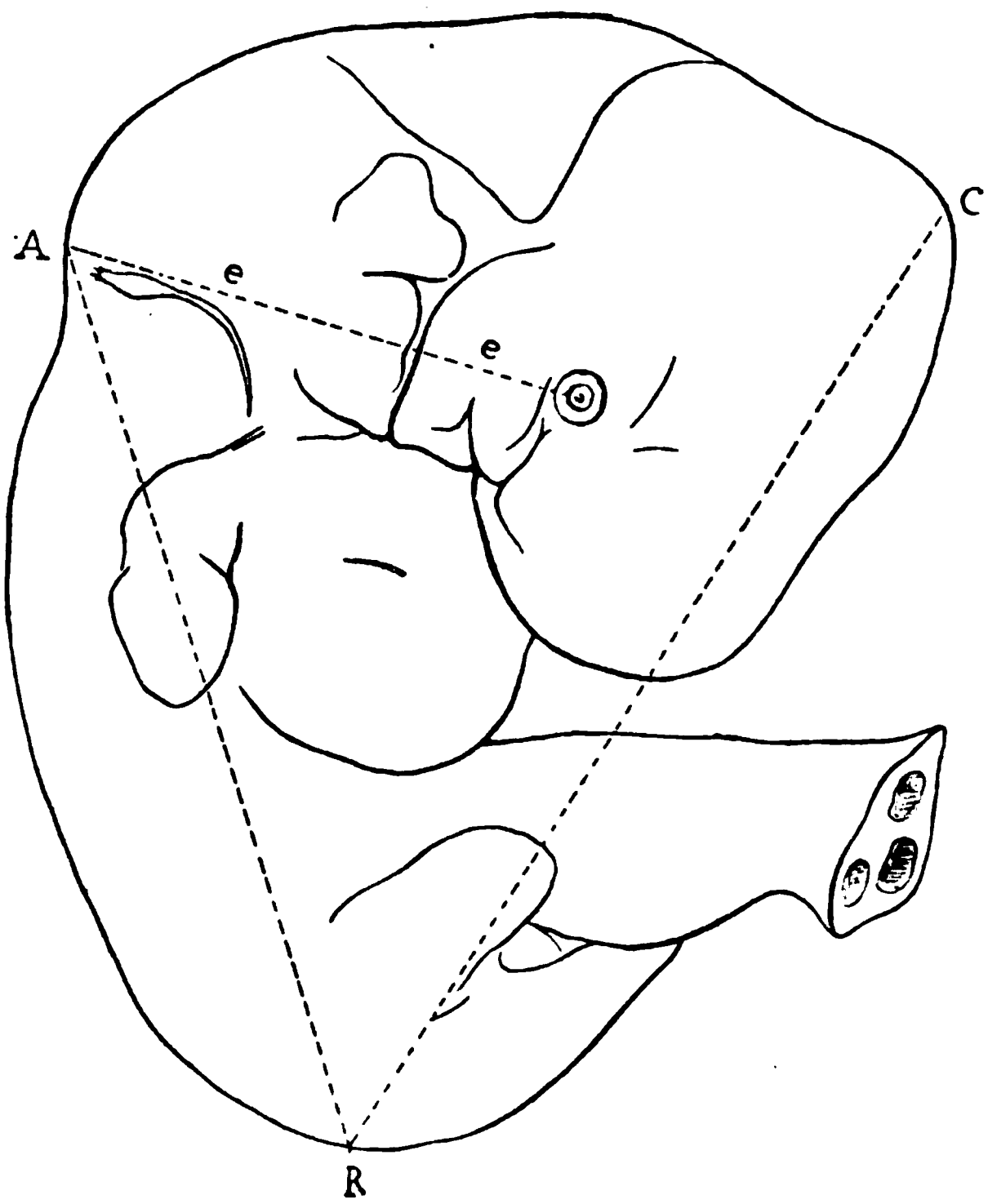

FIG. 141.—Embryo No. 163, × 10 diameters. *C*, crown immediately over the mid-brain; *R*, rump; *A*, point between the occipital bone and the first vertebræ; *ee*, eye-ear line.

back of the head; in both cases the skull is cut off. All three of the lines meet in the adult at the foramen magnum; but in the embryo only the eye-ear line is of practical use, for it can be determined early and with certainty. The height of the skull, which forms the submodulus in the Fritsch-Schmidt canon, can be obtained in any embryo by measuring the distance at right angles from the above-mentioned horizontal line, through the nasal spine, to the crown (Figs. 141–144, *C*), that is, the point immediately over the mid-brain.

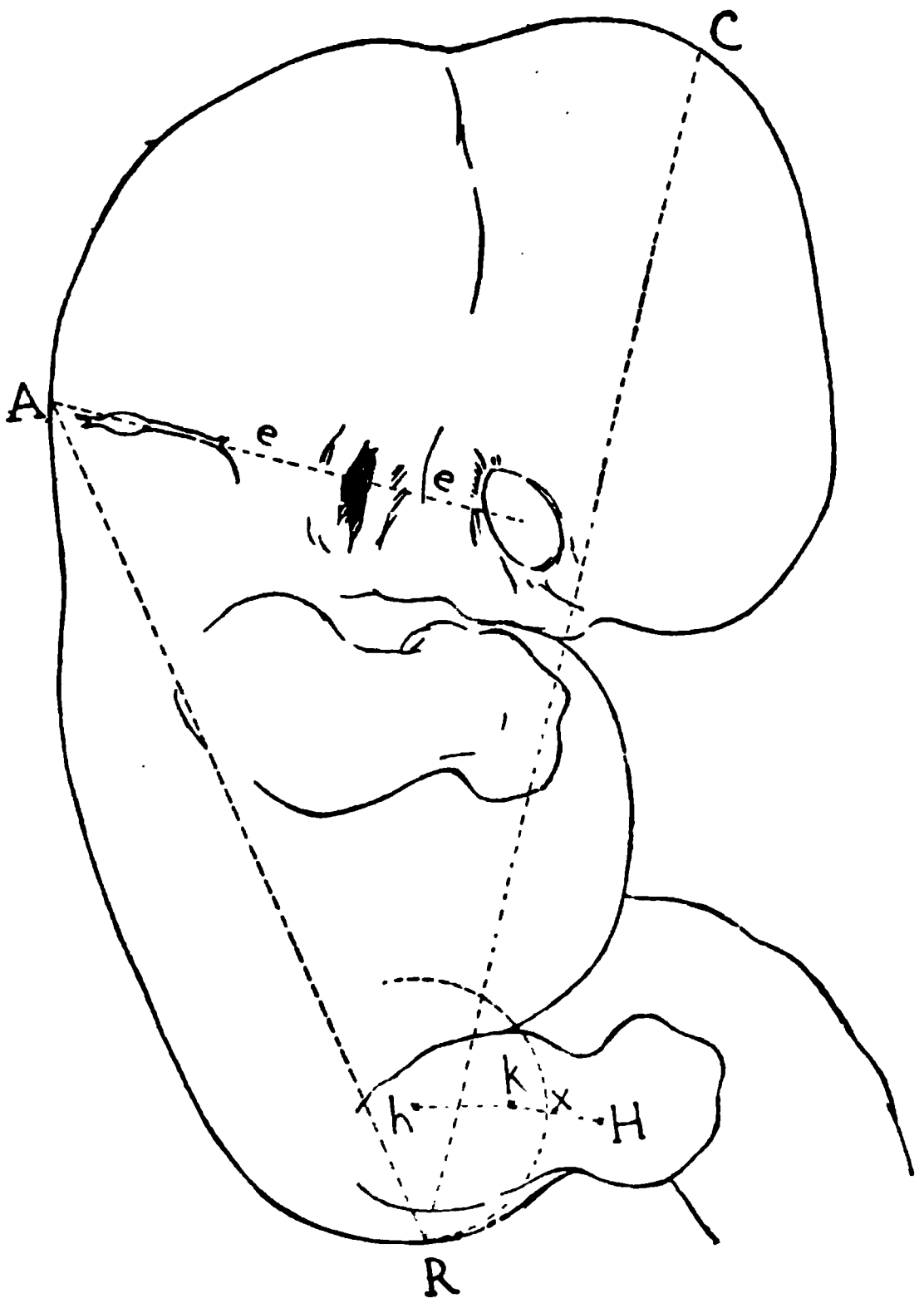

FIG. 142.—Embryo No. 144. × 7 diameters. Letters as in Fig. 141. *H*, heel; *h*, hip-joint; *K*, knee-joint; *x*, point in leg which equals the distance from *h* to *R*. By adding *xH* to *CR* the standing height of the embryo is obtained.

The two upper points from which to measure being fixed just above the atlas and just over the mid-brain, it is necessary to have a lower point in order to measure the length of the head and trunk. All embryologists agree that it be placed at the lowest point of the breech. The line *AR* approximates the length of the spinal column and the line *CR* equals the sitting height of the embryo. These two lines mark respectively the atlantosacral and the mesencephalosacral measurements. In Figs. 141 and 142 the point *R* is exactly below the sacrum, but as the embryo grows longer (Figs. 143 and 144) the ischium gradually recedes; at birth it is considerably below the level of the sacrum. For practical purposes, therefore, the line from the foramen magnum to the rump, *AR,* equals the length of the spinal column. In the adult the tip of the sacrum is at the level of the middle of the acetabulum, and this latter point is naturally chosen by Fritsch in the construction of his canon. On account of the high position of the ilium in both the embryo and the fetus, and on account of the close relation between the lower end of the sacrum and the rump in them, I believe it most desirable to measure to the rump and not to the acetabulum. Furthermore, it makes one of the measurements, *AR,* equal the length of the spinal column, and the other, *CR,* the sitting height of the embryo.

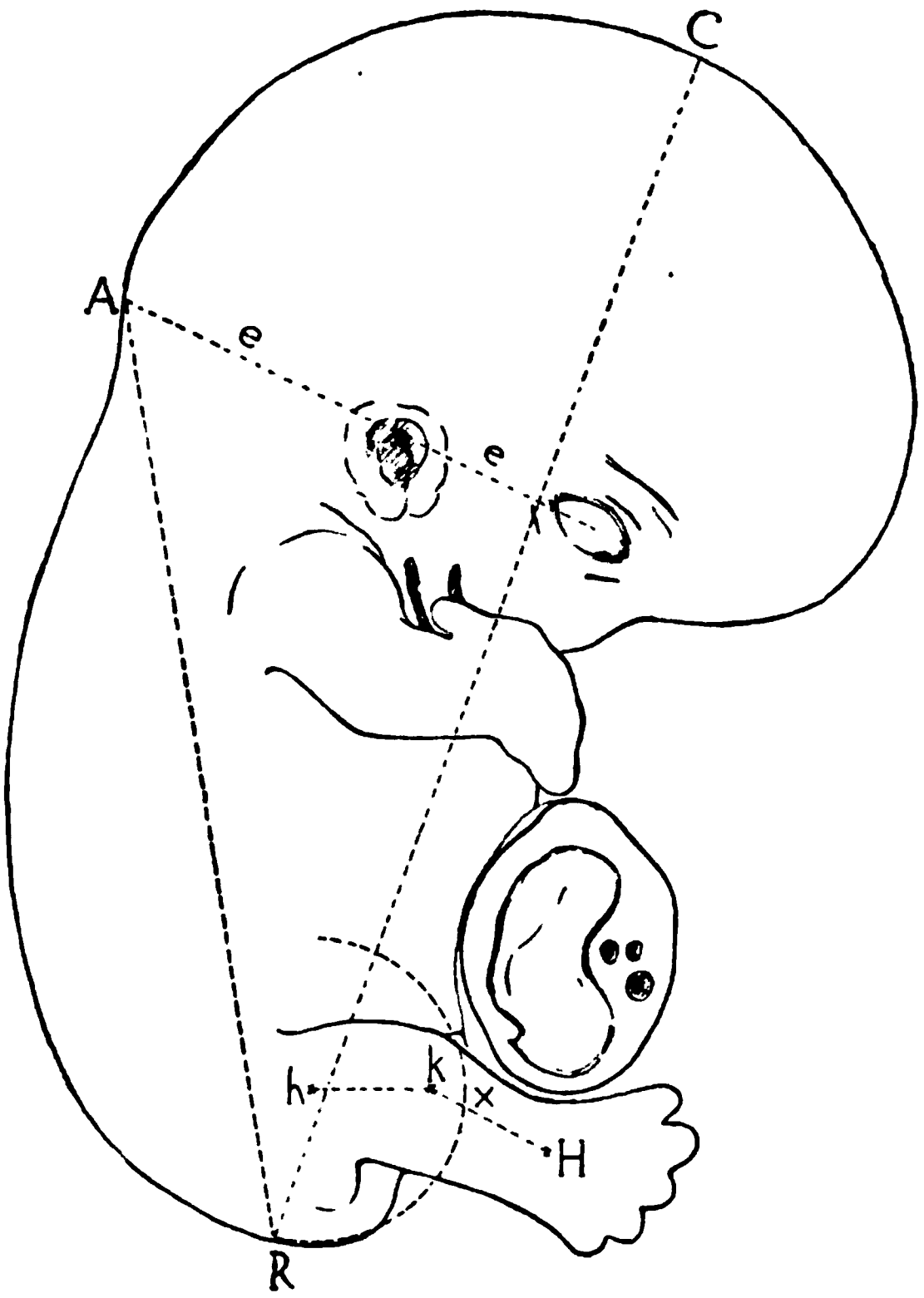

Fig. 143.—Embryo No. 22, × 5 diameters.

A comparison of these two lines upon all four figures shows that in all cases they are the longest lines that can be drawn from the mid-brain and atlas to the rump in each case. Furthermore, as the embryos increase in size the angles these form at the rump become more and more acute. In Fig. 141 the crown-rump line falls far in front of the eye; in Fig. 142 it is just in front, and in Fig. 143 just behind the eye; in Fig. 144 it nearly strikes the ear.

The entire length of the body, the mesencephalocalcanean line, or the standing height of the embryo, is really the best single measurement of the embryo, for it is the one usually made by obstetricians as well as by anthropologists. It has been said that the standing height of embryos and fetuses is an unsatisfactory measurement on account of its uncertainty, but my experience obtained from the measurement of many embryos, Fig. 146, shows that it is no more variable, probably less so, than either the sitting height or that of the spinal column. In Fig. 141 the sitting and the standing heights still equal each other, for, as is easily seen, the leg bud cannot be stretched beyond the rump. The other figures show that by extending the legs the standing height becomes greater than the sitting. In each of the figures the hip- and knee-joints and heel are indicated by letters. If a circle is described around the head of the femur, as has been done in the figures, the portion of the length of the leg to be added to the sitting height in order to obtain the standing height is easily ascertained. In Figs. 142 and 143 this amount is only a portion of the leg, while in Fig. 144 it includes most of the thigh and all of the leg. A number of fresh embryos were measured in this way, the legs were then

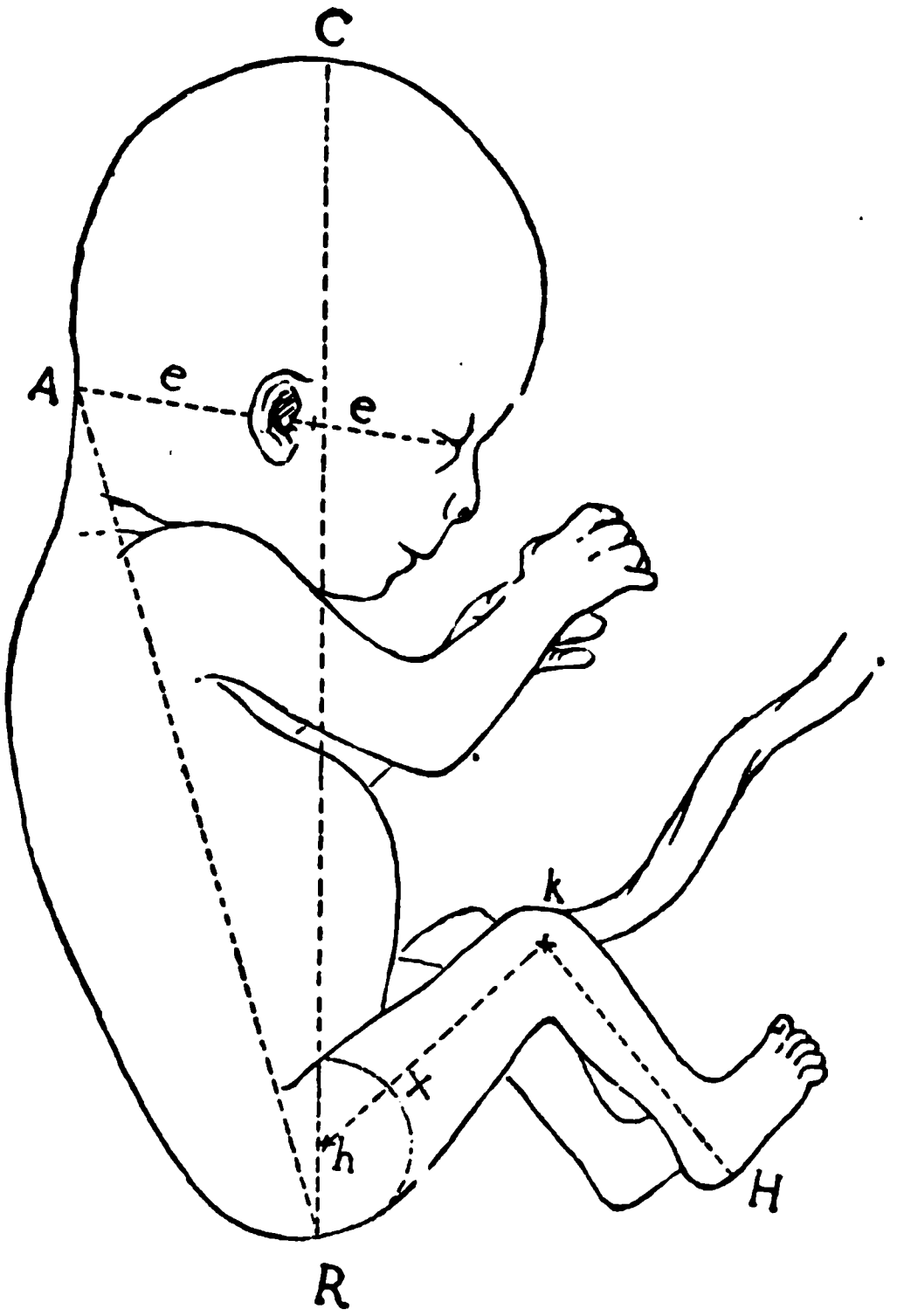

FIG. 144.—Embryo No. 131, natural size. Length of "vertebral column," 68 mm., sitting height (crown-rump or vertex-breech length), 90 mm.; standing height (90 + 21 + 23), 134 mm.

straightened and specimens were again measured from crown to heel, and it was found that the two measurements agreed exactly. By this method, then, the standing height of an embryo can be determined without stretching a fresh specimen or injuring a valuable one after it has been hardened.

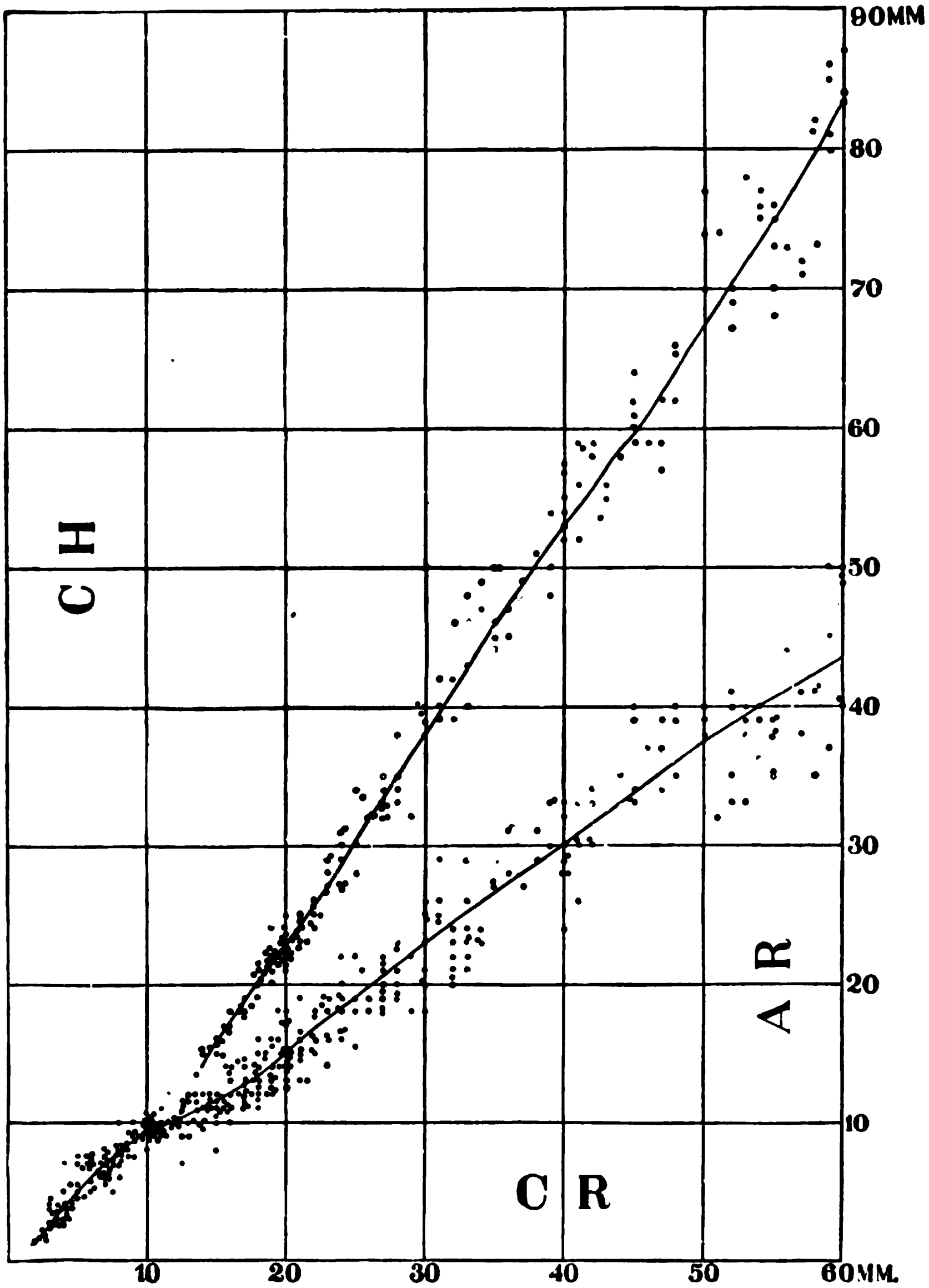

FIG. 145.—Chart giving the standing height (*CH*), sitting height (*CR*), and vertebral column (*AR*) measurements of embryos less than 90 mm. long. The abscissas are *CR*, and the two series of ordinates are *CH* and *AR* measurements. Each dot represents two measurements of an embryo.

By making a large number of measurements of the human body, Pfitzner has demonstrated that the most constant ratio of

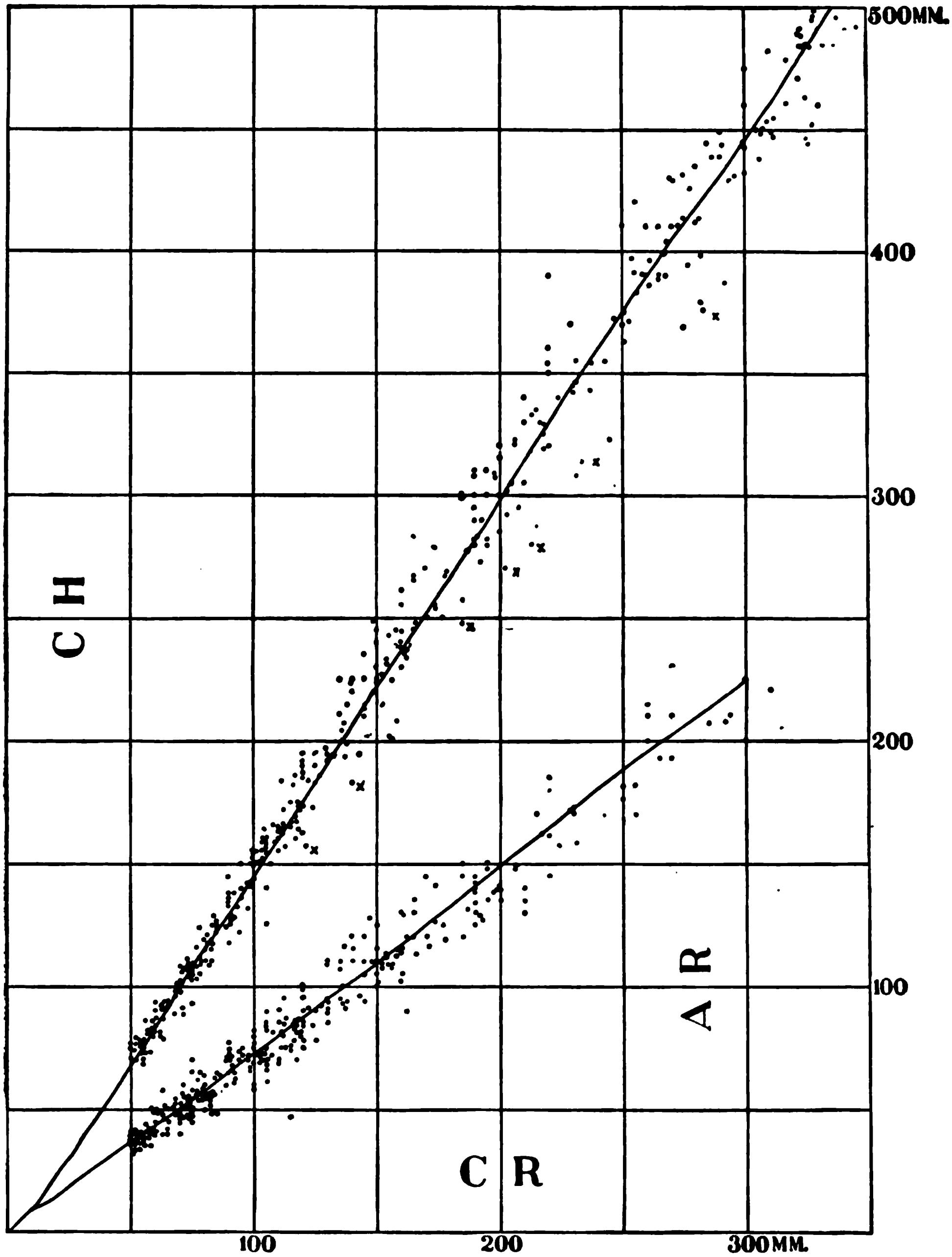

FIG. 146.—Chart shown in Fig. 145 extended to include all fetuses. The lower row of specimens marked x are all from Burtscher's measurements.

any is obtained by dividing the breadth of the head by its length. The mean index for individuals of every year, from birth to old age, is 83 in males and 82 in females. I gather from the figures of embryos and fetuses published by Retzius that in all months of uterine life the index is the same as after birth, for in the individual cases given it ranges between 80 and 85. Were it possible to apply these measurements to all fetuses, I think either the length or the breadth of the head would prove the best standard, and all other measurements could be adjusted to it as the art anatomist has adjusted all proportions to the submodulus. That other measurements are required of the body of the embryo than those that are usually made, including that of the entire length of the body, is indicated by various writers, including His, who was the first to use the *Nackenlinie.* More recently he employed a new measurement which he calls *Kopftiefe,* and which he says corresponds about to the height of the head, measured from the chin to the crown. The *Kopflänge* is the length of the head, a measurement which can easily be obtained if this part of the embryo is not distorted. The point between the occipital bone and atlas having been determined, as is done by the eye-ear line, a second line may be introduced connecting the spine of the nose with it. The longest line within the head of the embryo parallel with this measures the length of the head, and a line at right angles to it extending to the crown measures the height of the head. Thus it is seen that it is possible to make some of the ordinary head measurements of the adult upon the head of the embryo. It may be that the submodulus of Fritsch-Schmidt may yet prove to be the standard measurement in human embryology, comparing all of the other measurements of the body with it, as is the case in the Fritsch-Schmidt canon of the adult. However, this possibility appears to be remote.

It seems to me that for the present we must continue to employ the sitting height or the crown-rump measurement as the standard. Next in importance is the standing height, and, judging by the form of a curve made by abscissas and ordinates to determine the means by the graphic method, I do not find that one is more variable than the other (Figs. 145 and 146). The sitting height is the measurement most easily, and, therefore, the one usually made upon young specimens, and the standing height upon older ones. These two measurements can be compared directly with the two standard measurements made after birth. By means of the eye-ear line the point between the head and neck can be marked and from it the length of the head, and of the skull, may be obtained. That the standing height is just as good a measurement as the sitting height is further found by the experience of Pfitzner, who was at first opposed to it, but after having made many more measurements he selected it as the best standard measurement with which to compare all others. This last statement is based upon the careful measurements of 5000 cadavers.

All the measurements that I have been able to collect from the literature, by correspondence, and from my own specimens, are given in the two curves (Figs. 145 and 146).[1] These were tabulated with the crown-rump measurements as abscissas and the standing heights as ordinates. In the embryos and smaller fetuses a second set of ordinates gives the length of the vertebral column, and it is seen that the deviations here are quite marked. The rows of dots were then divided by curves which included half of the cases, leaving one-quarter on one side and the other quarter on the other. The dots which fell between the two lines mark probable deviations and a line drawn midway between them gives the probable mean. By this method a probable mean is determined in a graphic way from a relatively small number of cases. From the two curves the means of all the measurements in any specimen may be obtained at a glance. This is necessary, for the age of embryos with the standing height given had to be compared with those in which the sitting height is given. In the embryos with a *CR* measurement less than 13 mm. long there is considerable deviation on account of the irregularity of these young specimens, their smallness, and the great probable error in making the *CR* and *AR* measurements. In embryos 13 mm. long the legs begin to grow and the *CR* and *CH* measurements form a very even curve, but the deviation of the *AR* measurement is very marked, showing that it is not altogether satisfactory.

Having remeasured in three directions after a uniform plan all the embryos I could collect it is now possible to tabulate them in relation to the menstrual history, and the curve is by no means as satisfactory as I had hoped it to be. However, it must stand for the present, and new and much better material is needed before it can be revised. Even if we should limit ourselves to specimens got from mechanical abortions, operations, and autopsies we must still reckon on 6 per cent. of abnormalities, which are present in all pregnancies. The cases given in the two curves have been shifted and tested, and again and again controlled by the curves of Hecker, Ahlfeld, Toldt, His, Issmer, and Michaelis, and it seems to me that they are the best that can be done with the data at hand. Towards the end of pregnancy I have allowed Ahlfeld's and Issmer's data to influence my curve a little; for a number of the measurements of my older fetuses came from negroes, and their statements are

---

[1] From the literature: Retzius, Merkel, Burtscher, Sömmerring, Ecker, Kölliker, O. Schultze, Kollmann, Heisler, Minot, His, Frédéric, Fraser, Keibel, Bade, Bonnet, Piersol, Rabl, Tandler, Merttens, Reichert, Peters, Graf Spee, Frassi, Êternod, Thomson, Hensen, Janôsik, Meyer, Stubenrauch, and Wagner.

Through correspondence: From Professors Graf Spee, Laguesse, Hasse, Robinson, Edwards, Hrdlicka, Streeter, Jackson, Bruner, Lee, Meyer, Waldeyer, Brachet, Keibel, Gage, Thomson, Austrian and Mandelbaum.

Together there are over 1000 measurements, of which over 500 have data relating to the age. Fully half of both these are from my own collection.

not as reliable as they might be. At the beginning of the curve I have deviated considerably from His for reasons given above. Toldt's curve is largely an opinion, as he states in his article. The other specimens from the latter months of pregnancy (Issmer, Ahlfeld, and Michaelis) are from exact data and are very reliable. In transferring Michaelis's means I placed it in the middle of the month and not at the end. The His curve is constructed from measurements taken from his "Normentafel," and the higher line gives his *Nackenlinie.* In all other cases the *CH* measurement is given as soon as the legs begin to develop.

The great amount of scattering of early specimens, as shown in Fig 147, is due no doubt in part to an arrest of development, on the one hand, and continued menstruation after pregnancy, on the other. In order to get any kind of agreement His, in the construction of his curve of growth, deducted about twenty-eight days from the age of many specimens in order to make them agree with the rest. However, his curve which I have introduced is an irregular one, unlike the probable curve obtained by tabulating any growing organic body.

Length of embryo in mm.	Days between the beginning of the last menstruation and the abortion.	Only possible time of copulation between the last menstruation and the abortion.	Author.
Embryo anlage, 0.15	38	Exactly 16 days	Bryce-Teacher's monograph, 1908.
Ovum, 5.5×3.3	42	20 days before and earlier	Reichert.
Embryo anlage, 1.3.	34	Exactly 21 days	Êternod: Anat. Anz., vol. xv, 1899.
Embryo, 3.2	48	40 days before and later	His: A. M. E., II.
Embryo, 6	50	38 days before and later	Kollmann's Atlas.
Embryo, 7	49	39 and 41 days before	No. 208.
Embryo, 7¾	57	45 days and later	His.
Embryo, 8.8	42	Exactly 38 days	Tandler: Anat. Anz., vol. xxxi, 1907.
Embryo, 10	60	49 days and earlier	His.
Embryo, 11	55	31 days (?)	Rabl: Entwickl. d. Gesch.
Embryo, 13.6	63	53 days and later	His.
Embryo, 14	65	Exactly 47 days	Rabl.
Embryo, 30	75	Exactly 56 days	No. 26.

There are a few cases in which the time of copulation as well as that of menstruation is given in the history of young embryos. These I have brought together in the above table, and I have also entered them with a * in Fig. 147. That is, the age of the embryo, as rated by the only copulation between the menstruation and the abortion, is also given. From this it is evident that the most probable time of conception is during the first week after the menstrual period, as advocated by Hensen and most obstetricians.

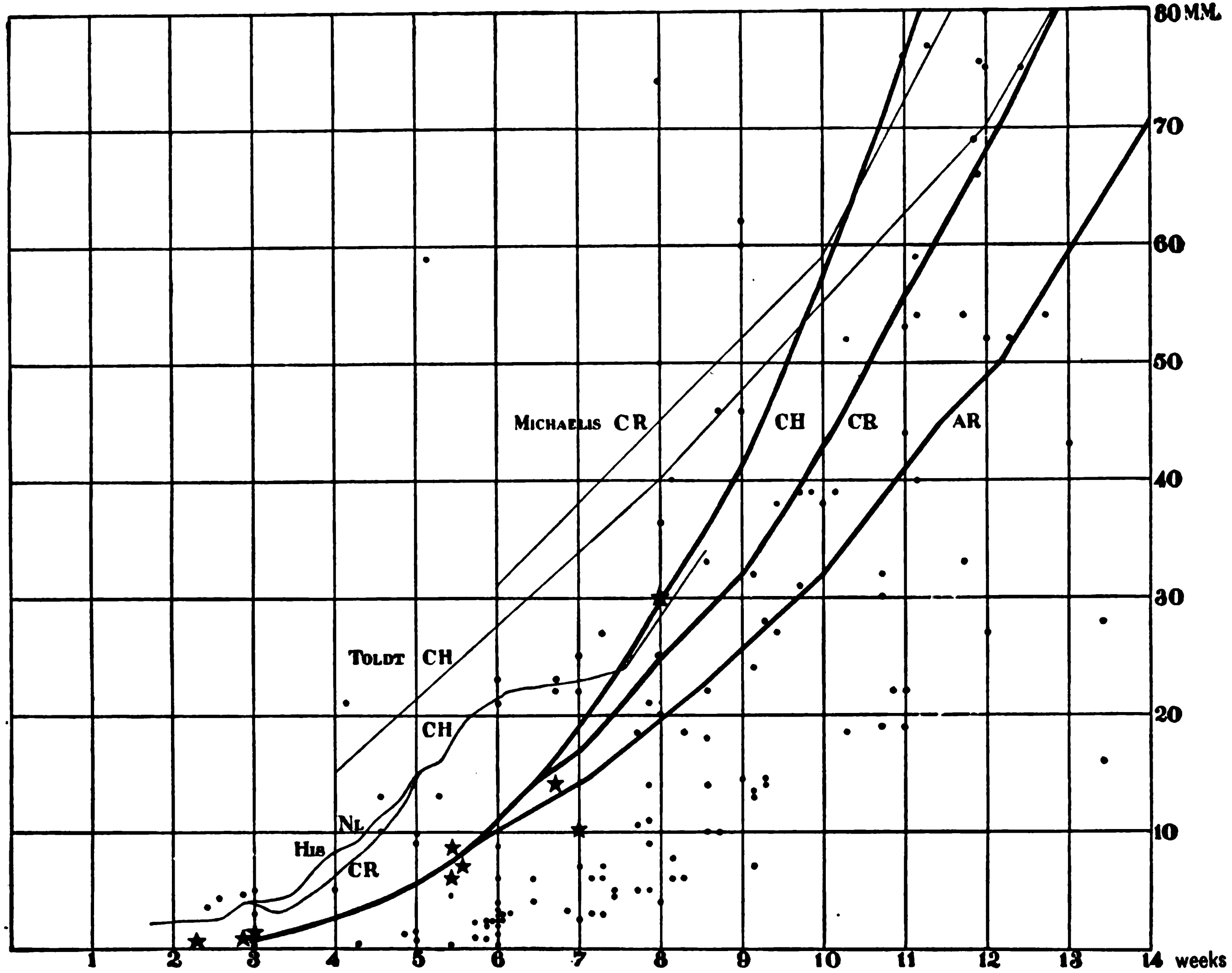

FIG. 147.—Chart giving the specimens with menstrual history in embryos less than 80 mm. long (*CH*). The curves of His, Toldt, and Michaelis are included. My curve is given with all three measurements. The embryos in which the age could also be traced back to a single copulation are inserted a second time and marked with a star (*). Thus an embryo 30 mm. long (*CH*) was aborted fifty-six days after the fruitful copulation and seventy-five days after the beginning of the last menstrual period. The curves marked *CH* represent standing height, *CR* sitting height, and *AR* length of vertebral column.

This view is supported by all the evidence, including that obtained by the study of early human embryos.

Among civilized races copulation does not take place during the menstrual period, and it is believed that it is most likely to be followed by pregnancy if it occurs immediately after the period. Furthermore, competent authorities recommend that women who are anxious to become pregnant should copulate before the period is fully over. If it is true that ovulation takes place towards the end of the period the ovum is most likely to become fertilized if it is met by a host of spermatozoa in the tube. After the spermatozoa have passed through the tube the probability of fertilization is reduced. In such cases pregnancy should occur within twenty-four hours after copulation. If the sperm awaits the ovum, as is the case when the copulation takes place some time before the period, the probability of fertilization is greatly reduced, and if it occurs it is only after the lapse of a number of days. This accounts for the discrepancies given by Issmer. That conditions regarding the relation of fertilization to menstruation and to the œstrous cycle are identical is further proved by the habit of American negroes, who, I am informed by Professor Williams, prefer to copulate during the menstrual period. At this time the odors of the negress are said to excite the passion of the negro and are very attractive to him.

The following table gives the probable deviation of the length of embryos and of the menstrual age, that is, the age as computed from the first day of menstruation. I have also included in it the figures given by Michaelis. Since he gives the mean for each month I have given his data for the last day of the second week, for, as I take it, his mean measurements apply to the middle of the month. The probable age which is the basis for this table is given in the form of a curve in Fig. 148. It may be noted that its form during the first month (Fig. 147) is somewhat drawn out and does not correspond any too well with the curve during the remaining nine months of pregnancy. However, in embryos up to 10 mm. long the *CR* measurement is less than that of the spinal column, while later on it exceeds it. In fact it is the diameter of a circle in very young embryos, while later on it is half of the circumference. This Toldt attempted to correct. The His curve is very irregular in form and for this reason, if for no other, cannot be correct. It falls between Toldt's and mine.

Probable age in weeks.	Probable age in days.	Mean menstrual age.	Probable deviation of menstrual age.* Maximum.	Probable deviation of menstrual age.* Minimum.	Mean length of the embryo (*CH*).	Probable deviation (*CH*).* Maximum.	Probable deviation (*CH*).* Minimum.	Measurement of embryo (*CH*). According to Michaelis.† Mean.	Measurement of embryo (*CH*). According to Michaelis.† Maximum.	Measurement of embryo (*CH*). According to Michaelis.† Minimum.	Mean length of embryo (*CR*).	Measurements of embryo (*CR*). According to Michaelis.† Mean.	Measurements of embryo (*CR*). According to Michaelis.† Maximum.	Measurements of embryo (*CR*). According to Michaelis.† Minimum.	Mean of greatest diameter of ovum.‡	Mean of intermediate diameter of ovum.‡	Mean of smallest diameter of ovum.‡
1	7																
2	14														[2.]¶	[1.5]	[1.]
3	21	31	42	19	.5	4.5	0				.5				5	4	3
4	28	37	49	25	2.5	10.0	0				2.5				14	9	9
5	35	43	55	32	5.5	15.0	0				5.5				24	17	15
6	42	51	62	40	11	25	4				11				34	29	22
												31	40	25			
7	49	59	70	48	19	37	9				17				42	36	29
8	56	65	76	55	30	50	15				25				52	44	37
9	63	72	84	61	41	66	22				32				60	51	43
10	70	79	91	68	57	86	33				43				71	58	49
												59	67	53			
11	77	86	98	75	76	105	45				53				80	64	54
12	84	94	105	83	98	135	68				68						
13	91	100	111	89	117	155	80				81						
14	98	108	119	96	145	178	113				100						
								149	185	105		113	132	78			
15	105	114	125	103	161	190	130				111						
16	112	121	133	109	180	210	155				121						
17	119	128	140	117	198	230	172				134						
18	126	136	146	125	215	243	187				145						
								223	293	196		148	184	112			
19	133	143	154	132	233	265	207				157						
20	140	150	162	137	250	283	227				167						
21	147	157	171	144	268	305	245				180						
22	154	165	179	151	286	320	256				192						
								295	346	245		188	240	108			
23	161	171	186	156	302	323	270				202						
24	168	177	192	162	315	345	282				210						
25	175	185	201	170	331	362	300				220						
26	182	192	207	176	345	380	315				230						
								331	370	308		222	242	197			
27	189	199	214	183	358	400	327				237						
28	196	205	221	189	371	413	340				245						
29	203	212	229	195	384	430	355				252						
30	210	219	239	200	400	447	370				265						
								397	453	353		260	290	225			
31	217	228	250	206	415	473	385				276						
32	224	234	259	210	425	485	393				284						
33	231	241	267	215	436	500	403				293						
34	238	248	279	219	448		413				301						
								443	477	385		289	320	264			
35	245	256	288	224	460		421				310						
36	252	262	296	228	470		430				416						
37	259	271	308	234	484		440				325						
38	266	276	315	237	494		445				332						
38½	270	280	320	240	500		450				336						

* " Probable deviation " includes half of the measurements.

† The data of Michaelis are placed in the middle of the month.

‡ Includes 140 specimens.

¶ Figures in brackets are estimations.

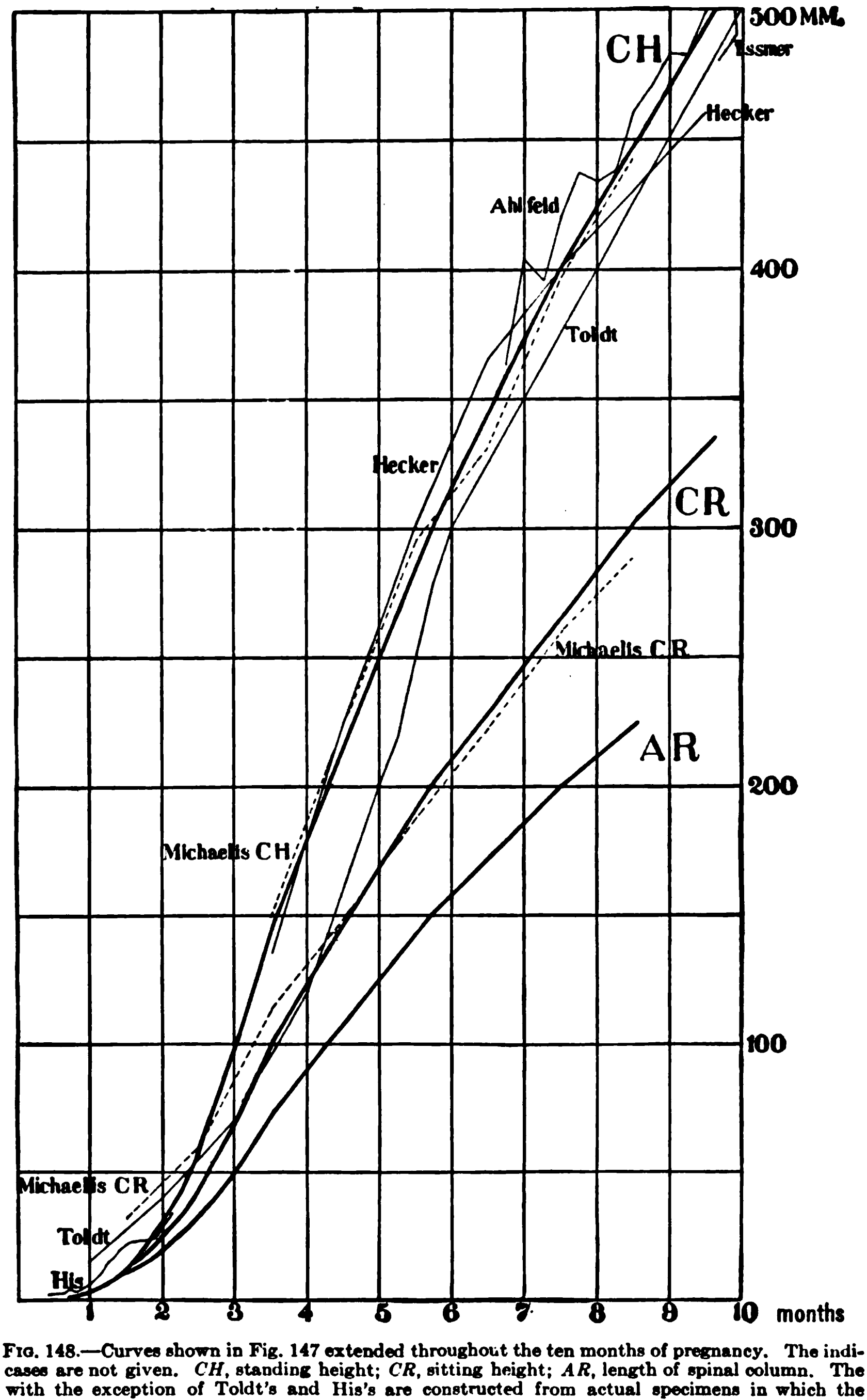

FIG. 148.—Curves shown in Fig. 147 extended throughout the ten months of pregnancy. The individual cases are not given. *CH*, standing height; *CR*, sitting height; *AR*, length of spinal column. The curves with the exception of Toldt's and His's are constructed from actual specimens in which the menstrual history is given. Toldt's is an estimation based upon the literature. His's is an estimation based upon the Reichert-His theory.

BIBLIOGRAPHY.

AHLFELD: Monatsschrift für Geburtskunde, vol. xxxiv, 1869.
ARNOLD: Inaug. Diss., Würzburg, 1887.
VON BAER: De Ovi Mammalium et Hominis Genesi. Epistola, Leipzig, 1827.
Entwicklungsgeschichte der Tiere, 1828.
BISCHOFF: Beweis der von der Begattung unabhängigen periodischen Reifung und Lösung der Eier der Säugetiere und des Menschen als erste Bedingung ihrer Fortpflanzung, Giessen, 1844.
Entwicklung des Hundeeies, 1845.
BONNET: Beiträge zur Embryologie des Hundes, Anat. Hefte, vol. ix, 1897.
Entwicklungsgeschichte der Haussäugetiere, 1891.
BRYCE and TEACHER: Contributions to the Study of the Early Development and Imbedding of the Human Ovum, Glasgow, 1908.
DALTON: The Corpus Luteum of Menstruation and Pregnancy, Philadelphia, 1851.
FRITSCH: Die Gestalt des Menschen, 1899.
HASLER: Inaug. Diss., Zürich, 1876.
HECKER: Klinik für Geburtskunde, 1861.
HENSEN: Hermanns Handbuch der Physiologie, vol. vi, 1881.
HIS: Anatomie menschlicher Embryonen, Leipzig, 1880.
Die Entwicklung des menschlichen Gehirns, Leipzig, 1904.
ISSMER: Arch. f. Gynäkol., vol. xxxv. (For literature upon the history of the duration of pregnancy, 1889.)
KEIBEL: Normentafeln, vol. i, 1897.
LEOPOLD: Arch. f. Gynäkol., vol. xxi, 1883.
LEOPOLD and MIRINOFF: Arch. f. Gynäkol., vol. xlv, 1894.
LEOPOLD and RAVANO: Arch. f. Gynäkol., vol. lxxxiii, 1907.
LEUCKART: Wagners Handwörterbuch der Physiologie, vol. iv, 1853.
LOEVENHARDT: Arch. f. Gynäkol., vol. iii, 1872.
MALL: Johns Hopkins Hospital Reports, vol. ix, 1900; also Jour. Morph., vol. xix, 1908. (Both papers give many of the measurements which are used in the construction of the tables and figures of Chapter VIII.)
On Measuring Human Embryos, Amer. Jour. Anat. (Anat. Record, No. 6), 1907.
MARSHALL: Phil. Trans. Roy. Soc., 1905.
MERTTENS: Zeitschrift f. Geburtsh. und Gynäkol., vol. xxxix, 1894.
MICHAELIS: Arch. f. Gynäkol., vol. lxxviii, 1906.
MINOT and TAYLOR: Kiebel's Normentafeln, vol. v, 1905.
PETERS: Einbettung des menschlichen Eies, Leipzig und Wien, 1899.
PFITZNER: Zeitschrift f. Morpholog. und Anthropolog., vols. i and v, 1899 and 1903.
RAVANO: Arch. f. Gynäkol., vol. lxxxiii, 1907.
REICHERT: Beschreibung einer frühzeitigen menschlichen Frucht im blasenförmigen Bildungszustande, Abh. Kgl. Akad. Wiss., Berlin, 1873.
RETZIUS: Biol. Untersuch., vol. xi, 1904.
STRASSMANN: in Von Winkel's Handbuch d. Geburtsh., vol. i, 1903.
TOLDT: Prager med. Wochenschrift, 1879.
WEYSSE: The Blastodermic Vesicle of Sus Scrofa, Proc. Amer. Acad. of Arts and Science, vol. xxx, 1894.

IX.

THE PATHOLOGY OF THE HUMAN OVUM.

By FRANKLIN P. MALL of Baltimore.

A large percentage of human ova that are obtained by embryologists are quite unlike the normal ones and therefore they need special study. From comparative embryology we have learned that in normal development the tissues are transparent and sharply defined, and that the organs of the embryo and its membranes maintain constant proportions in each stage of development. Any marked variations from these constants, which are as yet not well established, are to be viewed as anomalies, but if they are accompanied by distinctive tissue change of a pathological nature we view the ovum containing them as diseased or pathological. When the pathological processes of the ovum are pronounced the villi are atrophied and irregular; the chorion is thin and transparent, or thick and hemorrhagic; the embryo is usually dwarfed in an irregular fashion; the exocœlom is often filled with an excessive amount of dense reticular magma; and there is usually hydramnios with a granular deposit in the liquor amnii. These are the chief changes which are easily seen by a superficial observation of a pathological ovum, and since all of the changes are relative their recognition depends absolutely upon a knowledge of the normal form and relation of the structures within the ovum.

Seventy-five years ago Granville made a report of forty-five aborted ova, a few of them having complete histories, in which he concludes that the chorion is first diseased and that this in turn results in retarding the growth of the embryo. He also notes that an inflammatory condition must have been present in the uterus, for the abortion of pathological ova is usually accompanied with great pain and excess of bleeding. For the present I shall not consider the etiology of pathological ova, reserving this question for the conclusion of the chapter.

It is well known that the larger number of abortions occur during the second and third months of pregnancy, and according to Hegar there is one abortion in the early months of pregnancy for every eight or ten births at term. "A conservative estimate indicates that every fifth or sixth pregnancy in private practice ends in abortion, and that this percentage would be increased considerably were the very early cases taken into account, in which there is a profuse loss of blood following the retardation of the menstrual period for a few weeks" (Williams). Fully twenty per cent., then, of all pregnancies end in abortion and but 80 per cent. continue to full term.

Only a portion of aborted ova contain normal embryos which, judging by their state of preservation, were alive a short time before they were expelled. According to His, embryos which are slightly malformed, that is, young monsters, are occasionally seen, and their condition shows that they were living at the time of the abortion. His further states that he observed two specimens of spina bifida, several of anencephaly, one of ectopia of the liver, and one of cleft palate in ova that were sent to him in the course of several years. I have had a similar experience. By far the largest percentage of the specimens, however, contain embryos to which His applies the collective term abortive forms, characterized by a general arrest of development.

His also noted that among the embryos sent him by his colleagues 22 per cent. were pathological, while in those sent him by midwives it rose to 40 per cent. In the first group there had been some selection in the specimens. My own experience, as well as that of Giacomini, is similar to that of His, for physicians have a tendency to send good specimens only, and therefore we are of the opinion that the correct percentage of pathological ova among early abortions is considerably higher than indicated by His's statistics. My own records include 434 specimens (Nos. 1 to 404 in my catalogue) of all ages, among which there are 163 pathological ova and embryos of various ages. Among them there are 151 normal and 138 pathological embryos of the first two months of pregnancy, that is, in embryos less than 32 mm. long. For the sake of comparison I have arranged my data in chronological series parallel with those given by His.

Total number of Normal and Pathological Ova of the first two months.

	No. of normal.	No. of pathological.	Percentage of pathological.
His's collection from all sources..................	62	18	22
His's collection, only the specimens obtained from midwives....................................	19	12	40
My collection, first series........(Nos. 1 to 126)	61	28	32
My collection, second series .....(Nos. 127 to 208)	24	37	61
My collection, third series.......(Nos. 209 to 379)	52	65	56
My collection, whole number ....(Nos. 1 to 404)	151	138	48

It may be noted that the percentage of pathological embryos in my first series is much less than in the subsequent series, a difference similar to that found by His in his two series. At first, before 1898, there was also a tendency for physicians to send me the normal specimens, but since then I have repeatedly urged them to send me all specimens, and during the past ten years the pathological ova of the first two months of pregnancy have been about 50 per cent. These data are sufficiently good to be considered representative for America—especially Baltimore. It may be, and I think it will probably prove to be, that the percentage of pathological embryos will vary markedly in different communities and in different classes of society, to correspond with the frequency of uterine troubles as well as with the tendency towards sterility.

My own statistics show also that there are about twice as many pathological ova in abortions of the first month as are found in those of the second month. The statistics arranged in two groups are as follows:

Number and Percentages of Pathological Ova during the First and Second Months of Pregnancy.

	Normal.	Pathological.	Percentage of pathological.
Less than 5½ weeks old (0–8 mm.).			
Catalogue numbers, 1–208	26	33	56
Catalogue numbers, 209–404	18	45	71
Catalogue numbers, 1–404	44	78	59
From 5½ to 9 weeks old (8–32 mm.).			
Catalogue numbers, 1–208	59	32	35
Catalogue numbers, 209–404	48	28	37
Catalogue numbers, 1–404	107	60	36
Totals of the above (0–32 mm.).			
Catalogue numbers, 1–208	85	65	43
Catalogue numbers, 209–404	66	73	53
Catalogue numbers, 1–404	151	138	48
Total for all months.			
Catalogue numbers, 1–404	271	163	38

In the first month the low percentage of pathological ova, in Nos. 1–208, is due to the fact that no effort was made to collect them before No. 127. Up to No. 127 the percentage of the pathological is 44, but between Nos. 127 and 404 it has been constantly above 70. The figures and percentages for the second series (Nos. 209 to 404) are, therefore, representative.

According to Marchand 615 monsters were found among 81,187 births, and these figures with the data I have just given enable me to give the probable number and percentage of abortions and of monsters found in every 100,000 pregnancies.

	Pregnancies.	Births.	Normal embryos aborted.	Pathological ova aborted.	Monsters born at term.
Number	100,000	80,572	11,765	7,048	615
Percentage	100	80	12	7	0.6

The above table has been constructed from Williams's statistics regarding the frequency of abortion, from Marchand's on births and monsters, and from the percentage (38) of pathological ova and embryos I have found among 434 abortions. This table permits the following statement. Eighty out of 100 pregnancies end in the birth of normal individuals; seven are aborted as pathological ova containing radical changes within them; and about one (0.6) produces a monster at term. The remaining twelve "normal" fetuses and embryos are by no means all normal, for we are constantly finding in them, especially the younger specimens, minor changes which must be viewed as forerunners to real monsters. Teratology will not be on a satisfactory scientific basis until many embryos with minor changes have been studied with as much care as Fischel has recently studied several young embryos with spina bifida, and until the norm has been established with greater precision for every stage of development.

The line of demarcation between normal and pathological embryos is by no means sharply defined; in all probability a number of the so-called normal embryos are slightly deformed or abnormal and we must continue to sharpen our conceptions of the norm. Even those specimens that are obtained directly from the uterus in operations or in autopsies are by no means necessarily normal, for a large percentage of all pregnancies contain pathological ova. The probabilities in favor of monstrous embryos is even greater in tubal pregnancies; and we should be most cautious in declaring embryos obtained from them normal, even if they are well formed and are transparent and alive when they come into our hands. In passing judgment upon any given specimen we must continue to rely upon its comparison with well-known embryos of record, as well as with the structure of other mammalian embryos. Any deviation from the norm as thus determined should be viewed with grave suspicion, for it is likely to be pathological in nature.

His has pointed out that the state of preservation of an embryo is of much value in determining whether it was alive or not at the time of abortion. An embryo which is sufficiently transparent, or still translucent enough, so that the blood-vessels and other structures within can be recognized, was probably alive shortly before or at the time of abortion. Such an embryo is also probably normal. When they are hardened in formalin or other suitable preservatives their external contour is in beautiful even curves, and their sections show the boundaries of the organs and the histological details sharply defined. These conditions, however, only indicate that a specimen is in all probability normal. There is always the possibility that an embryonic monster with but slight changes has been aborted early in the pregnancy, and as more young embryos are studied we find the percentage of them is larger than we anticipated.

Poorly preserved specimens, that is, those which show signs of maceration before they were fixed, are not necessarily pathological; their condition may be due to post-mortem changes, either before or after the abortion. In case their death took place within the uterus a certain number of them may show changes in the amnion and chorion, but even in these cases we are not necessarily dealing with abnormal embryos. Abnormal conditions of the uterus may kill a normal embryo without causing it to become monstrous or to abort. In fact, it seems to be quite common for the act of abortion to extend itself over a number of days, and if such abortions are due to the death of the embryo it is natural that it should undergo some maceration before it is born.

These views, given almost verbatim from His, are now quite generally entertained; but I think it likely that he emphasized too much the early and complete death of the embryo before the abortion. At the time he first wrote upon this subject he believed that the primary cause which produced pathological ova lay in either the germ or the sperm before fertilization, but in his last contribution to this subject he expressed himself in favor of the view that the changes in pathological ova are of a secondary nature due to external influence. In fact, recent work in experimental teratology, as well as my own studies of pathological human embryos, bears out this view. In this chapter hereditary malformations, like polydactyly and muscle anomalies, are not considered. Pathological embryos, experimental monsters, and human monsters at term form a class by themselves, inasmuch as they are produced from normal ova through causes which lie in their environment.

Embryos that die suddenly are usually aborted at once, and if they are not they macerate and disintegrate but do not continue to grow in an irregular fashion as do pathological embryos. The latter become rounded, grow into nodules or into cylindrical forms, but do not die immediately. Judging by the well-preserved state of the tissues so frequently encountered, especially the epidermis, I am inclined to the belief that they lived up to the time of the abortion. However, viewed with the naked eye, the embryo is usually opaque, the borders of the internal organs are quite obscure, and no blood-vessels are seen through the skin. Furthermore, the sharp outlines of the branchial arches, head, hands, and feet are often wanting; the embryo is not dead, but has grown in an irregular way, just as do fish, frog, and bird embryos when experimented upon. Not only are the protruding parts of the embryo atrophic, but the tissues do not move with sufficient rapidity to bring about the proper form of the subsequent stage, thus producing all kinds of arrestments of development, for example, spina bifida, anencephaly, and cleft palate. In other words, monsters of all varieties and of all degrees of intensity are produced in the first months of pregnancy. As a rule, the changes in them are so radical that they lead to their own destruction and they are aborted. According to the table given above twelve monsters are aborted for each one that develops to the end of a normal pregnancy.

FIG. 149.—Ovum of 105 × 65 × 65 mm., containing a markedly pathological embryo 9 mm. long. The cavity of the amnion is filled with a large mass of granular magma. Three views of the embryo are also shown.

There are, however, other characteristics of pathological ova that are more recognizable to the naked eye than are those of the embryo. The most apparent of these is the diminished size of the embryo, first described by His (Fig. 149). In order to make this statement it is necessary to determine the relative size of the embryo and chorion in different stages of development. The figures of His, which are given in the first two columns of the following table, show that the length of the embryo is about one-fifth of the diameter of the ovum in younger stages and one-third in older ones.

Table giving the Relation between the Diameter of the Chorion and the Length of the Embryo in Various Stages. All the Measurements are in Millimetres.

Chorion.	Normal according to His. Probable deviation.	Normal (106 specimens).		Pathological (77 specimens).	
		Extremes.	Probable deviation.	Extremes.	Probable deviation.
From 1-15	2- 4	0.2- 4	0.2- 3.5	0- 5	0- 3
From 25-30	4-10	2.0-23	3.5-10.0	2-17	3- 7
From 25-40	10-15	4.0-23	7.0-16.0	3-20	5-10
From 35-50	15-20	6.0-33	13.0-24.0	2-32	8-14
From 40-60	20-25	6.0-45	16.0-32.0	2-32	10-19
From 60-80		23.0-50	32.0-42.0	4-56	19-30

The measurements of the chorion include the villi, which may add somewhat to the great amount of variation in the different columns. I think it would have been better if the villi had not been included, for they are also a variable quantity, especially in pathological ova.

FIG. 150.—Ovum containing deformed embryo 5 mm. long.

In the table I have placed after His's figures my own for both normal and pathological ova. It will be noticed that my probable deviations vary considerably more than those of His, while the extremes do so still more. In fact the probable deviation is so great that only in extreme cases is the ratio of the length of the embryo to the diameter of the chorion of any value in determining whether or not the embryo is pathological. However, the measurements of the pathological embryos in general are less than those of the normal, especially in the larger ova. In a few instances the embryos are larger than the normal, which really should be interpreted the other way round, *i.e.,* the chorion is too small for the embryo and is markedly fibrous, while the embryo is nearly normal. Only in the extreme cases, therefore, are "embryos 4–5 mm. long found in chorions 4.5–5 cm. in diameter, or embryos 2.5 mm. long in chorions 3.5–4 cm. in diameter " (His).

His also pointed out that pathological ova containing small monsters usually have marked hydramnios. In normal development the amnion hugs the embryo quite closely until the beginning of the sixth week, when its cavity enlarges more rapidly than the embryo, and by the beginning of the third month of pregnancy grows to obliterate the exocœlom. In pathological ova, however, large dilated amnions are found containing small atrophic embryos. In other words, hydramnios is frequently found, just as is the case when experimental terata are produced in hens' eggs. All of this speaks decidedly against the prevailing amniotic theory of the cause of monsters, which is dependent upon hypothetical amniotic bands and contraction of the amnion early in development. In addition to the hydramnios found so frequently in pathological ova the walls of the chorion are often very thin and transparent (Fig 150), or thick and hemorrhagic (Fig 151); and the villi, which are unequally and poorly developed, are scattered over the chorion in an irregular manner (Fig 152). In such ova the villi are sometimes arranged in small groups forming islands, between which there are large bare spaces composed of the main wall of the chorion only (Fig. 155).

In normal development the exocœlom is filled with a mass of delicate fibrils which bind the amnion to the chorion. These fibrils, which do not seem to be connected with cells, give the fluid of the exocœlom a jelly-like consistency and form the main part of the magma réticulé of the older authors. As the amnion advances and encroaches upon the cœlom the fibrils of the magma gradually form in a layer which finally rests between the amnion and chorion after the exocœlom is obliterated. A second group of pathological ova in which there is no hydramnios often have their exocœloms stuffed with magma réticulé, and Giacomini has shown that its excessive development always indicates that the ovum is pathological. My own experience fully confirms that of Giacomini.

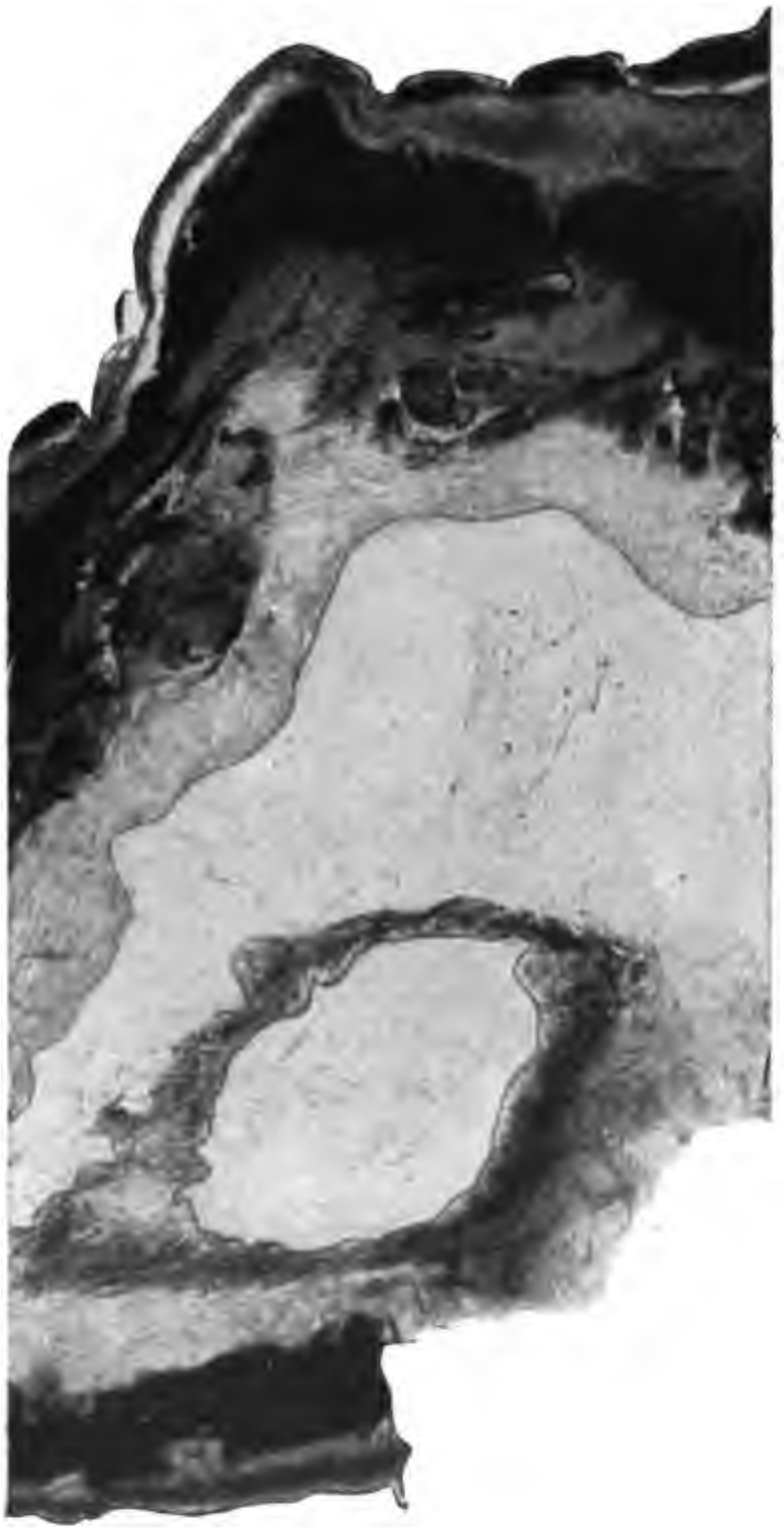

Fig. 151.—Section of a hemorrhagic chorion with the adjacent yolk sack. The deformed embryo was 4½ mm. long. The walls of the umbilical vesicle contain many blood-vessels which communicate directly with those of the chorion.

All stages of an excessive development of the magma are seen, from those in which the fibrils are but slightly accentuated to those in which they form a dense hyaline mass (Figs. 153 and 154). In many respects the fibrils look much like those of fibrin, but they do not give Weigert's fibrin reaction. As the magma grows and becomes more fibrous it also often undergoes a granular degeneration (Figs. 156 and 157), and pathological magmas are therefore of two varieties, which I have termed reticular and granular respectively. Nor is the magma always confined to the exocœlom in pathological ova; it may also penetrate the amnion and more or less fill its cavity (Fig. 160). However, this is rare in the case of reticular magma, that within the amnion being nearly always granular in nature (Fig. 161). In pathological ova irregularities in development may be seen. The magma may become too extensive, the amnion may grow too rapidly, or in relation to the growth of the chorion the embryo's development may be retarded. The changes are no doubt due to retarded development of some portions of the ovum rather than to death of the entire structure.

FIG. 152.—Pear-shaped ovum, 30 × 20 × 10 mm., with most of the villi destroyed.

It was mentioned above that His gradually became convinced that pathological embryos were due to secondary changes in embryos which had been normal, a view advanced long before by Granville. He came to this conclusion on account of his study of the structure of pathological embryos which showed abnormal changes in successive stages of development. Were the difficulty germinal in origin these changes should be successive from the smallest to the largest pathological embryos, and they should not arise from various stages of normal embryos (Figs. 162 and 163). The real condition of things pointed towards the environment of the ovum and not to the germ for the cause of the abnormality. It was difficult for His to come to this conclusion, because at first he was of the opinion that ordinary monsters in the narrower sense are due to primary changes in the germ.

His did not examine the membranes of his specimens microscopically, but he has repeatedly referred to changes in the chorion of pathological ova which are recognizable with the naked eye. In fact, if special care is not taken in the examination of the chorion of these specimens, one is often inclined to think they are normal, and this error has been committed by both Giacomini and myself. However, Giacomini recognized that in some instances the chorion is not altogether normal in structure, which he thought might be due to secondary changes after the death of the ovum, either before or after the abortion. In my own case I was gradually led to believe that there were two classes of pathological ova, one in which the primary trouble is in the chorion, and the other in the embryo. In the first group the embryo is dwarfed and in the second it is destroyed altogether. This conclusion was based upon anatomical study, for in the first group the chorion is usually pathological and in the second it often appears to be normal. However, more recent studies, with better material than I had at first, show an ever-increasing number of pathological membranes in both groups (Figs. 165–168), and I think that this classification of pathological ova must be abandoned. It appears now that the membranes of nearly all pathological ova are pathological, and, what is more, the decidua, syncytium, and chorion are frequently affected in specimens containing apparently normal embryos. The borderline specimens can not be considered satisfactorily at present because they have not been investigated sufficiently.

FIG. 153.—Embryo 3 mm. long, embedded in a dense mass of réticulé filling the exocœlom.

FIG. 154.—Ovum 32 mm. in diameter, stuffed with a dense mass of magma réticulé, within which there is a pathological embryo.

My more recent investigation of this question shows that the chorion is diseased in 113 out of 132 pathological specimens studied. The nineteen in which the chorion is said to be normal show changes in the decidua in a few cases, and the rest are mostly older specimens before formalin was used. Fifteen of them are ova without embryos, that is, specimens in which the embryonic mass was destroyed at a very early date. In some of these the chorion and decidua are undoubtedly normal in every respect. A specimen 6 mm. in diameter, which had been scraped out of the uterus on account of chronic endometritis, was perfectly developed, the decidua, syncytium, and villi being normal; but it contained no embryo and the cœlom was filled with magma réticulé and strands of mesoderm cells from the chorion (Fig. 169). But in this case there is a history of uterine trouble which may have been of sufficient importance to affect the embryo at a very early stage in its development. Comparative experimental teratology supports this view.

FIG. 155.—Photograph of an ovum of 50 × 30 × 30 mm., covered with irregular villi.

The distribution of the specimens into normal and pathological chorions is given on page 224 with the table on the distribution of the embryos. It shows that in all but a few cases in which the embryo was present the membranes were also pathological.

The changes in the chorion may now be briefly given. The most common of all is a fibrous degeneration. The mesoderm, instead of being beautifully transparent and of even structure, becomes coarse and fibrous, with the nuclei closely packed together. There may be atrophy or hypertrophy of the villi, as well as of the main wall of the chorion. Next we have œdematous, mucoid and hyaline changes in the villi, in which there is a tendency to destroy their structure; in these there are also often vacuoles and larger spaces containing granules. These changes may be found in villi side by side with others that are normal, showing that the chorion may have both destructive and constructive changes going on in it at the same time. In fact this must also be the case in normal development, but until the norm of the growing chorion is established very little can be said about this process. In the present state of our knowledge pathological changes in the chorion must be very marked in order to be recognizable.



FIG. 156.—"Shadow" of an embryo 3½ mm. long lying within the magma of the ovum shown in Fig 155

In many pathological ova the blood-vessels of the chorion undergo degeneration long before the embryo becomes necrotic, as may be seen from the discussion of this question in my large monograph. Or blood-vessels may be present after the embryo is destroyed entirely. At first I was inclined to think that in this latter instance it was necessary to assume the presence at one time of an embryo nearly 2 mm. long, for at this time the vessels grow from the embryo to the chorion in normal development. Recently I have observed the growth of blood-vessels, in several specimens, passing directly from the yolk sack to the chorion, which proves that it is unnecessary for the body of the embryo to develop in these cases (Fig. 170).

Fig. 157.—Piece of an ovum (18 × 14 × 14 mm.) showing a large clump of magma in the cœlom.

The chorion also shows all kinds of changes of its syncytium. It is often deficient, irregular, or necrotic, or intermixed with leucocytes, which may form small abscesses in it. In some instances, which are not rare, both syncytial cells and leucocytes invade the mesoderm of the chorion, and thereby hasten its destruction. The changes in the decidua are harder to follow, because it rarely remains attached to the chorion and is usually lost. However, in some instances it was found infiltrated with leucocytes, often in large groups, when the rest of the chorion appears

Fig. 158.—Section of the chorion of Fig. 157, showing a large nest of syncytium invading its wall.

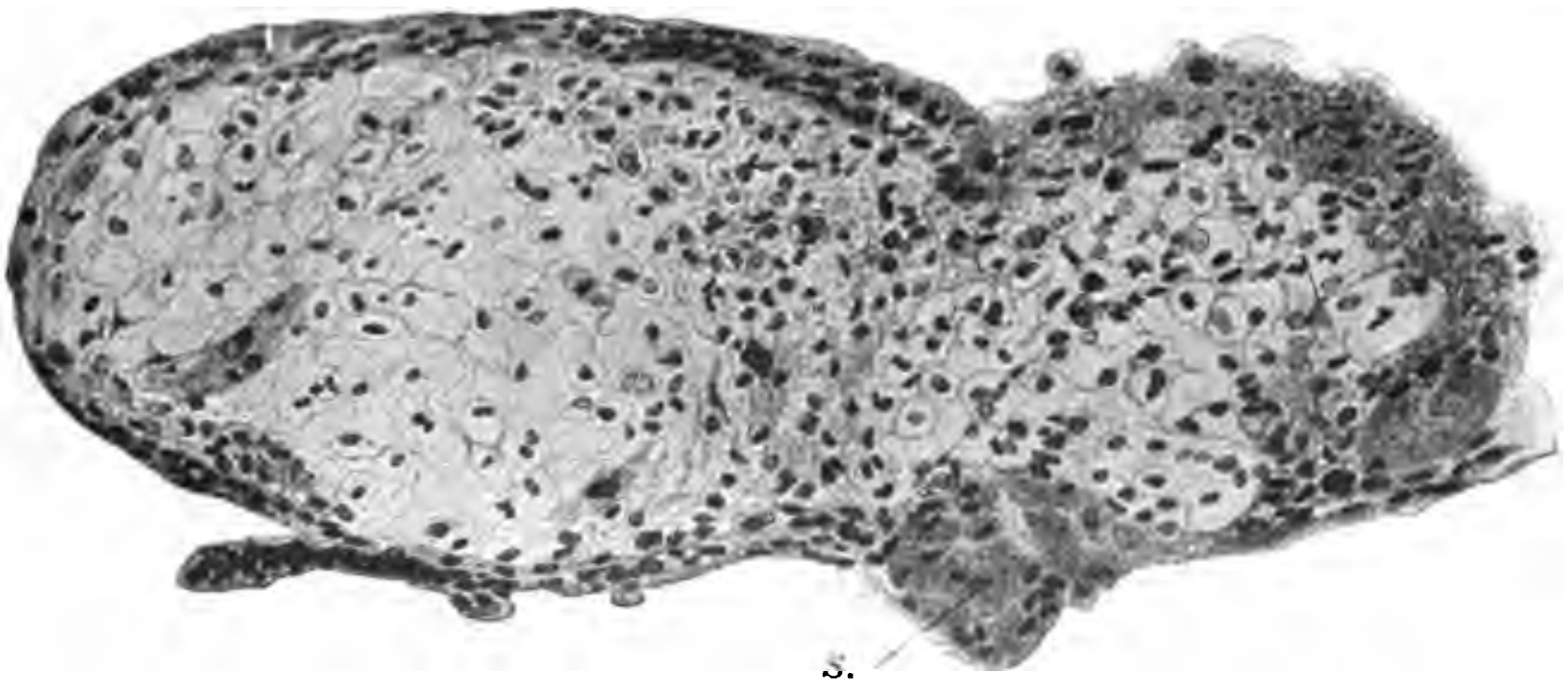

Fig. 159.—Section of the villus of the ovum shown in Fig. 157. *S.*, syncytium.

to be normal. Above all, this structure is in need of much more careful study than it has received before the chain of evidence of pathological ova is complete. However, one point is certain, disease of the chorion is as common as are pathological embryos, and the two usually coincide.

FIG. 160.—Ovum containing a "normal embryo" 20 mm. long with considerable magma réticulé within the amnion.

In nearly all of the pathological ova a peculiar stringy substance dotted with numerous very fine granules is seen between the villi (Fig. 171). This fibrinous or mucoid mass extends between the villi after covering their tips. Within it numerous leucocytes are frequently seen (Fig. 174), and into it nests of syncytium often grow. However, the latter do not radiate and spread as they do in normal growth, but instead they form clumps or rounded ends at the tips of long strands of cells. It appears as if they fail to receive their proper nutrition from this substance, which is no doubt pathological in its origin. The constancy of mucoid substance in pathological ova and the general relations of the tissues which come in contact with it makes of it a valuable sign of the pathological state. It is of especial value for this purpose, as it is present in the earliest pathological specimens before any other marked changes have taken place in the walls of the chorion (Figs. 175 and 176).

FIG. 161.—Ovum 50 mm. in diameter with the embryo incrusted in granular magma.

Pathological embryos were first classified by Panum in his experimental study of early monsters in the hen's egg. This classification is used as a basis by His for pathological human embryos and therefore will be given in full. Panum found that there were two great groups of monsters: (I) those in which the whole embryo is involved, and (II) those in which but a part of it is affected. Under the first group there are the following subdivisions: (1) flattened forms, that is, the shape of the germinal area is not markedly changed; (2) flattened forms with the production of red blood, that is, the embryo only is affected; (3) cylindrical forms, the embryo becoming abnormal later in its development; and (4) amorphous forms. The forms brought together by Panum under the first group (I) correspond in many respects

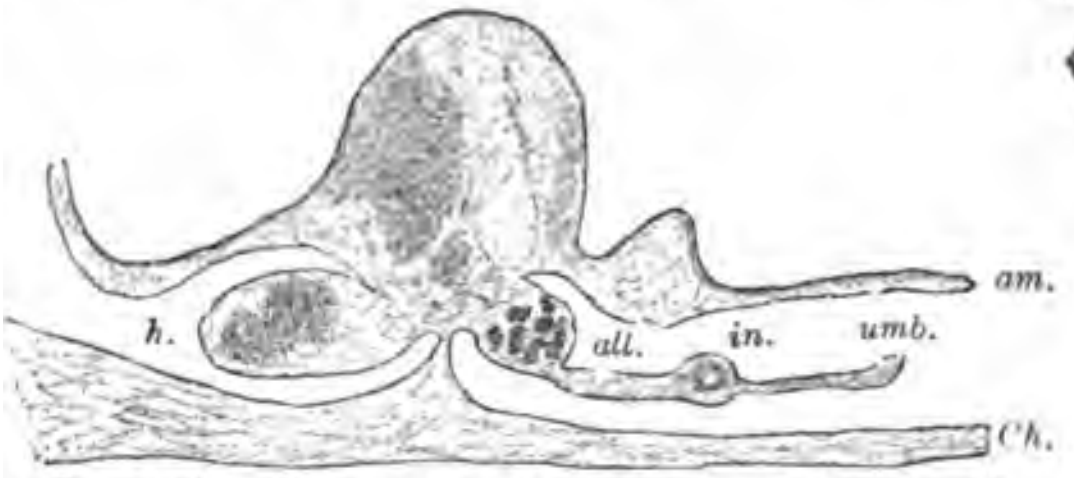

FIG. 162. — Deformed embryo one mm. long found within an ovum measuring 70 × 30 × 30 mm. *Ch.*, chorion; *am.*, amnion; *h.*, heart; *umb.*, umbilical vesicle; *in.*, intestine; *all.*, allantois, or possibly the liver.

FIG. 163. — Section of a pathological embryo 8 mm. long. The face is destroyed entirely.

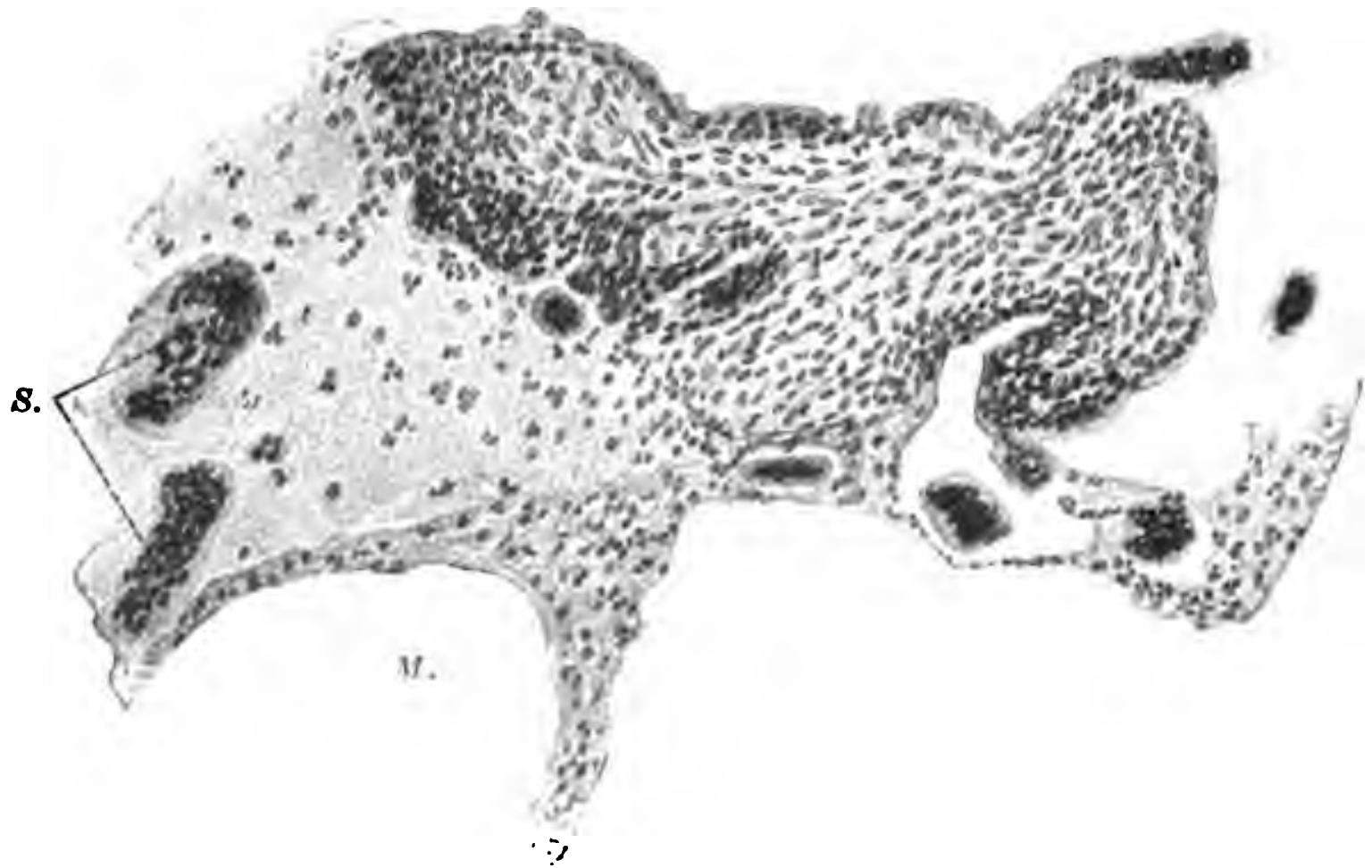

FIG. 164.—Section of fibrous villus invested by leucocytes and syncytium, from the specimen shown in Fig. 163. *M.*, strands of mucus; *S.*, nests of syncytium.

to those described by His in his classification. Among them His found three main groups of pathological embryos: (1) nodular forms, in which the embryo is largely destroyed leaving but a small mass of tissue; (2) atrophic forms, in which the embryo is more or less distorted; and (3) cylindrical forms, older embryos than those classed under (2), in which the head has usually suffered most by the pathological process. It is easy to see the similarity between the cylindrical forms of Panum and His in chicks and in human embryos; in both it appears as if the pathological process began quite late in development. Amorphous forms can be compared with the nodular forms of His; in both cases the pathological process began quite early in development and produced radical changes in the body of the embryo. His's atrophic, abortive, or

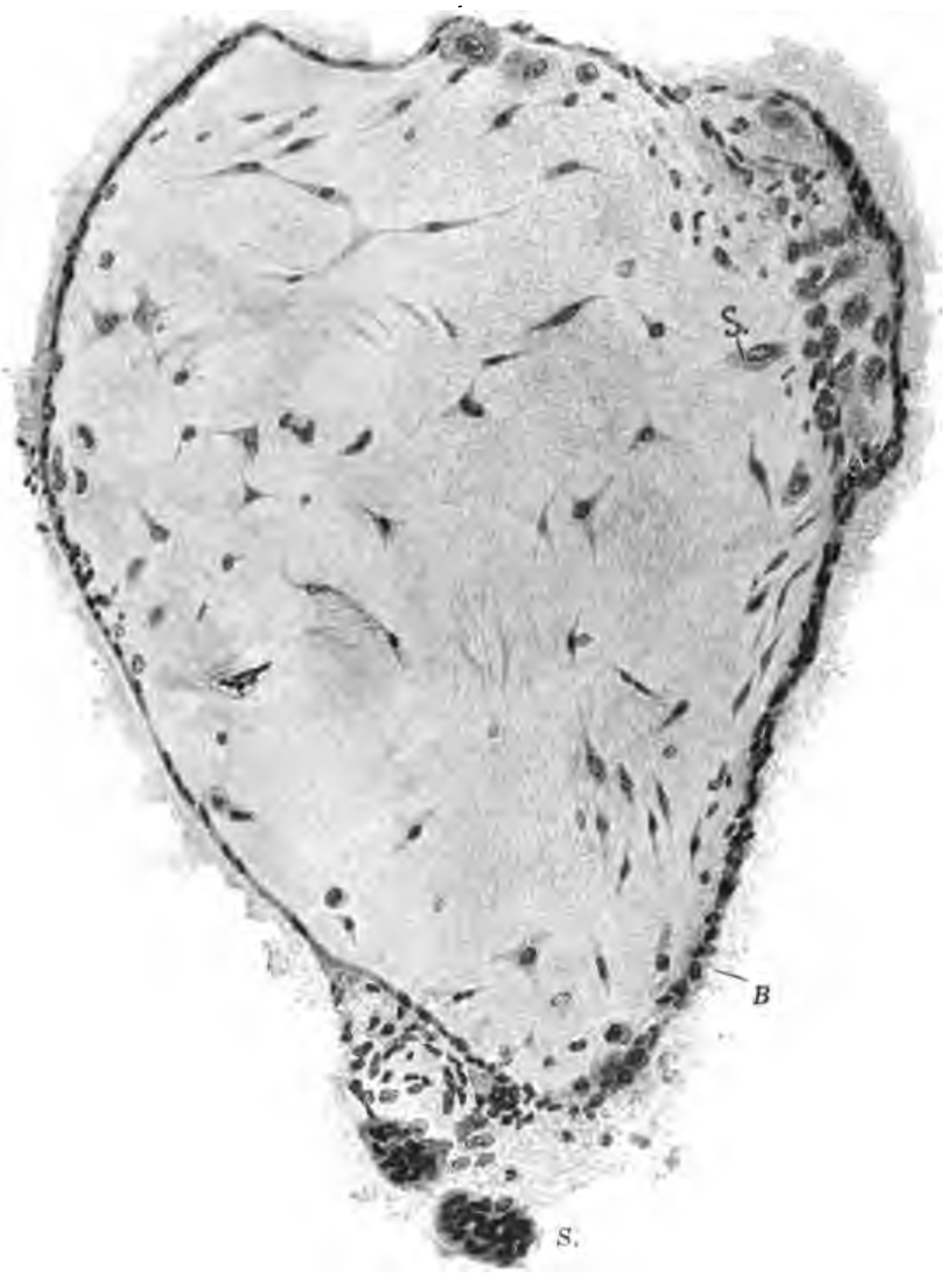

FIG. 165.—Section of a villus from an ovum measuring 70 × 40 × 30 mm. *B.*, blood; *S.*, syncytium, single cells of which are scattered throughout the mesoderm.

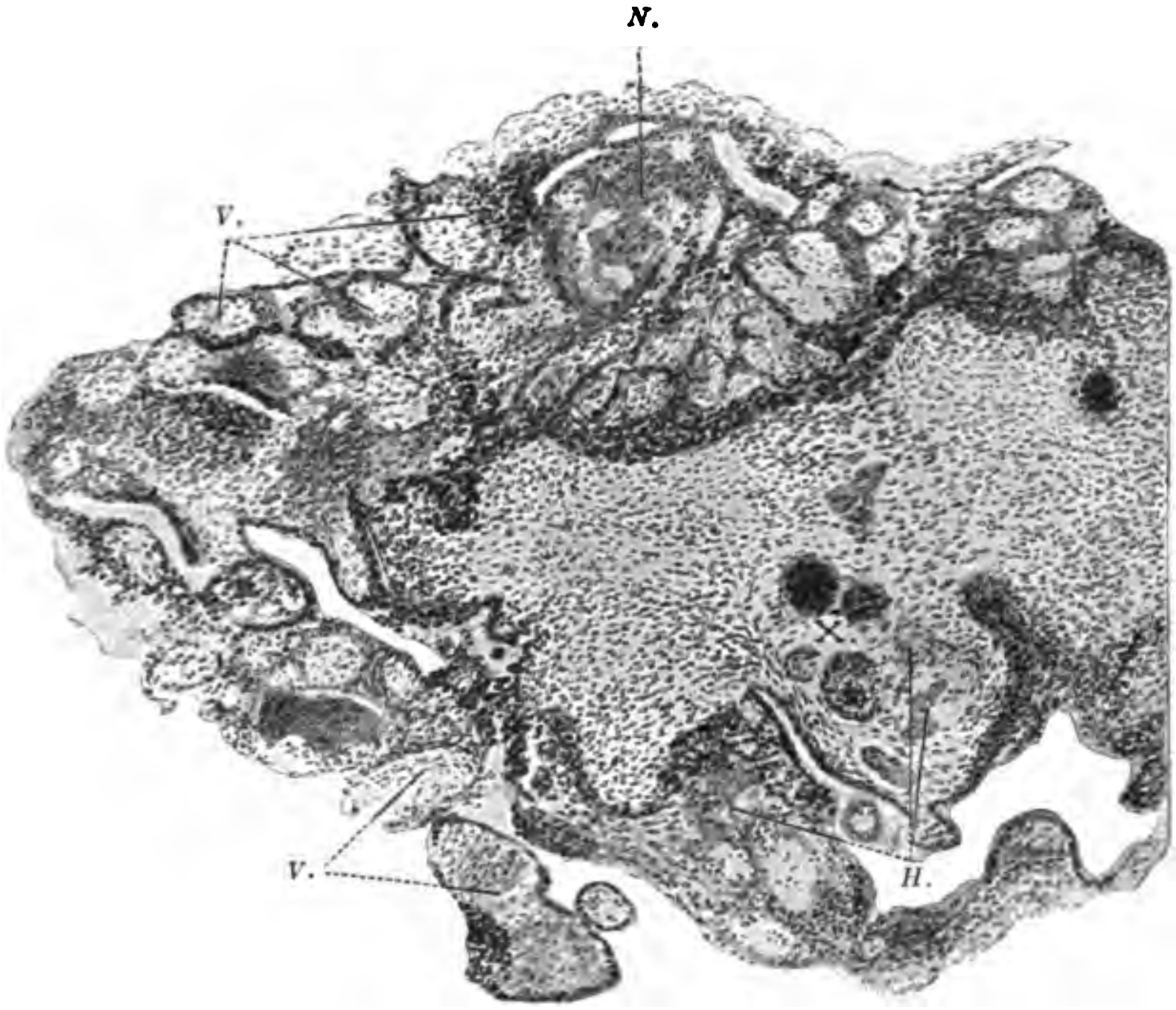

FIG. 166.—Section of a villus from an ovum of 100 × 50 × 40 mm., containing an embryo 60 mm. long. *V.*, villi; *N.*, necrotic villus and syncytium; *H.*, hyaline degeneration of the mesoderm and syncytium; *X.*, peculiar masses of cells in the mesoderm, probably degenerated blood-vessels.

FIG. 167.—Ovum (10 × 7 × 5 mm.) from a tubal pregnancy. Some of the villi are degenerated, others are nearly normal and contain blood-vessels, but no trace of the embryo could be found within.

degenerative forms are composed generally of small embryos, younger than the cylindrical forms and older than the nodular forms.

His did not recognize a class in which the embryo is destroyed entirely (Panum's class II, 2), for he had never seen a human ovum without an embryo. However, such specimens are not rare; Giacomini has described a number of them, and I have found many more. So in Giacomini's classification there are two main groups: (I) those in which the embryo is missing, and (II) those in which the embryo is present, but deformed. Under the second group he recognizes His's nodular and atrophic forms. In the first group he classes the ova according to the presence or the absence of an amnion, and he also gives a third group which presupposes that the embryo has the power to wander and migrates through the cavities of the ovum or out of it entirely. I consider this group unnecessary and fantastic; it includes ova in which the embryo has been displaced by mechanical means.

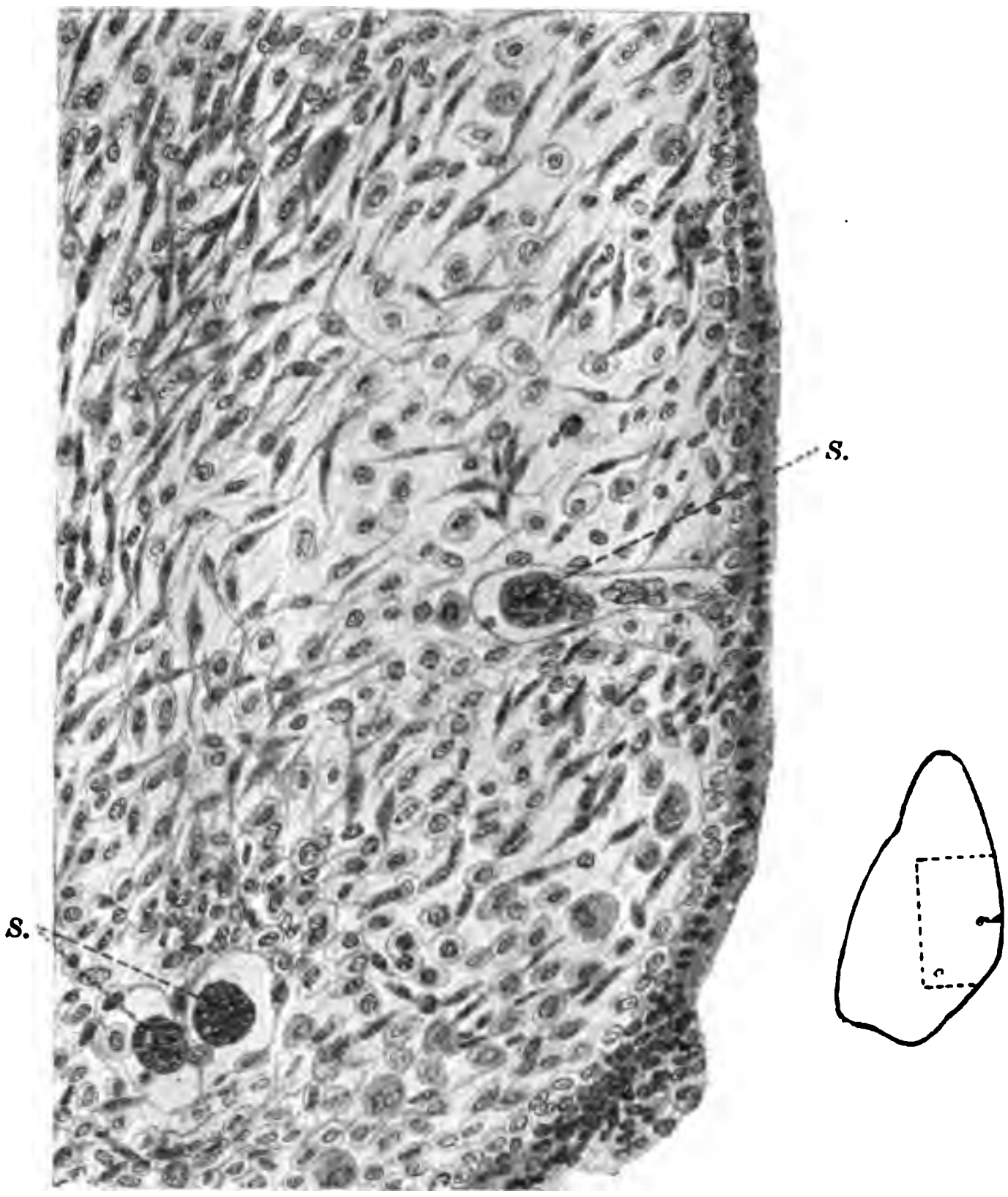

FIG. 168.—Section of a villus from an ovum of 35 × 25 × 15 mm. Large groups of syncytial cells, *S*, are invading the mesoderm.

FIG. 169.—Section of the chorion with strands of mesenchyme cells in the cœlom in an ovum 6 × 4 mm. in diameter. *M.*, Mesenchyme cells; *Ch.*, wall of the chorion; *E.*, nest of epithelial cells, probably the remnant of the embryo.

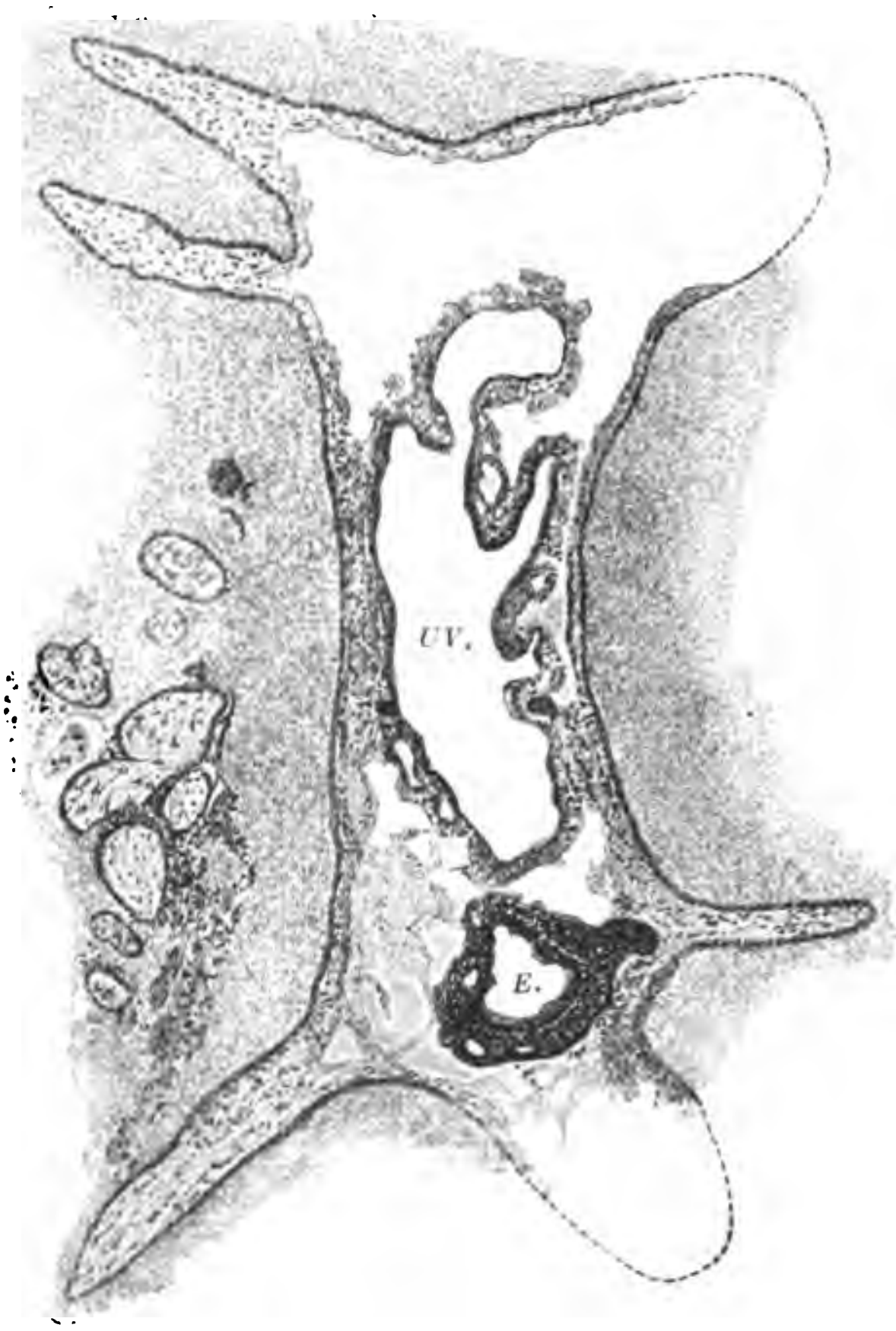

FIG. 170.—Section of an ovum 7 mm. in diameter, from a tubal pregnancy. *E.*, remnant of the embryo; *UV.*, umbilical vesicle, from which blood-vessels have grown directly to the chorion.

Lastly, I give my own classification in the form of a table in which the data are arranged with those of His, giving the number and percentage of specimens under each heading. It is noticed that the percentage is nearly the same in each collection when the figures are arranged in parallel columns. I always considered it remarkable that His never observed an ovum without an embryo, for 28 per cent. of my specimens are of that kind. However, many of them are bloody or fleshy moles, while others are ova which appeared to be perfectly normal until they had been cut into serial sections. I have also compared my vesicular forms with His's nodular forms, for no doubt they are the same in most cases.

Fig. 171.—Section of the chorionic wall of an ovum of 15 × 7 × 6 mm. *D.*, decidua; *S.*, syncytium; *V.*, villus; *Ch.* chorion; *M.*, mucoid substance between the villi rich in leucocytes.

Fig. 172.—Photograph of an embryo 11 mm. long, attached to the chorion.

Classification.	His.		Mall.	
	Number.	Per cent.	Number.	Per cent.
Ova without amnion or embryo	....	....	29	
Ova with amnion but without embryo	....	....	15	
Vesicular (nodular) forms	5	53.4	19	46.6
Embryos 2–2.5 mm. long	9		4	
Embryos 2.5–4.5 mm. long	10		18	
Embryos 5–8 mm. long	11	24.3	21	23.9
Embryos 9–14 mm. long	12	22.3	26*	29.5

*This number includes some of my specimens of the seventh week,—*i.e.*, all embryos less than 15 mm. long.

His did not cut sections of the nodular forms, and had he done so he would probably have found them, as I did, often composed of a single umbilical vesicle without an embryo, which was frequently not attached to the chorion. The large percentage (12) of vesicular forms in my collection is probably due to the refined method I have employed in examining these specimens, most of them having been cut into serial sections.

Fig. 173.—Section of the embryo shown in Fig. 172. Most of the head is destroyed, but the face is adherent to the chest below.

Giacomini notes especially that it is unnecessary to make a group to include the vesicular or cystic forms of pathological ova, for they may be scattered under the various headings of his classification. Under this Group I include those in which the entire embryo has been destroyed, leaving only the umbilical vesicle and sometimes a portion of the amnion. The remnants of the embryos of this group correspond well with Panum's II, 2, in which the embryo is destroyed but the area vasculosa remains and gives rise to blood, just as the vesicle in this form of human monster is composed mainly of an umbilical vesicle with its primary blood-vessels. It may be noted that some of these umbilical vesicles have been confused with the amnion in Giacomini's fantastic group, in which the embryo has wandered out. It is further stated by Giacomini that the openings through which the embryo wandered often healed up, for they could not be found.

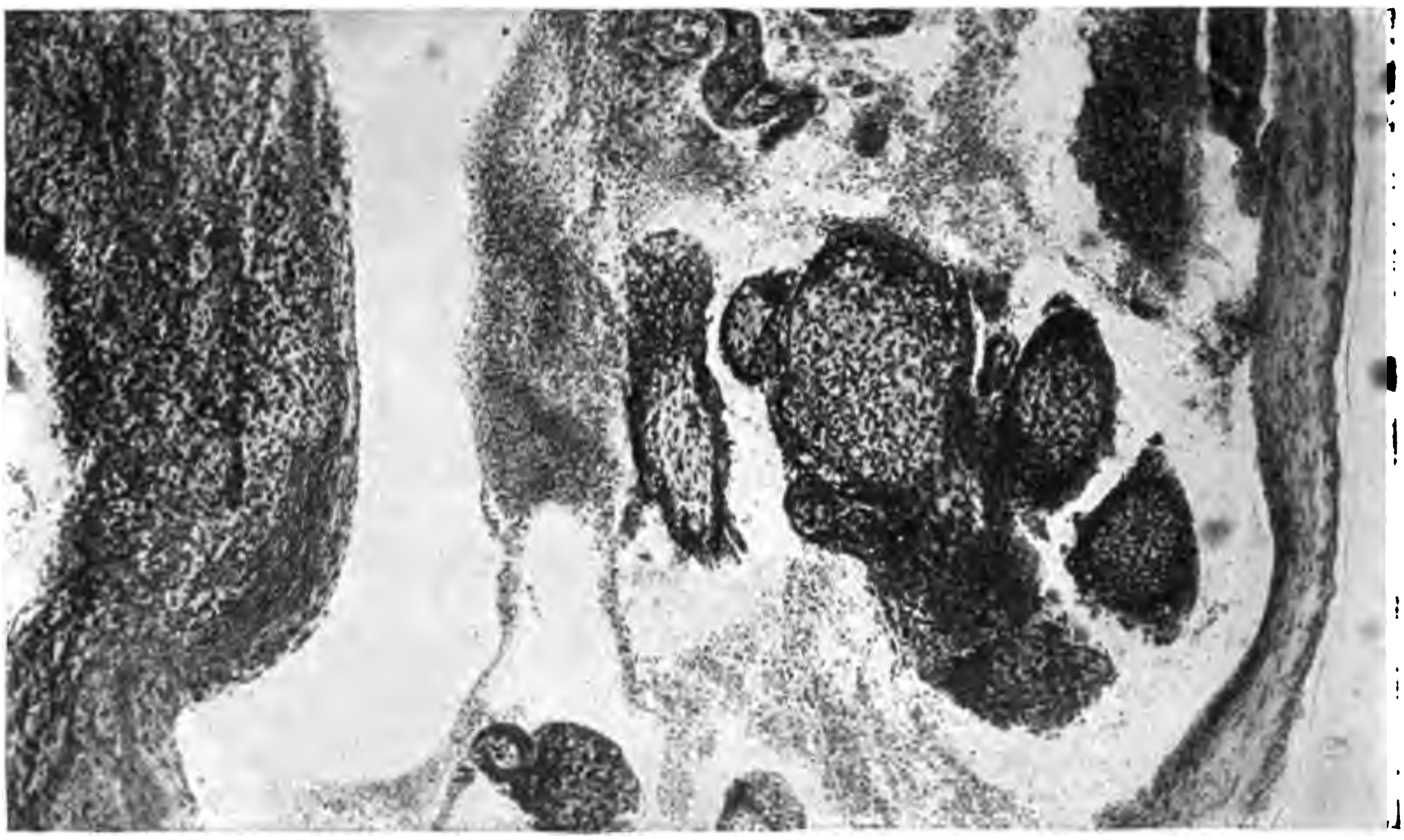

FIG. 174.—Section of the decidua, villi, and chorion of the specimen shown in Fig. 172. There is a mass of mucus between the villi which contains many leucocytes.

In the next table I have arranged nearly all of my pathological ova under various headings, omitting only a few embryos over nine weeks old.

GROUP I.—In the first group are the vesicular forms in which the main remnant of the embryonic mass is composed of the umbilical vesicle (Figs. 176a–178). In some of them the amnion is formed and in others it is destroyed entirely.

GROUP II.—In the second group there is neither amnion, embryo, nor umbilical vesicle; only the chorion remains. This group must have formed from that variety of Group I in which there is no amnion present. Vesicular and solid moles may arise from this group.

Group III.—In this group the embryo was destroyed after the amnion had been formed; usually it lines the chorion. All stages of the complete destruction of the embryo are found in this group, from a necrotic, granular mass to a vesicular ovum lined by the amnion with but a very short stump of the umbilical cord left (Fig. 179).

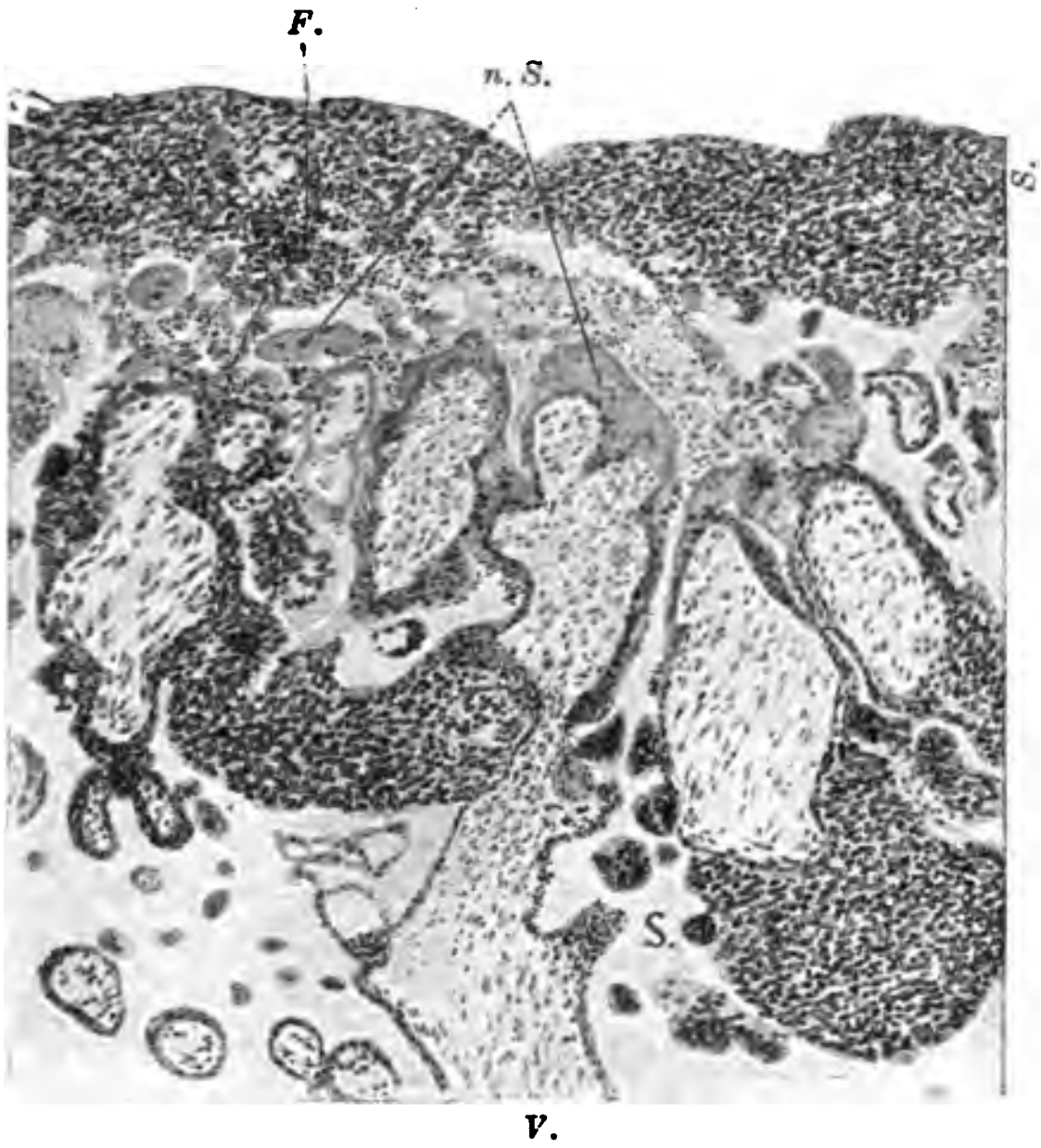

Fig. 175.—Section through the tips of the villi of an ovum 24 mm. in diameter. The embryo within, 2 mm. long, is deformed but nearly normal. *S.*, syncytium; *V.*, villus; *F.*, fragmented nuclei; *n. S.*, necrotic syncytium.

Fig. 176.—Mucoid mass between the villi and the chorion from the same specimen pictured in Fig. 175. *Ch.*, chorion; *V.*, villus; *M.*, mucoid mass rich in leucocytes and containing nests of syncytium.

Distribution of 159 Pathological Ova in a Collection of 434 Specimens, giving also the Condition of the Chorion.

	CR length in mm.	Number.	Per cent.	Condition of the chorion.		
				Normal.	Pathological.	No record.
I. Vesicular forms		19	12	6	11	2
II. Ova with neither amnion nor embryo		29	18	6	22	1
III. Ova with amnion but without embryo		15	10	3	11	1
IV. Embryos of the 4th week	2½	4	3	0	3	1
Embryos of the 5th week	5½	18	11	1	11	6
Embryos of the 5½th week	8	21	13	0	15	6
Embryos of the 6th week	11	13	8	0	10	3
Embryos of the 7th week	17	27	17	1	23	3
Embryos of the 8th week	25	10	6	2	4	4
Embryos of the 9th week	32	2	1.4	0	2	0
Embryos of the 10th week	43	1	.6	0	1	0
Total		159	100.0	19	113	27

Group IV.—The embryo is present in this group and is more or less degenerated. In case it is much degenerated it may produce a nodular embryo of His or an amorphous embryo of Panum. Usually after the fifth week it is quite easy to recognize the stage in which the embryo became pathological. The younger ones correspond with His's abortive, atrophic, or degenerated forms, the older ones often with his cylindrical forms (Figs. 180–183). I have found it more convenient to arrange them in weeks according to the age of the embryo at the time the pathological process began. The embryos of any given week may contain any of His's atrophic forms according to the extent, degree, and duration of the pathological process. It is noteworthy that there are so few path-

Fig. 176a.—Ovum 36 × 33 × 13 mm. without villi. A piece of the chorion is turned over to show a small nodule, the remnant of the embryo.

Fig. 177.—Ovum measuring 12 × 9 × 5 mm. with ragged villi and a large vesicle within.

ological embryos of the fourth week in my collection, while relatively there are four times as many in His's collection. Just the opposite is the case with the vesicular or nodular forms. It may be that I have had a tendency to class with these embryos those that he classes with the nodular form. The vesicular forms are intermediate between ova without embryos and ova with pathological embryos of the fourth and fifth weeks.

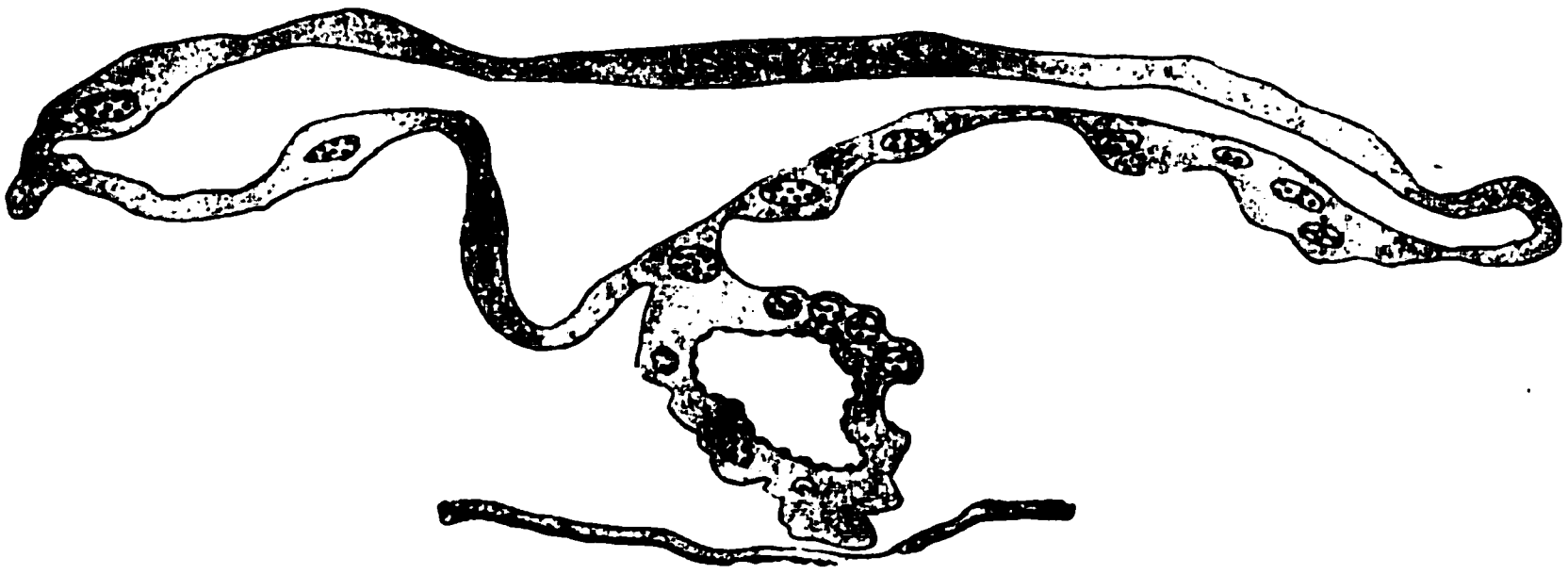

Fig. 178.—Section through the vesicle within the ovum shown in Fig. 177. The double vesicle measures 5.5 × 3.3 mm. The smaller vesicle between the larger one and the chorion may be the amniotic cavity or possibly the dilated allantois, although it is not attached to the chorion.

Fig. 179.—Umbilical cord without an embryo in an ovum of 55 × 40 × 40 mm.

The largest number of pathological embryos are formed during the first seven weeks of pregnancy; their number falls off markedly in the eighth and ninth weeks; and but very few occur

FIG. 180.—Photograph of a pathological embryo 6 mm. long.

FIG. 181.—Section through the embryo shown in Fig. 180.

FIG. 182.—Sagittal section of a much deformed embryo 6 mm. long. The dissociation of the tissues is nearly complete.

FIG. 183.—Sagittal section of a dissociated embryo 9 mm. long.

after the tenth week. Pathological embryos that survive the second month will probably continue through the normal period of pregnancy and give birth to monsters. From statistics given above, this should be the case in every twelfth pathological ovum.

It may also be suggested, with Giacomini, that threatened abortion in early pregnancy should be encouraged, for the cause of it is probably a pathological ovum and the uterus should be relieved of it. Careful investigations should also be made in these cases regarding the cause of the primary trouble. Sterility, or tendency towards sterility of women, especially if it is acquired, should be studied much more carefully than it has been for the sake of scientific teratology and the scientific treatment of abortion.

The study of pathological ova has shown that the embryos within are deformed and that there are structural changes in the chorion which appear to be associated with inflammatory processes in the uterus. The villi are usually fibrous or are otherwise degenerated, the syncytium is atrophic or necrotic, and there is an excess of blood and mucus rich in leucocytes between the villi. These are also often invaded by syncytial cells and leucocytes. The picture indicates that the chorion is affected by an inflamed uterus, which naturally interferes with its nutrition. It is probable, however, that the process is somewhat more complicated, for the trouble often seems to lie within the decidua, especially in tubal pregnancies, which nearly always contain pathologcal ova (Fig. 184). In such cases the inflammatory process around the chorion is not so marked, but the decidua is deficient and there is an excessive amount of blood between the villi (Fig. 170). In both cases the nutrition of the ovum is affected, in the uterus by inflammatory and in the tube by hemorrhagic processes, which interfere with its implantation. As a result of faulty implantation the chorion degenerates or its further growth is retarded and the embryo suffers and becomes atrophic.

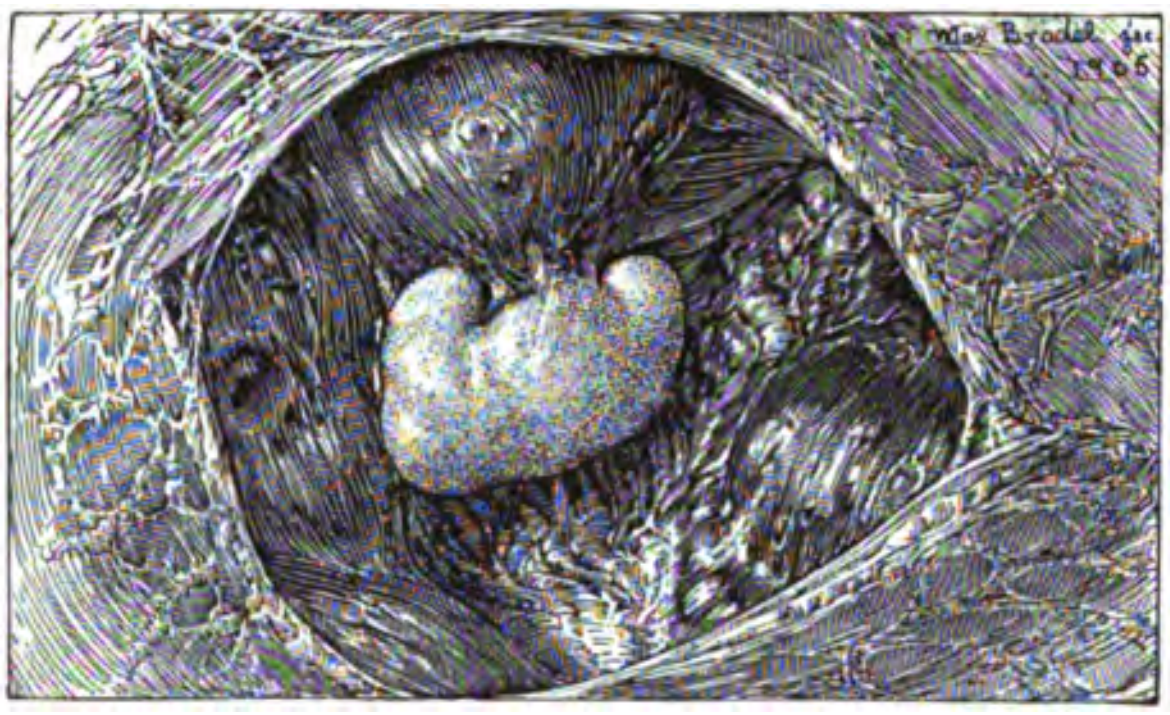

FIG. 184.—Embryo 3⅓ mm. long from a tubal pregnancy.

On the other hand, it is also possible to view the change in the chorion as secondary, as a result of primary changes in the embryo which are germinal in origin. In fact this view of them is entertained by many pathologists, who would consider the ovum as a foreign body after the death of the embryo, and all of the inflammatory changes found within it as of a secondary origin, as would be produced by a sponge if it were put in its place. This second attitude, which considers the changes within the embryo and in the chorion as a coincidence, is, I believe, incorrect. To be sure, it is well known that a woman who aborts a pathological ovum or gives birth to a monster is more likely to do so again, and this is the great argument in favor of the theory that the primary trouble lies in the germ and not in its environment. However, if pathological ova and monsters are due to a diseased condition in the uterus which interferes with the implantation of the ovum, this fact speaks equally as well for the environmental as it does for the germinal theory. The facts bearing upon these two theories I shall give briefly and in the order of their value.

1. It is shown in the table given in the beginning of this chapter that of all pregnancies 7 per cent. end in pathological ova. In case the pathological condition is present in either the germ or sperm that same percentage of pathological ova should be found in ectopic pregnancies. I have taken considerable trouble to investigate the evidence obtained from tubal pregnancies, and in general find stated in the literature that more deformed embryos are found in them than should be; but this statement is rather an opinion than a demonstration based upon actual records. The answer to the question is complicated and rendered difficult by the rupture of the tube, which is of frequent occurrence, through which the embryo is easily lost in case it was present. I have collected all the cases of unruptured tubal pregnancies from Dr. Kelly's gynæcological laboratory and find that there are forty-six in which the tube has been examined by refined modern methods. The enlargement in the tube containing the ovum measured in these specimens from 1 to 6 cm. in diameter, and in thirty-nine of them remnants of the chorion were found with villi ramifying through the blood-clot. Five contained pathological embryos, and but two contained normal embryos which were of the second month. In these two the chorion was well implanted, having a well-formed decidua, as is usually the case in the uterus. In all the rest the villi were of irregular shape, usually atrophic and degenerate, sometimes very long and thin with much blood between them, and the decidua was irregular and scanty. In these the implantation was faulty, and as a result 96 per cent. instead of 7 per cent. became pathological or produced monsters. This is the strongest argument against the germinal theory.

2. Von Winckel has done us a great service in collecting the data regarding the condition of live fetuses which had been removed from ruptured ectopic pregnancies by surgical operations.

They, of course, were derived from the 4 per cent. of normal embryos mentioned above, for the pathological changes in the 96 per cent. were so radical that they could not develop into fetuses of any kind. Von Winckel's specimens are especially valuable, inasmuch as they show the possible fate of the normal embryos I found in tubal pregnancies obtained from Dr. Kelly's clinic. Forty-seven out of eighty-seven fetuses were much deformed and twelve were markedly monstrous; but eight were really normal. Among the monsters there were six specimens of hydrocephalus, one each of hydromeningocele, spina bifida, encephalocele, anencephalus, omphalocele, and hypospadia. In addition, the head was deformed fifty-seven times, legs forty-four, and arms thirty-five, with club-feet in twelve and amniotic bands in four cases. The placenta was usually deformed, sometimes multiple and sometimes broad, thin, or short, and often very hemorrhagic. In general, the poles of the body suffer most, the head being deformed in 75 per cent., legs in 50 per cent., arms in 40 per cent., and the trunk in 4 per cent. of the cases. It is clear that the difficulty is due largely to ordinary mechanical causes which interfere with the growth of the placenta and the poles of the embryo and frequently produce typical monsters. From the data given, it is seen that but very few of the embryos in tubal pregnancies produce normal individuals.

3. Comparative experimental teratology has shown us that all varieties of monsters found in man can be produced in large numbers from normal ova after fertilization as well as from normal embryos. I can only enumerate the results, the literature and general discussion having been given in my larger monograph, as well as in Hertwig's "Handbuch."

a. Polysomatous monsters can be produced by a variety of mechanical methods from normal eggs. Thus Vejdowsky showed in 1892 that the number of monsters produced from *Lumbricus* eggs was greater in the summer months than in cool weather; and somewhat later Driesch succeeded in producing monsters from sea-urchin eggs by separating the cells in the two-cell stage by mechanical means, or by increasing their temperature, which acted upon them in a similar way. Somewhat later Loeb produced double monsters from sea-urchin eggs by changing the chemical composition of their surrounding sea water. In case it is diluted its rapid absorption by the egg causes the cell membrane to rupture, through which some of the protoplasm often escapes; upon returning the egg to normal sea water segmentation begins, nuclei wander out into the extruded protoplasm, and a double monster develops.

These important discoveries were next extended to vertebrates by Wilson, who experimented upon *Amphioxus;* and then by O. Schultze, who experimented upon frog eggs. Both teratologists used mechanical means to produce double monsters. Wilson shook his eggs after segmentation to form hour-glass shaped eggs, and Schultze fixed the eggs between two glass slides and inverted them after segmentation had begun. The partly separated blastomeres gave the anlagen for the bodies of the two embryos, and recently Spemann has produced double monsters in the frog by tying its eggs with a fine thread at the right time. Furthermore, Tornier has produced double legs or even clusters of legs from the single anlage of the leg. These experiments all show that polysomatous monsters are produced from normal eggs.

b. Another variety of monster, not well developed and polysomatous, but atrophic and merosomatous, is found in lithium larvæ. In 1893 Herbst found that there was often an inversion of the blastodermic membranes in case developing sea-urchin eggs were subjected to the action of lithium salts. Morgan extended these experiments to frog eggs and found that the inversion of the layers was due to a failure of the upper protoplasmic contents of the egg to move downward, and he concludes that this arrest is due to the physical and chemical action of the lithium. These monsters are similar in appearance to the irregular nodular forms produced by Panum, Dareste, and Féré, and are interesting inasmuch as they show that the action of lithium upon a normal egg is specific; the lithium produced a definite action upon the egg, interfering with its internal growth and also with its nutrition.

c. It has also been shown by Loeb that the action of calcium salts upon eggs has a specific action upon the growth of the heart and blood-vessels, by preventing the heart beat and retarding the growth of the blood-vessels, as well as of the embryo in general. Although Loeb states expressly that the action of the calcium is specific, as the rest of the embryo remains normal, I am inclined to believe him in error regarding this point, because he did not examine his specimens microscopically and because Knower has recently shown that mechanical enucleation of the heart in young embryos is followed by the gravest consequences. In such embryos the pronephros becomes œdematous and the lymph- and blood-vessels and body cavities become distended. There is a general arrest of development of the embryo; the coils of the intestine are atrophic and there is histolysis of the mesentery and vacuolation of the muscle cells. Teratologists recognized long ago that the heart must be affected more or less in monsters, on account of the frequent occurrence of an œdematous condition of the tissues, as well as of accumulation of fluid in the serous cavities and of the hydramnios and hydrocephalus. Such conditions are often seen in pathological embryos, as well as in the monstrous chicks which were produced experimentally by Panum and Dareste.

d. In 1892 Hertwig published his remarkable essay on spina bifida, which is of far-reaching importance. However, it was Morgan who discovered that spina bifida may be produced experimentally by subjecting frog eggs to the action of common salt. It was found that a 0.6 per cent. solution delays the development of the egg (the chorda, intestine, myotomes, and nervous system developing normally), but gastrulation is postponed for from twelve to twenty-four hours. Posterior spina bifida naturally results. Later in development the exposed cord undergoes cytolysis and histolysis. Subsequently Hertwig extended Morgan's sodium experiment to axolotl. Here the reaction is sharper than in the frog and there is also often anencephaly. It was found that a 0.5 per cent. solution had no effect upon the embryo at all, a 0.6 per cent. solution made half of them monsters, and in a 0.7 per cent. solution all of them developed spina bifida. Schaper has removed the brains of tadpoles mechanically and Harrison has done the same with the spinal cord. In these experiments the embryo grows normally without spinal nerves or cord unless the operation destroys the lymph hearts also; then dropsy follows. In fact this seems to be always the case when the heart is involved by either mechanical or chemical means.

e. The great precision by which spina bifida is produced by the action of sodium salts is equalled in a more striking manner by Stockard's magnesium experiments, in which typical cyclopia is produced in 50 per cent. of the fishes (*Fundulus*) experimented upon. Teratologists have speculated upon the cause and the development of cyclopia for centuries, and now with one stroke all is clear. Ten years ago Born occasionally produced cyclopia by splitting the head of the embryo through its sagittal plane. Later Spemann produced the same by ligature of the head, and Levy by cutting off the front tip of the head. Harrison also often produced a new variety of cyclopia by removing the brain of the embryo; the eyes then wandered to the back of the head in the region of the pineal eye and appeared to unite. By a very different method Lewis succeeded in producing cyclopia in a large percentage of the specimens experimented upon. He pricked the extreme end of the embryonic shield of *Fundulus* and from such eggs embryos with all degrees of typical cyclopia developed. Of course, the striking experiment is Stockard's, and recently he has given an account of the anatomy of his embryos. At any rate, all these experiments show that all kinds of monsters, including spina bifida and cyclopia, are produced from normal embryos due to external influences.

4. The consensus of opinion of gynæcologists is that pathological ova are due to a diseased uterus, but they are not inclined to associate pathological embryos with monsters. Neither do they

speak of curing the uterus of women who have given birth to monsters in order to prevent them from doing so again. However, the evidence I have given above proves that monsters are produced from normal eggs by conditions which either interfere with their nutrition or poison them, and that in tubal pregnancies there is a great excess of pathological ova and monsters. How is it with pathological ova which come from the uterus? Is the uterus usually normal, or pathological? The chorion in nearly all pathological ova examined shows signs of inflammation, often severe, which is, of course, uterine in origin. Taking all of the pathological ova in my collection, thirty-three altogether, in which any data regarding the women from whom they were obtained are given, it is found that they are easily arranged in three groups. (1) In the first group of eleven cases the main trouble preceding the abortion was a severe hemorrhage extending over a number of days. (2) The second group of twelve specimens were abortions from first pregnancies in newly married women or relatively sterile women who had been married for some time and were anxious to have children. (3) The third group of ten specimens were from women who had given birth to a number of healthy children and then began to abort, often a second or a third time. The first group throws no light upon the question we are discussing, but the second is of value because it comes from sterile women. The third group is more easily explained. The women, perfectly healthy at first, gave birth to one or more children and then conceived and aborted quite regularly. In these cases the uterus was normal at first, but later, due to a variety of infections, became inflamed, and thereafter the fertilized ovum could not implant itself, became pathological, and was aborted. My records also state that seven of the women are healthy and twelve have uterine disease. In general, those with uterine disease belong to the second and third classes mentioned above. It may be noted that all the pathological conditions of the ova of the third group could not be due to germinal causes, for all these women had given birth to healthy children and the probabilities for any class are but 1 to 14. The data only confirm those obtained from tubal pregnancy, as well as those from experimental teratology, that is, the primary cause is in the environment.

5. Especially interesting are those cases in which two pathological embryos are obtained from the same woman. Five such sets are in my collection, and in four of them the changes in those of a set are alike. Two sets are duplicate twins and one is composed of two twin ova from a woman who had aborted before. The fourth set are about a year apart from a woman who had had nine children, after which her health failed (ten years ago); since then she has conceived regularly and aborted every time. The

chorions of these two specimens are well infiltrated with leucocytes, the villi are largely destroyed, and the changes in the two embryos are severe and much alike. The fifth specimens are from a young woman, mother of two children, and the first of these appeared normal with the exception of an excessive amount of granular magma in the amnion, with leucocytic infiltration of the placenta. Nine months later a second typical pathological embryo was obtained from the same woman. Disease of the uterus began with the birth of the second child. Later she aborted again. Although these cases do not prove the point made they at least indicate that the same environment affected the ova of either successive or twin pregnancies in the same way.

The theory that merosomatous monsters are produced by mechanical influences was established by Lemery, defended by the Saint-Hilaires, but was antagonized to the utmost by Meckel, Bischoff, and others. In case they are produced from normal embryos by means of external influences it follows that the embryo must become wholly or in part diseased or pathological, a view entertained by Morgagni. Frequently the pathological changes in the fetus were compared with those in the adult and it was believed that they were also due to a variety of diseases, such as syphilis, tuberculosis, rickets, or to inflammation. However, it was impossible to show that the destruction of tissue necessary to produce a monster was associated with pathological changes peculiar to these diseases, but instead they nearly always appeared to be normal in character. Panum defended the nosological theory and asserted, with good reason, that only the fundamental characters of the changes within the embryo in a given disease should be like those in the adult. In fact he asserted that the nomenclature for the pathological changes in the embryo cannot be the same as that for the adult, and this opinion is borne out by the numerous investigations during the last fifty years. At best, Panum states, the etiological factors are the same for diseases of the embryo and of the adult. He had found in experimental chick monsters due to malnutrition that there are constant tissue changes, such as will produce exudates, bring about adhesions, and cause atrophy with scar formation. And since these changes are found constantly it indicates that they are due to a common pathological cause. Local softening and necrosis, which often accompany the above-mentioned processes, are of sufficient importance to account for the changes in development, which is otherwise normal, to produce spina bifida and the like. These changes, which often take place in the embryo before the blood-vessels are formed, may be likened to those accompanying inflammation in the adult. However, there is a multiplication of cells as well as a cell necrosis, and Panum thinks himself justified in calling the process parenchymatous inflammation of the embryo.

The tissue changes found by Panum in experimental chick monsters were subsequently seen and recognized by Giacomini, His, and myself in the human embryo, and are well described by Giacomini in his general article. By means of serial sections of pathological embryos it is easily seen that the sharp normal lines of demarcation of the structures are largely lost in young embryos; and in older embryos the elements of different organs become more or less mixed, which often gives them the appearance of lymph-glands. However, certain tissues like the ectodermal are more resistant than others. The changes in older embryos were described with great accuracy by His. He stated that the blood-vessels of pathological embryos enlarge and become gorged with blood, and that many of the cells wander into the surrounding tissues, thus converting the whole embryo into an even structure, as described by Giacomini.

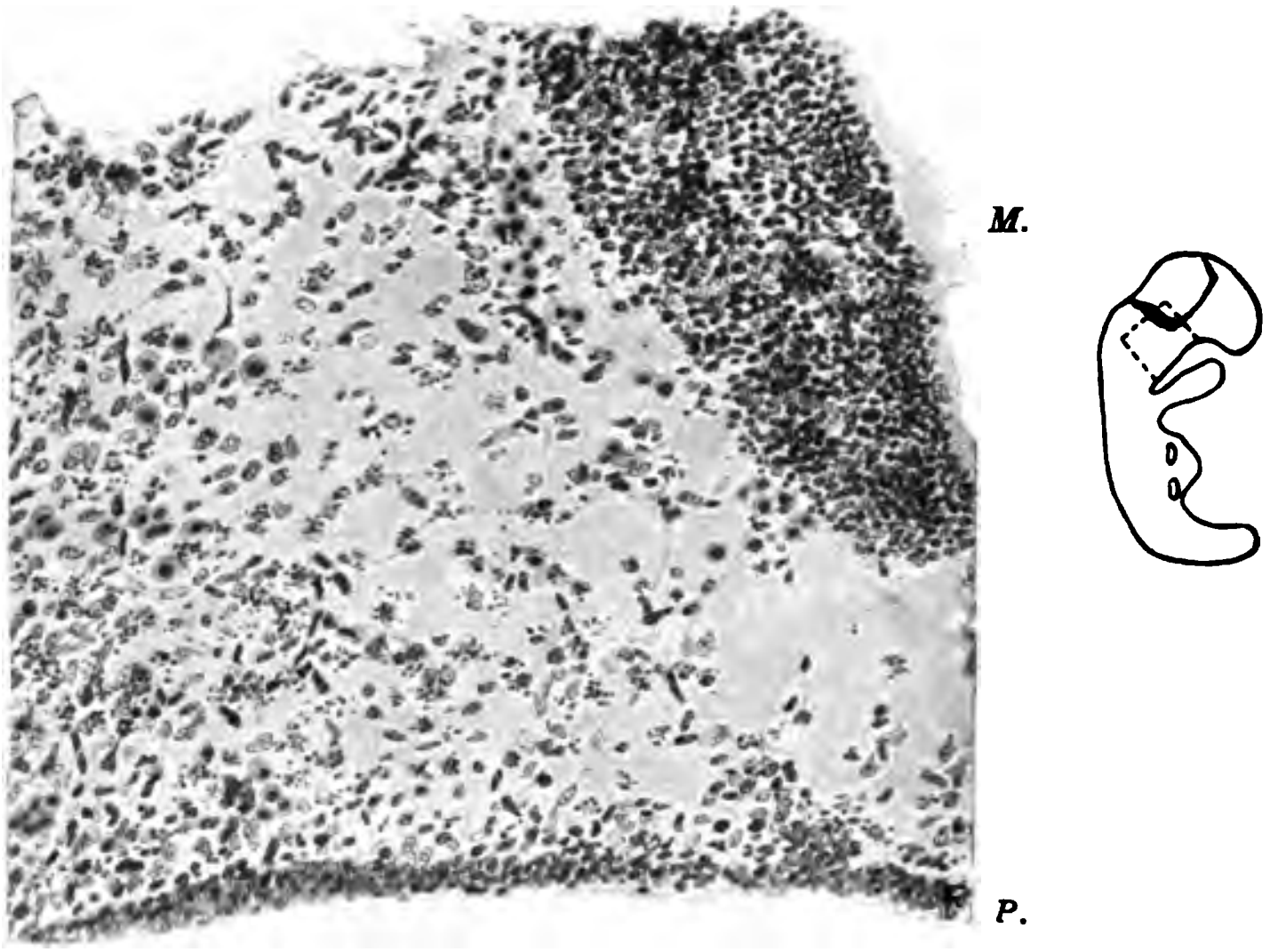

Fig. 185.—Section through the head, marked in the adjoining diagram, showing cytolysis and dissociation of the tissues in an embryo 2 mm. long. *M.*, hind-brain; *P.*, epithelial lining of the pharynx.

It seems to me, in view of what has been said above, as well as by the results of Born upon grafted embryos, and of Hertwig, Morgan, and others upon numerous experimental monsters, that we are dealing with a condition in which there is more or less correlation of growth, which may represent a fundamental type of inflammation. When, however, the embryonic tissues become mixed, which is generally due to malnutrition followed by some cytolysis, we have a new condition quite unlike any pathological change found in the adult. The repair of a simple wound in the embryo is always associated with further development of the surrounding parts, and in case the process ends in a perfect result normal development still remains, with or without regeneration;

but if there is a lack of correlation, pathological conditions arise, already recognized by Morgagni, and well described by Panum, Giacomini, and His. This pathological condition I shall term dissociation. The growth of dissociated tissues may be checked by excesssive cytolysis or they may be destroyed entirely by histolysis.

There are several young embryos in my collection in which dissociation is just beginning. One of them, 2 mm. long, which is practically normal in form, is from an ovum which was curetted from the uterus and included part of the decidua (Fig. 185). The decidua is infiltrated with leucocytes and the cœlom has in it an excess of magma réticulé; otherwise the chorion appears normal. The front end of the amnion is torn and well packed in with magma, showing that it too is not of mechanical origin. In general, this specimen shows that in young pathological ova the embryo is extremely susceptible and about the first to suffer. In this specimen the mesodermal tissue of the embryo and the ventricles of the fore-brain are filled with round cells containing fragmented nuclei. Most of the blood-corpuscles are still within the blood-vessels, and those that are free in the tissues are well defined and perfectly normal in appearance. However, it may be noted that the cells of the mesenchyme diminish as the free round cells increase, showing that they are dissociating, as are also those of the brain tube. Another specimen, somewhat more advanced in development, has an atrophic head and a wide open spinal cord below, anencephaly and spina bifida (Fig. 186). In this there are slight signs of its pathological nature in the chorion, and there is an excessive amount of magma in the cœlom. So far there is no dissociation of the tissues of the embryo; there is only an arrest of development of the central nervous system. As the pathological process continues in later

FIG. 186.—Embryo 2 mm. long, with an atrophic head, large neuropore, and spina bifida.

FIG. 187.—Embryo 35 mm. long, with deformed hands and feet. The largest diameter of the ovum is 90 mm. The abortion took place 18 weeks after the last menstrual period.

embryos of the fourth week, the amnion is often destroyed and the embryo rapidly degenerates, usually leaving the umbilical vesicle, which is quite resistant. Subsequently this is also destroyed, leaving only the chorion, without amnion or embryo, which may continue to grow into an irregular mole.

The embryo gradually becomes more and more resistant during the fifth week, the brain and heart showing somewhat greater resistance than the other organs. Between the fifth and sixth weeks, when the peripheral nervous system appears, the delineation of the organs becomes sharper. Here we also often find dissociation of one or more of the tissues or organs, a gorged vascular system, and frequent hydrocephalus, all probably due to an arrest of the heart action. Such embryos rapidly undergo secondary changes and within a month most of them abort, or if the chorion remains it may form the nucleus of a mole.

FIG. 188.—Embryo 19 mm. long, with dropsical back.

During the sixth week, owing, no doubt, to the unequal differentiation of the tissues, some of them become more resistant than others. The more central tissues stand the action better and the more peripheral tissues are more susceptible. Thus the spinal cord and medulla do not dissociate and atrophy so easily as do the head, face, brain, and extremities. The vascular system also suffers very much, probably on account of the effect of the impaired nutrition of the chorion upon the heart. As a result of the weakened heart the cavities of the brain and body become dropsical, and the tissues of the extreme ends of the embryo dissociate and develop poorly. The precartilages and cartilages suffer least of all.

In the beginning of the seventh week the cartilages of the extremities are outlined, and at the end of this week ossification centres make their appearance. Coincidently the peripheral nerves ramify through the body and the muscle anlagen appear. On account of the high degree of differentiation of the structures of the embryo, impairment of its nutrition produces very unequal effects upon its organs and tissues. In the earliest stages the umbilical vesicle is the most resistant, then the nervous system, and now it is the skeletal tissues. Before the development of the heart, the blood-vessels were very resistant; now that they are dependent upon the heart they are least resistant, and structures which are dependent upon the circulation for their nutrition suffer in a secondary way. The changes in embryos of the seventh week can be followed easier than those in earlier embryos, for they are less rapid and the differentiation of the structures aids the observer very much. Now the extreme ends of the embryo are profoundly changed (Fig. 187), due probably to affections of the heart of the embryo; there is much cytolysis and dissociation of the nervous system; and the face, head, and extremities are often atrophic. Towards the eighth week there is a great diminution of the number of pathological ova in my collection, as was also the case in that of His. It follows that most

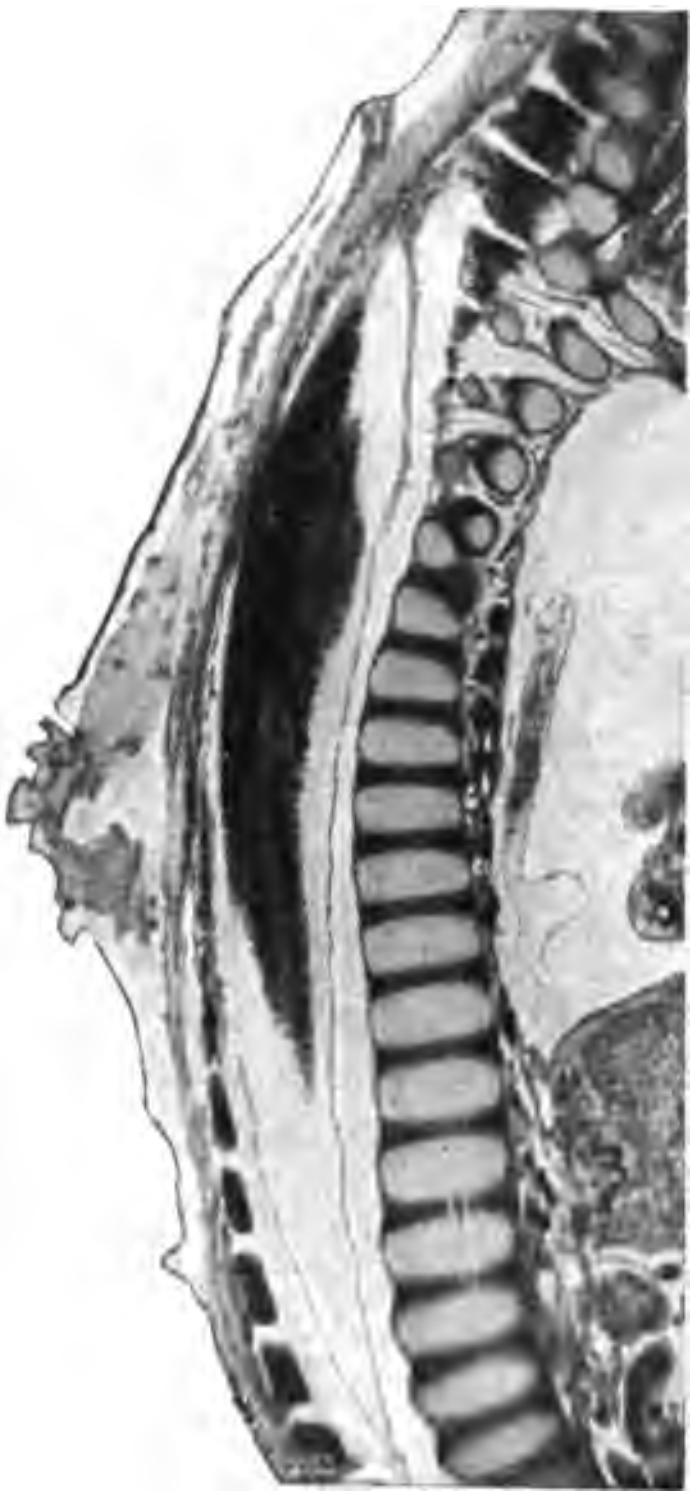

Fig. 189.—Sagittal section through the swelling in the back of the embryo pictured in Fig. 188, showing the blister of the epidermis.

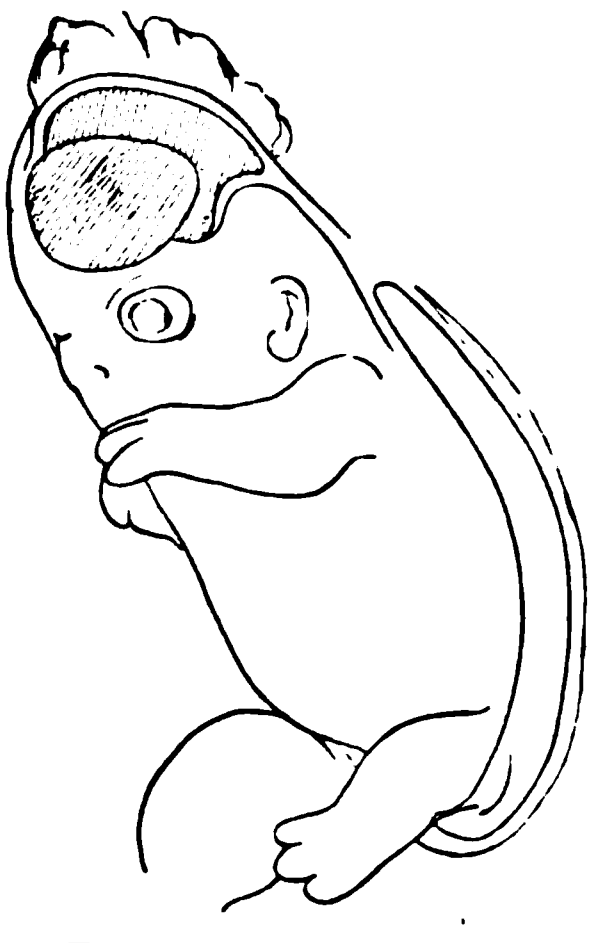

Fig. 190.—Reconstruction of the central nervous system in an embryo 24 mm. long, showing spina bifida, destruction of the medulla, and atrophy of the brain.

monsters are formed before the eighth week; those with radical changes in them are aborted, while those that are slightly affected continue to develop until the end of pregnancy. However, many of those that are aborted show considerable growth of a variety of structures, such as the epidermis, which proves conclusively that we are not dealing with post-mortem changes in the embryo. The longer such a specimen remains in the uterus the more radical are the secondary changes in the embryo and the more pronounced are the primary changes in the chorion. In order that a monster shall continue throughout pregnancy the changes in the embryo must not be extreme enough to eliminate the heart, and the chorion must be normal enough to permit the formation of a healthy placenta, which begins to differentiate at the time (end of the second month) monsters cease to form.

In the following table I have arranged the data regarding the percentage of the varieties of monsters found in pathological ova, and at birth. In general they agree very well. However, the percentage of spina bifida is greater in the embryo than at birth, indicating that the mortality is greatest in this variety of monster. If the larger number of cases of dropsy of the head were reduced or omitted, the proportion of monsters in pathological ova and those at birth would agree very well. No doubt water on the brain is an affection primarily of later fetal life, but this question remains to be investigated.

Percentage of Monsters in Pathological Ova and at Birth.

(Panum).			(Von Winckel).			(Mall).		
Varieties of monsters.	Number.	Per cent.	75 monsters in 12,378 births.	Number.	Per cent.	79 monsters in 163 pathological ova from 434 specimens collected.	Number.	Per cent.
Anencephalus	119	48						
Hydrocephalus	26		Head	23	31	Atrophic head	24	31
Hydrocephalocele	93							
Harelip	77	21						
Cyclopia	16		Face	12	21	Malf'd face & neck	17	25
Eyes missing	9		Neck	4		Displaced eyes	3	
Def'd upper jaw	3							
Def'd extremities	115	23	Upper extremity	9	35	Def'd extremities	18	23
			Lower extremity	17				
Spina bifida	38	8	Back	3	4	Spina bifida	12	15
			Abdomen	7	9	Exomphalos	5	6
Total	496	100		75	100		79	100

The specific action of salt solution upon amphibian eggs, producing a large percentage of spina bifida monsters, has been mentioned above. The work of Torneau and Martin, and more recently that of Fischel, has shown that spina bifida in man is not only to be viewed as an arrest of development of the medullary

Fig. 191.—Embryo 16 mm. long, showing harelip, displaced ears, exomphaly, and spina bifida.

Fig. 192.—Sagittal section of the embryo shown in Fig. 191. The central nervous system consists largely of a mass of vascular tissue.

Fig. 193.—Section of the chorionic villi of the specimen shown in Fig. 191. There is an extensive mucoid reticulum between the villi, which contains many leucocytes and syncytial cells.

plate, leaving the neural tube open, but that there is also a secondary destruction of the membrana reuniens behind, at least in all cases of spina bifida occulta (Figs. 188–190). Deformities of the head, such as anencephaly (Figs. 191–193) and, what may often follow it, cyclopia (Figs. 194 and 195), are now easily understood, since we have the splendid experiments of Stockard and of Lewis upon this question in *Fundulus*. That the great varieties of dropsy, as pictured by Kollmann and as are frequently seen in embryos and fetuses, are due to an impairment of the action of the heart is now definitely proved by the enucleation experiments of Knower. It is no longer necessary for us to seek for mechanical obstructions which may compress the umbilical cord, such as amniotic bands, for it is now clear that the impairment of nutrition which naturally follows faulty implantation, or the various poisons which may be in a diseased uterus, can do the whole mischief. That monsters group themselves, both in nature and when made experimentally, rather shows that certain tissues are influenced at crucial periods in their development, and not that given substances have specific influences upon the embryo as a whole.

FIG. 194.—Cyclopian embryo, 20 mm. long, with anencephaly. The ovum measured 80 × 60 × 50 mm.

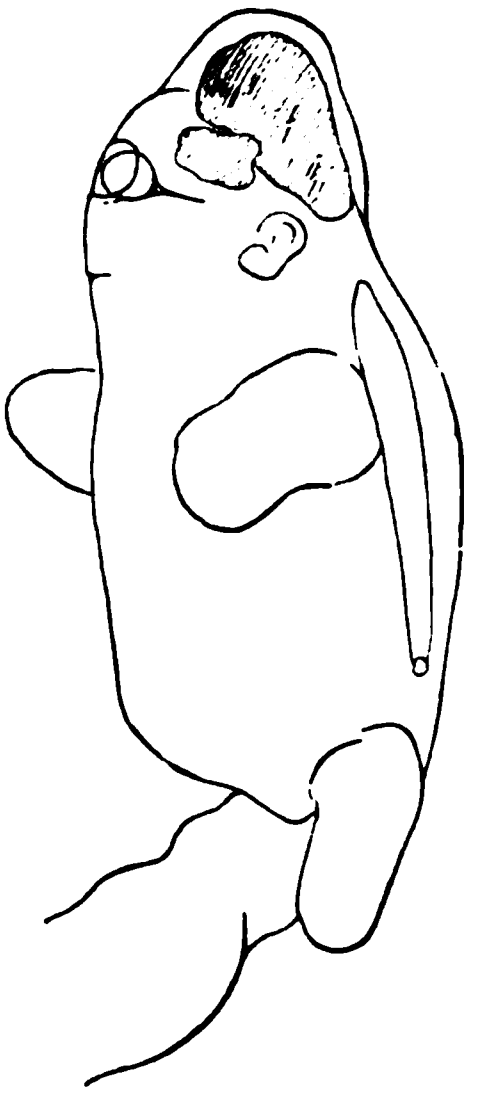

FIG. 195.—Diagrammatic reconstruction of the cyclops of Fig. 194, showing the extent of the central nervous system.

BIBLIOGRAPHY.

Ahlfeld: Geburtshilfe, 1903.
Die Missbildungen des Menschen, Leipzig, 1880–1882.
Bardeen: Jour. of Experimental Zoöl., 1907.
Ballantyne: Antenatal Pathology, 2 volumes, Edinburgh, 1904.
Bischoff: Wagner's Handwörterbuch, 1842.
Born: Roux's Archiv, vol. iv, 1897.
Dareste: Recherches sur la production de monstruosités, Paris, 1891.
Driesch: Zeit. f. wiss. Zoöl., vol. lv, 1892.
Eycleshymer: Amer. Jour. Anat., vol. vii, 1907.
Fischel: Ziegler's Beiträge, vol. xli, 1907.
Förster: Die Missbildungen des Menschen, Jena, 1865.
Giacomini, **Merkel**, and **Bonnet**, Ergebnisse, vol. iv, 1894.
Gerlach: Doppelmissbildungen, 1882.
Granville: Graphic Illustrations of Abortion, London, 1834.
Harrison: Amer. Jour. Anat., vol. iii, 1904.
Hertwig, O.: Arch. f. mik. Anat., vol. xxxix, 1892; vol. xliv, 1895.
Gegenbaur Festschrift, vol. ii, 1896.
Handbuch d. Vergl. u. Experiment. Entwicklg. d. Wirbeltiere, vol. i.
Hegar: Monatsch. für Geburtskunde, vol. lxi, 1863.
Hirst and **Piersol**: Human Monsters, Philadelphia.
His: Anatomie menschl. Embryonen, vol. ii, 1882.
Virchow Festschrift, vol. i, 1899.
Kelly: Operative Gynæcology, vol. ii, Philadelphia.
Knower: Anatomical Record, vol. i, 1907.
Koch: Beiträge zur Lehre von spina bifida, Kassel, 1881.
Kollmann: Archiv für Anat. u. Entwicklgesch., Supplement-Band, 1899.
Leopold: Arbeiten aus der dresdener Frauenklinik, vol. iv.
Leuckart: De Monstris, Göttingem, 1845.
Levy: Roux's Archiv, vol. xx, 1906.
Lewis: The Experimental Production of Cyclopia in the Fish Embryo, Anatom. Record, vol. iii, 1908.
Loeb: Biological Lectures at Woods Holl, 1893; Pflüger's Archiv, vol. liv, 1893; ibid., vol. lv, 1894; Roux's Archiv, vol. i, 1895; and Studies in General Physiology, Chapter X, Chicago, 1905.
Mall: Welch Festschrift, Johns Hopkins Hospital Reports, vol. ix, 1900.
Vaughan Festschrift, Contributions to Medical Research, Ann Arbor, 1903.
Johns Hopkins Hospital Bulletin, 1903.
Anatomical Record, January 1, 1907.
A Study of the Causes Underlying the Origin of Human Monsters, Jour. Morph., vol. xix, 1908 (contains a full description of all the specimens used in this chapter).
Marchand: Missbildungen, Eulenburg's Real-Encyclopædia, third edition, 1897, vol. xv.
Meckel, J. F.: Handbuch d. pathol. Anatomie, Leipzig, 1812.
Morgan: Ten Studies in Roux's Archiv, vols. xv–xix, 1902–1905.
Morgan and **Tsuda**: Quart. Journ. Micr. Sci., N. S., vol. xxxv, 1894.
Müller: Meckel's Archiv, 1828.
Panum: Entstehung der Missbildungen, 1860.
Piersol: Teratology, Ref. Hndbk. Med. Sci., new edition, vol. vii.
Von Recklinghausen: Virch. Arch., vol. cv, 1886.
Richter: Anat. Anz., vol. iii, 1888.
Schaper: Jour. Bost. Soc. Med. Sci., 1898; and Roux's Archiv, vol. vi.
Schultze, O.: Verhandl. d. anat. Gesellsch., 1894; and Roux's Archiv, vol. i, 1895.

SCHWALBE, E.: Die Morphologie d. Missbildungen des Menschen und der Thiere, Jena, part i, 1906, part ii, 1907.
SPEMANN: Stizungsber. d. phys.-med. Gesellsch., Wurzburg, 1900.
Roux's Archiv, vol. xv, 1903; and Zoöl. Jahrbücher, vol. vii, Supplement, 1904.
STOCKARD: Roux's Archiv, vol. xxiii, 1907; also Jour. Ex. Zoöl., vol. vi, 1909.
TARUFFI: Storia delli Teratologia, 8 volumes, Bologna, 1881–1895.
TORNEAU and MARTIN: Journal d'Anat. et Physiol., vol. xvii, 1881.
TORNIER: Roux's Archiv, vol. xx, 1905.
VALENTIN: Handwörterbuch d. Physiologie, vol. i, 1842.
VEJDOVSKY: Entwicklsg. Untersuchungen, Prag, 1890.
VOIGT: Anatom. Hefte, vol. xxx, 1906.
WETZEL: Arch. f. mik. Anat., vol. xlvi, 1895.
WILLIAMS: Obstetrics, New York, 1903.
WILSON: Jour. of Morph., 1893.
VON WINCKEL: Ueber die Missbildung von ektopisch. entwichten Fruchten, Wiesbaden, 1902.
Ueber die menschl. Missbildungen, Samml. klin. Vorträge, Leipzig, 1904.

X.

THE DEVELOPMENT OF THE INTEGUMENT.

BY FELIX PINKUS OF BERLIN.

A. THE EPIDERMIS.

FROM the beginning of development the epidermis forms the outermost investment of the body. It consists of a uniform two-layered sheet, the upper layer forming a sort of hard covering-layer while the lower one remains soft and gives rise to new cells and to all the epidermal appendages of the integument. This two-layered stage persists over most portions of the body until into the fourth month, but even at the end of the second month it is not altogether unmodified.

The regions which show the first signs of further development are all upon the ventral surface of the body, the skull and back remaining covered by an unaltered, two-layered, indifferent epidermis. In an embryo of 15 mm. Kallius found the first indications of the milk ridge, and Tandler observed it later in one of the 9.75 mm. But the modifications of the epidermis are not confined to the regions of the milk ridges at the sides of the body; also on the ventral surface, anteriorly over the branchial arches and posteriorly as far as the tail, changes occur which indicate a strong formative tendency. In somewhat older stages (32 mm., 40 mm.) an increased tendency towards development shows itself, especially over the facial region, on the anterior surface of the face and neck by the height and regularity of the basal columnar cells, and in the region of the eyebrows, the upper lip, and chin by the distinct commencement of hair formation.

a. EARLY STAGES.

Where its formation is most simple the epidermis consists of:

1. A superficial layer of flat cells, the *epitrichium,* or, better, the *periderm* (W. Krause, 1902).

2. A layer of cells greater both in height and breadth, the *stratum germinativum* (see Fig. 196).

Beneath the latter and sharply marked off from it is the fibrous and very cellular connective tissue.

1. The *periderm* is the outermost layer of the epidermis. It consists, for the most part, of flat cells, which in transverse sec-

tions of the integument appear to be spindle-shaped with deeply staining, thin nuclei, while from above they appear as a layer of large polygonal cells with large roundish nuclei. Even in very early stages the peripheral portions of the cells flatten out, so that only the central portions containing the nuclei remain thick (Fig. 199). Gradually they become quite flat and unusually large (Minot, 1894). Frequently one finds some of these cells separated from the rest, so that they are seen from the surface in transverse sections, in which cases they appear as slightly irregular roundish disks with centrally placed nuclei, which are either still round or have become irregular. Around the nuclei there are frequently a large number of roundish cavities, which give to the central portions of the cell the appearance of a coarse network. These are the cells which Rosenstadt (1897) found in the beak of an embryo chick, where they were full of large keratohyalin granules by whose solution the cavities are formed. Zander (1886) described them in the skin of all fingers and toes, where they were also observed by Kölliker (vesicular cells) and by Okamura (1900). As the outermost layer of the epidermis the periderm cells have the function of the later-formed corneous layer, and they actually form an investment of a horny character (as shown by their reactions: indigestibility, Unna, 1889; yellow staining with picric acid, Cedercreutz, 1907). In the more developed portions of the epidermis (as on the forehead) these cells become heaped up in two or several layers, and may even form distinct elevations, as at the nostril and mouth openings, in which cases the cells are especially large (Fig. 198).

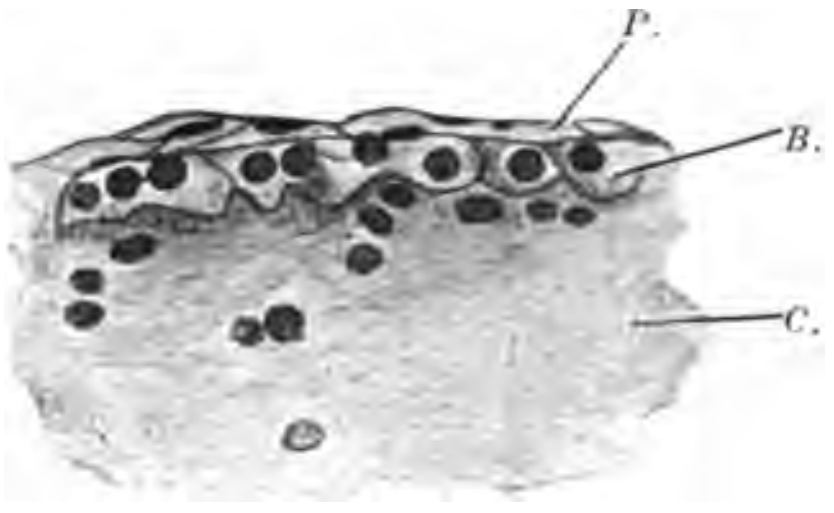

FIG. 196. — Human fetus, 5 cm. in greatest length, female. (Collection of Prof. Robert Meyer, No. 249.) Integument of abdomen, right side; epidermis two-layered. *P.*, periderm; *B.*, layer of basal cells; *C.*, corium with few cells. × 200.[1]

In man the periderm is not a layer which requires to be especially distinguished as the oldest or specifically embryonic investing layer. It is only the outer layer of epidermis, whose cells are no longer turgid and have become firmer and incapable of reproduction. It merely occupies the place of the later horny layer and receives additions from the subjacent germinative layer, just as throughout life all the more superficial layers are recruited from the deepest layer, the stratum cylindricum.

That the periderm is added to is shown

1. By the desquamation of its cells.

---

[1] Figs. 196–198 were drawn without use of a camera and consequently the enlargements cannot be given with certainty. The remaining figures were drawn with a Zeiss-Abbé camera.

2. By the arrangement of its cells in a regular layer, notwithstanding the increased growth of the skin surface.
3. By the local heaping up of layers of completely and similarly formed periderm cells in the course of development.

Each of these three phenomena indicates an increase in the number of periderm cells.

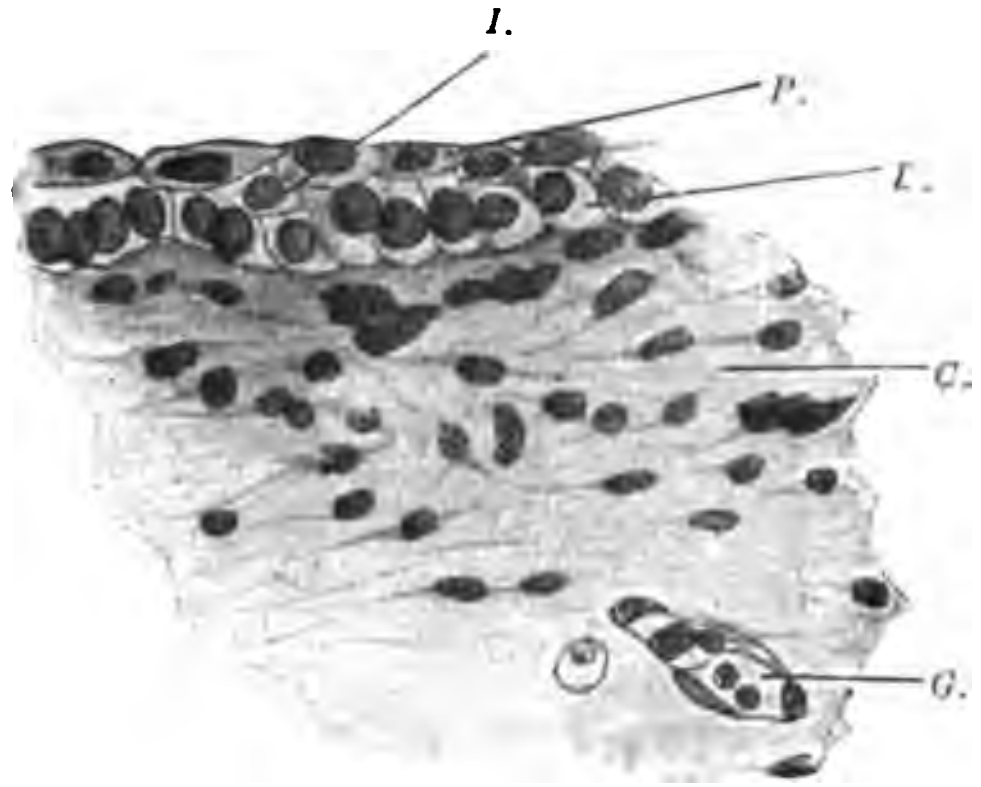

Fig. 197.—Human fetus, 32 mm. in greatest length. (Collection of Prof. Robert Meyer, No. 307.) Integument from the right side of the body; the epidermis is beginning to become three-layered. *P.*, periderm; *I.*, stratum intermedium; *B.*, stratum germinativum; *C.*, corium, rich in cells; *G.*, vessel. × 400.

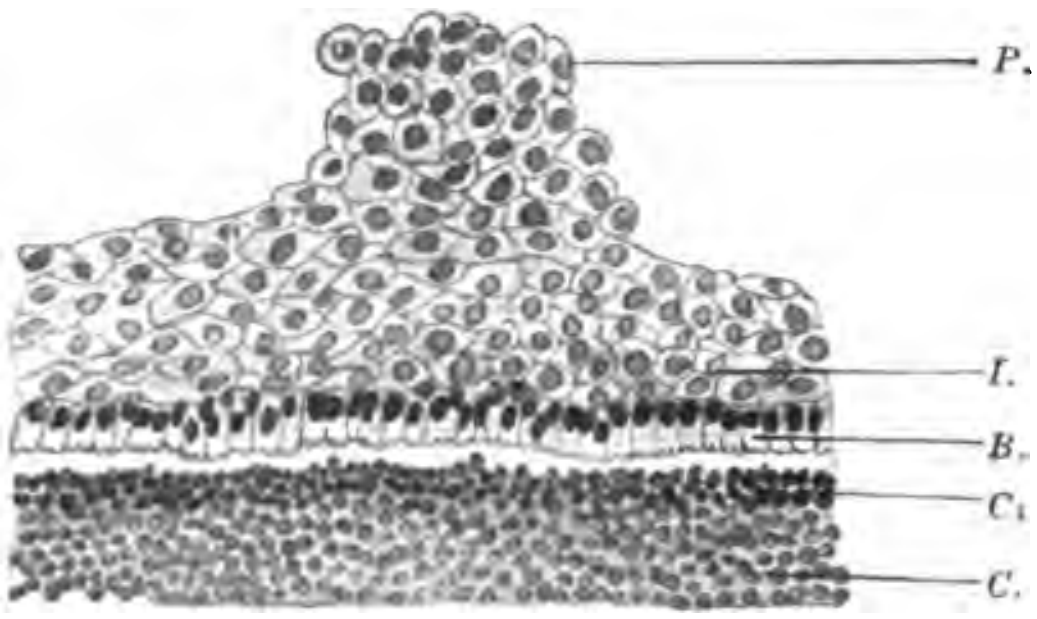

Fig. 198.—The same fetus as Fig. 197 (32 mm.); periderm elevation of the right upper lip. *P.*, periderm, consisting of large vesicular cells, probably cut somewhat obliquely; *I.*, stratum intermedium, with cells somewhat smaller, flattened; *B.*, stratum germinativum, of high columnar cells with high, smaller, dark nuclei; *C.*, corium separated from the epithelium, very cellular; C_1, the uppermost layer of the corium, especially rich in nuclei. × 100.

2. The deeper layer, the *stratum germinativum,* is the reproducing layer of the epidermis. Its cells are at first low, the breadth being equal to or even greater than the height; their nuclei are round or slightly oval, stain beautifully with a distinct chromatin network, and are very large in proportion to the entire volume of the cells. The basal surfaces of the cells, turned towards the connective tissue, are flat or slightly concave, and at first are but slightly connected with the corium, so that they readily separate in spots after the death of the fetus (maceration) or as the result of preparation. The lateral walls are variously curved, but in general but slightly, in correspondence with the pavement-like apposition of the essentially cubical cells. The outer surfaces are for the most part more or less convex. No special contents can be distinguished in their protoplasm by ordinary methods of preparation.

In those regions which already, in these early stages, show an advance in development, the cells of the deep layer become higher, and finally columnar; the nuclei are closer together and form a quite regular layer, parallel with the lower surfaces of the cells, as may be recognized by weak magnification of not too thin (15 μ) sections. They stain distinctly darker and are round or oval, the long axis being perpendicular to the surface. The cells are arranged palisade-like, close together, with perpendicular side walls; and their upper surfaces are rather straight, forming a slightly wavy line beneath the stratum intermedium. Their lower surfaces are no longer smooth as in the first stage, but are drawn out into small projecting feet. The cell bodies are much clearer than those of the superposed layers; they are homogeneous, without any granular contents. Since the nuclei all lie in the outer portions of the cells, the lower portions appear as a clear band between the row of dark nuclei and the dense mass of nuclei which occupies the most superficial portions of the corium.

b. FURTHER DEVELOPMENT.

Very early there appears between the periderm and the stratum germinativum a middle layer of cells, the *stratum intermedium.* Previous to its appearance the cells of the stratum germinativum become higher and more closely approximated, and their nuclei become round and large. First individual cells appear between the two primary layers (Fig. 197), and then a complete row of them (Fig. 199), their nuclei being small and transversely oval and the cell bodies smaller than those of the basal cells, and they take the nuclear stain (carmine) somewhat.

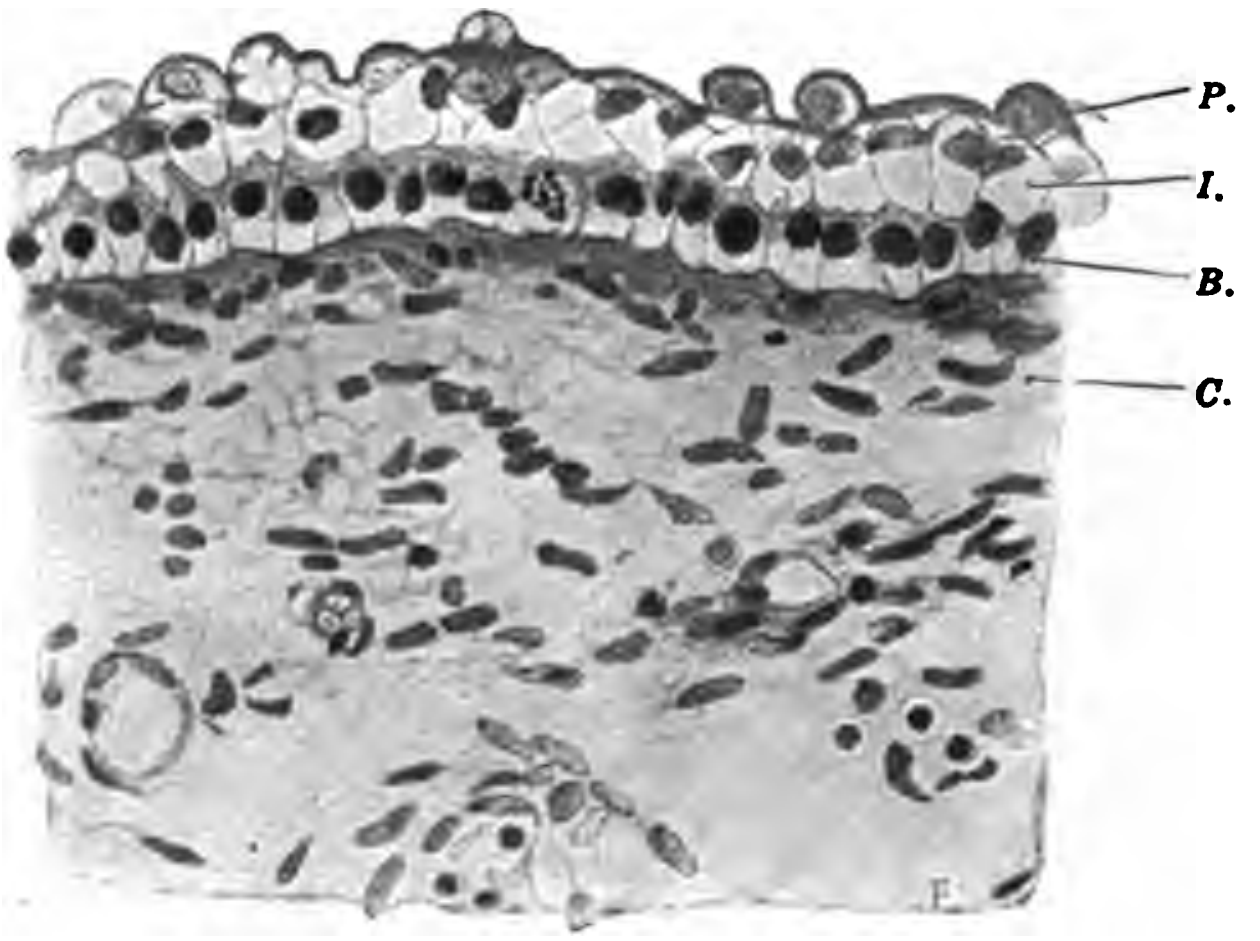

FIG. 199.—Human fetus, 85 mm. vertex-breech length, male. Epidermis distinctly three-layered. *P.*, periderm with partly separated cells; *I.*, stratum intermedium; *B.*, basal layer of cells with mitosis; *C.*, corium, rich in cells (mostly spindle-shaped). Mammary region. × 430.

These simple conditions occur from the youngest up to rather advanced stages of development (end of the fourth month), where the integument has not yet formed any special organs. In those places where a modification occurs, as, for example, in the region of the mouth and nose, the epithelium assumes quite early a very considerable thickness. Toward the end of fetal life the layer (layer of prickle cells) situated between the stratum germinativum and the corneous layer becomes the principal constituent of the epidermis. It is a solid layer, varying in thickness in different regions of the body, and its under surface forms an irregular network of ridges and convexities, which increase its surface of contact with the corium from which it is nourished (rete Malpighi). In vertical sections of the skin these ridges appear as the so-called rete papillæ. The layer of prickle cells is composed of a mosaic of closely apposed and regularly spaced large cells; their nuclei are large, they have a polygonal outline in section, and are variable in form and size within narrow limits (Fig. 200).

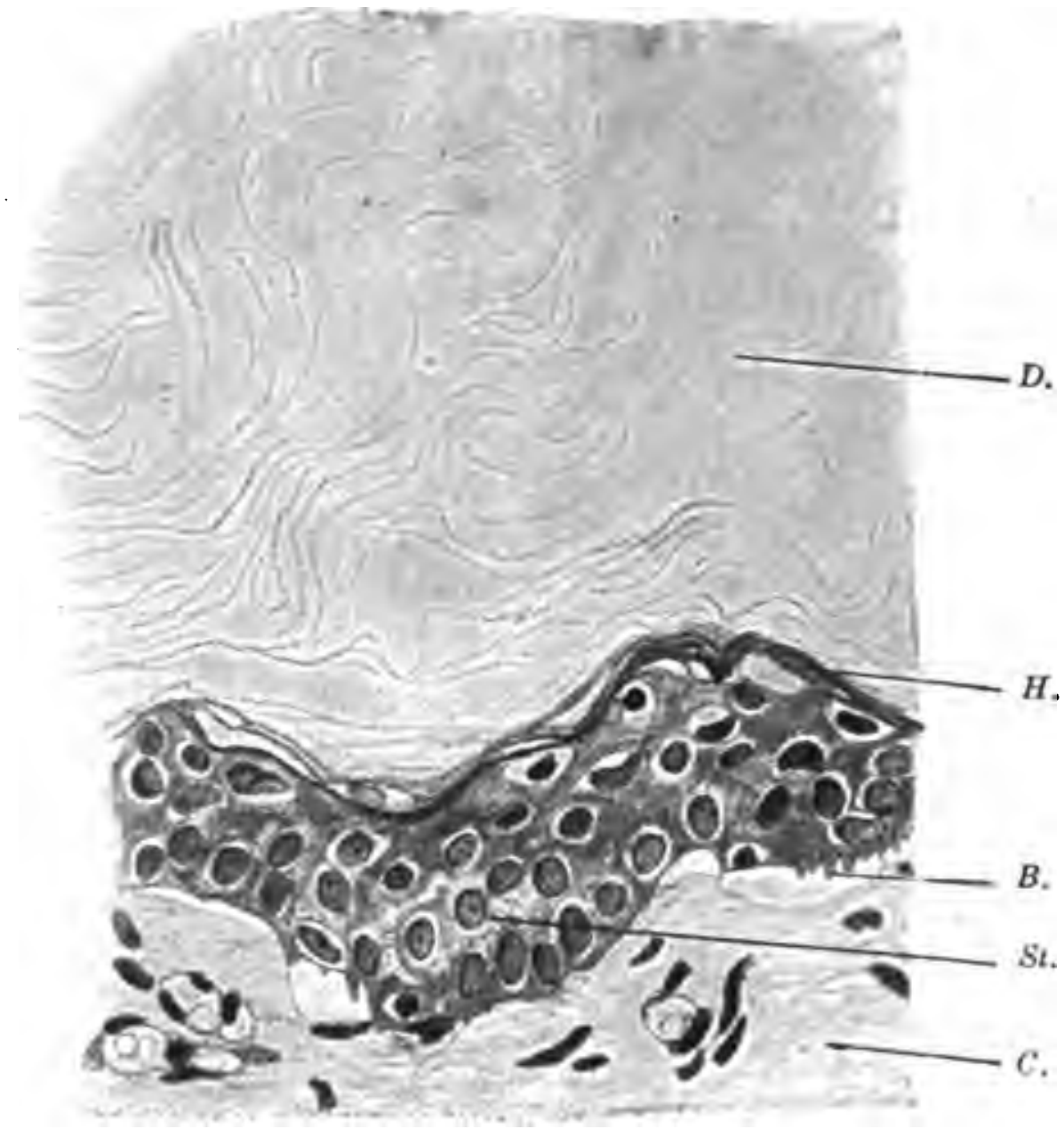

Fig. 200.—Human fetus, eighth month, male. *D.*, stratum disjunctum of the corneous layer; *H.*, deeper portion of the corneous layer (the keratohyalin and eleïdin layers are not recognizable); *St.*, layer of prickle cells with epithelial bridges; *B.*, stratum germinativum, partly separated from the corium and with the processes of the basal portions of the cells; *C.*, corium. From the right mammary region. × 430.

Between the layers of the two- or three-layered epidermis epithelial bridges cannot yet be made out with certainty; but as the epidermis increases in thickness, or in early stages where it has already thickened, they become distinct. With ordinary stains or when unstained they appear as *prickles* (*Riffel,* Max Schultze; *filaments d'union,* Ranvier), but with specific stains (Kromayer, Unna) they appear as *epithelial fibres,* which extend throughout a whole series of cells.

These epithelial fibres form only in the peripheral portions of the cells; these become denser and are distinguished as exoplasm from the endoplasm which contains the nucleus (Studnicka, 1903). The epithelial bridges arise by the formation of vacuoles at the boundaries between cells; the fibres differentiate from the exoplasm. In cell division the entire cell divides and both daughter cells again form on their contact surfaces a new exoplasm layer containing vacuoles. In a similar manner Ide (1889) regards the outer layer of the epidermis cells as a membrane, the prickles being formed by a process of drawing out, as is especially evident after division when an intervening wall is formed between the two young cells.

Almost the same idea, that the outer parts of the epithelial cells are a membrane, is expressed by Unna (1903). According to his view the epithelial cells are in close contact, the apparent clear intervals between them (readily visible in the case of cells rich in protoplasm) not being intercellular spaces, but the outer layer of the cells, which stains with difficulty and is practically a membrane. The epithelial fibres are not empty spaces or spaces merely filled with intercellular fluid; empty spaces have a very different appearance, as may be seen where the protoplasm has retracted from around material (leucocytes) which has penetrated it. The limits between the cells are at the so-called nodes of Bizzozero, situated approximately at the middle of the epithelial bridges. These nodes lie in the very narrow clefts between the cells and appear as nodes on account of differences in refraction on staining. In cornification it is only this membrane-like exoplasm layer that becomes cornified, and the remains of the nodes are retained on its surface.

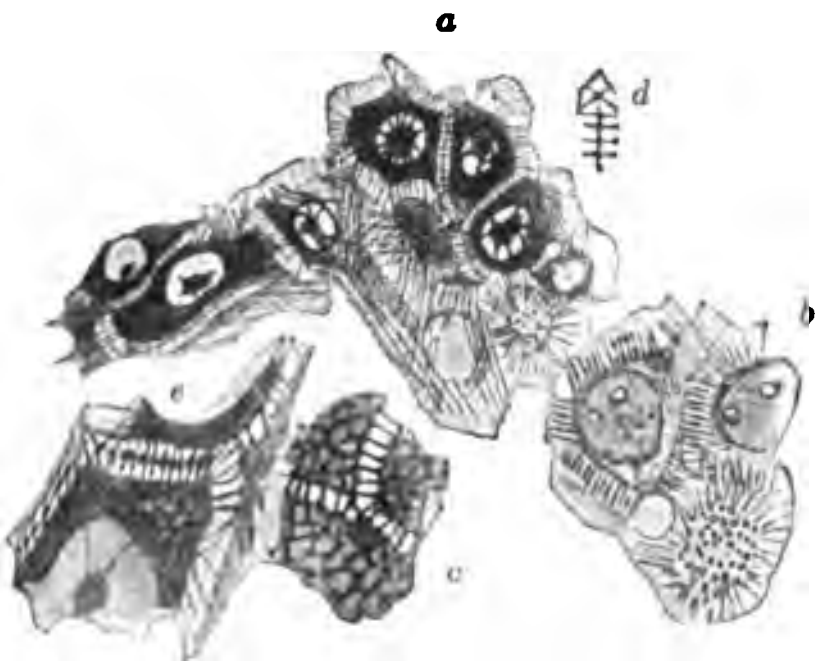

FIG. 201.—Epithelial fibres and cell bridges from the layer of prickle cells. From a pointed condyloma, adult. *a*, Unna's epithelial fibre stain; long fibres traverse the protoplasm of the epithelial cells, nodes on the intercellular bridges. (*d* is from the same preparation, more highly magnified.) × 430. *b*, unstained; nodes partly double. × 860. *c* and *e*, stained with iron-hæmatoxylin; nodes visible in addition to the fibres. × 860.

The question whether the nodes are actually form elements or merely the result of light interference by superposed networks, is not yet definitely settled; it would appear that the cell walls traversed by fibres may be confused with nodes in the thin (unstained) section, for nodes are frequently seen to be united by a narrow streak parallel to the cell wall (see Fig. 201, *a*, *d*, *e*).

That the epithelial fibres arise from the exoplasm is generally admitted. They do not merely unite neighboring cells, but may extend through a whole series of cells. According to Schridde (1906) certain regular fibre systems may be recognized: in the deepest layers of the epidermis they form perpendicularly placed ovals, which are found also in higher layers; nearer the surface they form circles; and at the surface horizontally placed ellipses. The form of the fibre arrangement consequently follows that of the cells, which nearer the corium are columnar, while those higher up are equal in all their diameters, and, finally, those at the surface are flattened.

c. FORMATION OF THE STRATUM CORNEUM.

Those regions in which the epidermis consists of many layers show a cornification, but also in other regions of the body there early appear indications of it. These are distinctly visible in the second month, and in the third month the entire skin is undergoing cornification.

Cedercreutz (1907), using the method of Zilliacus, obtained the following colorations in a fetus 3.5 cm. in length:

Yellow: the face, especially in the region around the mouth and nose (most marked in the epithelial plugs of the nostrils) and in front of the pinna.

Yellowish: the lateral portions of the back, especially in the lower part, and also the lateral portions of the abdomen. The arrangement of the yellow spots on the body was rather distinctly symmetrical.

Bluish-violet: the umbilical cord, the pinna, and the fingers and toes.

In all other regions the skin assumed a dirty bluish-brownish green color.

In a fetus 5 cm. in length the entire body was distinctly colored yellow.

The pavement epithelium, which becomes yellow with this stain, picric sublimate, and hæmalum, must be regarded as cornified. Björkenheim (1906) has shown that the same regions that stain yellow also resist pepsin and trypsin digestion—a peculiarity which in the skin and mucous membranes is associated only with cornified epithelium.

The cornification of the periderm, however, does not pass through the same stages as are to be seen in the formation of the definitive corneous layer. This is shown by the observation of Ernst (1896), who found that in the fourth month cornification could nowhere be observed in the hand or foot, except in the nails, by the Gram method of staining, and that a uniform corneous layer first appeared on the toes in the sixth month.

In young embryos whose cells of the corneous layer still retain their nuclei, keratohyalin and eleïdin, which are later the constant by-products of cornification, are completely wanting.

Keratohyalin and eleïdin (parakeratose) are also lacking in the adult skin in places which cornify (pathologically) in such a manner that the nuclei of the corneous cells remain colorable with nuclear stains (hæmatoxylin, methylene blue).

These substances first appear at the end of the third month in places where the epithelial cells are arranged in many layers. In fetuses 10 cm. in length keratohyalin granules are rather abundant in the face, but at this stage they are to be found elsewhere on the body only in places where longer outgrowths of the epidermis occur, as, for example, at the mouths of the long epithelial appendages around the nipples, in the anlage of the mammary gland, and, especially, in the epidermis of the nail bed. At the beginning of the fifth month keratohyalin is still lacking in the skin in general (Stöhr, 1903); but trichohyalin has formed in the hairs and keratohyalin in the epidermis of the hair follicles. With the continued development of the skin the process of cornification takes an entirely different course. The same substance that had already appeared in the early fetal stages, although in much smaller quantities, keratin, seems to result from the process; but at the surface of the skin in later stages the cornification is usually accompanied by the formation of the by-products already mentioned. As a consequence the corneous layer, on account of characteristic refractive properties and staining peculiarities, may be divided from below upwards into certain readily distinguishable layers. These are:

1. The *stratum granulosum,* with keratohyalin granules. The keratohyalin (Waldeyer), in the form of round or irregularly shaped granules (clumps, threads, occasionally bent at an angle or branched), is situated between the nuclei and the fibrillar layer of the epithelial cells, the exoplasma always forming an external investment of the cells free from granules. From it and its fibrillæ the keratin is formed (Unna); the keratohyalin forms in the rest of the protoplasm. That the nucleus is concerned in its formation does not seem to be definitely shown by the similar staining properties of the keratohyalin and the nuclear chromatin, by the similar non-polarizing refraction of the nucleus and stratum granulosum (the layer of prickle cells, on the other hand, being doubly refractive, as well as the superficial corneous layers), and by the diminution of the nucleus as the keratohyalin increases. Arcangeli (1908), it is true, claims to have directly observed (in the œsophagus of the guinea-pig) the extrusion of keratohyalin granules from the nucleus; and Cone (1907) has seen the same outpouchings and expulsions of chromatin from the nucleus in human skin which had been kept for eighteen to twenty-four hours in a thermostat. The keratohyalin is often situated at first at the periphery of the protoplasm (Weidenreich, 1901; Apolant, 1901), but collects later and preferably in the neighborhood of the nucleus. It is insoluble in our hardening fluids, and especially in water, alcohol, and ether; but is soluble in alkalies and acids. In contrast to keratin it is soluble in hydrochloric-pepsin. It stains deeply with nuclear and acid stains (methyleosin, Zander, 1886; Rosenstadt, 1897; acid fuchsin), but not with osmic acid or Sudan (Rabl, 1902). Unna believes that with its appearance the glassy transparency of the skin of the young fetus disappears, since the keratohyalin (and eleïdin), on account of its high refractive index, would render the skin opaque white.

2. The *stratum lucidum* (Oehl's layer) with eleïdin drops. Immediately over the keratohyalin stratum is a thin layer which also remains unstained when treated with osmic acid, but after such treatment stains red with picrocarmine (Unna's basal corneous layer, Ranvier's stratum intermedium). Upon this there follows a thicker layer, that blackens with osmic acid (Unna's

superbasal corneous layer). This layer contains the eleïdin, a name proposed by Ranvier for both keratohyalin and eleïdin, the latter having been distinguished from keratohyalin by Unna and Buzzi in 1889. Eleïdin is soluble in water and, in the fresh condition or after hardening, in *strong* alcohol; it stains with picrocarmine and nigrosin (Buzzi). Rabl (1902) regards it as softened keratohyalin, the softening giving it the consistency of a fatty oil (keratoeleïdin). According to the microchemical investigations of Ciliano (1908) it is an albumin. It does not appear in the form of granules, but either as a thickish fluid extending throughout the entire layer, or else in large drops or pools. Dreysel and Oppler (1895) could not detect it in a five-months fetus; it was abundant in the skin of one of eight months.

With ordinary stains or when examined unstained in glycerin the stratum lucidum appears as a clear band. In this layer the cell membranes are already composed of keratin.

3. The *stratum corneum* forms the outermost portion of the skin. In its cells only the exoplasmic portion and the thickened fibrillar layer are cornified (Unna; Ranvier; Weidenreich, 1901), and on their surfaces remains of the prickles can still be recognized. In the cells themselves a fat which reduces osmic acid collects and becomes very distinct in sections on treatment with osmic acid after fixation in Müller's fluid (Rabl, 1902); according to Ranvier it has some resemblance to beeswax. The cells which contain this substance are flat and thin, but possess the property of swelling after an infiltrating injection of fluid into the skin. Probably the fat (pareleïdin, Weidenreich) is formed in some way from eleïdin (Rabl). Apolant (1901) assumes that the eleïdin must be expelled from the flat corneous scales which represent completely cornified cells. The most superficial portion of the corneous layer stains diffusely with osmic acid. It has been termed by Ranvier the stratum disjunctum and by Unna (1883) the superficial corneous layer.

In the horny substance there are two kinds of substances which react differently to chemical reagents (Unna and Golodetz, 1908): (1) those which are not digested by hydrochloric-pepsin and which color red with Millon's reagent (presence of tyrosin), but are insoluble in fuming nitric acid or in sulphuric acid + hydrogen peroxide (keratin A); and (2) those which also are undigested by hydrochloric-pepsin and stain red with Millon's reagent, but are soluble in the strong acids mentioned (keratin B).

d. GRANULE INCLUSIONS OF THE EPIDERMAL CELLS.

While the cells, as they pass toward the surface, become cornified and in so doing form keratohyalin, eleïdin, a wax-like substance, and tyrosin, the deeper layers contain other substances which are not found nearer the surface.

1. *Pigment* (melanin) occurs only in the deepest layers of the epidermis and develops chiefly only after birth. In a six months fetus Dreysel (1895) found no pigment; the granules which blackened with osmic acid did so also after previous treatment with chromic acid, a reaction which indicates fat but always destroys melanin. The extra-uterine development of pigment is much more distinct in the dark races than in Europeans. Negro children are quite light-colored at birth; they become brownish yellow on the second day and thereafter darken rapidly (Wieting and Hamdy, 1907), so that in six weeks they have reached the normal degree of darkness (Falkenstein; at four months according to Frédéric, 1905). The children of the Australian aborigines are pale yellow with the exception of some black lines around the mouth, eyes, and nails—but by the broadening of these lines they become black in a few days (Gunn, according to Merkel). The pigment of the epidermis is much more abundant than that which occurs in the corium; indeed, the latter may be entirely lacking. The epidermal pigment seems to be formed *in situ*. That it may be formed there is shown by experiments on the adult (exposure to Finsen light rays for two hours, accompanied by cooling and deprivation of blood, after which treatment excised portions of skin, examined immediately, show an increase in the amount of pigment), by the pigmentation of skin from a cadaver (in incubator, Meirowsky, 1906, 1908), and by the pigmentation of vitiligo spots in the absence of pigment in the corium (Buschke, 1907). Furthermore, the preferential presence of pigment in the skin, chorioid, and ependyma is an indication of a special pigment-forming faculty of the ectoderm (chromatophoroma of the central nervous system). In the epidermis the pigment granules occur:

a. In the ordinary epithelial cells, at first surrounding the nucleus (Grund, 1905; Meirowsky, 1906, who regards the pigment as a transformation of the nucleolar substance), but later mostly in a cap-like mass on its outer surface.

b. In stellate cells (chromatophores), which resemble the Langerhans cells. Whether these apparently stellate cells are really branched or whether the processes extending out from them are not streams of pigment granules passing out into the spaces between the small contact surfaces of adjacent ordinary rete cells (Rabl), is not as yet determined. According to Meirowsky's (1908) observations these cells develop from ordinary epidermis cells.

The similarity of the chromatophores to the greatly branched Langerhans cells is striking, these latter cells, as well as the former, being demonstrable with especial distinctness and in large numbers by the gold and silver methods (Ramon y Cajal's and Levaditi's silver method), so much so that on the basis of this reaction the Langerhans cells have already and again recently been actually termed colorless pigment cells (Schreiber and Schneider, 1908; Bizzozero, 1908). The questions in discussion turn upon whether the epithelium always forms pigment *in situ* (Post, 1893, the development of feathers; Jarisch, 1892, no pigment in the hair papillæ; Schwalbe, 1893, the change of hair coat in the ermine, in which the white winter coat contains no pigment, while the summer coat makes its appearance pigmented; Rosentadt, 1897), whether the epithelium also forms the spider-like cells (melanoblasts) (Grund, 1905; L. Loeb, 1898; Wieting and Hamdy, 1904, the gradual pigmentation of the nose in new-born dogs), which then may wander from the epidermis into the cutis (pigment stored up in the lymph-nodes, shown by Jadassohn, 1892, in pityriasis rubra and by Schmorl, 1893, in the negro), or whether the chromatophores are originally pigmented connective-tissue cells which wander into the epidermis and supply its cells with pigment (Ehrmann, 1896; in the unpigmented egg of the triton there is formed in the mesenchyme, when the development of the blood begins, a series of dark cells, melanoblasts, which later become rich in pigment granules and give rise to all the pigment in the body. No pigment is formed in the epithelium, it is carried there by the melanoblasts; they appear about the hair anlagen at an early period, even before the formation of the papillæ). According to all recent works the idea that pigment is formed in the epidermis itself seems to be well founded.

2. *Glycogen* is abundantly present in the embryonic epidermis (S. H. Gage, 1906). After the sixth month it diminishes in quantity and is finally to be found only in the cells in which it occurs in the adult (Lombardo, 1907). The epithelium of the sudoriparous glands, especially, regularly contains glycogen, the more the more actively they are secreting; furthermore, the outer root sheath of the growing hair, from the bulb to the insertion of the muscle, contains it, while in that of the bulb hairs it is wanting (Brunner, 1906; Lombardo).

3. *Fat* is especially evident in the basal columnar cells and in the stratum granulosum even from the fifth month. The layer of prickle cells which intervenes between these is practically fat-free, its fat having presumably been used up during the divisions of the cells. As evidence for the absence of fat in the prickle cells it may be stated that post mortem no fat appears in them when they are placed in a thermostat, while in twenty-four to seventy-two hours the quantity of it in the stratum cylindricum and stratum granulosum is greatly increased (Cone, 1907). In the layer of columnar cells the fat, made evident by fettponceau, surrounds the nucleus in the form of granules of varying size (up to one-quarter the size of the nucleus) and streams out toward the periphery of the cells. In the stratum granulosum it is equally distributed from the cell periphery to the edge of the nuclear cavity, some loops lying even within this (according to Unna it is completely filled by a fat drop). Much fat is also present in the stratum lucidum, where it is more irregular both in form and distribution than in the stratum granulosum. In the actual stratum corneum it lies especially between the cells.

In between the epithelial cells processes of branched connective-tissue cells filled with fat granules (lipophores, Albrecht) extend from below.

B. CORIUM.

The connective-tissue portion of the skin, the corium, is developed from the most superficial portions of the somites. Ventrally it arises from the outer part of the dermomuscular plate and is applied to the myotomes so that, together with the epidermis, it sinks down into the furrows between successive myotomes (sub-epithelial segments, Osc. Schultze, 1897). The case is similar dorsally, where the segmental furrows are continued between the sclerotomes which surround the spinal cord. The segmental furrows, however, soon disappear. The corium or dermis is at first very cellular, and the two portions into which it later divides, the corium proper and the subcutaneous fascia (tela subcutanea), are not distinguishable in the second month. Its oval cells elongate and begin to form fibrils (observed by Spalteholz, 1906, in the fifth week) in their own protoplasm, and these soon anastomose and form a delicate, somewhat irregular network, which, according to Spalteholz, remains throughout life unsheathed by the protoplasm mass and in connection with its original cells. A regular arrangement of the bundles of fibrils makes its appearance at about the end of the third month. In embryos 7–8 cm. in length the bundles arrange themselves in the lower part of the body in parallel bands running around the body (a result of the stretching of the skin by the growing liver). A little later the parallel arrangement of the bundles appears in the remaining portions of the skin as a result of the tension produced in it by growth (Otto Burkard, 1903). The regularity of the fibrils is interfered with by the development of the hairs (from the fourth month onwards), since the bundles separate around the down-growing hairs and form meshes, which after certain modifications are transformed into Langer's (1861) rhomboidal meshes.

In the later embryonic period the superficial layer of the corium separates into the *papillary bodies* and the *stratum reticulare.* The *papillary bodies* form a superficial layer whose fibres —collagenous connective tissue—stain reddish with Van Gieson's stain (picric acid and acid fuchsin) and are arranged horizontally, but with many vertical fibres that extend to the boundary of the epidermis.

The *stratum reticulare* consists of coarse and fine bundles of connective-tissue fibres, which, interwoven, run more or less parallel to the surface of the skin and take the picric acid of Van Gieson's stain somewhat more strongly. The varieties of fibres which can be clearly distinguished microchemically differentiate rather early in certain regions of the body. According to earlier accounts the elastic fibres of the corium first appear in the seventh or eighth month, but according to Spalteholz (1906) they are present in the truncus arteriosus of the chick even in the third day, in pig embryos of 9.2 mm., and in calf embryos (in the ligamentum nuchæ) of 35 mm. They arise intracellularly, either directly as fibres without any granular prophases in the protoplasm of the cells (Spalteholz; Gemmill, 1906, in tendons; Schiffmann, 1903), or as rows of granules (Jones, 1907, in the epicardium of chick embryos; Teuffel, in the fetal lung; Nakai, 1905, in the vessels of chick embryos). The elastic substance can, apparently, form in all fibroblasts; special elastoblasts (Passarge, 1894; Loisel, 1897) are not recognizable.

Pigment cells occur in the corium in varying numbers; they are partly small, like the epithelial chromatophores, partly especially large and deeply seated. These latter appear during the fourth fetal month. According to Grimm (1895) and Adachi (1902) they are the cells which produce the blue gluteal spots (Mongolian spots). The corium pigment appears to be formed in the connective-tissue cells themselves, as the result of activities by which pigment is produced from uncolored constituents (according to Meirowsky, 1908, the cell nuclei are concerned in the process; extruded nucleoli are transformed into pigment).

The young, richly cellular corium contains wide blood-vessels with a distinct endothelium, but without any of the other constituents of the wall. Gradually the abundant and specialized vascular supply of the skin of the child develops, with its superficial vascular network and a deeper one parallel with the surface of the skin and connected with the superficial network by vertical branches, and with the vascular supply to the glands and hairs and some superficial fat islands.

Beneath the corium is a looser tissue characterized by the formation of fat islands. According to Toldt these begin to form at definite places, so that the fat lobe is a special organ, with a peculiar blood-supply—a view with which, according to Rabl (1902), the sharp delimitation of the fat lobes is in agreement. More generally accepted is the idea, first suggested by Czajewicz (1866) and later more definitely by Hemming (1876), that in the subcutaneous tissue every cell may become a fat cell, even although there are constant areas in which fat develops by preference (Unna, 1881). The cells are at first branched and contain the fat in the form of small droplets, from which larger drops are formed, while the processes of the cells become less distinct. Gradually a large fat drop is formed, surrounded by a thin layer of protoplasm which contains the nucleus. The fat cells lie in groups, surrounded by ordinary connective tissue and richly supplied with blood-vessels. The masses of fat assume various forms, such as *lobes* into which the principal blood-vessel enters from below, *cords* extending along the blood-vessels, or *islands* standing isolated on the blood-vessels of the hair follicles and lacking a special vessel.

With the modern fat stains (fettponceau) it is possible to find even in the adult skin branched fat cells packed with small and large drops, whose processes extend into the epidermis (near to which they usually lie). These are Albrecht's lipophores (Cone, 1907). Fat granules may also be detected by staining in cells with pigment granules and in those with enzyme granules.

C. THE CONNECTION BETWEEN THE CORIUM AND EPIDERMIS.

The two-layered epidermis lies flat upon the corium throughout the greater portion of the body. In those places where the basal layer consists of high columnar cells, even in early stages (30 mm.) a closer connection occurs, the bases of the epidermal cells being divided into fine processes which fit into corresponding depressions of the corium. With increasing growth this connection becomes continually more intimate, and in fetuses of 10 cm. the basal portions of the columnar cells consist of a finely fibred protoplasm, which stains deeply and represents the rooting feet of the epidermis cells, firmly connected with the especially cellular surface of the dermis. This condition becomes more marked with increasing growth. In the adult skin the central parts especially of the cell bases seem to have formed fibrous processes. By maceration in 10 per cent. salt solution (Merk, 1904), in pyroligneous acid (Loewy), or in weak acetic acid (Blaschko, 1888) the epidermis separates from the corium without losing its own continuity, so that it seems that a change in the arrangement of the protoplasm of the foot portions of the epidermal cells has occurred (Merk), a change which is also indicated by their different staining properties (bright red with eosin; reddish yellow with picric-acid-fuchsin, in contrast with the yellow color of the rest of the cell, a darker brown than the epithelial cells with saffranin after fixation in Flemming's fluid; a brown or grey color, the epithelium remaining uncolored, with the elastic fibril stain of Unna and Weigert, Rabl, 1902). Quite as delicate as the fibre structure of the epithelial root feet is that of the subjacent superficial layers of the corium. But while the former are arranged perpendicular to the surface, in correspondence with the arrangement of their fibrils (epithelial fibres), the delicate fibrillation of the corium is, in general, parallel with the surface, only the finest of connective-tissue and elastic fibres ascending vertically towards the epithelium boundary. A penetration of corium fibres into the epidermis cannot be made out, but whether basal epithelial cells separate from the epidermis and wander into the corium or not is less certain. According to Kromayer (1905, dermoplasia), and especially according to Retterer (1904), the superficial portion of the corium is of epithelial origin, being formed by cells separated from the epidermis; and recently Krauss (1906), as the result of the employment of an especially distinctive staining method, has regarded a portion of the corium in the Reptilia as derived from the epidermis. On account of the irregularity of the contact surface between the epidermis and the corium, even the thinnest sections are more or less oblique and give the appearance of an interstratification of the deepest portions of the epithelium and the connective-tissue fibres (the elastic fibres, namely), and so of the penetration of the fibres into the epithelium. So extensive a migration of epithelial cells and their conversion into connective-tissue cells has certainly not been demonstrated. A certain mingling in the course of development of living epithelial elements, such as touch corpuscles, pigment cells, and perhaps also unpigmented nævus cells, with corium constituents has been observed by many authors. In pathological processes separated epithelial cells (as in lichen ruber and vesicular eruptions) or epithelial islands or appendages (as in tuberculosis and trauma) usually gradually degenerate and only rarely find opportunities for further growth; when they do so the growth is always of an epithelial form (traumatic epithelial cysts, milia).

The connection of the epidermis and corium, notwithstanding the ease with which they may be separated by maceration, is exceptionally intimate and is not broken by the displacements of the integument which occur in the course of normal development. The epidermis follows every outgrowth of the corium and the latter yields to every epithelial projection, closely surrounding it on all sides. Since the epidermis and superficial corium (in later stages separable into the papillary bodies and the subpapillary layer) constitute anatomically a single tissue-mass, and also are exposed in common to all changes, physiological and pathological, Kromayer (1899) has united them under the term *parenchyma skin.*

D. DERMAL RIDGES AND FOLDS.

DERMAL RIDGES PRODUCED BY SURFACE GROWTH, GROWTH FOLDS.

For a long time the under surface of the epidermis remains smooth or slightly and irregularly wavy. With the development of hairs on the eyebrows and lips in the second month its first deep ingrowths into the corium occur. Much later, when the rest of the hair has begun to form everywhere, the lower surface of the epidermis begins to increase in certain regions, the rete ridges begin to form on the palms of the hands and the soles of the feet, and some time after these the more delicate outgrowths which form the papillary bodies and the rete Malpighi appear. The rete ridges make their appearance on the previously formed touch balls (see Figs. 73, 76, 77, and 78, p. 87–89). Each terminal phalanx of the fingers and toes bears one of these, four occupy the interdigital spaces between the heads of the metacarpal and metatarsal bones, and one corresponds to each of the lateral swellings of the hand and one to the side of the little toe. These are recognizable after the sixth week and reach their greatest relative development in the fifteenth week. After that they begin to disappear and their place is taken by corresponding systems of papillary ridges (papillary ridge patterns, which have a triradiate form, consisting of three lines arranged in the form of a triangle, with diverging lines from each angle, Schlaginhaufen, 1905; Whipple, 1904). In the eighth week (Evatt, 1907), in fetuses of 3–4 cm. (Wilson, 1880), the epidermis lies flat on the corium and is separable by slight maceration; no trace of ridges is visible. In the eleventh week (Evatt), in fetuses of 9 cm. (Wilson), the skin appears streaked when seen from the surface, showing alternating light and dark lines, the beginnings of the formation of the rete ridges.

While the outer surface of the epidermis is still smooth, without any pattern, there arise on its lower surface simple ridges, that are triangular in section with the apex directed downwards. They produce the striated appearance of the skin and are *Blaschko's gland ridges,* the sudoriparous glands forming later on their lower angles. The outer surface is not raised into corresponding ridges; rather it may show grooves (W. Krause, 1902). Only in the eighteenth week do ridge-like elevations of the outer surface appear, one corresponding to each of those on the lower surface. The development of the ridges begins at the tips of the fingers and toes and proceeds proximally over the entire surface (not radially from a centre), at the same time producing the ridge patterns with their whorls and spirals. These patterns even in this early stage show the same individual differences as may be observed in adults, and this is so even before the ridges of the outer surface are formed. First the *gland ridges* are formed and then the sudoriparous glands begin to form from them. At about the same time the same process takes place in the palm of the hand. In the cases of the gland ridges (papillary ridges, Hepburn; epidermic ridges, Whipple, 1904) an epithelial elevation of the outer surface (crista epidermidis superficialis, Heidenhain, 1906) corresponds to an epidermal ridge of the under surface (crista epidermidis profunda intermedia, Heidenhain; subdermal ridge, Evatt, 1907). At regular intervals sudoriparous glands arise from them, their ducts later traversing them in a cork-screw fashion to reach the exterior. Then a second series of lower ridges, destitute of glands, is interposed between the gland ridges, forming *Blaschko's folds* (cristæ epidermidis profundæ limitantes, Heidenhain); and finally delicate low transverse bridges are formed between the two series. Corresponding to the folds on the outer surface, and therefore corresponding to the grooves between the ridges, are depressions of the epidermis (sulci superficiales, Heidenhain).

According to Whipple (1904) the gland ridges are formed by the union of isolated epithelial papillæ, each of which is traversed by a sudoriparous gland; and the transition of a ridge into a series of such papillæ with few or but one gland duct is also to be seen in certain regions of the adult skin, constantly on the radial sides of the fingers and especially of the index finger. The development of the ridges on the palms and soles is completed at the end of the fifth month. From them there arise as secondary outgrowths the rete papillæ, between which the true papillary bodies occur. In extra-uterine life the ridges lose much of their regularity, since new irregularly arranged outgrowths make their appearance.

Simultaneously with the formation of the rete ridges the outer surface of the corium develops elevations and papillæ, as a negative, as it were, of the epidermis; for, on account of the continuity of the entire parenchyma skin, an elevation of the epidermis must produce a practically corresponding depression of the corium. The dermal ridges of the hands and feet, so far as these are not movement folds but are the result of the enlargement of the epidermis surface (Lewinski, 1883), have their arrangement determined by a series of mechanical conditions. In general, they are arranged transversely to the direction of the limb in grasping or progressing (friction skin, Whipple) and, consequently, at right angles to the directions of the most delicate sensations for the substratum (Schlaginhaufen; their distally overlapping, imbricated arrangement at the tips of the fingers, pointed out by Kidd, 1905, also serves to increase sensation); they constitute neutral curves, so that they are neither stretched nor compressed by tensions of the surface, and, consequently, the touch sensation is not disturbed by the sensation of a surface tension (Kolosoff and Pankul, 1906).

In the regions of the body where hair occurs, longer or shorter meshed networks form between the hairs; the rete papillæ become much lower in the vicinity of the hairs, so that these, when fully developed, occupy the centre of a star of low rete papillæ, which extend more or less distinctly upon the hair follicle (Philippson, 1906).

As a result of the formation of the papillæ of the corium and of the ridges and papillæ of the epidermis, the under surface of the latter becomes greatly increased in comparison with its earlier smooth condition, and a very much greater nutritive and functional surface is thus secured for the epidermis. The rete ridges follow in general the tension lines of the skin, so that a correspondence exists between the tension lines and the development of the ridges.

TENSION FOLDS.

In addition to the folds produced by the development of the skin—the growth folds—a second variety occurs, produced by the innumerable repeated bendings and foldings of the skin during movements of the parts (Lewinsky, 1883; Blaschko, 1888; Loewy), or by the strains resulting from these movements (Philippson, 1889; distention folds, Charpy, 1905). In the palm of the hand, where the system of growth folds is most marked, some of the strongest flexion folds have the same direction; but elsewhere a contrast between the two systems seems to exist in that, in parts with strong flexion folds (joints, hands, nape), these cross the lines of tension of the connective-tissue bundles at right angles. The tension of the tissue is the cause of Langer's lines, the connections between the slit-like clefts formed when the skin of the cadaver is pierced by a round instrument. With these also correspond, in addition to the rete ridges, the arrangement of the hairs. The investigation of the tension lines shows that in the fetus great displacements of the skin occur during the course of development.

At first no directions of cleavage can be distinguished in the skin, the tensions to which it is subjected being equal in all directions; but with the commencement of the parallel arrangement of the connective-tissue bundles there arises a definite cleavage (Otto Burkard, 1903). The cleavage lines pass transversely from the dorsum ventrally, diverging, accordingly, ventrally; in the extremities they run longitudinally. This cleavage arises gradually, those portions of the skin that are more strongly stretched by the growth of the deeper parts showing it at an earlier period than those parts in which the conditions of tension are indifferent. It begins in the third month and lasts until the end of the fourth or the beginning of the fifth. By the formation of the hair in the fourth month, the originally parallel bundles of connective tissue become arranged so as to form rhombic meshes, and then suddenly rearrange themselves as a result of the hair development in the fifth month, so that their new arrangement is at right angles to the original one and the cleavage lines become longitudinal in the trunk and circular on the arms though less so on the legs. The gluteal region now shows cleavage for the first time, the lines running circularly and diverging from the gluteal cleft. In the neck they run horizontally around and remain thus until the adult condition, in which they run horizontally from the occipital region to the thorax. Transitions between the courses of the first cleavage lines and the second do not occur. It is not a question of a gradual development as the result of growth processes, but of a very rapid rearrangement of the originally transversely directed rhombic meshes into longitudinally directed ones, with a brief intervening stage in which the meshes are quadrate and in which no definite lines of cleavage occur.

These second cleavage lines vanish in the fifth and the beginning of the sixth month and gradually become horizontal, returning to the primary direction and being at right angles to the secondary one. This change is the result of gradual growth displacements (growth in length) and from it there gradually develop the oblique cleavage lines of the adult, directed from above downwards. The cleavage lines of the head and face change but little during development. (See representation by Otto Burkard, 1903.)

E. THE METAMERISM OF THE SKIN.

The segmental plan upon which the human body is constructed suggests that a metameric arrangement exists also in the skin (Blaschko, 1888). In some mammals (mouse, pig, rabbit), and also in man, the skin in early stages of development follows the metameric arrangement of the underlying structures with which it is connected (the myotomes ventrally and the sclerotomes dorsally, O. Schultze, 1897); this is the subepithelial segmentation.

In fishes the segmental arrangement of pigment cells (Bolk, 1906) indicates such a metamerism of the skin. In mammals none of the well-known metameric markings (such as those of young animals, the zebra and tiger), nor yet the metameric arrangement of the hair (trichomerism, Haacke), nor the circular arrangement of scales on the trunk and tail, can with certainty be referred to a primary metamerism of the skin. That this may exist, however, although invisible to our eyes, is indicated by pathological conditions, which are only to be explained as due to a certain predisposition to disease of growth zones or their boundaries (nævi, linear inflammations). The method of investigation that represents to us the development of skin segments is the comparison of the course of development of the peripheral nerves with that of the skin areas which they supply. No other tissue, neither the skeleton nor the musculature, corresponds with the segmental structure of the skin. Even the blood-vessels are less satisfactory in this respect; for the blood follows the most convenient paths it can find. The blood-vessels accompany the nerves and frequently confuse, by their anastomoses, the distinct metameric course maintained by the nerves.

The nerve connection between the skin and the spinal cord is established in early stages, and it may be supposed that it remains unchanged until the completion of development in spite of all displacements and modifications dependent on growth. Those portions of the skin which are supplied, for instance, by the sixth and seventh thoracic nerves, and which Grosser and Fröhlich (1902) have followed throughout the development from an embryo of 14½ mm. onwards, are to be regarded as identical in both the fetus and the adult.

The territory which is supplied by a definite segmental spinal nerve remains the same from the beginning to the end and is known as a *dermatome*. At first the dermatomes form rings around the body, narrower ventrally and broader dorsally, in correspondence with the curvature of the embryo, in which the thorax and abdomen are much shorter than the back. The spinal cord at first grows more rapidly than the skin, and the lagging behind of the latter is shown by the fact that the cutaneous nerve branches pass proximally from, for example, an intercostal trunk, in order to reach their cutaneous areas. They are held back because their areas of distribution are of slower growth than the spinal cord. Later on the spinal cord lags behind, and the skin, with the outgrowths of the arms and legs, grows more quickly, drawing the nerves peripherally with it. The growth of the extremities draws the skin out, and the more distant cutaneous areas of the trunk must follow towards the region from which the limbs arise. The dissection of the nerves (Voigt, 1857) shows the situation of the corresponding skin areas, which are to be regarded as skin metameres. In spite of all displacements, such as occur, for example, in the extremities, the common supply of an area of skin by the branches of the metameric nerve indicates its individuality (Head, 1898; Sherrington, 1893; Seiffer, 1898); and comparative studies (Grosser and Fröhlich, 1902, 1904) show that it is to be regarded as a genetic anlage (dermatome).

The conditions are much the clearest in the trunk, although even in this region great displacements occur. To the skin pass:

1. Twigs of the ramus posterior of each spinal nerve, the medial twigs in the upper regions and the lateral in the lower. Both pass downwards from the intravertebral foramen on their way to the skin, the medial (upper) ones to a lesser extent than the lower (lateral), which occasionally descend rapidly over three to four rib regions, since their cutaneous areas have been drawn downwards to this extent by the development of the lower limbs.

2. The rami laterales and the rami mediales are carried out of their original course, parallel to the ribs, to a much smaller extent. On the ventral surface of the body the skin follows more regularly the growth of the deeper parts; it is drawn downwards to a certain extent, but at the same time the ribs and the greatly enlarged abdominal wall are also displaced caudally. The skin and the deeper parts have a common growth and retain their relative positions.

F. THE HAIR.

The development of the hair begins on the eyebrows, the upper lip, and chin at the end of the second month. On the eyebrows it has been seen in fetuses of 27 mm. (Keibel and Elze, "Normentafel," No. 80, 1908), but the number of anlagen was still very small. In a fetus 32 mm. in its greatest length (No. 307 of the collection of Professor Robert Meyer) I found on the eyebrows 89 anlagen on the left and 81 on the right; on the upper lip 73 anlagen on the left and 57 on the right; on the chin only one of which I could be certain and several uncertain ones.

In another fetus 30 mm. in length (No. 310 of the same collection) the anlagen were somewhat more numerous and to a certain extent further advanced in development. At this time hair anlagen are present in no other regions.

The general hair coat begins to form at the beginning of the fourth month, and at this time only the earliest anlagen occur, except in the face region, where they already show a more advanced development. On the body the anlagen are quite closely placed, on the head they are somwhat further apart, and on the face they are especially close, being arranged laterally on the upper lip in a row which at places is unbroken. The hairs arise singly, but in many regions another appears early on each side of the first-formed hair, so that groups of three are formed. Stöhr (1907) saw on the back of the neck two additional hair follicles sprouting out beside a regularly arranged hair group, but the nature of these could not be determined on account of their slight development.

The phylogenetic origin of the hairs has not yet been definitely ascertained. Certain facts in connection with their structure and arrangement have, however, been taken as the basis for theories whereby the mode of formation of the hair might be explained. Of these theories the two most important are the following:

1. *Maurer's theory* of the origin of hairs from the epithelial sense organs (lateral-line organs) of the Amphibia (Stegocephali) is based upon the similarity of these organs to the first epithelial hair anlagen (hair germs) and upon the comparable arrangement of the sensory hairs (sinus hairs) of the mammals and the lateral-line organs of the head in fish and Amphibia. It explains, according to Maurer, all the conditions of the evolution of the hairs. The transverse rows of hair groups, which are of the greatest importance for the following theory, constitute merely a topographic arrangement, and are independent of the arrangement of the scutes of the Stegocephali.

2. *Weber's theory* of the identity of the scutes of mammals with those of their reptilian ancestors (1893), a theory which has been further worked out by Reh (1896) and De Meijere (1894). As the type of the hair arrangement rows of hairs standing in groups of three have been taken, the groups in successive rows frequently alternating regularly (quincunxial arrangement). This plan is shown in the development of the hairs at the posterior margin of regularly arranged scutes (supposed to represent the scutes of the Promammalia). The coat of the most thickly covered mammals is derived from the groups-of-three arrangement by secondary hair formations, which are usually recognizable in the embryo, or by the arrangement of the hair muscles and the sudoriparous glands. The hair groups belong genetically to the scutes, behind (De Meijere), or, better, upon (Reh), which they arise. This theory receives support from my discovery of the hair disks, in case these may be identified with the touch spots of the reptilian scutes. Just as the reptilian and stegocephalan scutes are bilaterally symmetrical structures, whose planes of symmetry correspond with the longitudinal axes of the trunk or the extremities, so, too, each skin area which is regarded as belonging to a group of three hairs is to be regarded as a bilaterally symmetrical structure from its first beginning, the middle hair of each group of three being situated in its longitudinal axis and being flanked on either side by the two additional hairs, or by all the additional hairs when the group consists of more than three; on the posterior surface of the hairs it has associated with it the sebaceous gland, the sudoriparous gland, the muscle, and the hair plate, the whole forming a hair terri-

tory which must be regarded as corresponding to a scute of the promammalian integument. According to this theory the hairs are to be regarded as new acquisitions by the Mammalia, if the entire scute did not in much earlier periods surround a lateral-line organ. Such a condition would be analogous with what occurs in the fishes, in which the scales of the lateral line also bear the lateral-line organs, and it would render possible a union of the present theory with that of Maurer.

As the first anlage of a hair, in small areas of the three-layered epidermis the nuclei of the columnar cells become higher and more closely packed, so that more cells rest upon a given area of the corium surface than is the case elsewhere (Fig. 202, *primary hair germ*). In addition, there may perhaps be a very slight downward convexity of the germ, but the nuclei of the corium usually do not show any increase in number. These structures are rather uncommon; they seem to represent a very transitory stage, and only when they occur among more developed hair anlagen can they be recognized as the first stage of these. A similar appearance is presented by marginal sections through structures which are distinctly hair germs (Stöhr, 1903) and they must not be confounded with these. They correspond in size with the hair germs, measuring 45–60 μ in diameter. The *hair germ* (Fig. 203) differs from them in the distinct bulging out of the layer of columnar cells towards the corium. The nuclei of the columnar cells are arranged radially to a somewhat distant centre, and are frequently slightly curved so as to be concave toward the centre of the structure (Maurer, 1895, the kiln-like arrangement of the hair cells). At the point toward which the cells converge there is occasionally a roundish opening. Even in this early stage the germs do not possess a radial structure, but are bilaterally symmetrical (Figs. 204 and 205). On one side (the side of the later acute angle between the hair follicle and the under surface of the epidermis, the anterior surface of the hair) the columnar cells come quite up to the hair germ; on the other side (the posterior surface of the hair) lower cells occur in its neighborhood (Stöhr's anlage of the hair canal). The kiln-shaped anlage is covered by some cells placed horizontally. The corium beneath the columnar cells, which are increasing in height, usually contains more nuclei than are present in yet undiffer-

FIG. 202.—Primary hair germ of human fetus, 8.5 cm. in length, male, from the mammary region. Two successive sections in which the circumscribed approximation of the nuclei is visible. The cells of the stratum intermedium have not yet increased in number and there is no increase of the connective-tissue cells of the corium. × 41.

entiated regions, and beneath many hair anlagen the increase of the nuclei is especially pronounced (anlage of the papilla). No differences seem to exist between the early formed hair anlagen of the face and head and those of other portions of the body.

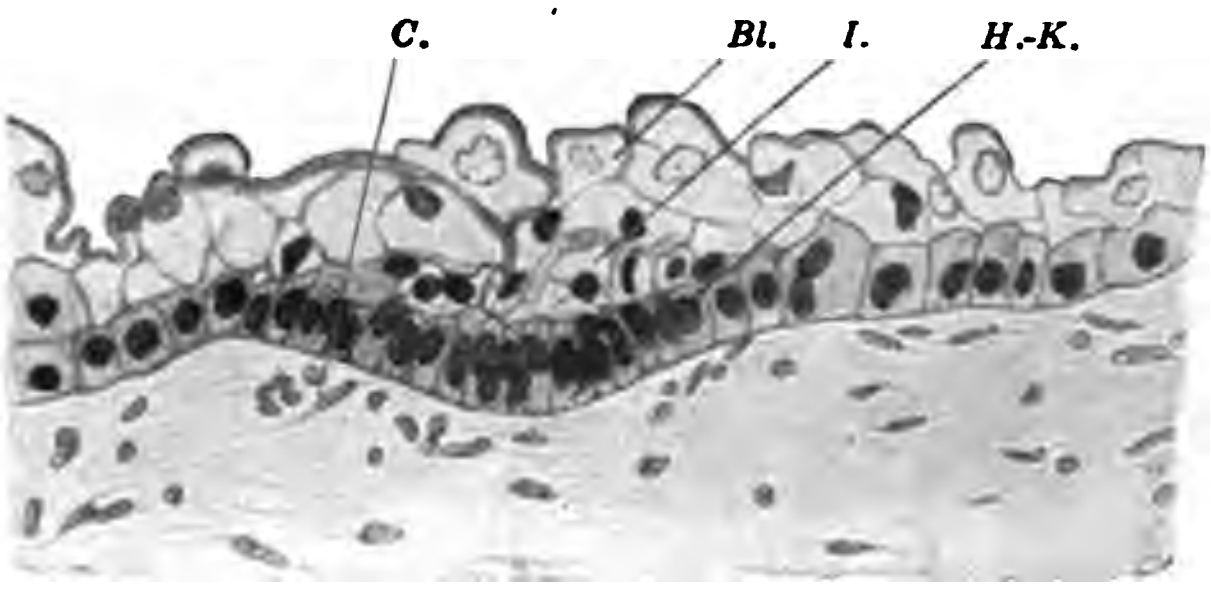

FIG. 203.—Hair germ from the same region as Fig. 202, *H.-K.*, hair germ; *I.*, increase of the cells of the stratum intermedium, and *C*, of the connective-tissue cells of the corium; *Bl.*, periderm cell. × 430.

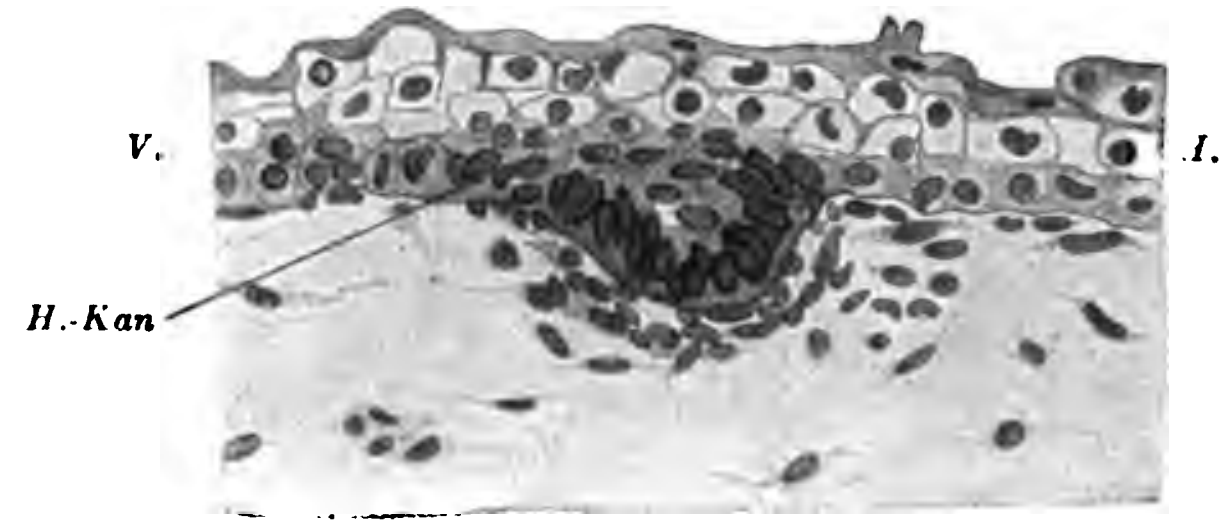

FIG. 204.—Longitudinal section of a hair germ of another 8.5 cm. human fetus, more advanced stage. *H.-Kan.*, hair canal cells (Stöhr). Spaces exist among the cells of the germ. *V.*, anterior surface; *H.*, posterior surface of the hair germ. × 430.

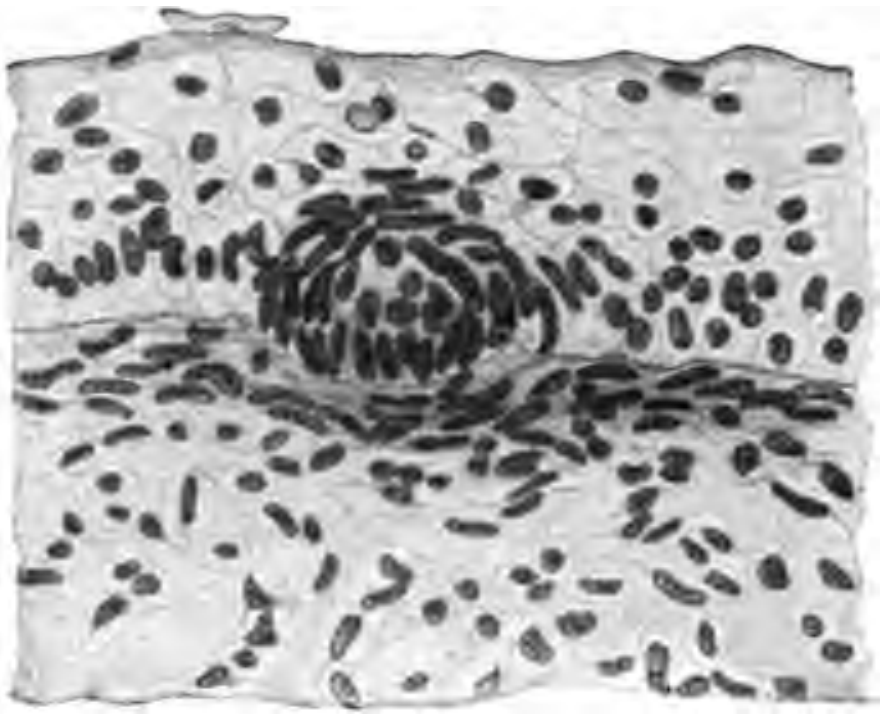

FIG. 205.—Transverse section of a hair germ in the same stage as Fig. 204, from pectoral region of the fetus of Figs. 202 and 203. Shows the distinctly symmetrical structure and the kiln-like arrangement of the cells. × 430.

With the further development of the hair germ Stöhr's stage of the *hair papilla* is reached, in which the hair anlage, while retaining approximately its original diameter, gradually grows downward into the corium (Fig. 206). The hair papilla projects downward from the stratum cylindricum; it consists of an outer layer of cylinder cells, which are already beginning to differentiate in the deeper parts of the follicle, and of polygonal cells, arranged more irregularly, which fill the space bounded by the columnar layer. The latter, when the length of the hair papilla is about three times its breadth, shows on the posterior surface two low outgrowths with outwardly diverging, regularly arranged nuclei. The upper of these is the anlage of the *sebaceous gland,* which in rare instances may be double (one above the other, Diem, 1907); the lower one is that of the *swelling* (hair bed, Unna, 1883), which, usually, becoming lower, extends around to the anterior surface of the follicle. The lowest portion of the hair papilla consists of high columnar cells arranged in a kiln-like manner and forming a convexity which is higher than that of the similarly arranged cells of the hair germ (matrix plate, Garcia, 1891). There is also occasionally to be found in this region, at the point toward which the cells of the

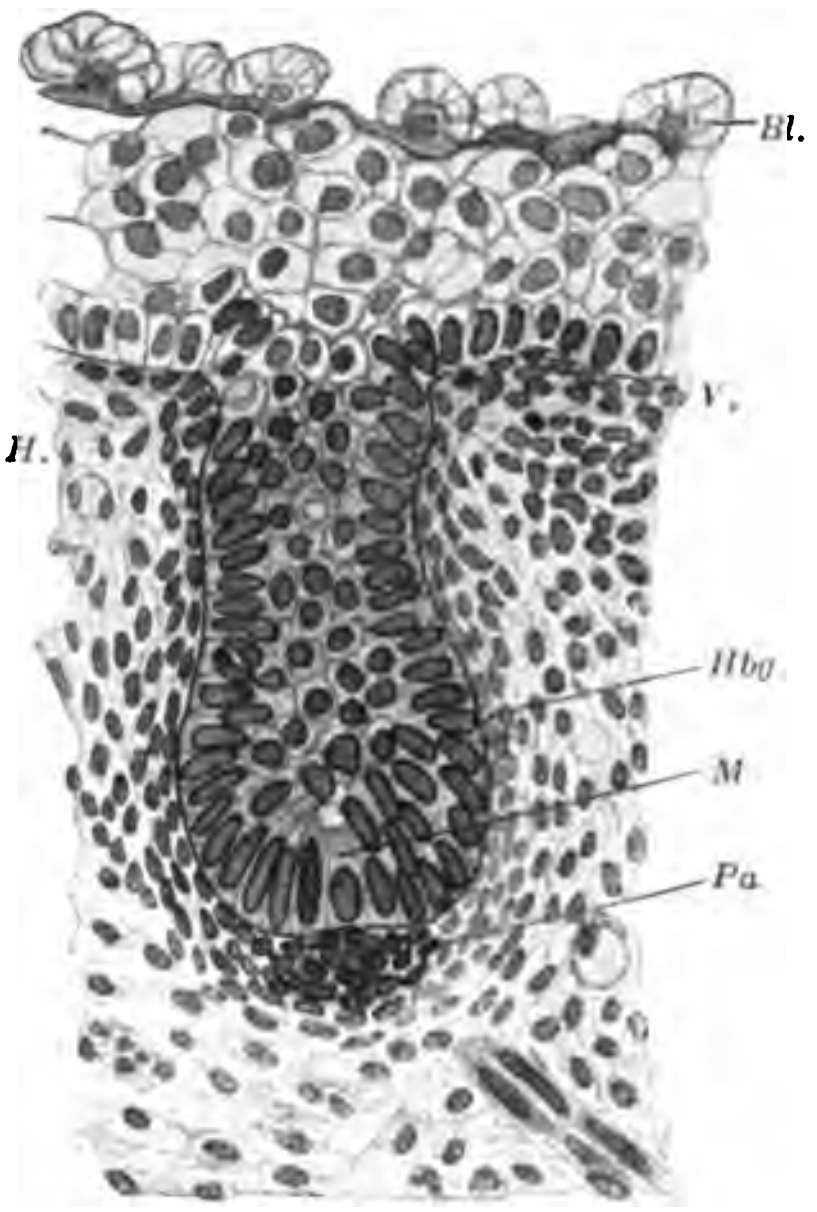

FIG. 206.—Hair papilla from the upper lip of the fetus of Figs. 202, 203, and 205. *M.*, hair matrix with spaces at the converging point of the matrix cells; *Pa.*, anlage of papilla; *Hbg.*, connective-tissue hair sheath; *Bl.*, vesicular cells of the periderm; *V.*, anterior surface of the follicle; *H.*, its posterior surface with the (scarcely recognizable) differentiated arrangement of the nuclei (sebaceous gland and region of the hair swelling). × 430.

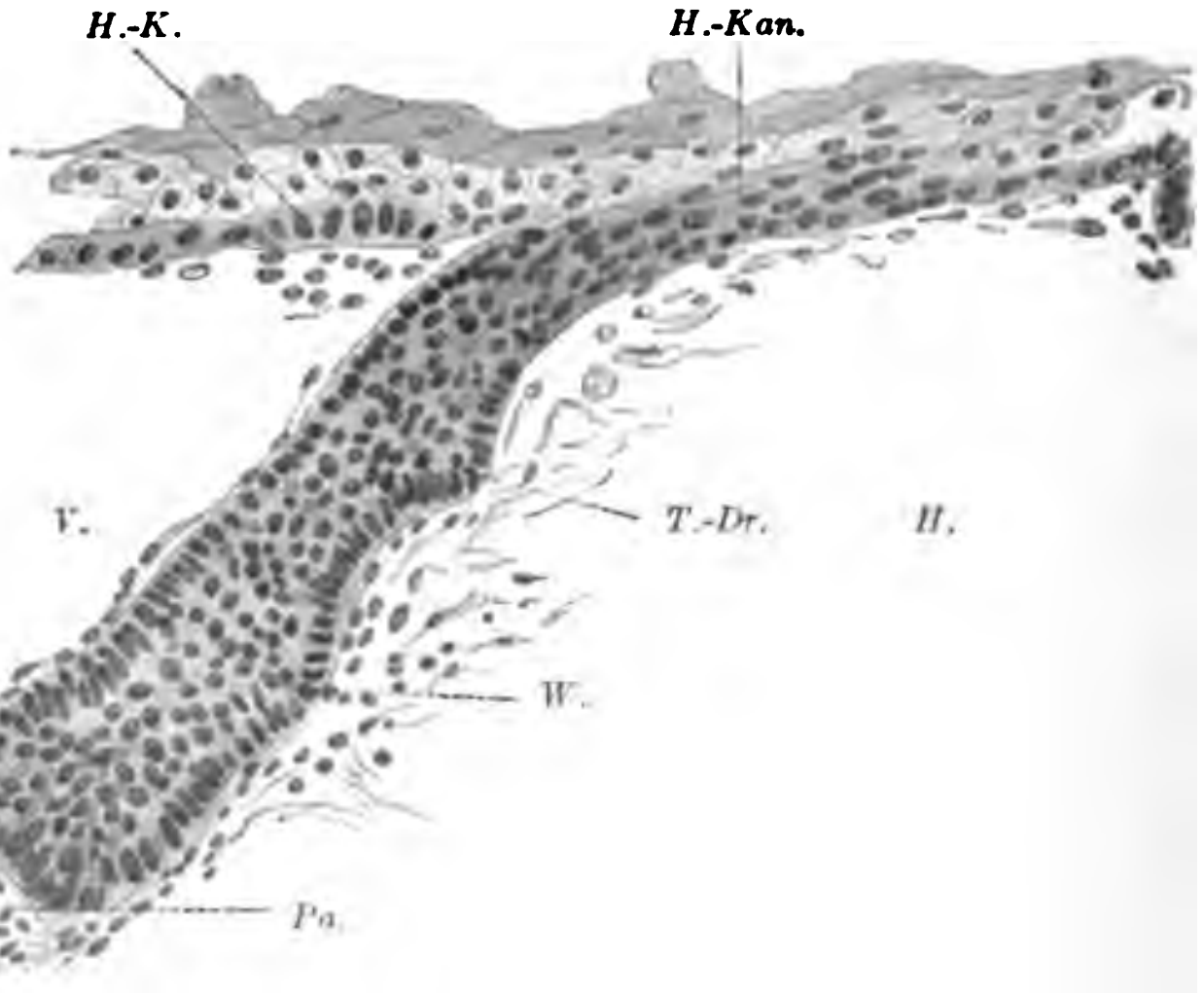

FIG. 207.—Hair papilla in a more advanced stage, transition into the bulb papilla. *Pa.*, anlage of papilla; *W.*, swelling; *T.-Dr.*, anlage of sebaceous gland; *H.-Kan.*, hair canal cells; *H.-K.*, tangential section of a neighboring hair germ. × 230. (After Stöhr: Lehrbuch der Histologie, Fig. 300; Entwicklung des menschlichen Wollhaares, Fig. 9.)

matrix converge, a roundish cavity (Fig. 206). The under surface of the hair papilla is flattened or even somewhat concave. The epidermis in front of the hair is unmodified and three-layered, consisting of periderm, stratum intermedium, and stratum cylindricum; the posterior surface consists of proliferated, flatter, and elongated cells (the hair-canal anlage), which in part already show a beginning cornification (Stöhr). The hair papilla is enclosed laterally within a layer of connective tissue with numerous cells. On the under surface this is continued into a mass of cells with perpendicularly arranged, concave nuclei, the concavity looking upwards, which are immediately adjacent to the matrix (connective-tissue *papilla*). All these peculiarities of the hair papilla may be more or less pronounced. Thus a very distinct swelling may occur on one which does not show any marked apical flattening; or on a very short epidermal papilla there may be a distinct connective-tissue one, or *vice versa.* Further, in these early stages there may be opposite the swelling a marked aggregation of nuclei, which is to be regarded as the anlage of the *musculus arrector pili* (Stöhr). The hair anlagen, almost two months old, on the brows and lips have not advanced beyond this stage when the formation of the anlagen of the general hair coat begins. Some similar structures (gland anlagen) are alone larger; these will be considered in connection with the perimammillary epithelial appendages.

In the further course of development the layers of the hair and its sheath begin to form (Fig. 208). The epithelial papilla grows longer and thicker below (the bulb-papilla stage, Stöhr). Its anterior surface abuts upon thin unaltered epidermis, while the posterior is continuous with the anlage of the hair canal, already recognizable in the two younger stages. This assumes the form of an elongated, partly cornified mass of flat cells, projecting from the under surface of the epidermis behind the hair. The epithelial papilla is still surrounded by a high columnar epithelium, which at two regions on the posterior surface, that of the sebaceous gland above and that of the hair swelling below, projects more markedly than formerly. The anlage of the sebaceous gland does not always lie exactly in the posterior surface of the hair; occasionally it lies more laterally and later may surround the entire periphery of the hair or come to be principally lateral or anterior to it. The specific fat formation begins at an early period in the central cells. The under surface of the epidermal papilla or bulb is at first only slightly concave for the reception of the connective-tissue papilla, but later (apparently very quickly, Stöhr) it becomes deeply concave. The high columnar cells which line the concavity, the matrix plate, become the source of an upwardly projecting, conical, pointed mass of cells (the *hair cone*), which extends upwards into the still rather irregularly arranged cell material in the interior of the follicle. The outer boundary of this cone is formed by a layer of cells (the anlage of Henle's sheath), which extends from the point where the outer surface of the follicle bends into the under surface to the summit of the cone. It is the first formed and outermost layer of the cone and arises from the most peripheral cells of the matrix plate; it also cornifies sooner than any of the other layers of the hair. The inner sheaths and the hair are formed later from the middle cells of the matrix plate. Above the apex of the hair cone the cells arrange themselves to form an axial column, which eventually comes into relation with hair canal cells abutting upon the superficial epidermis and indicates the path along which the hair sheaths, and with them the hair, must grow. The connective-tissue portions of the hair become more distinct. The concavity on the under surface of the bulb becomes filled by the large connective-tissue papilla, which consists of abundant, transversely arranged cells and which as yet shows no neck-like constriction. It seems to be covered by a very thin continuation of the vitreous layer and to be separated by this from the epithelium. From the richly cellular connective tissue of the hair follicle a denser homogeneous layer separates, especially in the region of the swelling; this is the *vitreous layer*. The *mus-*

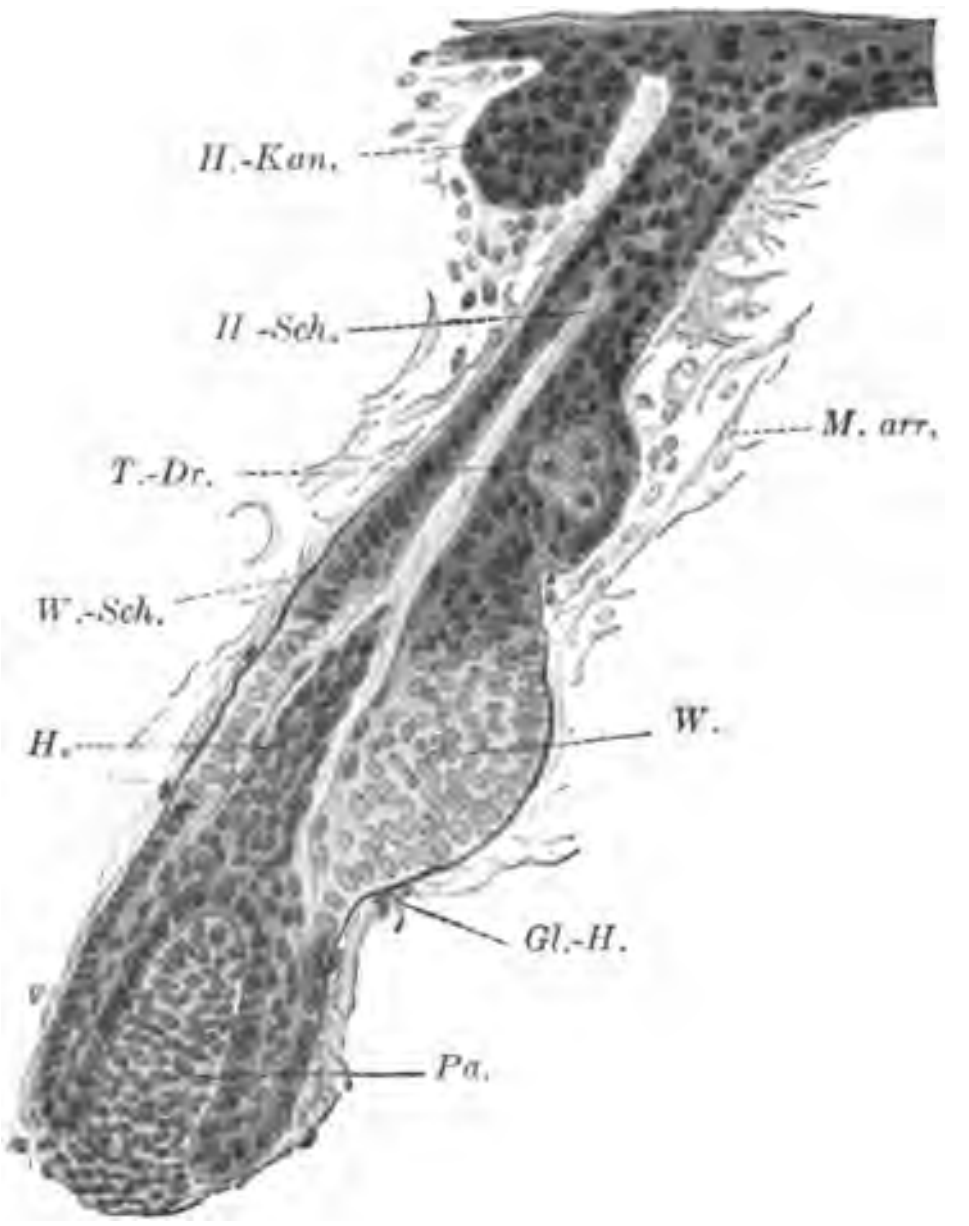

FIG. 208.—Sheath hair still near the bulb-papilla stage. *Pa.*, papilla; *Gl.-H.*, vitreous layer; *W.*, swelling; *M. arr.*, musculus arrector pili; *H.-Sch.*, inner root sheath; *T.-Dr.*, sebaceous gland; *W.-Sch.*, outer root sheath; *H.*, cells of the hair cone, not yet differentiated. × 230. (After Stöhr: Lehrbuch der Histologie, Fig. 302; Entwicklung des menschlichen Wollhaares, Fig. 14.)

culus arrector has at first the form of elongated cells, which show the oblique course from the bulb to the epidermis that is characteristic for the muscle; it becomes more distinct in this stage.

The follicle, gradually enlarging, grows obliquely downwards, and all its constituent parts undergo further development until it becomes the anlage of the actual hair. The sebaceous gland and the swelling assume noticeable dimensions and the connective-tissue papilla increases in height in correspondence with a deepening of the concavity of the matrix plate. While the bulb forces its way downwards the cornified hair sheaths which arise from it are pushed towards the surface.

As the last stage, that may be taken in which all constituents of the hair are laid down (the sheath hair, Stöhr). The hair elongates, especially in that part which lies below the hair bed. The upper part, with the swelling, sebaceous gland, and orifice, grows somewhat with the further development, but in general retains the same proportions. And, furthermore, it is the portion of the hair follicle intervening between the surface of the skin and the hair bed which remains unchanged throughout life, while the processes connected with hair change and the subsequent death of the hair take place only in the portions of the follicle below the hair bed. The *outer root sheath,* except in its lowest portion, from which the hair and its sheaths are developed, consists of two or three layers of cells, the innermost of which is flattened against the inner root sheath and later is united with it (Stöhr). The outer layer consists of more or less high columnar cells, which, in younger follicles, are all directed outwards and downwards (Fig. 209), probably in correspondence with the downwardly directed growth pressure of the follicle; later they become arranged perpendicularly to the axis of the hair. Towards the completion of development, when the hair change begins, the columnar cells become very high and their nuclei round or hemispherical with the flat surface directed outwards; they lie in the inner portion of the cells, while the outer portions, which rest upon the vitreous layer, are clear and unstainable. On the outer surface of these high columnar cells a homogeneous layer is secreted. The portions of this layer, at first separated, fuse together to form the *inner vitreous lamella* and unite intimately with the outer vitreous layer, which is formed by the innermost layer of the connective-tissue portion of the follicle. Later the two vitreous lamellæ become closely connected together. The columnar cells stand in small transverse grooves of the vitreous layer, these grooves corresponding in width with the cell bases and being readily recognizable in microscopic sections, in which the vitreous layer is easily separated from the follicle epithelium, as slight elevations between the rows of cylinder cells. The vitreous layer terminates at the swelling, and above its

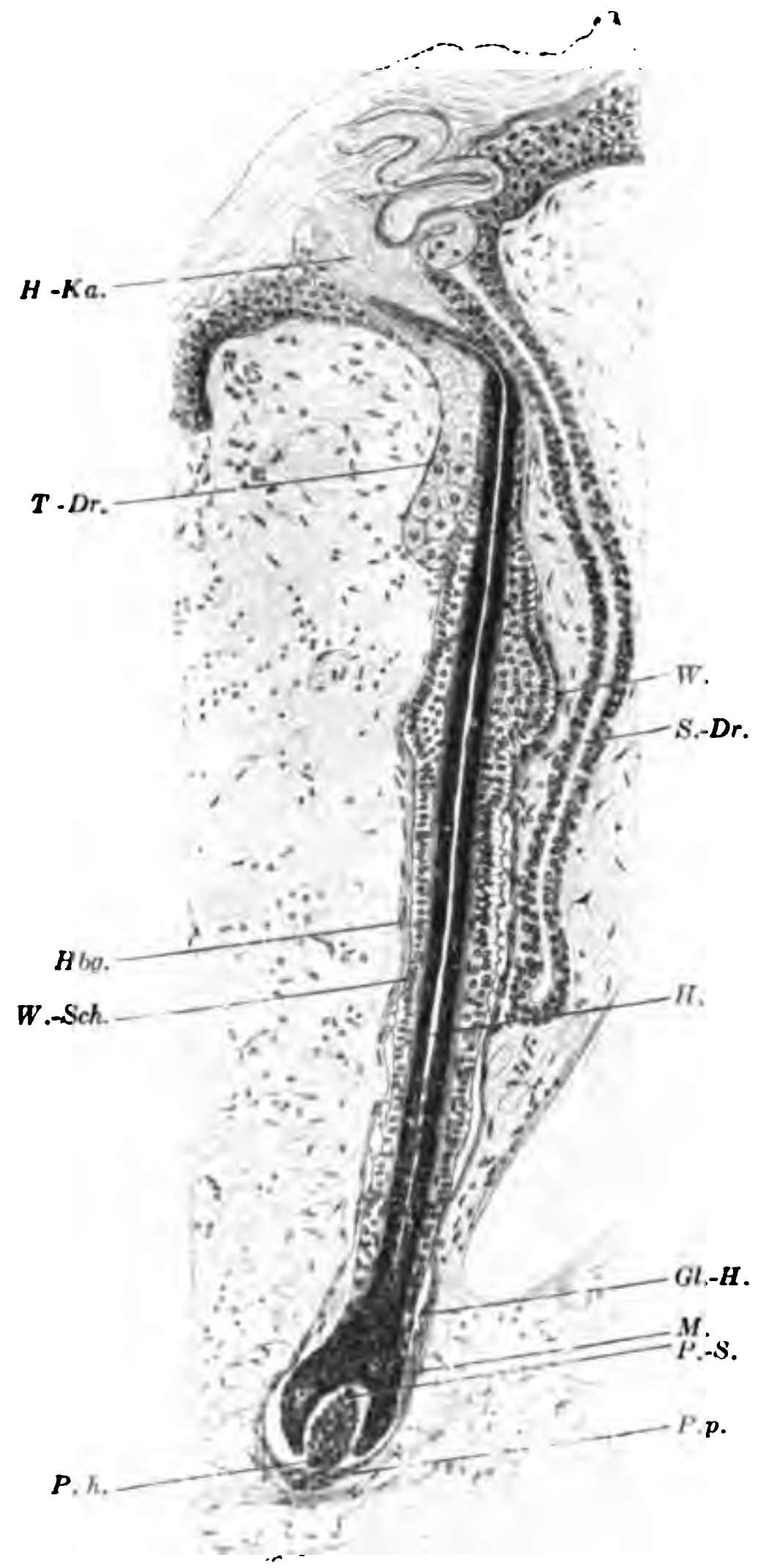

FIG. 209.—A completely formed lanugo hair, from the mammary region of an eight months male fetus. Partly schematic, reconstructed with the camera lucida from an oblique series of sections. *P.p.*, cushion of connective-tissue papilla; *P.h.*, neck of papilla; *P.-S.*, tip of papilla; *M.*, hair matrix; *Gl.-H.*, vitreous layer, for the most part separated from the outer root sheath; *H.*, shaft of hair; *W.-Sch.*, outer root sheath; *Hbg.*, connective-tissue portion of follicle; *S.-Dr.*, sudoriparous gland; *W.*, swelling; *T.-Dr.*, sebaceous gland; *H.-Ka.*, hair canal. *Black*, inner root sheath + cuticulæ. × 120.

upper edge an especially strong layer of elastic fibres lies close against the epithelium and extends upward as far as the sebaceous gland. In the swelling the epithelium becomes many-layered, more so on the anterior surface of the follicle than on the posterior, which, from the beginning, shows the strongest development of the swelling. At this point the arrector muscle, surrounded from below upwards with elastic fibres, is usually inserted. Above the swelling the epithelium again becomes thinner and its cells lower, and it is especially thin in the region of the sebaceous gland, at whose orifice the hair follicle has its smallest diameter (the isthmus). At this point the funnel of the follicle begins, not being formed by a depression from above, but by the cornification, accompanied by the formation of keratohyalin, of the central cells of the follicle and of the hair-canal cells, whereby a long streak of cornified cells, which extends far into the epidermis, is formed. This indicates the path which the hair will shortly take, and, after it has broken through, the funnel becomes usually much widened and its walls strongly cornified.

The lowermost part of the outer root sheath encloses the elements of growth for the hair. It has already been seen that in younger stages Henle's sheath could be followed down to the matrix and was the most external and at the same time the oldest of all the structures which arise from the matrix. It also cornifies the earliest and the most strongly of all the hair sheaths. Somewhere about the level of the connective-tissue papilla (according to Gavazzeni, 1908, even in the matrix cells) there is formed in it a ring of cells containing granules; the nuclei of these cells do not become smaller, as is nearly always the case in the stratum granulosum, and their granules differ from keratohyalin in both their chemical and staining reactions (staining with eosin and fuchsin).

It would seem that these granules, as also those of Huxley's layer and of the hair itself, are not keratohyalin, but a different chemical substance (*trichohyalin*, Vörner, 1903). The granules of Henle's layer became converted into elongated rods and soon disappear, the layer itself staining diffusely with eosin and becoming completely cornified.

Henle's layer covers all the central structures and extends to the region of the hair canal, where it breaks up and is perforated by the hair in its upward growth (Fig. 209).

Huxley's layer, the inner lamella of the inner root sheath, cannot be followed quite down to the matrix plate, although it is certain that it has its origin from a definite ring of matrix cells. In the lanugo hair it extends at first far beyond the tip of the connective-tissue papilla into the apparently undifferentiated mass of cells at the base of the follicle, and in later stages of development its trichohyalin-containing cells can be distinguished further down toward the matrix. Its granule cells extend far upward upon the shaft of the hair, which has formed in the meantime, and they then become cornified. It stands in intimate connection with the Henle layer, which has already become completely cornified, and between the cells of this layer those of Huxley's layer send processes containing granules.

According to Garcia (1891) the sheaths can be followed quite to the matrix plate in the head hairs of fetuses of eight to nine months, when the hairs have just attained their complete development. Of the forty to fifty cells which occur in a longitudinal section through the summit of the matrix, Henle's and Huxley's layers correspond to four to six cells on either side. When the hair, in its full strength, has broken through the inner root sheath, this terminates in a sharp edge surrounding the hair in a circular manner, at the level of the isthmus below the orifice of the sebaceous gland; at first it extends somewhat higher than this, as far up as the hair canal.

Beginning somewhat higher than Huxley's layer, there are formed from the more internal regions of the matrix the cuticle of the inner root sheath (the sheath cuticle) externally and the hair cuticle internally. These two cuticles arise from the four to six cell-rings of the matrix internal to those which form the inner root sheath. Their cells contain no granules (whether they are also destitute of granules in the adult condition is still uncertain), and they cornify probably before Huxley's layer, forming scales which in the sheath cuticle are small and directed obliquely inwards and downwards, while in the hair cuticle they are large and directed obliquely outwards and upwards; in the fully developed follicle the two sets of scales (imbrications) fit into one another. The sheath cuticle is almost inseparable from Huxley's sheath, and the hair cuticle, similarly, from the hair; and their imbrications apparently determine the equal ascent of the hair and the hair follicle, which their disappearance promptly disturbs (Von Ebner, 1876).

The hair itself arises from the large central portion of the matrix plate. It forms at first an acute cone-shaped structure, just as the sheaths do, and is covered by the cornified sheaths as with a cornucopia until it breaks through the torn sheaths in the vicinity of the hair canal. Gradually it becomes broader, and arises from the greater portion of the matrix. On the head (in the eighth to ninth fetal month) each hair arises from twenty-four to thirty of the cells seen in a greatest longitudinal section of the matrix plate (Garcia, 1891), and Stöhr's figures of the lanugo hairs show about the same number. The large roundish nuclei above the matrix gradually become elongated and the cells cornify without forming trichohyalin. The cornification begins deep down, the nuclei vanishing at the level of the junction of the lower and middle thirds of the follicle (head hairs, Garcia). Between the matrix cells of the hair branched *pigment cells* appear, which ascend into the hair and contribute pigment granules to its other cells. According to the most recent views they take their origin from the epithelial rather than from the connective-tissue cells (see p. 253). The diameter of the hair gradually diminishes as it grows away from the papilla, and its smallest diameter is reached with the completion of its cornification. But before it becomes hardened, the succulent hair mass is pressed, as in a mould, by the elastic compression of the sheaths. Henle's sheath is a stiff tube, which on account of its net-like structure (flat cells separated by meshes, very well shown by Günther, 1895, in his Fig. 202), may exercise an elastic pressure. In it the soft hair with its soft sheaths is compressed and moulded. The remaining sheaths form a softer cushion for the forming tube. After the cornification of Huxley's layer the hair with the cuticles and the inner root sheath forms a compact cylinder, which is pushed upwards by new formation at the base of the follicle. The inner part of the outer root sheath follows in the upward movement—the imbrications of the hair cuticle, firmly united to the hair, and those of the sheath cuticle, firmly adherent to the hair sheath, seeming by their interlocking to determine the regularity of this upward growth.

The epithelial hair follicle is enclosed in a layer of connective tissue, sharply marked off from the surrounding corium connective tissue, which is, in general, arranged horizontally. This connective-tissue sheath consists of an outer layer of longitudinal fibres and an inner transverse or circular layer. The inner layer secretes the outer vitreous layer, whose connection with the columnar cells of the follicle by means of the inner vitreous layer formed by their bases has already been described. Beneath the hair bulb, the *papilla* (papilla pili), which fills the spacious cavity of the hollow hair bulb, projects from the connective tissue. It projects from the mass of transversely arranged cells (the *papilla cushion*), which lie below the entrance into the hair bulb, and extends some distance upwards to form a papilla terminating above in a point (the tip of the papilla). At the lower border of the hair bulb, the papilla is constricted in a neck-like manner (papilla neck, Garcia).

The cells of the papilla are partly directed obliquely upward and partly are arranged transversely, as they are at their first appearance. They are distinguished from all other connective-tissue cells by their epithelial-like structure, being closely set cells with large, roundish or elongated, darkly staining nuclei.

The first-formed hairs have only a short life.

Even before birth the first hair change begins in the human species. This is total, compressed into a brief space of time, and associated with a change in the quality of the hairs.

Some hairs cease to grow even before they have broken through the surface of the skin, a condition which is often shown in later life by lanugo hairs (such as hairs of the face). In hair change the cessation of growth of the hair seems to begin externally and to proceed internally. The cells of Henle's layer and then those of Huxley's layer cease to proliferate and are carried upwards by the still growing hair by means of the interlocking of the imbrications. Then the matrix, the cuticles, and the hair itself cease their growth. The hair becomes cornified right to its tip and, probably because it is no longer compressed by Henle's layer at its lower end, this enlarges to form a brush-like structure, the hair being then known as a *bulb hair.* A cell mass, the bulb cushion (Garcia), is formed by the matrix and occupies the space left vacant by the hair. This is carried outwards rapidly, as if squeezed out from the tube formed by the outer root-sheath. The matrix and connective-tissue papilla pass outwards more slowly, and the outer cells of the outer root sheath lose their columnar form (Aubertin, 1896, in adult head hairs). A diminution seems to occur in the pressure which the growing hair exerts downwardly and which is at first greater than that exercised by the surrounding tissues; the pressure of the tissues is now alone active and the space left vacant is filled by their being forced inwards.

During the ascent of the hair and its follicle the connective-tissue investments of the follicle thicken, especially the circular fibrous and the outer vitreous layers. Perhaps these thickened layers exert a compression on the thinning lower part of the follicle, whereby the hair is forced outwards. But the thickening may also be regarded as a protection against the pressure of the surrounding tissue, or as the simple contraction of an overstretched membrane. Indeed, all mechanical theories are to be advanced with great caution (Stöhr), since in every step the growth of the hairs apparently follows old inherited paths which, like the phylogeny of the hair, are unfortunately poorly understood. All arrangements are naturally intelligible mechanically and explicable as strain and pressure conditions; but whether these mechanical explanations are correct is a question.

While the separated hair and the papilla are ascending the epithelial root cylinder between the two becomes thinner; it becomes composed of cubical indifferent cells and the connective-tissue papilla becomes smaller (diminishing at the most to about half its original size in section). When the papilla has reached its highest position, a new life begins in the root cylinder. It covers itself anew from above with new columnar cells, becomes thicker, and develops a new swelling-like outgrowth, which later applies itself to the old swelling (Garcia). Gradually a new hair papilla forms in this, the hair matrix producing first a new inner root sheath and then a new hair, just as on the first formation of the hair. As the new hair grows out, its matrix and papilla are forced downwards by the renewed growth, and the inner root sheath is broken through just below the orifice of the sebaceous gland. The tip of the hair pushes its way, frequently in a tortuous course, through the old follicle canal, and after a considerable enlargement of this the old hair, which projects considerably, eventually falls out, as the result of some mechanical cause. The new hair is no simple replacement of the old, but has a quite different character. While the hairs of the first generation are practically all alike, there begins to appear in the second generation the great difference between the head and body hairs, and this increases in generation after generation, until, at the beginning of puberty, the genital and axillary hairs begin to differ from the lanugo of the remaining portions of the body; the lanugo of the face gives place to the hairs of the beard, etc., in the male; and the apparently unaltered lanugo, as well as the head hairs, eyelashes, and eyebrows, assume a different type. In later years still more of the lanugo becomes transformed into strong body hairs (terminal hairs, Friedenthal, 1898). Each change of hair is at the same time a change in the character of the hair (type change, Unna, 1893). An accurate enumeration of the lanugo hairs on the human ear (Oshima, 1907) seems to show that the number of the fetal lanugo hairs is in places much greater than that of the lanugo of the adult.

The direction of the hairs is determined from the beginning. In the individual hairs it is recognizable in the hair-germ stage on account of the bilateral form of the germ, and in later stages it reveals itself by the hairs spreading out over the surface in the manner permanently determined for them (Blaschko) and not radially from some centres that arise. The same conditions have already been described as occurring in the development of the dermal ridges, which, in the same way, extend out over the surface of the skin from the regions of their first formation (the finger tips). With the completion of the hair formation the skin shows an arrangement of the hairs which is definite, unchangeable in any individual, and varying but slightly in different individuals, for the knowledge of which we are indebted to Eschricht (1837) and especially to Voigt (1857).

The latter regarded the direction of the hairs as the result and an indication of the mode of growth of the skin especially, but also, to a certain extent, of the underlying portions of the body. The general spiral arrangement of the lines of the larger hair streams indicated a spiral growth of the enlarging skin, such as is the rule in plants, a mode of growth which was thoroughly studied by Ohlert (1854–55) and later by Schwendener (1909), and was regarded as a peculiar law of growth for the animal body, the law of torsion, by Fischer (1886). The centres of the spirals are the hair whorls, around which the hairs arise at intervals and in curves which are regular even although they have not hitherto been expressed mathematically. Voigt pointed out that the hairs at the ends of a stream are further apart than they are near the whorl. A considerable number of constantly occurring hair centres have the form of whorls, from which the hairs diverge in spirals (the direction of the free hairs being towards the periphery, *diverging whorls*). The more important of these are:

1. The crown or vertex whorl, curving towards the right in more than half the cases, towards the left in about a third, and doubled in the remaining cases (curving to the right on the left side and towards the left on the right side), or, in rare cases, trebled.
2. A right and a left brow whorl.
3. A right and a left ear whorl.
4. A right and a left axillary whorl.
5. A right and a left lumbar whorl.
6. Occasionally one or frequently two whorls, right and left at the side of the body (often only on one side).
7. Hand and foot whorls.

In other regions the hairs converge from all directions to form *converging whorls*, the most constant of which are:

1. The frontal whorl, at the root of the nose or at the edge of the scalp, or in both places.
2. Lateral cervical whorls.
3. Elbow whorls.
4. Umbilical whorl.
5. Penial whorl.
6. Coccygeal whorl.

The hair lines meet one another at acute angles in *streams;* when they meet at right angles *crosses* are formed, such as the nasal cross, the hyoid cross, the pectoral cross, the abdominal cross, the penis cross, and the coccygeal cross in the middle line of the body; the brow crosses, the nape crosses, the supra-auricular crosses, and the lateral crosses, one on each side; and the shoulder crosses, the ulnar crosses, the carpal crosses, and the crural crosses on the extremities. Many are doubled, and very frequently one is absent on one side of the body.

The diverging whorls, according to Voigt, are regions of least growth, of comparative rest; the converging whorls correspond to especially great stretching of the skin, in regions where (either in the ontogeny or phylogeny) some organ projected from the body (Wiedersheim: penis, umbilicus, branchial clefts, and, in animals, horns), or where especially strong growth resulted from the pressure of adjacent parts (coccyx, elbow). The crosses are regions of relative rest, lying between forces acting from either side; the converging hair streams are regions which became stretched during growth.

Of the arrangement of the hairs in transverse rows, corresponding to the arrangement of the scutes in transverse girdles around the body and limbs of reptiles, and of the development of such rows, we have as yet no comprehensive investigation.

G. THE SUDORIPAROUS GLANDS.

The development of the sudoriparous glands begins on the finger tips (Blaschko, 1888), the palms of the hands, and soles of the feet (Grefberg, 1883) in the fourth month; according to Kölliker (1889) in the fifth month. It follows immediately upon the formation of the dermal ridges. Their anlagen resemble closely those of the hairs, except that they lack the close aggregations of cells in the corium, from which, in the case of the hairs, the papillæ are formed. The anlagen project downwards as solid flask-shaped rete papillæ, which, becoming long and slender, begin to become tortuous in the sixth month. In the seventh month a lumen begins to form in each, the beginning secretion producing intercellular clefts which later unite to form a continuous cavity. In the meantime the lower end, bending upon itself, forms the anlage of the coiled portion of the gland. The outer terminal portion of each gland forms its own lumen, which later unites with that of the glandular portion. The two-layered epithelium of the duct portion becomes transformed at its passage into the glandular portion into two distinct layers; the inner of these remains the large-celled secretory layer, while the outer becomes flattened and forms the epithelial muscular layer (Kölliker, 1889). The gland canal is then composed of an inner layer of cubical, or even higher, glandular cells, with large, round nuclei, and of an outer layer of flat muscle cells, whose nuclei are flattened and whose angles project between the cells of the inner layer; these cells form an outer investment of closely set parallel striæ around the gland. At the time of birth the sudoriparous glands, like the hairs, seem to be completely laid down, so far as their number is concerned.

In the hairless palms of the hands and soles of the feet it is certain that the sudoriparous glands arise from the surface epidermis, and in most of the other portions of the skin they seem to have a similar origin in man. In many places, however, a relation of the sudoriparous glands to the hair follicles, of general occurrence in animals, persists, the sudoriparous glands partly developing directly from the uppermost portions of the hair follicles (Wimpfheimer, 1907; Diem, 1907), or partly having at least a connection with its follicles at their mouths (Fig. 209).

The idea that the follicles and the sudoriparous glands belong to genetically single areas has been somewhat generally accepted; according to my observations the *hair disks* (not constant in their occurrence) also belong to these areas, each of which, with all its appendages (vessels, nerves, muscles) corresponds in its original form to a promammalian scute (scute area or hair area). According to this view the completely isolated sudoriparous glands of the palms and soles must each represent the remains of a hair area (Whipple). That in spite of an imperfect development of the hairs the sudoriparous glands may actually retain their proper places in the hair areas, I have been able to show in the sole of the foot of

Ornithorhynchus (Pinkus, 1905) where the paradoxical arrangement of a complex consisting of a sudoriparous gland behind, a simple hair follicle in the middle, and a hair disk anteriorly, can only be explained as a semicircular arrangement of the elements of the hair area, peculiar to *Ornithorhynchus,* and a disappearance of all the hairs with the exception of the middle one. A further small step in the reduction would leave nothing remaining but the sudoriparous gland. The connection of the sudoriparous gland with the hair follicle, regarded as merely a topographical relation by Maurer (1895), but by most authors (De Meijere, 1894; Eggeling, 1904) as genetic, has been demonstrated to be of the latter nature by the embryological observations of Stöhr's pupils, Wimpfheimer and Diem, who found that in the majority of the mammals examined the sudoriparous glands arise from the follicle epithelium and their orifices only later migrate to the surface epidermis. Usually the sudoriparous gland is formed, like the other appendages of the hair (sebaceous gland, swelling, muscle, hair disk), on its posterior surface. It begins to form even in the hair germ stage and becomes distinct in the papilla stage (although not visible in man). Its cell nuclei, in contrast to those of the columnar layer of the hair, are small (Eggeling); in contrast to the regular arrangement in the anlagen of the sebaceous glands they are irregular (in the mole); and the increase in the number of the connective-tissue cells, which usually begins early in the case of the hair germ, is wanting beneath them. Unfortunately, in man, as well as in many other mammals, the original mode of development of the sudoriparous glands cannot be observed. In these forms they appear to arise, for the most part, not from the follicle epithelium, but from the surface epidermis.

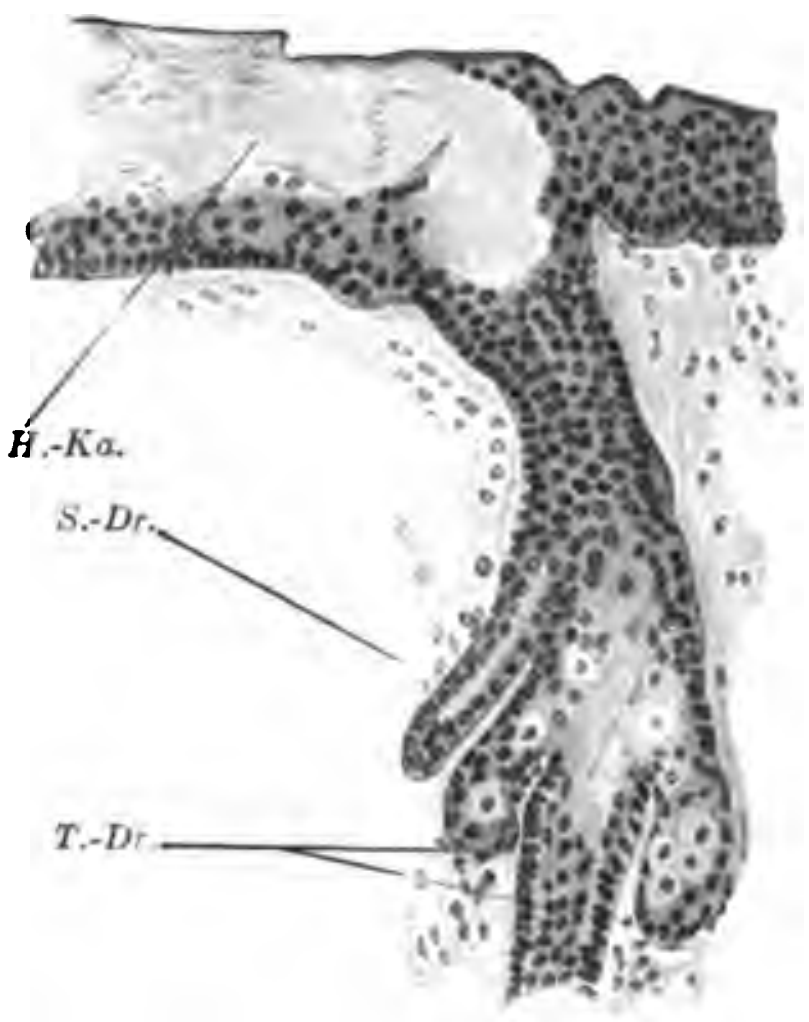

FIG. 210.—Human sudoriparous gland opening into a hair follicle, from the axillary region. *T.-Dr.*, sebaceous gland (the lower leader does not extend quite clearly enough to the gland); *S.-Dr.*, sudoriparous gland; *H.-Ka.*, hair canal. × 165. After Stöhr, from Diem: Entwicklung der Schweiss-drüsen an der behaarten Haut der Säugetiere, Fig. 7.

Departures from the usual structure of the sudoriparous glands occur in certain regions of the body. If we make exception of the eyelids with their specialized glands, these regions are the mammary and axillary regions, the inguinal folds with the scrotum, and the anus. In some cases the characteristic peculiarities are recognizable in the anlagen (region of the mammary gland), in others they first appear at puberty (the axillary glands).

A. The Glands of the Mammary Region.—The ventrolateral surfaces of the embryo at an early stage (6.25–6.75 mm., Keibel and Elze, 1908, "Normentafel," Nos. 21, 24, and 25, Figs. 11 and 12) are occupied by a broad diffuse area of high epithelium (*Schwalbe's milk streak*), that has a variable development, extending in some cases forward over the branchial arches and backwards, over the limb buds, until it reaches the tail; but in other cases it is of less extent and may be completely wanting. This

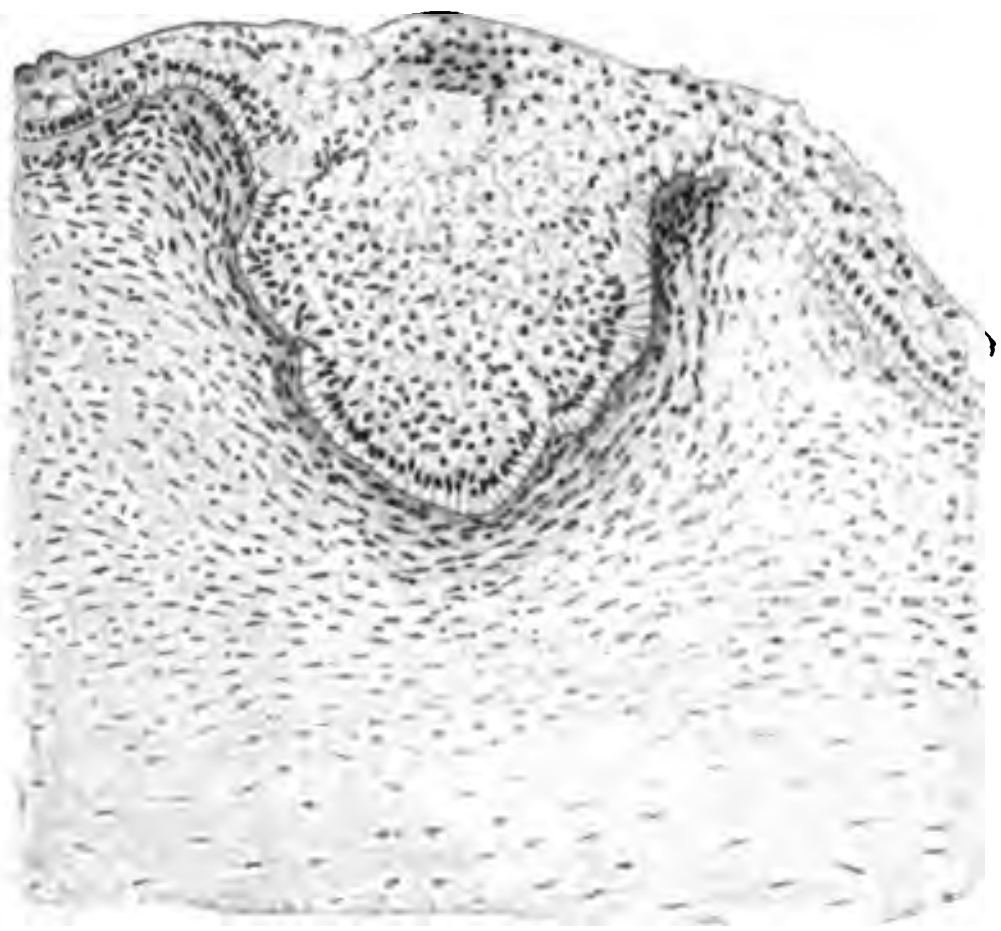

FIG. 211.—Section through the middle of the mammary anlage in a human fetus 8.5 cm. in length, male. × 120.

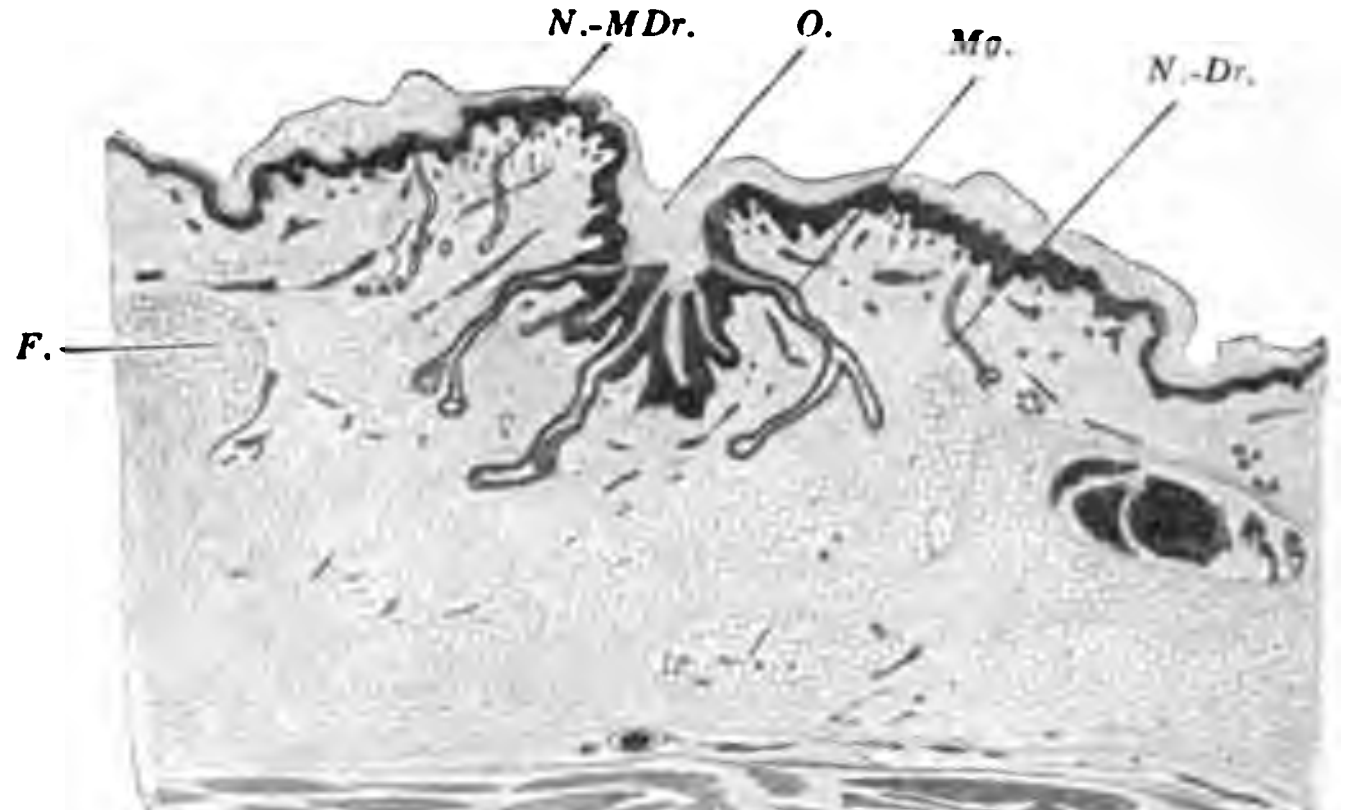

FIG. 212.—Section through the mammary gland of an eight months male fetus. *O.*, opening of the nipple; *Mg.*, milk duct; *N.-MDr.*, accessory milk glands (modified sudoriparous glands); *F.*, fat lobes. × 44.

epithelial thickening represents a formative region, which occurs also in the lower mammals and in birds (Heinrich Schmitt, 1898). In it, especially in its anterior portion, there develops in embryos 9 mm. in their greatest length ("Normentafel," Nos. 37–39) the *milk line* or *milk ridge* (O. Schultze, 1892), a band of thickened epithelium which is approximately lenticular in transverse section. The milk ridge is a structure comparable to the ganglionic or dental ridges, glandular anlagen appearing in it from place to place (O. Schultze, 1897; Brouha, 1905). In it the anlage of the mammary gland develops in man. Its primary epithelial anlage is, according to Rein (1882), (*a*) mound-shaped, consisting of an aggregation of epithelial cells projecting beyond the surface of the epidermis. Even in embryos with a greatest length of 9.5 mm. it has become (*b*) flatly lenticular, projecting somewhat beyond the epithelium both above and below, and being surrounded by an aggregation of corium cells (*nipple zone*). As the result of strong downward growth there is formed (*c*) the *papilla-shaped anlage* (Fig. 211), from which (*d*) the *bulb-shaped anlage* is formed as the lower parts increase in breadth while the more superficial portion becomes constricted in a neck-like manner. Later the milk ducts begin to sprout out, the anlage becoming polygonal and beset with short buds, (*e*) the period of bud formation. The development progresses slowly. Several simple papillæ project downwards into the connective tissue from the epithelial mass, and in the eighth month these become hollow and somewhat branched, their terminal portions being large (Fig. 212). The *primary epithelial bulb* from which these milk ducts arise becomes cornified in its central portion and a cavity forms in it, with which the lumina of the gland ducts become continuous (Fig. 212). When the hair development begins the region around the mammilla becomes conspicuous, on account of the absence of hairs on its surface, and forms the *nipple area* (O. Schultze, 1897).

In addition to the paired mammæ, supernumerary mammary glands are frequently developed. As a rule, they occur along a line from the anterior axillary fold to the inguinal region and make it seem as if several mammary glands had formed from the milk ridge; in other cases the hyperthelial structures are arranged irregularly in the mammary region.

The anlage of the mammary gland is usually compared with those of the sudoriparous glands. In the monotremes the glands of the mammary pouches in their functional condition differ from the ordinary sudoriparous glands only in their exceptional size (Gegenbaur, 1886, who, however, originally derived the mammary glands from sebaceous glands). Their genetic origin from sudoriparous glands is shown both by their development and by their comparative anatomy. Futhermore, in the adult condition their hidradenoid structure, represented by the two-layered epithelium of the ducts and the simple epithelium in the glandular alveoli, is an indication of their sudoriparous character. Their glandular alveoli, like those of the sudoriparous glands, produce their secretion without destruction of the cells (Bertkau, 1907) and are enclosed within a muscular network (Benda, 1893), which resembles the basket-like muscular network of the sudoriparous glands in the snout of many animals (Kormann, 1906). Their similarity to sudoriparous glands is rendered still greater by the fact that such glands, modified along the lines of the mammary glands, are formed in the neighborhood of these structures. Rein (1882) has already identified these as the anlage of the Montgomery's glands. Close around the nipple a number of sudoriparous glands is formed from a primary epithelial anlage similar to that of the mammary gland itself, but smaller; they resemble milk ducts by possessing peculiar outpouchings and wide lumina. Occasionally sebaceous glands and small hair anlagen are to be seen arising from the same epithelial papillæ, so that the hair areas, whose remains are represented by the accessory mammary glands (Eggeling, 1904), are in these cases not absolutely rudimentary (Brouha, 1905).

In rather early stages (embryos of 15.5 mm., Walter, 1902) some other epithelial appendages begin to develop around the mammary glands and were at first regarded as hyperthelial structures (accessory mammary glands, Hugo Schmidt, 1896). From another standpoint they were interpreted as marsupial anlagen (Walter), similar to the marsupial pouches which form around each mammary orifice in the opossum and fuse by their outer ends on the appearance of the marsupium (Bresslau, 1902). The number of these anlagen is occasionally very large in human embryos, reaching in some cases forty; they are scattered around the nipple and as far up as the axilla, and are usually smaller than the milk glands proper. Up to the present they have not been found in fetuses longer than 60 mm. To the same category perhaps belongs also the inguinal epidermal anlage, which has been described by Brugsch and Unger (1903).

In the same situation as these epithelial thickenings I have found around the mammary gland during my preparation for the present work, in a fetus of 85 mm., five epithelial structures, which must be regarded as something quite distinct. They are long tubules, surrounded by a thin longitudinal layer of connective tissue and formed of a two- to four-layered epithelium, which bounds a small lumen, not opening to the surface. Near the epidermis the most superficial portion of the tubule contains a small cavity, filled with cornified cells and surrounded by keratohyalin cells; it resembles Stöhr's hair canal, and neither opens to the exterior nor communicates with the lumen of the tubule. Below, the tubule, beyond the termination of its lumen, ends in an epithelial thickening, which sometimes forms a very regular, almost conical structure, covered externally by columnar cells (Fig. 213). These epithelial tubules are, with the exception of the mamma, the largest epithelial appendages of the fetus. At this stage the hair anlagen are still in the stage of the much shorter bulb papilla and the sudoriparous glands are not yet formed. I would assign the tubules without question to the mammary apparatus, were it not that similar, longer structures occurred in the nasal mucous membrane (Fig. 214). Possibly those in the pectoral region are a form of the further development of the epithelial structures of Schmidt (1896), mentioned above; probably they are forerunners or early stages of the Montgomery glands of the nipple area. That they are glands of the sudoriparous system is shown by their complete similarity to the ciliary sudoriparous glands, Moll's

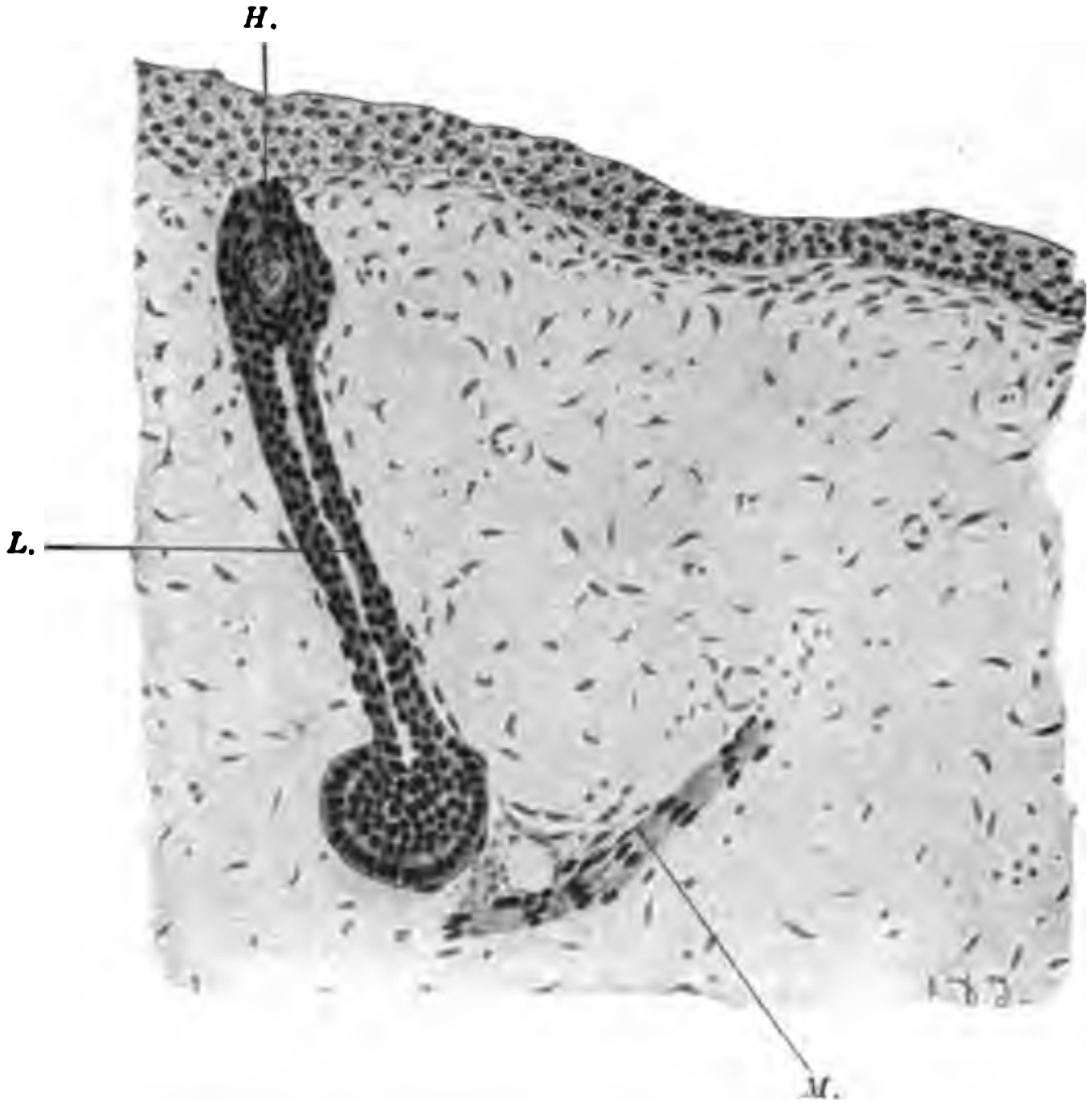

Fig. 213.—Epithelial appendage occurring near the mamma of the fetus from which Fig. 211 was taken. *H.*, cornified plug with keratohyalin; *L.*, lumen; *M.*, muscle (?). × 180.

glands, whose development from the epithelium of the hair follicles and occasional occurrence quite separated from these has been described by Ask (1908). The ciliary glands are, at this stage, however, younger, and only in fetuses of 170–250 mm. show the grade of development in these structures seen in 85 mm. fetuses. On the same side of the ciliary follicle as the sebaceous gland and swelling (the outer surface of the eyelid, but the posterior surface of the cilia) there extends above the level of the sebaceous gland a thin elongated epithelial cord, which, after passing over the sebaceous gland, bends downwards and is continued downwards for some distance parallel to the anlage of the cilium, to terminate in a pear-shaped enlargement composed of small rounded epithelial cells. Later a lumen appears at the orifice and another in the coiled portion of the gland. The connective-tissue cells around the anlagen of Moll's glands are not, however, increased in number.

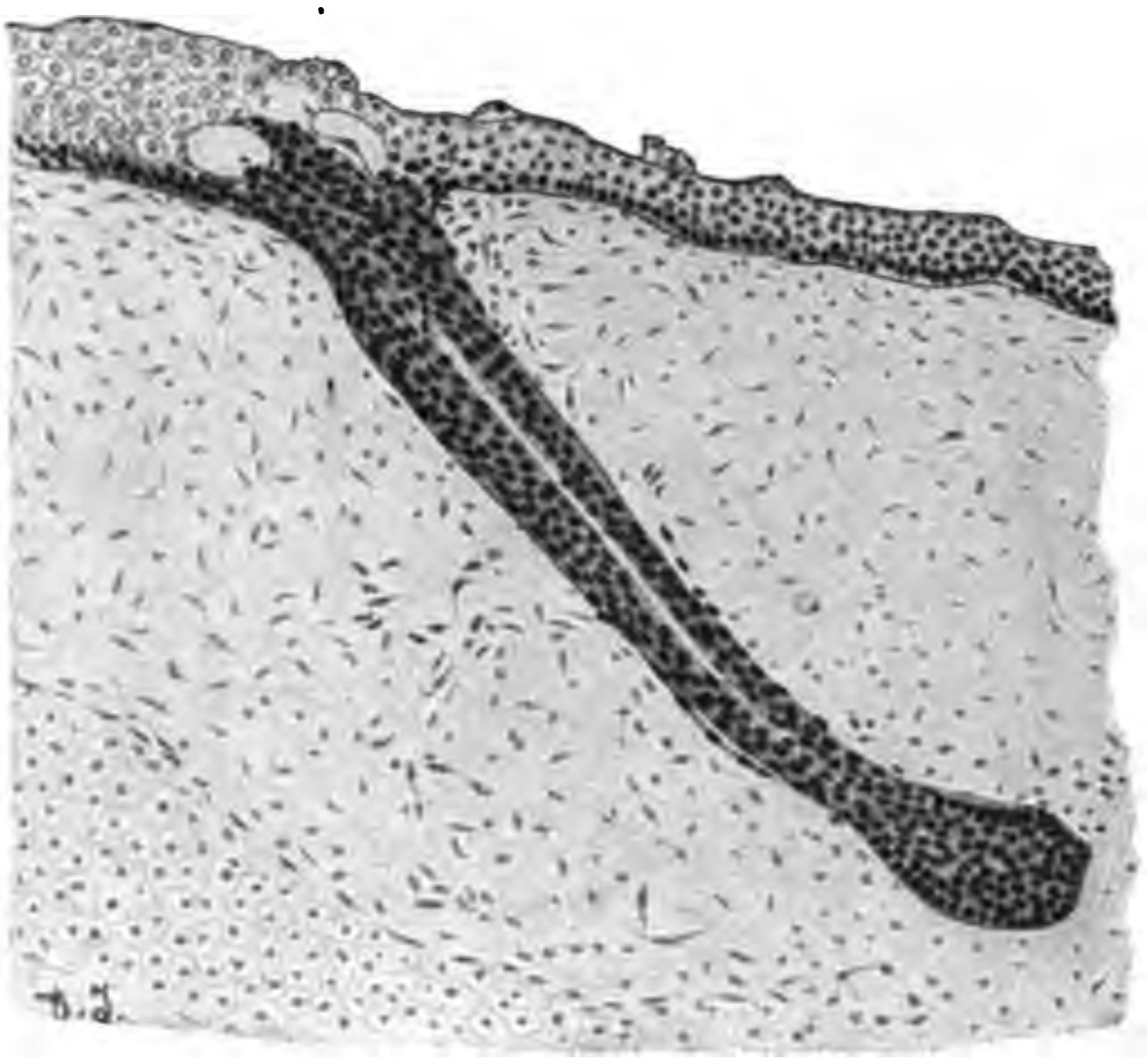

FIG. 214.—A similar epithelial structure from the nasal cavity of the same fetus. × 180.

B. The further development of the *axillary* glands begins in the ninth year in the female, but not until the time of puberty in the male (Lüneberg, 1902). They are formed from the ordinary sudoriparous glands of this region, a large number of which persist as small glands. The large axillary glands form a continuous layer of large, partly branched tubules, with an inner layer of high secreting cells and an outer single-layered muscle coat.

Nothing special is known concerning the development of the inguinal and scrotal glands.

H. THE NAILS.

At a very early period the place where the nail will be formed is recognizable on the dorsum of a terminal phalanx. The *primary nail field* (Kölliker, 1888), *primary nail base* (Zander, 1884), is recognizable in microscopic sections in fetuses of 4.5 cm., while in those of 2.75 cm. the region in which it will develop is quite undifferentiated (Okamura, 1900). Externally, the primary nail field somewhat later becomes evident on account of its smooth appearance and its firmer adherence to the subjacent tissue, as well as by its sharp anterior, posterior, and lateral boundaries. It extends from the finger tip almost to the articular process of the terminal phalanx—an extent which the fully formed nail also possesses and which is only relatively diminished transitorily during development by the increased growth of the ball of the finger. At its proximal (posterior) edge the epidermis invaginates to form a transverse, posteriorly convex pouch (the *root lamella* of Kölliker, the posterior nail fold of the adult), in which later the nail matrix is formed and whose roof is termed the *nail wall.* The epithelial invagination is the *posterior limiting furrow* (Kölliker), and laterally, on each side, it is continued into a lateral groove (the *lateral nail fold,* bounded externally by the lateral nail wall). Anteriorly the primary nail field abuts upon a shallower depression, which bounds it anteriorly in a transversely arched manner (the anterior groove, Unna; nail fringe, Kölliker). The primary nail field is flatly convex and is at first distinguished from the two- to three-layered skin of the fingers by its three- to four-layered epithelium with a germinal layer of cubical cells. Later on, also, the cells of the lowest layer of the nail field (the later nail bed) remain cubical, in contrast to the columnar cells of the nail fringe, the nail fold, and the germinal layer of the rest of the epidermis of the finger. In front of the nail fringe a transverse ridge appears, which is of great importance from the comparative standpoint. It corresponds to the region of the skin in which later the looser cornification, seen under the free edge of the nail and equivalent to the sole plate of the other mammals, is formed (Boas, 1894). In front of this ridge the epidermis is depressed to form a groove (the *distal limiting furrow,* Kölliker). The germinal layer in this region is formed of high columnar cells and the epithelium is five- to six-layered. In front of the sole plate the germinal layer becomes still more columnar.

The periderm and the stratum intermedium extend over the entire anlage, levelling its surface. The most superficial layer of very flat cells desquamates to a remarkable degree; and one finds, still adhering to the surface, cells swollen to a vesicular form and with small pyknotic, darkly staining nuclei (for a description of these cells see especially Zander, 1884; Kölliker, vesicular cells; Okamura; for those of the chick embryo, Rosenstadt, 1897).

In the course of further development the region of the sole plate becomes higher and eight- to ten-layered, and the cells of the nail field become flat, so that by its cell form alone the dorsal surface of the terminal phalanx can be readily distinguished from the volar surface, the germinal layer of which remains columnar. Only in the neighborhood of the nail wall, and, later, still further proximally also large vesicular, round cells persist at the surface, to a greater extent on the toes than on the fingers. The flat periderm cells, beginning at the nail fringe, fuse to form a tough superficial layer, and between them and the cubical germinal layer there lie distally several layers of prickle cells and proximally, at the nail fold, an area of pale vesicular cells (Zander's limiting layer). These vesicular cells remain large until much later on the toes, but on the fingers they become flatter, probably in correspondence with the greater general flattening of the anlagen of the finger nails.

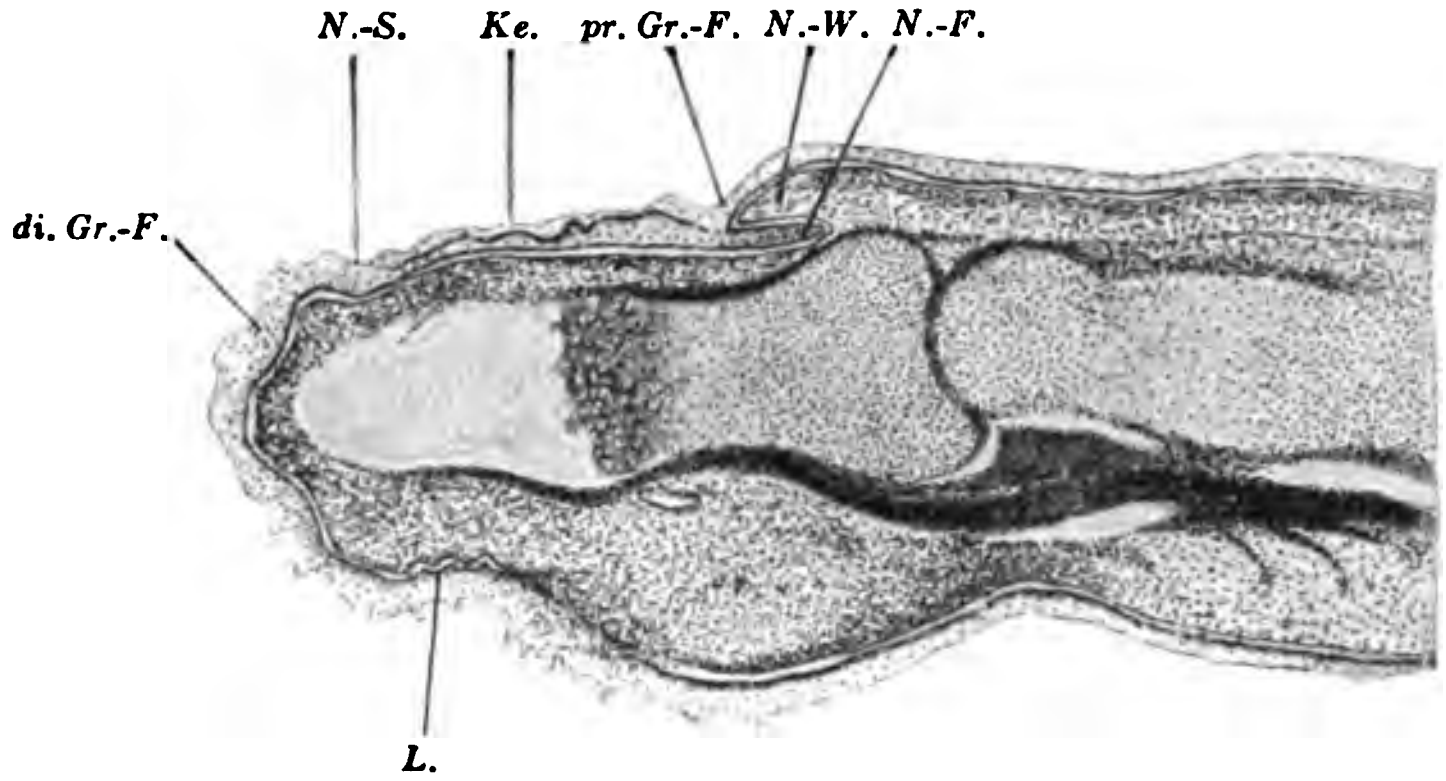

FIG. 215.—Median longitudinal section through the index finger of a human fetus of 8.5 cm. *N.-F.*, nail fold; *N.-W.*, nail wall; *pr. Gr.-F.*, proximal limiting furrow; *Ke.*, keratohyalin layer; *N.-S.*, nail fringe; *di. Gr.-F.*, distal limiting furrow; *L.*, commencing dermal-ridge formation. × 44.

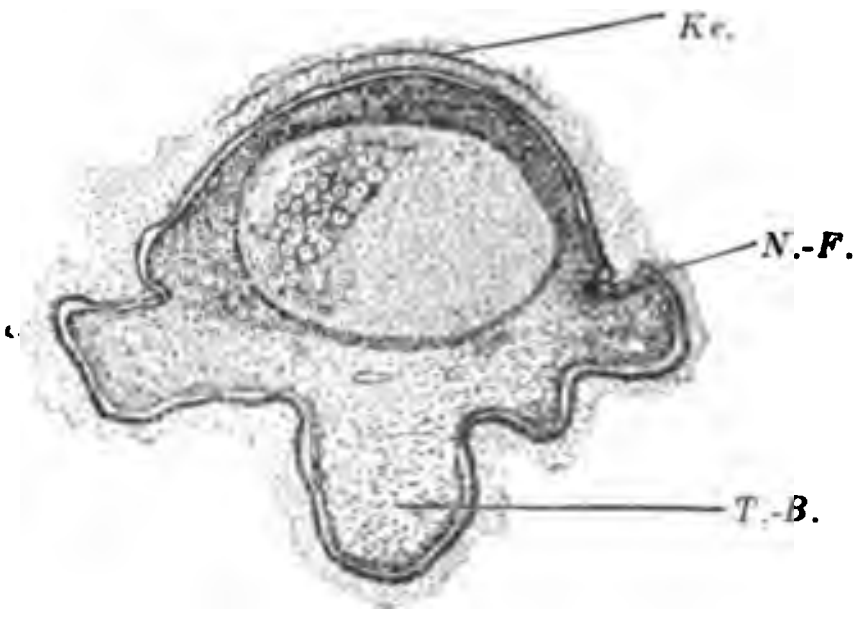

FIG. 216.—Transverse section through the terminal phalanx of another finger of the same fetus from which Fig. 215 is taken. The basal cell layer is cubical dorsally, columnar volarly. *N. F.*, lateral nail fold; *Ke.*, keratohyalin layer; *T.-B.*, touch ball. × 44.

Below Zander's limiting layer there is formed from the uppermost portions of the stratum intermedium, in somewhat larger embryos (10 cm., Zander; 9.3 cm., Kölliker; 8.5 cm., according to my own observations), a stout layer with abundant keratohyalin granules, which are partly large and roundish and partly quite fine and dust-like. Beneath this granule layer, whose keratohyalin nature was first determined by Pollitzer (1889), there lies a layer of pale vesicular cells, which also, especially at the cell peripheries, contain granules similar to those of the superjacent layer. These three layers form Unna's eponychium (1883), and the nail itself is formed from them according to

Kölliker, while according to Zander it is formed from the limiting layer, which is continually reinforced from the subjacent keratohyalin layers. The eponychium with its granule layer represents, according to Zander, only a precocious cornification, of the same type as that which occurs in the epidermis over the whole body at a later stage, when the granule layer, at the first sign of cornification, forms from the layer of prickle cells. This kind of cornification is found in such early fetal stages not only in the nail anlagen, but in all places where large appendage structures of the skin are being formed. It occurs also at the openings of the peculiar long epithelial appendages to be found in the nasal mucous membrane and around the mammary glands, and it occurs in slightly later stages in the development of the hairs, in the anlagen of the hair canals. It appears to be merely an indication of increased formative force in the epidermis. This layer of actual cornification, already similar to the later cornification, cannot, however, be directly identified with the periderm (eponychium). This is an actual horn layer, which remains partly retained throughout the rest of life (as the fringe at the proximal edge of the nail; see below). Okamura (1900) is correct when he regards as the periderm merely the outermost layer of desquamating cells, which lies over the keratohyalin layer, for we have already seen, in the consideration of the general skin, that the periderm in man is not a special layer, but merely the outermost layer of the quite young epidermis, which in the later development of the skin is permanently cast off.

The nail itself is formed from the region of the nail fold, quite without keratohyalin formation, in the manner described by Unna (1883) and confirmed by Okamura (1900) and Apolant (1901). The actual nail formation begins at the posterior part of the nail field, under the eponychium, as a layer of cornified cells. It begins in the fifth month (Unna), in fetuses 17 cm. in length, the first indications of its cells being visible in those of 16 cm. (Okamura, 1900). These cells lie at the entrance of the nail fold, at the level of the distal end of the nail wall. They present fine granulations, which do not take the stains which color keratohyalin, but stain with picric acid, swell in strong alkali, and are insoluble in all ordinary reagents such as water, alcohol, xylol, chloroform, ammonia, acetic, hydrochloric, and nitric acid, alkalies, and digestive ferments; therefore they cannot be keratohyalin. They have been termed by Ranvier *onychogenous* substance; but they neither represent a special substance (onychin), nor are they really granules, but probably nothing but the cross sections of fibrillæ. They consist of *keratin* and are the cross sections of *keratin* fibrils which occur in the nail cells (Unna, Apolant).

The cornification takes place, without being accompanied with a formation of keratohyalin, in the cells of the nail matrix, which extends from the posterior (proximal) margin of the fold to the anterior (distal) border of the lunula. The cells flatten and become converted into platelets, which compose the solid substance of the nail. The formative region for this reaches, with advancing development, from the original point to the deepest part of the posterior nail fold, and anteriorly to the anterior border of the lunula. Over this area the nail is formed and pushed forward from the beginning, just as it is throughout the whole of later life. The newly formed nails are for some time completely covered by eponychium, but later this is thrown off and the surface of the nail is exposed. Nevertheless a portion of the eponychium persists throughout life as a small membrane resting upon the proximal end of the nail; this grows forward with the nail and sooner or later desquamates at a distance of from 1–3 mm. from the posterior nail wall. The anterior edge of the nail is at first very thin and projects in older fetuses and after birth at the anterior end of the phalanx as a delicate membrane, but it is very quickly removed by the accidents of extra-uterine life (washing, movements) (Unna). The nail then grows, becoming gradually stronger, throughout the rest of life continuously, unless interrupted by some pathlogical condition. The portion of the skin on which the nail rests in front of the lunula takes no part whatever in the formation. Its rete papillæ, which form at the same time as the rete papillæ and ridges of other regions, produce the longitudinal ridges of the nail.

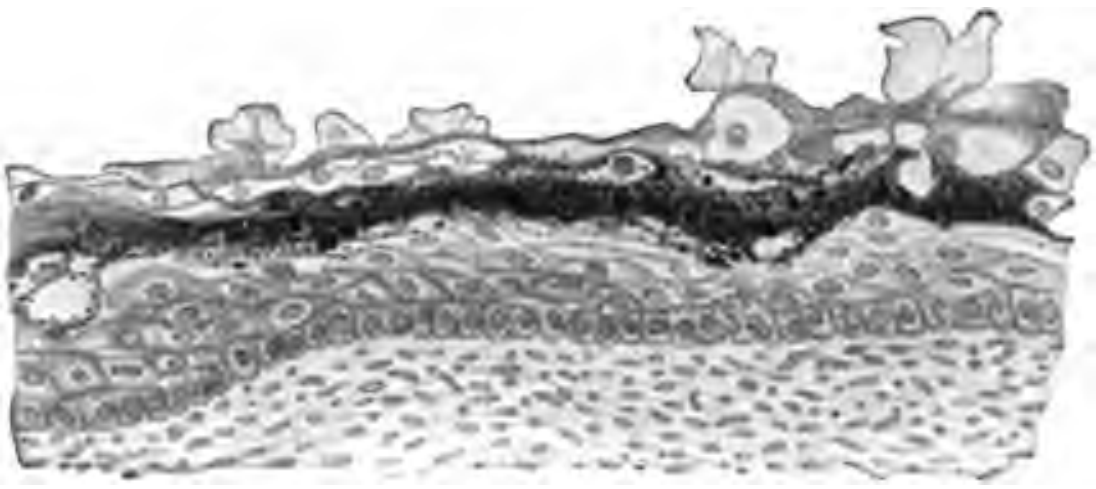

FIG. 217.—Longitudinal section through the keratohyalin layer of the fetal nail bed, anterior part. From a human fetus of 8.5 cm. (see Fig. 215). × 380.

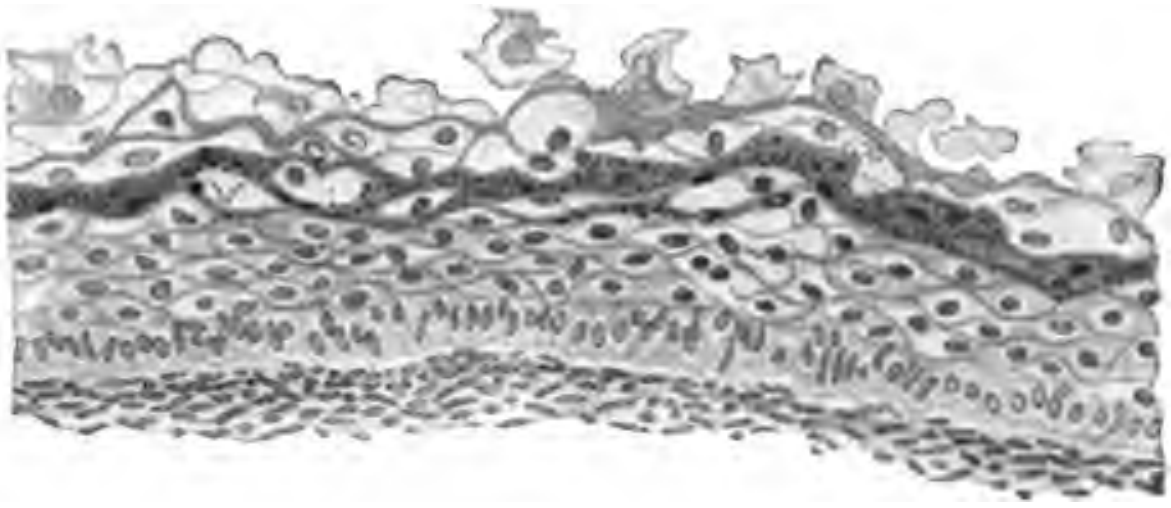

FIG. 218.—Transverse section through the keratohyalin layer of the nail bed, posterior part. From a human fetus of 8.5 cm. (see Fig. 216). × 380.

BIBLIOGRAPHY.

Adachi, B.: Hautpigment beim Menschen und beim Affen, Anatom. Anzeiger, vol. xxi, 1902, p. 16.

Apolant: Ueber den Verhornungsprozess, Arch. f. mikr. Anat., vol. lvii, 1901, p. 766.

Arcangeli, A.: Einige histologische Beobachtungen über das Deckepithel des Oesophagus beim Meerschweinchen (mit besonderer Berücksichtigung des Keratinohyalins), Monatsh. f. prakt. Dermatol., vol. xlvii, 1908, p. 297.

Ask, F.: Ueber die Entwicklung der Lidränder, der Tränenkarunkel und der Nickhaut beim Menschen, nebst Bemerkungen zur Entwicklung der Tränenableitungswege, Anat. Hefte, No. 109, vol. xxxvi, part ii, 1908, p. 189.

Aubertin, G.: Das Vorkommen von Kolbenhaaren und die Veränderungen derselben beim Haarwiederersatz, Arch. f. mikr. Anat., vol. xlvii, 1896, p. 472.

Beard, J.: The Birth-Period of Trichosurus vulpecula, Zoöl. Jahrb., vol. xi, 1908.

Benda, C.: Das Verhältnis der Milchdrüse zu den Hautdrüsen, Dermat. Zeitschr., vol. i, 1893.

Bertkau, F.: Ein Beitrag zur Anatomie und Physiologie der Milchdrüse, Anat. Anz., vol. xxx, 1907, p. 161.

Björkenheim, E. A.: Zur Kenntnis des Epithels im Uterovaginalkanal des Weibes, Anat. Anzeiger, vol. xxviii, 1906, p. 447.

Bizzozero: Münchener med. Wochenschr., 1908.

Blaschko, A.: Beiträge zur Anatomie der Oberhaut, Arch. f. mikr. Anat., vol. xxx, 1888, p. 495.

Boas, J. E. V.: Zur Morphologie der Wirbeltierkralle, Morph. Jahrb., vol. xxi, 1894, p. 281.

Bolk, L.: Ueber die segmentale Anordnung der Melanoblasten bei jungen Teleostieren, Verh. d. Anat. Gesellsch., Berlin, 1908, p. 135.

Bonnet, R.: Haarspiralen und Haarspindeln, Morph. Jahrb., vol. xi, 1886, p. 220.

Bresslau, E.: Beiträge zur Entwicklungsgeschichte der Mammarorgane bei den Beuteltieren, Zeitschr. f. Morphol. u. Anthropologie, vol. iv, No. 2, 1902.

Brouha: Sur la bande et la crête mammaires et sur les prétendues ébauches hyperthéliales chez l'homme et le murin, Anat. Anzeiger, vol. xxvii, 1905, p. 462.
Sur la signification morphologique de la mamelle, Anat. Anzeiger, vol. xxvii, 1905, p. 311.

Brugsch, Th., and Unger, E.: Ein warzenförmiges Gebilde der vorderen Bauchwand bei einen menschlichen Embryo von 4½ cm. Scheitelsteisslänge, Anat. Anzeiger, vol. xxiii, 1903, p. 216.

Brunner: Ueber Glycogen in der gesunden und kranken Haut, Deutsche Dermatol. Gesellsch., Bern, 1906.

Burkard, O.: Ueber die Hautspaltbarkeit menschlicher Embryonen, Arch. f. Anat. u. Physiol., Anat. Abth., 1903, p. 13.

Buschke: Notiz zur Behandlung des Vitiligo mit Licht, Mediz. Klin., No. 33, 1907.

Buschke and Mulzer: Weitere Beobachtungen über Lichtpigment, Berlin klin. Wochenschr., No. 49, 1907.

Buzzi: Keratohyalin und Eleïdin, Monatsh. f. prakt. Dermatol., vol. viii, 1889.
Ueber Eleïdin, Monatsh. f. prakt. Dermatol., vol. xxiii, 1896.

Cedercreutz: Ueber die Verhornung der Epidermis beim menschlichen Embryo, Arch. f. Dermatol. u. Syphil., vol. lxxxiv, 1907, p. 172.

Charpy, A.: Les plis de la peau, Arch. méd. de Toulouse, Ref. Zentralbl. f. norm. Anat., 1905, p. 335.

Ciliano, P.: Eleïdin, Monatsh. prakt. Dermatol., vol. xlvi, 1908, p. 435.

Cone, Claribel: Zur Kenntnis der Zellveränderungen in der normalen und pathologischen Epidermis des Menschen, Frankfurter Zeitschr. f. Pathol., 1907, p. 37.

Czajewicz: Mikroskopische Untersuchungen über die Textur, Entwicklung, Rückbildung und Lebensfähigkeit des Fettgewebes, Arch. f. Anat. u. Physiol., 1866, p. 289.

Diem, F.: Beiträge zur Entwicklung der Schweissdrüsen an der behaarten Haut der Säugetiere, Inaug. Dissert., Würzburg, 1907.

Dreysel, M.: Pigment und osmierbare Substanzen in der menschlichen Haut, Verh. d. V. Deutschen Dermatologen-Kongresses, 1895.

Dreysel, M., and Oppler, P.: Beiträge zur Kenntnis des Eleïdins in normaler und pathologisch veränderter Haut, Arch. f. Dermatol. u. Syphil., vol. xxx, 1895.

Von Ebner, V.: Mikroskopische Studien über Wachstum und Wechsel der Haare, Sitz. Ber. d. K. Akad. d. Wiss. Wien., vol. lxxiv, 1876.

Eggeling, H.: Ueber die Stellung der Milchdrüse zu den übrigen Hautdrüsen, Semon's Forschungsreise, Jena, 1895.

Ueber ein wichtiges Stadium in der Entwicklungsgeschichte der menschlichen Brustdrüse, Anat. Anzeiger, vol. xxiv, 1904, p. 595.

Ehrmann, S.: Das melanotische Pigment und die pigmentbildenden Zellen des Menschen und der Wirbeltiere in ihrer Entwicklung, nebst Bemerkungen über Blutbildung und Haarwechsel, Bibliotheca medica, vol. ii, part vi, 1896.

Ernst, P.: Studien über normale Verhornung mit Hilfe der Gram'schen Methode, Arch. f. mikr. Anat., vol. xlvii, 1896, p. 683.

Eschricht: Müller's Arch. f. Anat. u. Physiol., 1837 (cited by Voigt).

Evatt, J. E.: The Development and Evolution of the "Papillary" Ridges and Patterns on the Volar Surface of the Hand, Journ. Anat. and Physiol., vol. xli, 1907, p. 66.

Fick, J.: Ueber metachromatische Färbung des Keratohyalins durch Cresylechtviolett, Centralbl. f. allgemein. Pathol., 1902, p. 987.

Fischer, E.: Das Drehungsgesetz bei dem Wachstum der Organismen, Strassburg, published by the author, 1886.

Flemming: Centralbl. f. d. med. Wissensch., July, 1870.

Beobachtungen über Fettgewebe, Arch. f. mikrosk. Anat., vol. xii, 1876, p. 434.

Ueber die Entwicklung der Fettzellen und des Fettgewebes, Arch. f. Anat. u. Physiol., 1879.

Frédéric: Zur Kenntnis der Hautfarbe der Neger, Zeitschr. f. Morphol. u. Anthropol., vol. ix, 1905, p. 41.

Friedenthal, H.: Beiträge zur Naturgeschichte des Menschen (Lief. I, Das Wollhaarkleid des Menschen; Lief. II, Das Dauerhaarkleid des Menschen; Lief. IV, Entwicklung, Bau und Entstehung der Haare), 1908 (with a most complete bibliography).

Gage, S. H.: Glycogen in a 56 Days Human Embryo and in Pig Embryos of 7–10 mm., Amer. Journ. Anat., vol. v; Proc. Assoc. Amer. Anat., 1906, p. xiii–xv.

Garcia, S. A.: Beiträge zur Kenntnis des Haarwechsels bei menschlichen Embryonen und Neugebornen, Morph. Arbeiten, vol. i, part ii, 1891, p. 136.

Gavazzeni, G. A.: Trichohyalin, Monatsh. f. prakt. Dermatol., vol. xlvii, 1908, p. 229.

Gegenbaur: Zur Morphologie des Nagels, Morph. Jahrb., vol. x, 1885, p. 465 (cited by Unna, 1889).

Gemmil: Notes on the Origin of Elastic Fibre in Tendon, Journ. Anat. and Physiol., vol. xl, 1906, p. 397.

Grefberg, W.: Die Haut und deren Drüsen in ihrer Entwicklung, Mitth. a. d. embryol. Institut zu Wien, vol. ii, part iii, 1883, p. 126 (cited by Blaschko).

Grimm: Pigment in der Haut, Dermatol. Zeitschr., vol. ii, part iv, 1895.

Grosser, O.: Die Metamerie der Haut, Sammelreferat, Centralbl. f. die Grenzgebiete der Med. u. Chir., vol. vii, Nos. 1, *et seq.*, 1904.

Grosser, O., and **Frölich, A.**: Beiträge zur Kenntnis der Dermatome der menschlichen Rumpfhaut, Morph. Jahrb., vol. xxx, 1902.

Grund: Experimentelle Beiträge zur Genese des Epidermispigments, Ziegler's Beiträge, Suppl. 7, 1905.

Gunther, M.: Haarknopf und innere Wurzgelscheide des Säugetierhaares, Inaug. Dissert., Berlin, 1895.

Head, H.: Die Sensibilitätsstörungen der Haut bei Visceralkrankungen, edited by Seiffer, Berlin, 1898.

Heidenhain, M.: Ueber die gegenseitige Entsprechung von Epidermis- und Coriumleisten an der Beugefläche von Hand und Fuss beim Affen und Menschen, Anat. Hefte, No. 91, 1906, p. 419.

Hirschland: Beiträge zur ersten Entwicklung der Mammarorgane beim Menschen (Embryo von 4 mm.), Anat. Hefte, vol. xi, 1898.

Ide, M.: Nouvelles observations sur les cellules épithéliales, La Cellule, vol. v, 1889, p. 319 (abstr. in Monatsh. f. prakt. Dermatol., vol. ix, 1890, p. 550).

Jadassohn: Ueber Pityriasis rubra und ihre Beziehungen zur Tuberculose, nebst Bemerkungen über Pigment verschleppung aus der Haut, Arch. f. Dermatol. u. Syphil., 1892.

Jarisch: Ueber die Bildung des Pigments in den Oberhautzellen, Arch. f. Dermatol. u. Syphil., vol. xxiv, 1892.

Jores, L.: Ueber die feineren Vorgänge bei der Bildung und Wiederbildung des elastischen Bindegewebes, Ziegler's Beiträge, vol. xli, part i, 1907.

Kallius, E.: Ein Fall von Milchleiste bei einem menschlichen Embryo, Anat. Hefte, vol. viii, 1897.

Keibel, F., and **Elze, C.**: Normentafel zur Entwicklungsgeschichte des Menschen, Jena, 1908.

Kidd, W.: On the Imbrication of the Papillary Ridges in Man, Journ. of Anat. and Physiol., vol. xxxix, 1905, p. 413.

The Papillary Ridges and the Papillary Layer of the Corium in the Mammalian Hand and Foot, Journ. of Anat. and Physiol., vol. xli, 1907, p. 35.

Kölliker, A. von: Die Entwicklung des menschlichen Nagels, Zeitschr. f. wiss. Zool., vol. xlvii, 1888 (cited by Unna).

Handbuch der Gewebelehre des Menschen, vol. i, 1889.

Kolosoff, G., and **Pankul, E.**: Versuch einer mathematischen Theorie der Hautleistenfiguren der Primaten-Palma und -Planta, Morphol. Jahrb., vol. xxxv; also Centralbl. f. norm. Anat., 1906, p. 319.

Kormann, B.: Ueber die Modifikation der Haut und die subkutanen Drüsen in der Umgebung der Mund- und Nasenöffnungen, die Formationes parorales und paranaricæ der Haussäugetiere, Anat. Anzeiger, vol. xxix, 1906, p. 113.

Krause, W.: Die Entwicklung der Haut und ihrer Nebenorgane, Handb. d. vergleich. u. experiment. Entwicklungsgesch. der Wirbeltiere, herausg. von O. Hertwig, vol. ii, 1902.

Krauss, F.: Der Zusammenhang zwischen Epidermis und Cutis bei Sauriern und Krokodilen, Arch. f. mikr. Anat., vol. lxvii, 1906, p. 313.

Kromayer: Die Parenchymhaut und ihre Erkrankungen, Arch. f. Entwicklungsmech. der Organe, 1899, p. 253.

Die Desmoplasie der Epithelzellen in der menschlichen Haut, Monatsh. f. prakt. Dermatol., vol. xli, 1905, p. 477.

Langer, K.: Zur Anatomie und Physiologie der Haut, I. Ueber die Spaltbarkeit der Cutis, Sitzber. d. k. Akad. Wiss. Wien, math.-naturwiss. Kl., vol. xliii, 1861, p. 19.

Lewinski: Ueber die Furchen und Falten der Haut, Virchow's Archiv, vol. xcii, 1883.

Loeb, L.: Ueber Transplantation von weisser Haut auf einer Defekt in schwarzer Haut und umgekehrt am Ohr des Meerschweinchens, Arch. f. Entwicklungsmech. der Organ., vol. vi, 1898.

Loewy, J.: Beiträge zur Anatomie und Physiologie der Oberhaut, Arch. f. mikr. Anat., vol. xxxvii, 1907, p. 159.

Loisel, G.: Formation et évolution des éléments du tissu élastique, Journ. de l'Anat. et de la Physiol., vol. xxxiii, 1897, p. 129.

Lombardo, C.: Il glicogeno della cute, Giorn. ital. delle mall. ven e della pelle, vol. xliii, 1907, p. 448.

Lüneburg, E.: Beiträge zur Entwicklung und Histologie der Knäueldrüsen in der Achselhöhle des Menschen, Inaug. Diss., Rostock (Abstr. in Hofmann-Schwalbe, Jahresb. f. Anat. u. Entwicklungsgesch., neue Folge, vol. viii, part iii, 1902, pp. 659, 670.

Maurer, F.: Die Epidermis und ihre Abkömmlinge, Leipzig, 1895.

Das Integument eines Embryo von Ursus arctos, Festschr. f. Ernest Haeckel, Jena, 1904.

De Meijere: Ueber die Haare der Säugetiere, besonders über ihre Anordnung, Morph. Jahrb., vol. xxi, 1894.

Meirowsky, E.: Die Entstehung des Oberhautpigments in der Oberhaut selbst, Monatsh. f. prakt. Dermatol., vol. xlii, 1906.

Die Entstehung des Oberhautpigments aus der Substanz der Kernkörperchen, Monatsh. f. prakt. Dermatol., vol. xliii, 1906.

Ueber den Ursprung des melanotischen Pigments der Haut und des Auges, Leipzig, 1908 (contains a full bibliography).

Merk, L.: Die Verbindung menschlicher Epidermiszellen unter sich und mit dem Corium, Monatsh. f. prakt. Dermatol., vol. xxxviii, 1904, p. 361.

Merkel: Tastzellen und Tastkörperchen bei den Haustieren und beim Menschen, Arch. f. mikr. Anat., vol. xi, 1875.

Merkel, Fr.: Die Hautfärbung neugeborener Farbiger, Korrespondenzbl. d. Deutschen Gesellsch. f. Anthropol., Ethnol., und Urgesch., 1907, p. 15.

Minot, C. S.: Lehrbuch der Entwicklungsgeschichte, 1894.

Nakai, M.: Ueber die Entwicklung der elastische Fasern im Organismus und ihre Beziehungen zu der Gewebsfunktion, Virchow's Archiv, vol. clxxxii, 1905, p. 153.

Ohlert, B.: Ueber die Gesetze der Blattstellung, Poggendorff's Annalen der Physik., vols. xciii and xcv, 1854–1855 (cited by Voigt).

Oshima, T.: Die Beziehungen des Wollhaares der Neugeborenen zu den Haaren des Erwachsenen, Pflüger's Archiv, vol. cxvii, 1907, p. 341.

Okamura, T.: Ueber die Entwicklung des Nagels beim Menschen, Arch. f. Dermatol. u. Syphil., vol. lii, 1900, p. 223.

Passarge: Monatsh. f. prakt. Dermatol., Ergänz-Heft, 1894.

Philippson, L.: Ueber die Herstellung von Flächenbildern der Oberhaut und der Lederhaut, Monatsh. f. prakt. Dermatol., vol. viii, 1889, p. 389.

Pinkus, F.: Ueber Hautsinnesorgane neben dem menschlichen Haar (Haarscheiben) und ihre vergleichend anatomische Bedeutung, Arch. f. mikr. Anat., vol. lxviii, 1905, p. 121.

Pohl, J. (Pincus): Die Querschnittsform des Kopfhaares der Kaukasier, Zeitschr. f. Ethnol. Verh., 1897, p. 483.

Pollitzer, S.: Ueber die Natur der von Zander im embryonalen Nagel gefundenen Körnerzellen, Monatsh. f. prakt. Dermatol., vol. ix, 1889, p. 346.

Post: Ueber normale und pathologische Pigmentierung der Oberhautgebilde, Virchow's Archiv, vol. cxxxv, 1893.

Profé, O.: Beiträge zur Ontogenie und Phylogenie der Mammarorgane, Anat. Hefte, vol. xi, 1899.

Rabl, H.: Histologie der normalen Haut des Menschen, Mracek's Handbl. der Hautkrankheiten, vol. i, part i, 1902, p. 1.

Reh: Die Schuppen der Säugetiere, Jen. Zeitschr. f. Naturwiss., vol. xxix, 1896.

Rein, G.: Untersuchungen über die embryonale Entwicklungsgeschichte der Milchdrüse, Arch. f. mikr. Anat., vols. xx and xxi, 1882.

RETTERER, E.: Structure et évolution du tégument externe, Journ. de l'Anat. et de la physiol., 1904.

ROSENSTADT, B.: Ueber das Eponychium des Hühnchens, Arch. f. mikr. Anat., vol. xlix, 1897, p. 561.

Studien über die Abstammung und Bildung des Haarpigments, Arch. f. mikr. Anat., vol. l, 1897, p. 350.

SCHIFFMANN, J.: Die Histogenese der elastischen Fasern bei der Organisation des Aleuronatexsudats, Centralbl. f. allg. Pathol. u. pathol. Anat., vol. xiv, 1903, p. 833 (bibliography).

SCHLAGINHAUFEN, O.: Ueber die Hautleisten der Planta der Primaten, Korrespondenzbl. d. Deutsch. Gesellsch. f. Anthrop. Ethnol. u. Urgesch., 1905, p. 336.

Ueber die Leistenrelief der Hohlhand und Fusssohlenfläche der Halbaffen, Ergebn. d. Anat. u. Entwicklungsgesch., vol. xv, 1905, p. 628–662.

SCHMIDT, H.: Ueber normale Hyperthelie menschlicher Embryonen, Anat. Anzeiger, vol. xi, 1896, p. 702.

SCHMITT, H.: Ueber die Entwicklung der Milchdrüse und die Hyperthelie menschlicher Embryonen, Inaug. Dissert., Freiburg (also in Morph. Arbeiten, vol. viii, 1898, p. 236).

SCHMORL, G.: Ueber Pigmentverschleppung aus der Haut, Centralbl. f. allg. Pathol. u. pathol. Anat., vol. iv, 1893.

SCHREIBER, L., and SCHNEIDER, P.: Eine Methode zur Darstellung von Pigmenten und ihren farblosen Vorstufen, mit besonderer Berücksichtigung des Augen, und Hautpigments, München. med. Wochenschr., No. 37, 1908, p. 1918.

SCHRIDDE: Die Protoplasmafasern der menschlichen Epidermiszellen, Arch. f. mikr. Anat., vol. lxvii, 1906, p. 291.

SCHULTZE, O.: Ueber die erste Analge der Milchdrüsenapparate, Anat. Anzeiger, vol. viii, 1892.

Ueber embryonale und bleibende Segmentierung. Verhandl. Anat. Gesellsch. Berlin, 1896, p. 87.

Grundriss der Entwicklungsgeschichte des Menschen und der Säugetiere, Leipzig, 1897.

SCHWALBE: Ueber den Farbenwechsel winterweisser Tiere, Morph. Arbeiten, vol. ii, 1893.

SCHWENDENER: Vorlesungen über mechanische Probleme der Botanik, bearbeitete von C. Holtermann, Leipzig, 1909 (contains a bibliography of Schwendener's original papers on p. 61).

SEIFFER, see HEAD.

SHERRINGTON, C. S.: Experiments in Examination of the Peripheral Distribution of the Fibres of the Posterior Roots of Some Spinal Nerves, Phil. Trans. Roy. Soc., vol. clxxxiv, 1893.

SPALTEHOLZ, W.: Ueber die Beziehungen zwischen Bindegewebsfasern und -zellen, Verhandl. Anat. Gesellsch., Rostock, 1906, p. 209.

STÖHR, P.: Ueber Intercellularbrücken zwischen äusserer und innerer Wurzelscheide, Verhandl. Anat. Gesellsch., Heidelberg, 1901, p. 24.

Ueber die Entwickelung der Glaschaut des menschlichen Haarbalges, Verhandl. Anat. Gesellsch., Heidelberg, 1901, p. 26.

Entwicklungsgeschichte des menschlichen Wollhaars, Anat. Hefte, vol. xxiii, 1903.

Lehrbuch der Histologie und der mikroskopischen Anatomie des Menschen, 12 Aufl., 1906.

Ueber die Schuppenstellung der menschlichen Haare, Verhandl. Anat. Gesellsch., Würzburg, 1907, p. 153.

STRAHL, H.: Die erste Entwicklung der Mammarorgane beim Menschen, Verhandl. Anat. Gesellsch., Kiel, 1898.

STUDNICKA, F. K.: Schematische Darstellungen zur Entwicklungsgeschichte einiger Gewebe, Anat. Anzeiger, vol. xxii, 1903, p. 537.

TANDLER, J.: Ueber einen menschlichen Embryo von 38 Tagen, Anat. Anzeiger, vol. xxxi, 1907, p. 49.

TEUFFEL, see SCHIFFMANN.

UNNA, P. G.: Das subkutane Fettgewebe, Monatsh. f. prakt. Dermatol., vol. i, 1881, p. 81.

Entwicklungsgeschichte und Anatomie, Ziemssen's Handb. d. spez. Path. u. Ther., Leipzig, 1883, vol. xiv, part i, p. 3.

Die Fortschritte der Hautanatomie in den letzten fünf Jahren, IV. Der Nagel, Monatsh. f. prakt. Dermatol., vol. viii, 1889, p. 79.

Der Nachweis des Fettes in der Haut durch secundäre Osmierung, Monatsh. f. prakt. Dermatol., vol. xxvi, 1898, p. 601.

Eine neue Darstellung der Epithelfasern und die Membran der Stachelzellen, Monatsh. f. prakt. Dermatol., vol. xxxvii, 1903, pp. 289, 337.

UNNA and GOLODETZ: Neue Studien über die Hornsubstanz, Monatsh. f. prakt. Dermatol., vol. xlvii, 1908, p. 62.

Zur Chemie der Haut, II. Der mikrochemische Nachweis der Keratine durch Millon's Reagens, Monatsh. f. prakt. Dermatol., vol. xlvii, 1908, p. 595.

VOIGT, C. A.: Abhandlung über die Richtung der Haare am menschlichen Körper, Denkschr. k. Akad. Wissensch. Wien. math.-naturwiss. Kl., vol. xiii, 1857.

VÖRNER, H.: Ueber Trichohyalin, Dermatol. Zeitschr., vol. ix, 1903, p. 357.

WALTER, H. E.: On Transitory Epithelial Structures Associated with the Mammary Apparatus in Man, Anat. Anzeiger, vol. xxii, 1902, p. 97.

WEBER, M.: Bemerkungen über den Ursprung der Haare und über Schuppen bei Säugetieren, Anat. Anzeiger, vol. viii, 1893, p. 413.

WEIDENREICH, F.: Ueber Bau und Verhornung des menschlichen Oberhaut, Arch. f. mikr. Anat., vol. lvi, 1900, p. 169.

Weitere Mittheilungen über den Bau der Hornschicht der menschlichen epidermis und ihren sog. Fettgehalte, Arch. f. mikr. Anat., vol. lvii, 1901, p. 583.

WHIPPLE, INEZ L.: The Ventral Surface of the Mammalian Chiridium with Special Reference to the Conditions Found in Man, Zeitschr. f. Morphol. u. Anthrop., vol. viii, 1904, p. 261.

WIEDERSHEIM, R.: Der Bau des Menschen als Zeugnis für seine Vergangenheit, 4th Aufl., 1908.

WIETING and HAMDY: Ueber die physiologischen und pathologischen Melaninpigmentierung und den epithelialen Ursprung der Melanoblastome, Ziegler's Beiträge, vol. xlii, 1907.

WILSON, H. C.: Beitrag zur Entwicklungsgeschichte der Haut des Menschen, Mitth. a. d. embryol. Inst. in Wien, part iv (abstr. in Monatsh. f. prakt. Dermatol., vol. i, 1880, p. 46.

WIMPFHEIMER, C.: Zur Entwicklung der Schweissdrüsen der behaarten Haut, Anat. Hefte, No. 104, 1907.

ZANDER: Die frühesten Stadien der Nagelentwicklung und ihre Beziehung zu den Digitalnerven, Arch. f. Anat. u. Phys., Anat. Abth., 1884, p. 103.

Untersuchungen über den Verhornungsprozess, Arch. f. Anat. u. Phys., Anat. Abth., 1886, p. 373.

Untersuchungen über den Verhornungsprozess, II. Mitteilung, Der Bau der menschlichen Epidermis, Arch. f. Anat. u. Phys., Anat. Abth., 1888, p. 51.

XI.

DEVELOPMENT OF THE SKELETON AND OF THE CONNECTIVE TISSUES.

By CHARLES R. BARDEEN, Madison, Wis.

GENERAL FEATURES.

In the bodies of most living things certain tissues are differentiated for the purpose of passively supporting or protecting the physiologically more active structures. These tissues are characterized in the higher vertebrates by the predominant amount of extracellular substance, usually fibrous in nature, which, in large part at least, is differentiated during embryonic development from the peripheral portions of branched anastomosing cells. According to the nature of the intercellular substance the supporting tissues are subdivided into white fibrous and yellow elastic tissues, reticulum, cartilage, and bone.

In early embryonic stages the branched anastomosing cells which compose the supporting tissue or mesenchyme, form an extensive continuous framework. Certain parts of this framework are differentiated into the definitive skeleton and other parts into connective-tissue structures which protect and support the parenchyme of the various organs of the body and attach these organs to the skeleton.

The development of the various connective-tissue structures may be considered from two aspects, that of histogenesis and that of organogenesis. The histogenesis of the connective tissues has been most carefully studied in the lower vertebrates, in which the cells are large and the conditions are relatively simple. Organogenesis has been more carefully studied in man than in any of the lower forms. The histogenesis of the connective tissues is apparently similar in the different vertebrates. Study of the histogenesis of these tissues in man and the higher mammals in general serves to confirm the results found in the lower vertebrates. Organogenesis is peculiar for each species, although there are fundamental similarities to be observed in related forms.

We shall first give a brief account of the histogenesis of the connective tissues with especial reference to man and then treat with more detail the morphogenesis of the human skeleton. The specific development of the intrinsic supporting connective-tissue framework of the various organs is most conveniently taken up in connection with each of these organs, and will therefore not be attempted here.

PART I.

Histogenesis of the Connective Tissues.

(a) Early Mesodermic Syncytium.

In the youngest human embryos which have been described there is present a well-developed layer of tissue composed of branched anastomosing cells. This tissue layer surrounds the amniotic and yolk-sacs and lines the chorionic vesicle (Fig. 219, A). It forms a continuous sheet between the epithelium lining the amniotic cavity and that lining the yolk sac. The origin of the tissue is uncertain. It evidently is homologous with the mesoderm which in many of the mammals is known to arise from the primitive streak and head process.

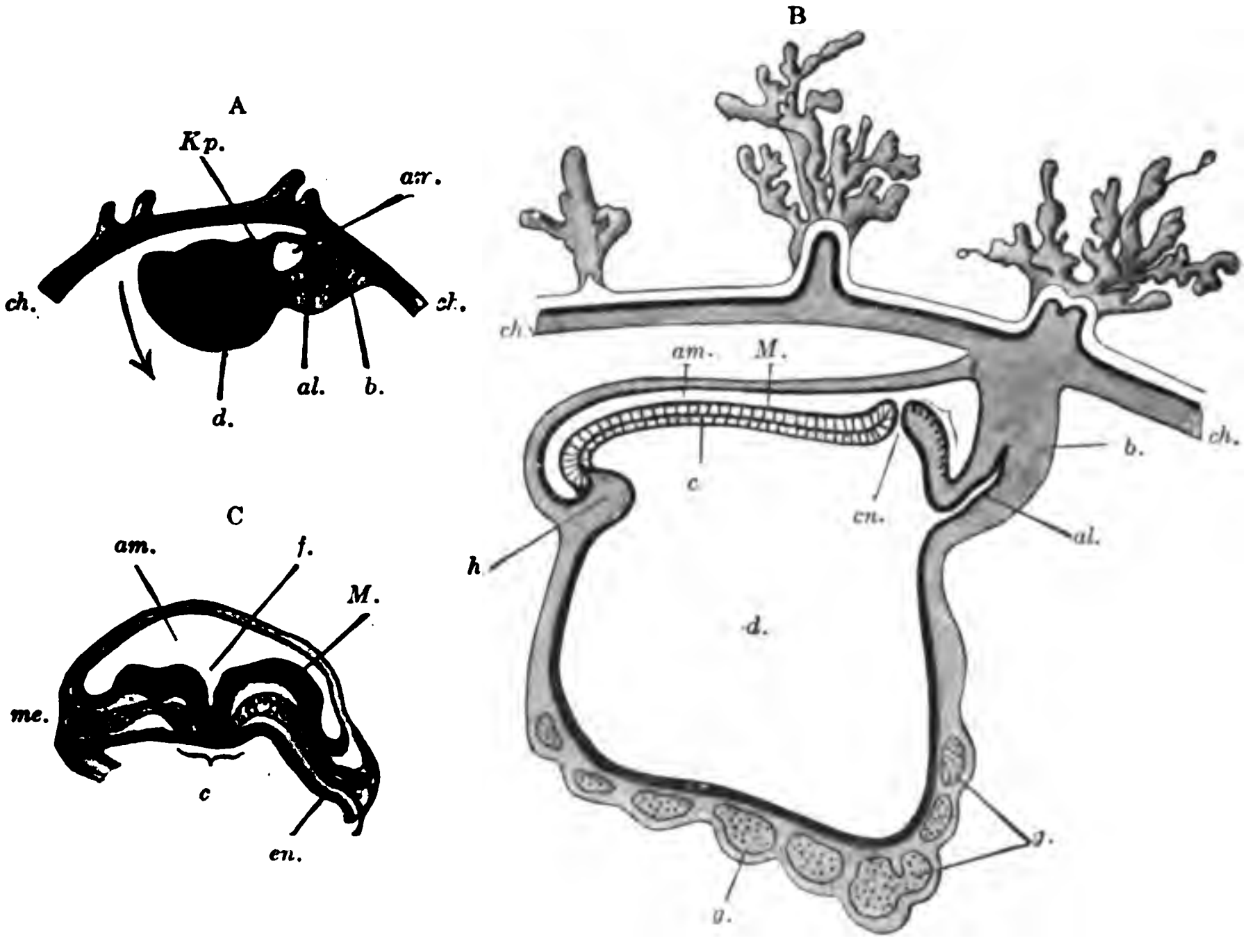

FIG. 219.—Diagrammatic sections through two young human embryos described by Graf Spee. A. (V. Spee, Arch. f. Anat. u. Physiol., Anat. Abt., 1896, Taf. I, Fig. 3.) Half-schematic sagittal section through Graf Spee's embryo v. H. B. (Ebenda, Taf. I, Fig. 1.) Half-schematic sagittal section through Graf Spee's embryo Gle. C. (Ebenda, 1889, Taf. XI, Fig. 14.) Transverse section through the embryonic anlage near the region opposite *M.* in Fig. B. *al.*, allantoic canal; *am.*, amniotic cavity; *b.*, belly stalk; *c*, chorda anlage; *ch.*, chorion; *cn.*, canalis neurentericus; *d.*, yolk-sac; *en.*, entoblast; *f.*, medullary groove; *g.*, blood islands; *h.*, heart; *kp.*, region of primitive streak; *M.*, medullary plate; *me.*, mesoblast.

In man the primitive mesoderm is apparently formed before the appearance of the medullary plate, the neurenteric canal, and the primitive streak. After these structures appear the mesoderm disappears in the mid-axial line *anterior* to the primitive streak, and a chordal plate is differentiated in the entoderm. (See Fig. 219.)

(b) Formation of the Mesodermic Somites.

In Graf Spee's embryo Gle (Fig. 219, B and C) the mesoderm extends on each side of the neurenteric canal and of the medullary groove (Fig. 219, C) to the anterior extremity of the embryonic anlage where the mesodermic sheets of both sides become united (Fig. 219, B, h). Posterior to the neurenteric canal the mesoderm is intimately united to the tissue of the primitive streak, a region of active production of mesenchymal tissue. At the outer margin of the embryonic anlage the mesoderm is continuous posteriorly with the mesenchymal lining of the chorion, laterally and anteriorly with the mesodermic covering of the yolk sac and amnion (Fig. 219, B and C).

At a slightly later period the sheet of mesoderm on each side of the neural tube becomes longitudinally separated from the more laterally situated mesoderm (Fig. 220, A and C) and at the same time divided into a series of segments (mesoblastic somites). In the chick the first somites formed are the occipital somites (J. T. Patterson, Biological Bulletin, 1907, vol. xiii, p. 121), then follow in turn the cervical, thoracic, lumbar, sacral, and coccygeal. It is probable that the first somites formed in the human embryo belong to the occipital region. In the latter half of the first month of development in the human embryo there are found anterior to the cervical myotomes three incomplete occipital myotomes. The relations of these myotomes to the first somites differentiated have not yet been definitely determined. Eternod (Anat. Anz., 1899, p. 131) has described an embryo with eight somites, Kollmann (Anat. Anz., 1890, Arch. f. Anat. u. Physiol., Anat. Abt., 1891) one with fourteen (Fig. 220, A), and Mall (Journ. Morphol., 1897) likewise one with fourteen. Mall considers the first three somites in his embryo to be occipital somites. They probably correspond with the first three somites in the embryo described by Kollmann and possibly with the first three in the embryo described by Eternod.

The occipital somites are probably not completely divided off either from one another or from the lateral mesoderm (Figs. 229, 230, A).[1] The cervical somites, at least the more distal ones, on the other hand, become completely separated, and the tissue in

---

[1] Kollman states that in his embryo Bulle, with fourteen somites, the segmentation externally appears well marked in the post-otic region, but internally is apparently incomplete. (Personal communication to the author.)

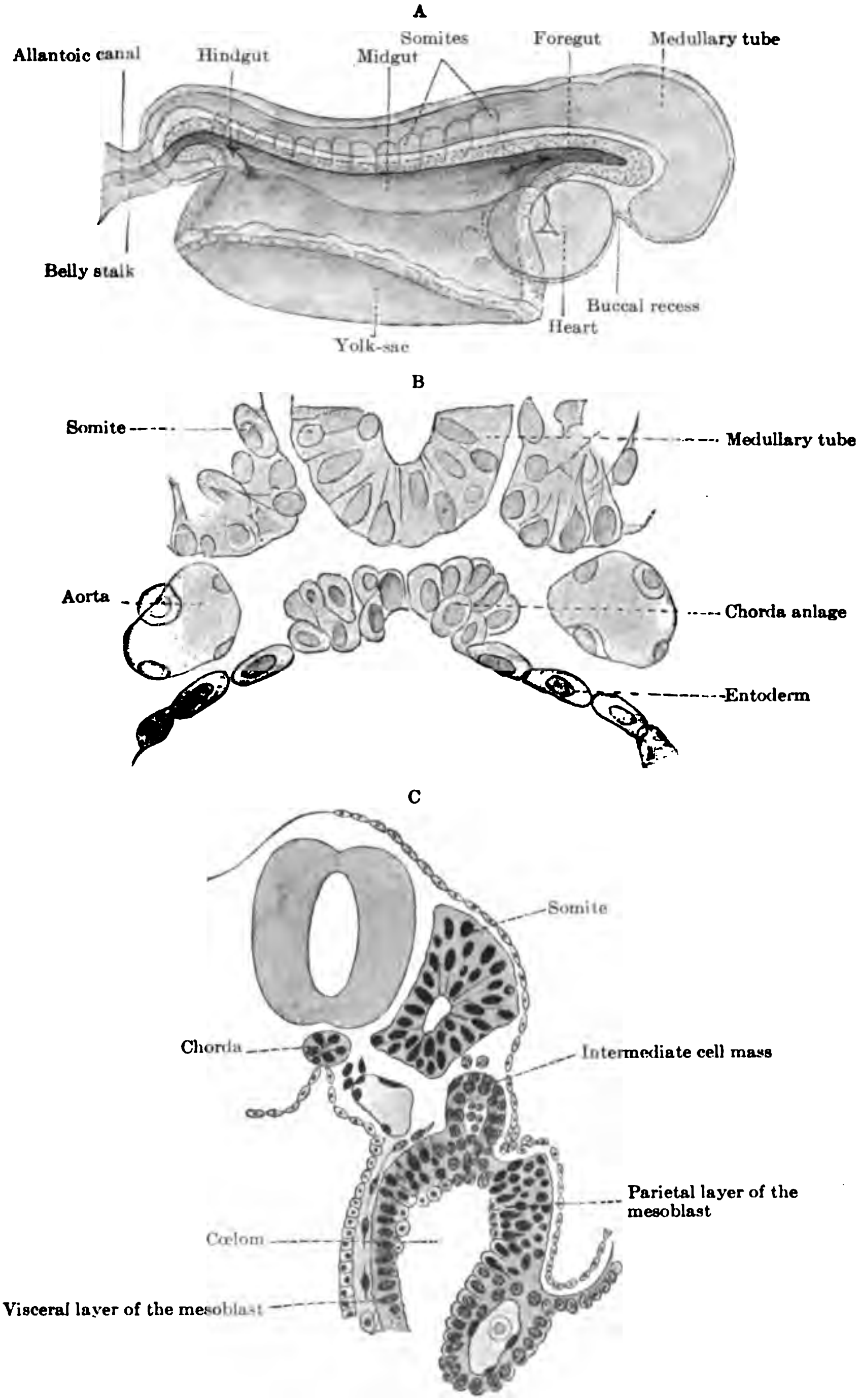

FIG. 220.—A. (After Kollmann, Lehrbuch der Entwicklungsgeschichte des Menschen, Fig. 119.) Human embryo with fourteen somites, 2.5 mm. long. Magn. 30 : 1. B. (Ebenda, Fig. 56.) Transverse section through the region behind the heart of the embryo shown in Fig. 220, A. C. (After Kollmann, Arch. f. Anat. u. Physiol., Anat. Abt., 1891, Plate III, Fig. 3.) Transverse section through the tenth pair of somites of the embryo shown in Fig. 220, A.

each assumes an epithelial character and becomes arranged about a central cavity or myocoel (Fig. 230, d). At the posterior end of the cervical region a solid column of cells marks for a short period the remains of the neurenteric canal. Beyond this in the axial region lies the tissue of the primitive streak which is continued into the mesenchyme of the allantoic stalk. In subsequent development mesoderm is differentiated from the anterior end of the primitive streak on each side of the posterior end of the neural groove. In this mesoderm successive somites are formed. Finally, as the differentiation of the body extends posteriorly, a definite primitive streak gradually gives way to a mass of mesenchymal cells situated between the ectoderm and entoderm, and then, in the caudal process, to a mass of cells entirely surrounded by ectoderm. From this mass of cells are successively differentiated the more caudal mesodermic somites.

(c) Axial Mesenchyme.

As the chorda dorsalis becomes differentiated (see below) marked changes take place in the somites. For a time these consist of epithelial tissue which surrounds a central cavity or myocoel (Fig. 220, C). Toward the end of the third week the cervical and thoracic myocoeles become gradually filled with branched spindle-shaped mesenchyme cells which come from the surrounding epithelium. The medial wall of the somite opens, and the mesenchyme cells wander out toward the neural tube and the chorda, and give rise to a tissue which ensheathes these organs (Fig. 221). The mass of mesenchyme derived from each somite represents a sclerotome. The successive sclerotomes soon fuse so as to give rise to a continuous mass of mesenchyme. The mesenchyme of the two sides becomes fused. After giving rise to the sclerotomes the somites become converted into myotomes, the further fate of which is described in the section on the development of the muscular system. In many of the lower vertebrates the lateral layer of the myotomes gives rise to dermis, but in mammals the dermis comes chiefly, if not wholly, from axial mesenchyme. (Bardeen, Johns Hopkins Hospital Reports, vol. ix, 1900.)

(d) Parietal and Visceral Layers of the Mesoderm.

During the formation of the embryonic cœlom, the lateral unsegmented mesoderm plates become divided into two layers, a parietal layer and a visceral layer (Figs. 220, C, and 221). The cells facing the cœlom assume an epithelial character. The deep strata of the parietal layer give rise to scleroblastema, from which some of the skeletal apparatus and connective tissues of the trunk and limbs are derived. The deeper strata of the visceral layer give rise to the connective tissues as well as to the musculature of the thoracic and abdominal viscera.

(e) Mesenchyme of the Head.

The axial mesoderm of the trunk is continued forward on each side of the chorda dorsalis to the region of the base of the midbrain. From it arises a large part of the mesenchyme of the head, including most of that which gives rise to the skeletal structures of the cranium and the upper part of the face. The transformation of mesoderm into definitive skeletal structures is more direct in the cranial than in the spinal region. The formation of somites for the axial region of the head is restricted to the postotic region, and even here it is, as mentioned above, less complete than in the trunk. The cranial mesoderm apparently is largely converted into mesenchyme without going through that process of division into somites characteristic of the spinal mesoderm. The mesenchyme near the chorda in the occipital region shows no segmentation in the latter half of the first month. More laterally segmentation is indicated by the formation of myotomes from the dorso-lateral portion of the mesoderm. Near the myosepta the mesoderm may show a slight condensation.

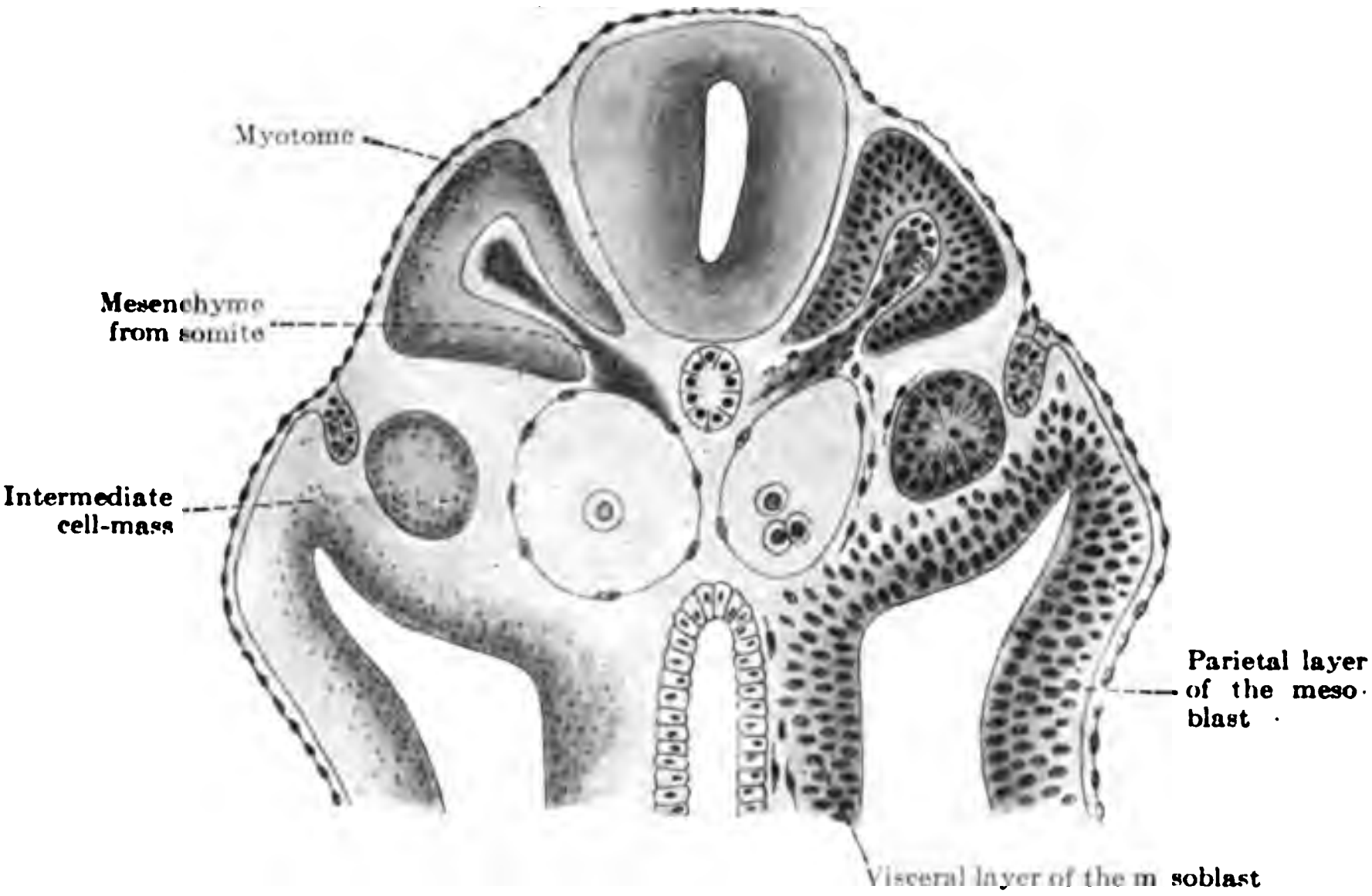

FIG. 221.—(After Kollmann, Arch. f. Anat. u. Physiol., Anat. Abt., 1891, Plate III, Fig. 8.) Transverse section through the posterior part of the trunk of a human embryo of the third week.

In the prechordal mesenchyme of the head there are differentiated in many vertebrates vesicular cavities, "head cavities," lined by epithelium, from which musculature and mesenchyme arise. There are four such cavities in selachians and in reptiles. Their relation to the somites is undetermined. In man very transitory structures of this nature have been reported (Zimmermann, Ueber Kopfhöhlenrudimente beim Menschen, Arch. f. mikr. Anat., 1898, vol. liii), but they are rare and play no essential part in development.

The dorsal portion of the lateral mesoderm plate of the trunk is continued anteriorly into the branchial region, where it gives rise to the mesenchyme of the branchial arches and partly also to that of the head. Ventral to the branchial arches the lateral mesoderm of the trunk is continued into the pericardial mesoderm. The cœlom does not extend into the branchial region of the lateral mesoderm of the head.

(f) Origin of the Connective Tissues.

From the mesenchyme, derived in part directly from the primitive embryonic mesodermic tissue, in part from somites differentiated from this primitive tissue, and in part from the primitve streak, there arses a syncytial tissue which in turn gives origin to the various connective tissues and skeletal structures of the body as well as to some other structures, for instance, muscles and blood-vessels.

In the adult connective tissues the bulk of the tissue substance is usually described as extracellular.[2] The chief problem for those who have studied the histogenesis of the connective tissues has been to determine whether the substances which are intercellular in the differentiated tissues have an intracellular or an intercellular origin. The weight of evidence seems at present to be decidedly in favor of the intracellular origin (Fleming, 1891, 1897, 1902, Retterer, 1892–1906, Spuler, 1897, Mall, 1902, and Spalteholz, 1906). Among recent investigators who believe that the connective-tissue fibres have an intercellular origin may be mentioned E. Laguesse (1903) and Fr. Merkel (1895, 1909). Golowinski, while contending that the fibres appear between the cells, admits that they rise close to the cell body. According to him, most investigators have described essentially the same phenomena, but some consider the mother substance in which the fibres arise as ectoplasm, while others consider it an intercellular substance. The majority of those who adopt the view that the "intercellular" portions of the adult connective tissues are intracellular in origin describe the primitive mesenchymal cells as becoming differentiated into endoplasmic and ectoplasmic portions. In the ectoplasm the

---

[2] Spalteholz (Anat. Anz., 1906) has, however, shown that even in the adult many, if not all, of the fibrils have an intracellular position.

intercellular elements characteristic of each of the various kinds of connective tissue are differentiated while the endoplasm becomes converted into the cells of the adult tissue. Retterer (1892–1906) gives a different description of the process. According to him the primitive tissue from which the various kinds of connective tissue are differentiated consists of a homogeneous syncytium in which nuclei are scattered about. This homogeneous syncytium becomes differentiated into two parts, a hyaloplasm and a granular chromophilic portion. The granular chromophilic portion surrounds the nuclei and gives rise to branching processes which anastomose so as ultimately to form an extensive network. The hyaloplasm lies in the meshes of this network. The fibres of recticulum, elastic fibres, and the branched anastomosing processes which fill the canaliculi of bone arise from the chromophilic network, while white fibrous tissue and the chief part of the ground substance of cartilage and of bone are differentiated from the hyaloplasm.

Recently still another view of the origin of the fibrils of the connective tissues has been advanced. It has been known for some time that in the vitreous humor before the entrance of blood-vessels and mesenchyme cells there exists a fibrillar structure the components of which may be looked upon as branched anastomosing processes of cells of the retina and lens. From this fibrillar network the fibrils of the adult vitreous humor are probably derived. Aurel v. Szily (1908) has described a fibrous network filling in spaces throughout the embryonic body before the origin of the mesenchyme. The fibrils of the network are branched anastomosing processes of the epithelial layers bounding the various cavities. Szily thinks that when the mesenchyme cells arise they wander into meshes of this fibrillar network and enter into intimate relations with the component fibrils. The fibrils subsequently lose connections with the epithelial cells from which they arise. According to Szily the fibrils of the early embryonic syncytium are thus of epithelial origin, while the cell protoplasm is of the mesenchymal origin. Although the early connective-tissue fibrils are thus according to this view of epithelial origin, at a later stage connective-tissue fibrils are also differentiated in the ectoplasm of cells derived from the mesenchyme. According to Retterer (1904 and 1906) the syncytium of the cutis arises partly from the epidermis.

The following account of the origin of the connective tissues is based chiefly on the paper of Mall, who has taken up the problem in connection with the pig and man.

At an early stage there appear to be many individual cells in the mesenchyme which multiply rapidly, so that in certain regions the nuclei are closely packed together. Then the cells unite to form a syncytium and the protoplasm of the syncytium increases more rapidly in amount than the nuclei, so that the latter appear more widely separated from one another than at first. The nuclei at an early stage lie within the protoplasm of the syncytium, but gradually differentiation takes place. Immediately about the nuclei the protoplasm becomes granular and forms an endoplasm which is distinct from the rest of the syncytium or ectoplasm. From the granular endoplasm about the nuclei processes may extend into the surrounding ectoplasm. In the ectoplasm fibrillation becomes more and more distinct. The nuclei surrounded by the endoplasm come to lie in certain of the meshes of the network formed by the ectoplasm. In other of the meshes merely a fluid substance is seen. From this embryonic syncytium the various types of connective tissue are differentiated.

Reticulum.—Reticulum seems to be the least highly differentiated form of tissue which arises from the embryonic connective-tissue syncytium. The reticulum develops directly in the syncytial ectoplasm, while the nuclei and endoplasm are converted into cells which lie upon the reticulum fibres. In the liver the origin of the reticulum differs from that in other parts of the body in that it arises from Kupffer's endothelial cells instead of from mesenchyme. The endothelial cells form a syncytium in which the reticulum fibres are differentiated. According to Retterer the reticulum fibres arise from chromophilic processes of the perinuclear protoplasm.

White Fibrous Tissue.—In the development of white fibrous tissue from the embryonic syncytium Mall distinguishes two stages. In the first or prefibrous stage a tissue much resembling reticulum is differentiated, in the second or fibrous stage true white fibrous tissue appears. (Fig. 222, A and B.) In the first stage the syncytium grows very rapidly. The ectoplasm increases in amount much more rapidly than the endoplasm. The nuclei, however, multiply, and the endoplasm about each nucleus becomes drawn out spindle-like, giving rise to the well-known embryonic bipolar cells. The tips of these cells are extended into the ectoplasm, and here the endoplasm appears constantly to contribute to the ectoplasm. The ectoplasm becomes steadily more fibrillated. The strands of ectoplasm become more and more drawn out, in tendons and fasciæ into parallel, in areolar tissue into interweaving bundles of fibres. In the fibrous stage the embryonic fibres are converted into true white fibrous tissue, their chemical nature meanwhile changing. The fibres at first occasionally anastomose, but during further development the anastomosing bridges begin to break down. According to Mall the larger fibres become split into the individual fibrils of white fibrous tissue. The embryonic spindle-shaped cells become converted into the adult connective-tissue corpuscles. According to Retterer the fibres in the prefibrous stage belong to the chromophilic processes of the perinuclear protoplasm. On the other hand, the collagenous fibres arise from the hyaloplasm (ectoplasm).

The body of the cornea is composed of a tissue the origin of which is similar to that of white fibrous tissue. It retains more features characteristic of the embryonic connective tissue than does the ordinary white fibrous tissue. It contains no elastic fibres.

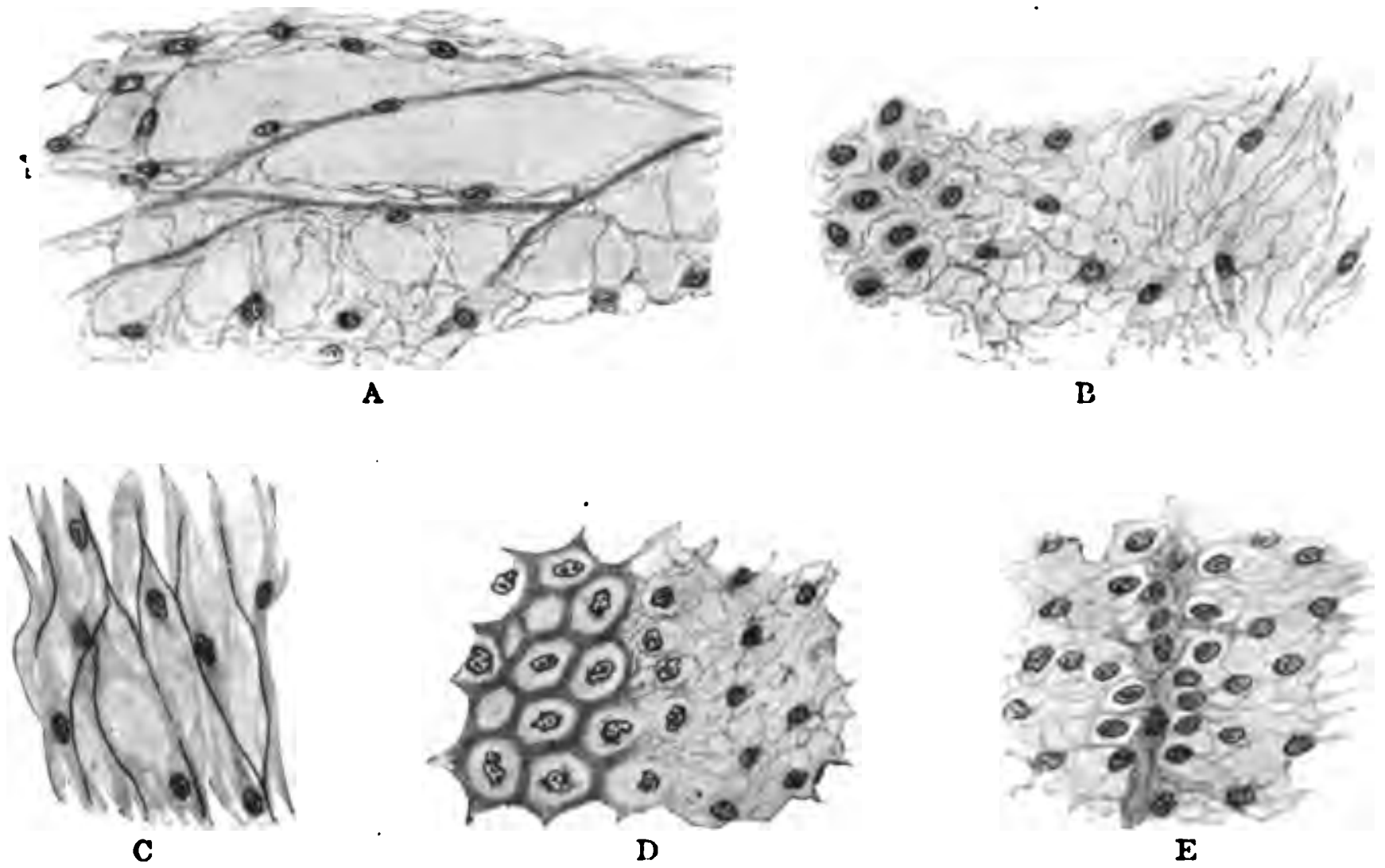

Fig. 222.—(After Mall, American Journal of Anatomy, 1902.) To illustrate the development of the connective tissues. A. (Fig. 12, Mall.) Section through the skin of a pig 5 cm. long. White fibres are forming in the ectoplasm. Magn. 250 : 1. B. (Fig. 13, Mall.) Section through the skin of a pig 16 cm. long. The nuclei and endoplasm on the left are immediately below the root of a hair. Magn. 250 : 1. C. (Fig. 14, Mall.) Elastic tissue just beginning to appear in the syncytium of the umbilical vein of a pig 7 cm. long. Magn. 250 : 1. D. (Fig. 10, Mall.) Section through the occipital cartilage of an embryo pig 20 mm. long. The ground substance is deposited in the ectoplasm of the syncytium. Magn. 250 : 1. E. (Fig. 11, Mall.) Section through the frontal bone of a pig 20 mm. long. Magn. 250 : 1.

Elastic Tissue.—With the exception of the tissue of the cornea probably all white fibrous tissue contains a greater or less number of elastic fibres intermingled with the bundles of white fibrils. The elastic-tissue fibres apparently are differentiated directly in the same syncytial ectoplasm in which the bundles of white fibrils develop (Fig. 222, C). The youngest pigs in which Mall found elastic fibres were four centimetres long. These fibres were found in the aorta and neighboring arteries. Fenestrated membranes are formed by the coalescence of neighboring fibres. Spalteholz (1906) has found elastic fibres in the truncus arteriosus of pig embryos 9.2 mm. long. Ranvier held that elastic fibres arise from the fusion of rows of elastic granules. According to Mall, elastic fibres are never formed by the fusion of rows of such granules. Spalteholz has likewise found that the elastic fibres are directly differentiated. According to Retterer, the elastic fibres arise in the perinuclear chromophilic protoplasm and from the chromophilic processes which spring from it.

Adipose Tissue.—Adipose tissue appears in the fourth month in the human embryo. In the regions where the adipose tissue is formed the embryonic mesenchymal tissue becomes differentiated on the one hand into blood-vessels and a supporting fibrous-tissue framework, on the other into cells in the protoplasm of which granules of fat appear. The granules of fat in each cell gradually become consolidated, so that finally there arises a single large globule of fat which greatly distends the cell. The protoplasm of the cell now forms a thin covering for the globule of fat. The nucleus surrounded by a small amount of granular protoplasm lies at one side. The fat cells are arranged more or less definitely with relation to the blood-vessels and frequently form well-marked clusters. (See Bell, 1909.)

Cartilage.—In the formation of cartilage the ectoplasm of the syncytium becomes more and more dense. The nuclei surrounded by endoplasm come to lie in spaces in the ectoplasm, thus forming precartilage cells which in turn become converted into cartilage cells (Fig. 222, D). The syncytial ectoplasm undergoes chemical changes which make it exhibit the reactions characteristic of hyaline ground substance. Not infrequently the ectoplasm before becoming converted into hyaline ground substance becomes marked out into cell territories by the appearance of membranes between the cell units. These membranes appear as fine lines in cross section and have staining reactions similar to hyaline cartilage. When this condition is found, the cartilage has an epithelioid appearance (cellular cartilage).

The endoplasmic units or cartilage cells exhibit a differentiation into perinuclear and peripheral portions. From the peripheral portion hyaline substance is differentiated so as to form a capsule (Max Schultze). The capsule appears lighter than the surrounding tissue and has slightly different staining reactions. Meanwhile the endoplasm increases in amount, the nuclei multiply, and from time to time cell division takes place in the endoplasmic units, but this division does not extend into the surrounding ectoplasm. When cell division takes place, the line of separation between the two daughter cells usually becomes marked by a fine septal membrane composed of a substance that has some of the staining qualities of the cell capsules. This septum then becomes divided into two lamellæ, each of which together with half of the old capsule surrounds a daughter cell. Sometimes the capsules of several successive generations of cells remain distinct for a considerable period, so that a capsule which first surrounded a single cell comes to surround several groups of daughter cells, each group and each daughter cell having in turn a capsule of its own. Usually, however, the primitive capsules become indistinguishably fused with the surrounding matrix, so that capsules about single cells or pairs of cells alone remain distinct.

Growth of cartilage is in part interstitial, in part perichondral. The interstitial growth is due (1) to the direct increase in amount of the ectoplasm or ground substance, (2) to the formation of cell capsules at the periphery of the cells and the fusion of these capsules with the matrix, and (3) to cell multiplication. Perichondral chondrification is due to the formation of new cartilage beneath the perichondrium. The ground substance increases in amount faster than the cells multiply.[3]

In white-fibrous cartilage bundles of fibrils develop in the syncytium while the hyaline substance is being deposited. In elastic cartilage, according to Mall, elastic fibres are formed after the hyaline substance has been differentiated. According to Spalteholz (1906), however, elastic fibres appear before the hyaline ground substance in the ear cartilage of the pig. In the arytenoid cartilage clumps of elastic granules are deposited. While Ranvier held that elastic fibres arise from the fusion of rows of these granules, Mall, as mentioned above, believes that neither here nor elsewhere are the elastic granules fused to form elastic fibres.

BONE.—The histological structure of bone is still a matter of dispute. Most investigators seem to consider the ground substance to be composed of bundles of fibrils resembling those of white fibrous connective tissue embedded in a homogeneous "cement" substance. V. Kölliker, who considered the cement substance to be slight in amount, believed the calcium salts to be embedded both in this and in the fibrils. V. Ebner, 1875, believed the calcium salts to be embedded chiefly in the cement substance. Retterer, 1905 and 1906, believes the ground substance of bone to be composed of a chromophilic reticulum embedded in a hyaloplasm impregnated with calcium salts. It is well known that the ground substance of bone contains a collagenous substance similar to that of white fibrous tissue.

Bone, like other connective tissues, is formed from a blastemal syncytium. Ectoplasm becomes distinct from nucleated endoplasmic cell units. In the ectoplasm calcium salts are deposited. Two stages may thus be distinguished,—a pre-osseous, previous to the deposition of calcium salts, and an osseous, after these salts have been deposited. During ossification about two parts of inorganic salts combine with one part of organic matter.

The cells which give rise to bone may appear similar to ordinary immature connective tissue cells or they may pass

---

[3] For details concerning the development of cartilage see Retterer (1900).

through a stage in which they appear epithelioid in character. Cells of the latter type are frequently found in regions where layers of bone are being applied to pre-existing bone or to calcified cartilage. The epithelioid cells, which Gegenbaur called osteoblasts, form a layer from the deep surface of which certain cells branch, anastomose, and give rise to an osteogenetic syncytium which becomes converted into bone (Fig. 223, A).

According to v. Kölliker (Gewebelehre) and to many other investigators, the osteoblasts secrete the ground substance, which, therefore, is to be looked upon rather as intercellular than as intracellular. To Waldeyer (1865) we are indebted for the first clear description of the differentiation of the ground substance of bone in the peripheral protoplasm of the osteoblasts.

The endoplasmic units, or bone corpuscles, have branched processes which anastomose freely through the canaliculi with those of neighboring cells. Before birth (Neumann) the periphery of the bone corpuscles becomes differentiated into a resistant cuticle which has staining reactions similar to elastic tissue (Retterer) and which is resistant to strong acids and alkalies. Brösike (1885) considered this cuticle (bone-cell capsule) to be composed of keratin, but Kölliker has shown it to be soluble in boiling water. According to Retterer the protoplasm of the branching processes which lie in the canaliculi is converted into a similar substance.

In the human embryo bone arises chiefly in connection with a transitory cartilaginous skeleton which it gradually in large part replaces. Thus the vertebræ, ribs, sternum, the skeleton of the extremities, and most of the base of the skull are first formed of cartilage, and the cartilage is later replaced by bone (substitution bone). Centres of ossification may appear within the cartilage (endochondral ossification) or beneath the perichondrium (subperiosteal ossification). On the other hand, most of the bones of the face and the flat bones of the skull are formed directly in membranous tissue (intramembranous bone).

When bone is first formed in the embryo, it consists of a coarse plexiform or spongy framework, in the meshes of which lies a vascular embryonic marrow. To the walls of the spaces in this primitive spongy bone successive layers of bone are added by osteoblasts, so that the spaces come to have lamellated walls. Similarly beneath the periosteum lamellæ of bone are laid down, so that the surface of the bone comes to consist of a series of successive lamellæ. The formation of definite lamellæ of compact bone is not, however, well marked until after birth. Previous to this period the vascular spaces in the bone are relatively large, so that the coarse spongy structure mentioned above is long retained. In long bones Schwalbe found compact lamellar bone formed about the marrow cavity and in the Haversian canals in

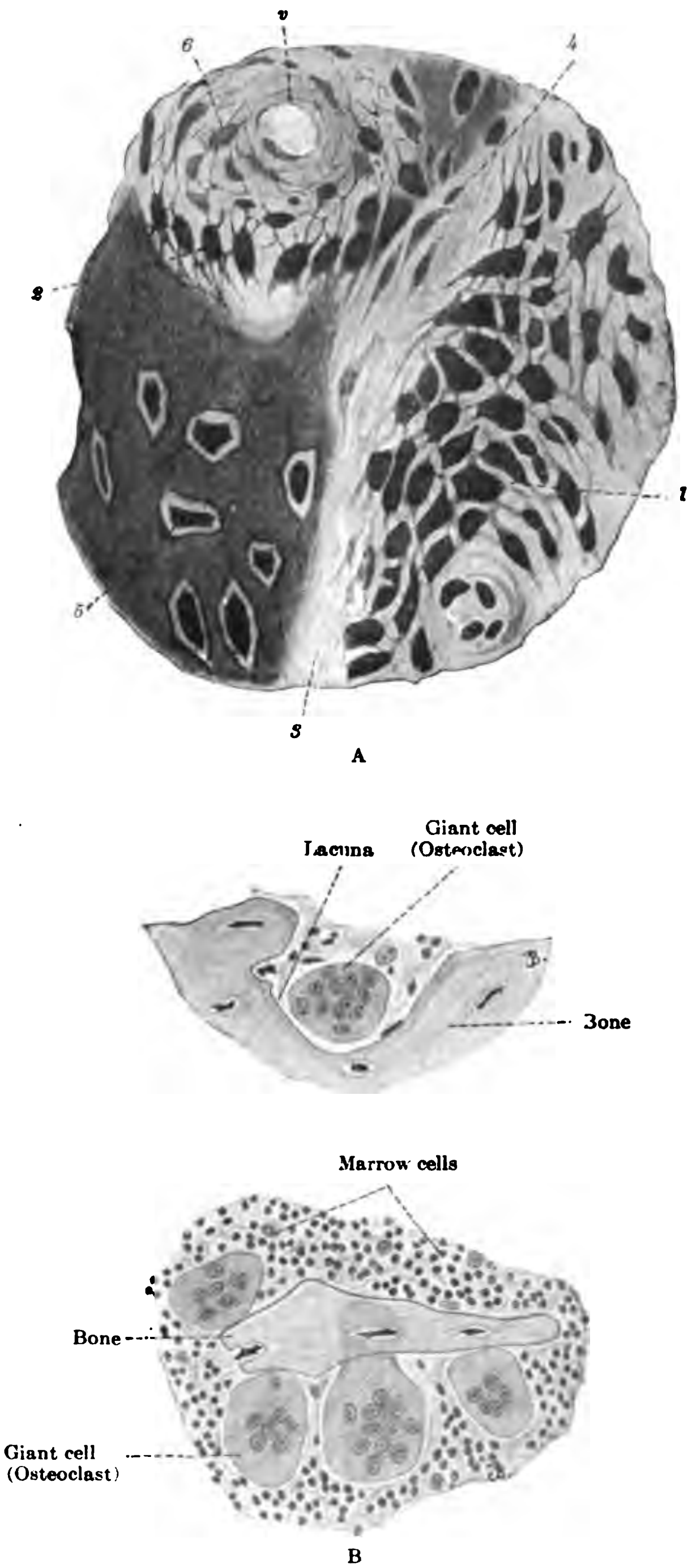

FIG. 223.—A. (After Retterer, 1906.) Section through the jaw of a dog at birth. 1, layer of osteoblasts beneath the periosteum; 2, osteoblasts with reticular connective tissue (6) in a medullary cavity in the bone; 3, layer of preosseous tissue; 4, nucleated, granular, cytoplasmic masses of the preosseous layer; 5, osseous lamina; *v*, blood-vessel. B. (After Szymonowicz.) From a longitudinal section of the femur of a rabbit embryo.

the sixth month after birth, but beneath the periosteum not until the fourth year. Kölliker (Gewebelehre) found lamellar subperiosteal bone as early as in the first year after birth.

During the period of the growth of bone new bony tissue is being constantly added in some regions, while in other regions the bone already formed is absorbed to make way for new vascular marrow cavities. In this process of bone absorption large cells, osteoclasts, containing, according to v. Kölliker who first described them, from one to sixty nuclei, play a chief part (Fig. 223, B). These osteoclasts vary in size, being from 43 to 91 μ long, 30 to 40 μ wide, and 16 to 17 μ thick. They apparently have the power of dissolving bone or calcified cartilage. The depressions which they cause in bone are called Howship's lacunæ. According to Kölliker, they arise from osteoblasts, and may again divide up into osteoblasts or after remaining for a greater or less length of time in the bone marrow they may disappear. The nuclei within the cell multiply by direct division. The changes of form which bones undergo through the process of growth by apposition of new layers of bone to pre-existing layers and the absorption of bone previously laid down are well illustrated by comparing the jaw of the infant with that of the adult (Fig. 224, C).

Under the term Sharpey's fibres, according to Retterer (1906), several distinct structures have been described: (*a*) prolongation of the periosteum into the bone; (*b*) granular elastic protoplasmic processes of the lamellar system; (*c*) portions of the bone in which calcium salts have disappeared from the hyaloplasm and fibrous tissue has been differentiated. The true Sharpey's fibres are probably prolongations of the periosteum left behind as successive layers of bone are differentiated beneath the periosteum.

To this brief description of the general nature of the process of ossification we may add a short account of the special features which characterize intramembranous, subperiosteal, and endochondral types of ossification.

Intramembranous Ossification (Fig. 222, E, Fig. 224).—In this type of ossification bone first appears in the form of a network of spicules interwoven with a network of blood-vessels. Ossification begins at a centre from which it radiates peripherally. As one passes from the centre towards the periphery in the early period of ossification, one finds all stages from fully formed bone to an undifferentiated embryonic connective-tissue syncytium. In ossification in very young embryos the connective-tissue syncytium appears to be directly transformed into bone. The transformation is marked first by the fibrils of the ectoplasm becoming more clearly marked, and then by the appearance of a basophilic substance in the ectoplasm. In older embryos the ectoplasm is, according to Mall (1906), transformed into prefibrous tissue and the

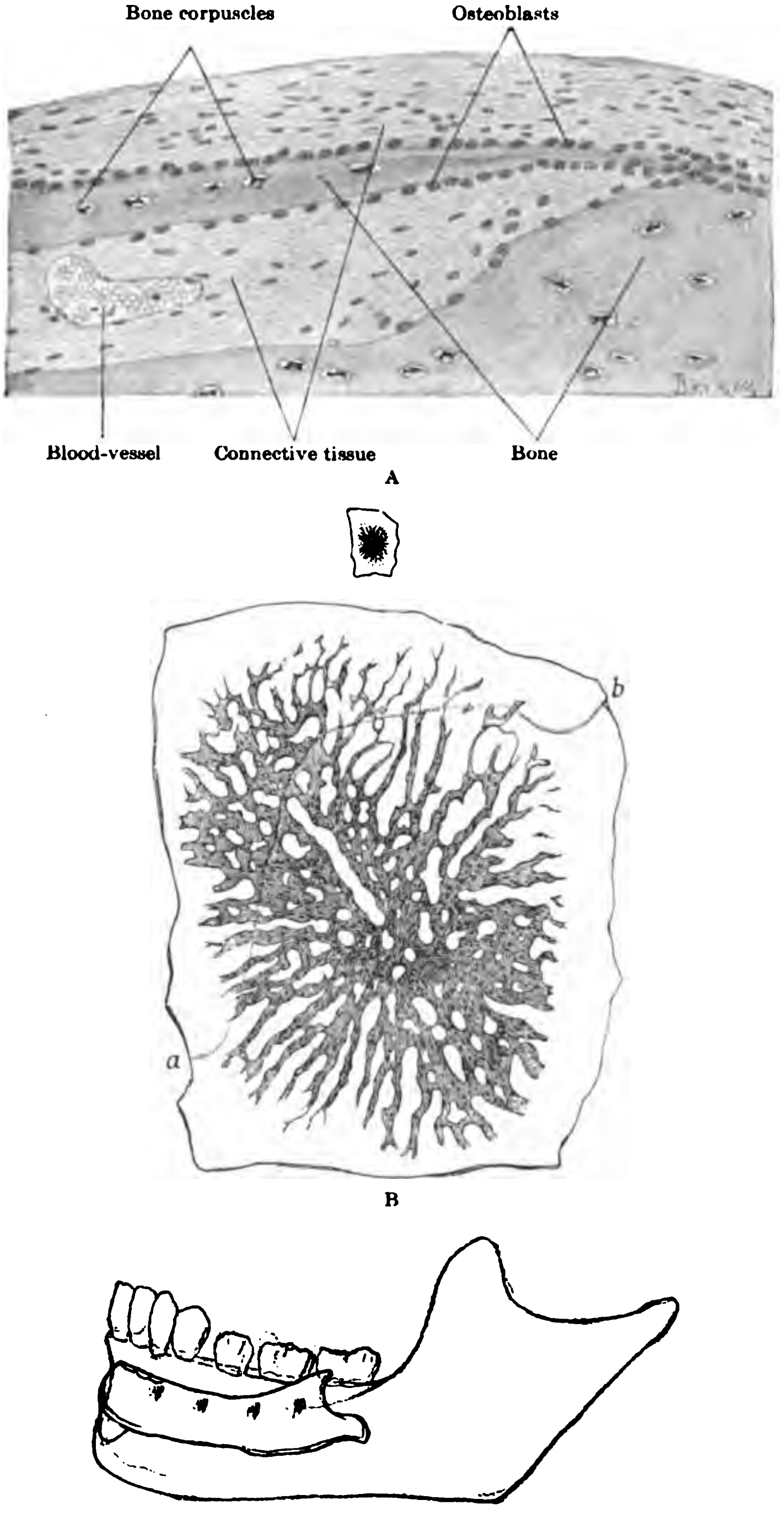

FIG. 224.—A. (After Szymonowicz, Text-book of Histology, trans. by MacCallum, Fig. 199.) From a transverse section of the parietal bone of a human fetus. B. (Quain, after Sharpey, Quain's Anatomy, 10th ed., vol. 1, Pt. 2, Fig. 308.) Parietal bone of a fetal sheep. Size of fetus 2½ in. Magn. about 12 : 1. *a*-*b*, height of subjacent cartilaginous lamina. C. (After Kölliker, Gewebelehre, Fig. 271.) Mandible of a new-born infant, contrasted with that of an adult.

latter is transformed into bone. The diameter of the embryonic bone corpuscles, according to v. Kölliker, varies from 13 to 22 μ.

The primitive plexiform bone is thickened by deposit of osseous substance beneath the periosteum. The latter appears soon after bone-formation has commenced. The spaces in the plexiform network of bone at an early stage become converted into canals containing blood-vessels and primitive marrow.

In bone of membranous origin cartilage may subsequently be developed beneath the periosteum. Examples of this are to be found in the temporomandibular joint.

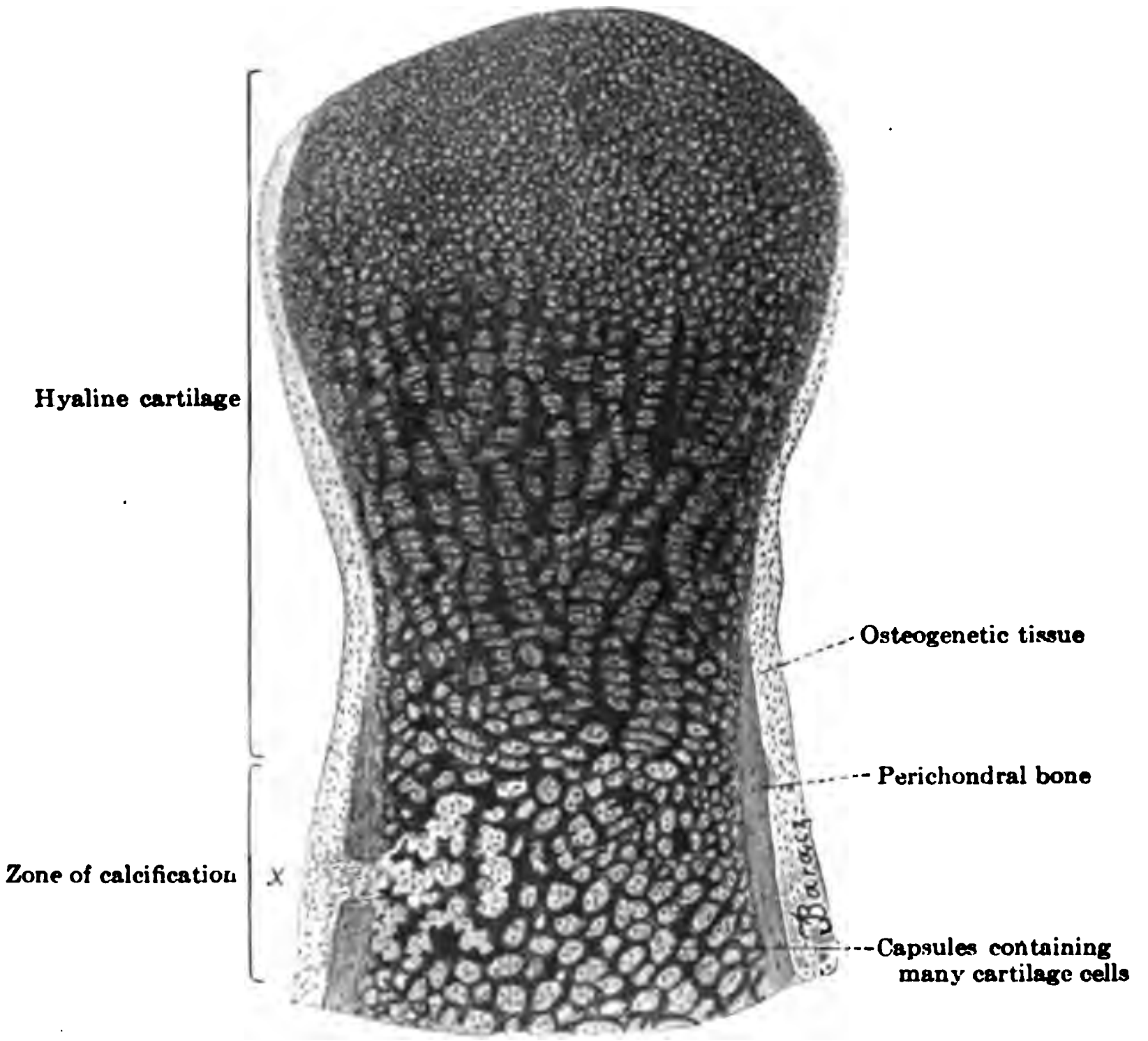

Fig. 225, A.—(After Szymonowicz, Text-book of Histology, translated by MacCallum, Fig. 193.) From a longitudinal section of a finger of a three-and-a-half-months human fetus. Two-thirds of the second phalanx are represented. At X a periosteal bud is to be seen. Magn. about 85 : 1.

Subperiosteal Ossification (Fig. 225, A and B).—Bone is formed in the deep layer of the periosteum (perichondrium) essentially as bone is formed in membrane which is not closely applied to cartilage. The bone formed beneath the periosteum has at first a coarse plexiform structure. The meshes of the osseous framework enclose vascular embryonic marrow. As mentioned above, dense subperiosteal lamellæ are formed in human long bones in the first year after birth, according to Kölliker (Gewebelehre), while according to Schwalbe they are not formed until the fourth year. Subperiosteal ossification is the sole method of substitution of osseous for cartilaginous tissue in some of the bones (in the ribs, for example), while in others it is closely associated with endochondral ossification (diaphyses of the long bones). When it is the sole method of ossification, the underlying cartilage frequently undergoes changes similar to those preceding endochondral ossification (see below).

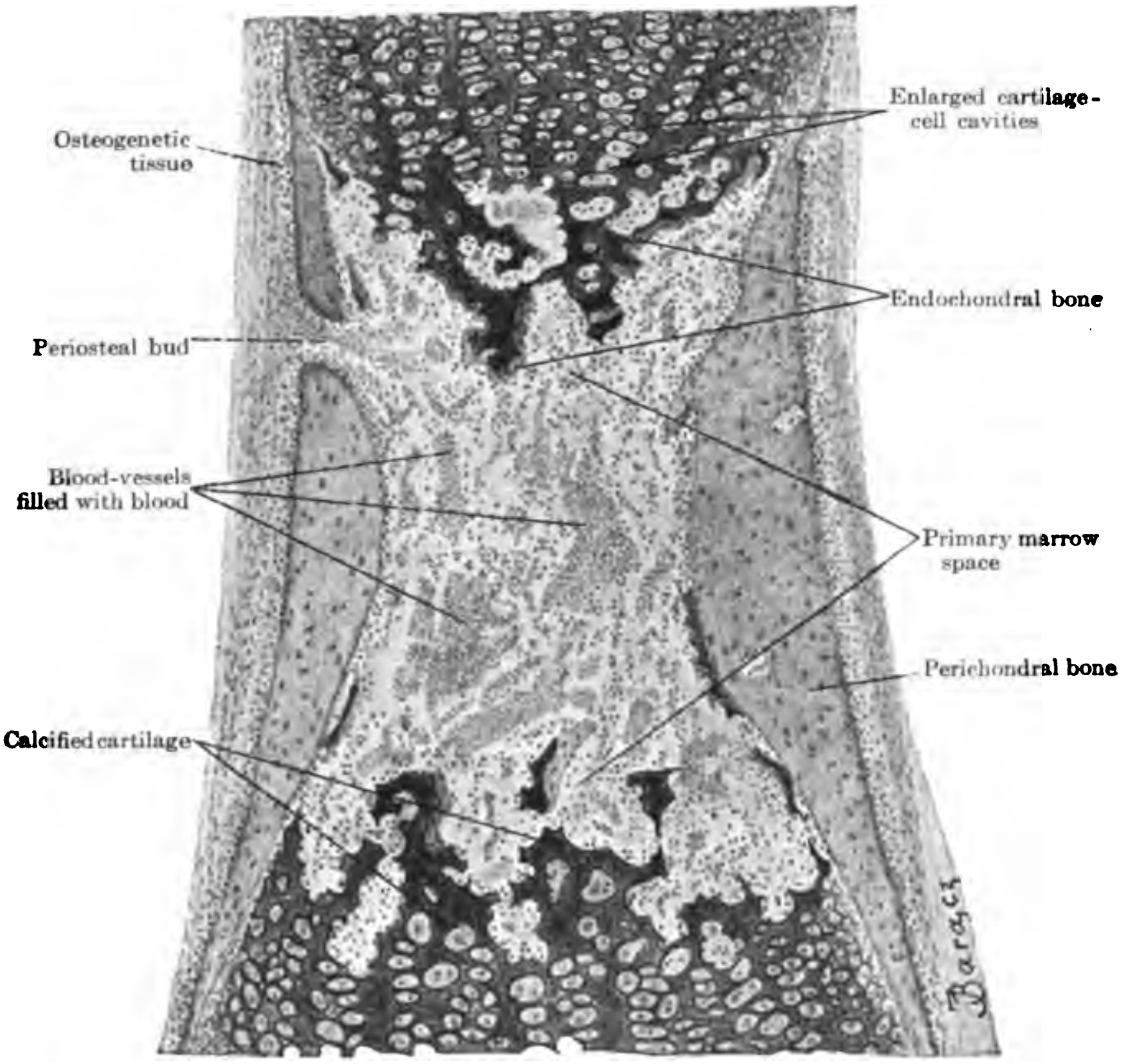

Fig. 225, B. — (Afer Szymonowicz, Text-book of Histology, translated by MacCallum, Fig. 195.) From a longitudinal section of a finger of a four-months human fetus. Only the diaphysis of the second phalanx is represented. Magn. about 85 : 1.

Endochondral Ossification. — In endochondral ossification processes from the osteogenic layer of the perichondrium, or periosteum, extend into the substance of the cartilage, and these give rise on the one hand to destructive activities which break down the cartilage and on the other to constructive activities which result in the formation of bone. Endochondral ossification is preceded by well-marked changes in the cartilage (Fig. 225). The cartilage cells first multiply rapidly in number and then enlarge so that the matrix becomes relatively reduced in amount. Neighboring cartilage cells may so expand that the matrix between them disappears. Meanwhile calcium salts are deposited in the matrix in the form of granules which may become confluent. The processes from the periosteum break into the cavities occupied by the cartilage cells, enlarge them, and thus give rise to primary marrow cavities. In the phalanges and other long bones of limited size, the cartilage at the centre of the shaft may be completely absorbed before the endochondral ossification begins. The primitive marrow is vascular and contains an embryonic syncytium not highly differentiated. Osteoblasts and osteoclasts and embryonic connective tissue, however, appear in it at an early stage, fat and marrow cells at a later period. About the primitive marrow cavities bone is quickly laid down and there thus arises spongy endochondral bone. The bone first laid down is later again absorbed during development of the larger central marrow cavities. From the cavities into which the marrow first penetrates it gradually extends into neighboring cartilage-cell spaces. As the osteogenic tissue spreads, the surrounding cartilage undergoes changes similar to those which took place at the primary centre of ossification. Thus, so long as the process of ossification continues, the cartilage farthest removed from the centre of ossification shows the least modification from the type of primitive hyaline cartilage, while as one passes toward the centre of ossification one finds the successive changes of cell multiplication, cell expansion, and calcification of the matrix. In long bones these successive stages are especially well marked. The multiplication of cartilage cells gives rise to groups which become arranged in long columns which are parallel to the long axis of the bone. The boundary between the zone of ossification and that of the highly modified cartilage is usually fairly sharp (Fig. 225, B). Capillary loops extend close to the limit of the advancing ossification. The extremities of these loops are often dilated.

The fate of the cartilage cells in the calcified matrix is still in dispute. Most modern investigators, including Kölliker (Gewebelehre, 1889), seem to follow Sharpey and Lovén in concluding that the cartilage cells are destroyed as osteogenic tissue derived indirectly from the periosteum enters the cell spaces. Numerous accurate observers, however, among who may be mentioned H. Müller (1859), Ranvier (1865), and Retterer (1900), believe that the cartilage cells become converted into osteogenic tissue, each cartilage cell giving rise to several smaller cells and to reticular tissue. The old view, that cartilage may become directly converted into bone, seems to have few modern adherents.[4]

---

[4] According to Strelzoff (1873), this metaplasia is constant in some regions, for example, in the lower jaw of human embryos.

In epiphyses centres of ossification arise at a comparatively late period. Blood-vessels, which spring from the periosteum and from the bone marrow, penetrate into the epiphyseal cartilage long before ossification begins. Friedländer (1904) gives good pictures of the blood-vessels in the epiphyseal cartilages of the long bones. In some cartilages the blood-vessels appear in the third fetal month. In the seventh all the larger cartilaginous areas show rich vascular plexuses.

Growth of Bone.—The question as to whether or not there is an interstitial growth of bone has given rise to extensive investigations. The evidence is fairly conclusive that there is no well-marked interstitial growth in bone. Hales, Duhamel, John Hunter, and others showed, during the eighteenth century, that two pegs driven into a bone do not move apart during development unless there is a non-ossified region between the two pegs. Z. G. Strelzoff (1873), however, brought forward a certain amount of evidence to show that under some circumstances there may be a slight interstitial growth of bone.[5] Experiments made with madder go to show that growth of bone takes place entirely by apposition. Madder stains newly forming bone, and by feeding it to young animals the successive applications of layers of bone may be followed. Experiments along this line were first performed by Duhamel and J. Hunter. Duhamel also showed that a ring placed on the outside of a long bone of a young animal may eventually be found in the marrow cavity.

Regeneration.—In case of fractures union is effected by osteoblasts which give rise to new bone which unites the broken ends. These osteoblasts in young animals may apparently be derived either from the marrow or from the periosteum, but in the adult chiefly, if not wholly, from the periosteum. Bonome (1885) has, however, brought forward evidence to show that the bone corpuscles in certain conditions where they are supplied with abundant nutrient blood may give rise to osteoblasts. Not infrequently temporary cartilage is produced in places at the site of the fracture. In man fibrous tissue is often produced if the broken ends of the fractured bone are not closely approximated. The experiments of Ollier and others have shown that the bone-forming power of the periosteum may be exercised even when this is transplanted into the tissues at some distance removed from any bone. If the periosteum is preserved it has the power of restoring in nearly normal form large parts of bone.

---

[5] See also Egger (1885) and J. Wolff (1885).

ADDENDUM.

Since the preceding section on the development of the connective tissues was written, there have appeared several important articles on the development of the connective tissues in mammals. *Fr. Merkel* (1909) brings forth new evidence in favor of the intercellular origin of the connective-tissue fibrils. He pays particular attention to the development of limiting membranes which in places sharply mark off epithelium from the underlying connective tissue. These membranes, according to *Merkel,* arise from the connective-tissue matrix independently of the connective-tissue cells. They may become fibrillated. Similar non-cellular connective-tissue substances are formed at an early stage in the septa between myotomes, and later between muscle cells of various types and in lamellated connective tissues. The sarcolemma of striated muscle cells has a similar origin, according to *Merkel. Disse* (1909), on the other hand, describes the osteogenetic tissue as arising from the cell protoplasm. Each osteoblast becomes divided into two parts, a perinuclear granular portion and a peripheral, usually basilar, hyaline portion. The hyaline substance derived from osteoblasts fuses to form a mass in which fibrils differentiate after the hyaline substance is separated from the perinuclear protoplasm. *Bell* (1909) gives a clear description of the development of adipose tissue. He supports the view of the histogenesis of the connective tissues adopted by Mall.

BIBLIOGRAPHY.

(On the development of the connective tissues, with especial reference to man.)

AEBY, C. L.: Uber die Symphysis ossium des Menschen nebst Beiträgen zur Lehre vom hyalinen Knorpel und seiner Verknöcherung. Zeitschr. f. rat. Med. Bd. 4. 1858.

ASKANAZY, M.: Uber das basophile Protoplasma der Osteoblasten, Osteoklasten und anderer Gewebszellen. Centralbl. f. allg. Pathol. usw. Bd. 13, S. 369–378. 1902.

BARDEEN, C. R., and LEWIS, W. H.: Development of the Limbs, Bodywall, and Back in Man. Amer. Journ. of Anat. Vol. 1. 1901.

BÉCLARD: Uber die Osteose, oder die Bildung, das Wachstum und die Altersabnahme der Knochen des Menschen. Meckel's Arch. Bd. 6, S. 405–446. 1820.

BELL, E. T.: I. On the Occurrence of Fat in the Epithelium, Cartilage, and Muscle Fibres of the Ox. II. On the Histogenesis of the Adipose Tissue of the Ox. Amer. Journ. of Anat. Vol. 9, p. 401. 1909.

BIDDER, ALF.: Osteobiologie. Arch. f. mikr. Anat. Bd. 68, S. 137–213. 1906.

BOLK: Die Segmentaldifferenzierung des menschlichen Rumpfes und seiner Extremitäten. III. Beiträge zur Anatomie und Morphogenese des menschlichen Körpers. Morphol. Jahrb. Bd. 27. 1899. IV. Ebenda, Bd. 28. 1899.

BOLL: Untersuchungen über den Bau und die Entwicklung der Gewebe. Zweite Abteilung: Die Entwicklung des fibrillären Bindegewebes. Arch. f. mikr. Anat. Bd. 8, S 28. 1872.

BONOME, A.: Zur Histogenese der Knochenregeneration. Virchow's Arch. Bd. 100. 1885.

BRÖSIKE, G.: Uber die sogenannten Grenzscheiden des Knochenkanalsystems, nebst Bemerkungen über die Keratinsubstanzen. Arch. f. mikr. Anat. Bd. 26. 1885.

BRÜNING, FR.: Uber das Auftreten des Fettes im Knochenmark in den ersten Lebensjahren. Diss. Freiburg i. Br. 1903.

COCA, ARTH. F.: Die Bedeutung der Fibroglia-Fibrillen. Eine embryologische Studie. Virchow's Arch. Bd. 186. 1906.

DISSE, J.: Die Entstehung des Knochengewebes und des Zahnbeines. Arch. f. mikr. Anat. Bd. 73, S. 563–606. 1909.

Ebner, V.: Uber den feineren Bau der Knochensubstanz. Sitzungsberichte der Kais. Akademie der Wissenschaften. Wien. Bd. 72, S. 49. 1875.

Sind die Fibrillen des Knochengewebes verkalkt oder nicht? Arch. f. mikr. Anat. Bd. 29. 1887.

Egger, G.: Experimentelle Beiträge zur Lehre vom interstitiellen Knochenwachstum. Virchow's Arch. Bd. 99. 1885.

Fibich, R.: Beitrag zur Kenntnis der Histologie des hyalinen Knorpels. Anat. Anz. Bd. 24, S. 209–214. 1904.

Flemming, W.: Zur Entwicklungsgeschichte der Bindegewebesfibrillen. Internat. Beiträge zur wissensch. Medizin. Virchow's Festschrift, Berlin, 1891.

Uber die Entwicklung der collagenen Bindegewebesfibrillen bei Amphibien und Säugetieren. Archiv. f. Anat. u. Physiol. S. 171. 1897.

Die Histogenese der Stützsubstanzen der Bindegewebsgruppe. Hertwig's Handb. d. vgl. Entwicklungsgesch. 1906, erschienen 1902.

Friedländer, Friedr. v.: Beitrag zur Kenntnis der Architektur spongiöser Knochen. Anat. Hefte. Bd. 23, Heft. 72. 1904.

Fromm, Wald.: Beitrag zur Kasuistik der kongenitalen Knorpelreste am Halse. Diss. München 1904. (Literatur. 63 Fälle.)

Froriep, A.: Kopfteil der Chorda dorsalis bei menschlichen Embryonen. Festschr. f. Henle. 1882.

Garmaschew, W. P.: Veränderungen des Knochenmarks während des Wachstums. Diss. St. Petersburg, 1902. (Russisch.)

Gegenbaur, C.: Uber die Bildung des Knochengewebes. Jen. Zeitschr, f. Med. u. Naturw. Bd. 1, S. 343-369. 1864; Bd. 3, S. 206–246. 1867.

Geipel, P.: Uber elastisches Gewebe beim Embryo und in Geschwülsten. Centralbl. f. allg. Pathol. usw. Bd. 17, Nr. 14. 31. Juli 1906. Cf. Nakai, Virchow's Arch. Bd. 182. 1906. (Man and fowl.)

Golowinski, J.: Zur Kenntnis der Histogenese der Bindegewebsfibrillen. Anat. Hefte. 1. Abt. Bd. 33. 1907.

Grandis e Copello: Studi sulla composizione chimica delle ceneri delle cartilagini in relazione col processo di ossificazione. Arch. Sc. Med., p. 175–183. Vol. 26. 1902.

Grekow, A. W.: Uber die morphologischen Veränderungen bei Röhrenknochen im Verlaufe des Kindesalters. Diss. St. Petersburg. 1903. (Russian.)

Hammar, J. A.: Zur Kenntniss des Fettgewebes. Arch. f. mikr. Anat. Vol. 45. 1895.

Hansen, C. C.: Uber die Genese einiger Bindegewebsgrundsubstanzen. Anat. Anz. Bd. 16, S. 147. 1899.

Heller, G.: Beiträge zur Histogenese der elastischen Fasern im Netzknorpel und Ligamentum nuchae. Monatsschr. f. prakt. Dermat. Bd. 14, S. 217–237. 1892.

Hertwig, O.: Uber die Entwicklung und den Bau des elastischen Gewebes im Netzknorpel. Arch. f. mikr. Anat. Bd. 9, S. 80. 1873.

Horwitz, K.: Uber die Histologie des embryonalen Knochenmarkes. Wien. med. Wochenschr. Jg. 54, S. 1449–1453, 1499–1503, 1544–1547, 1582–1584, 1631 bis 1634. 1904.

Hugonnenq: Sur la fixation des bases alcalines dans le squelette minéral du foetus pendant les cinq derniers mois de la grossesse. C. R. Acad. Sc. Paris. T. 130, p. 941. 1900.

Kassowitz, M.: Die normale Ossifikation usw. Stricker's med. Jahrb. 1879–1880.

Kölliker, A.: Die normale Resorption des Knochengewebes und ihre Bedeutung für die Entstehung der typischen Knochenformen. Leipzig 1873.

Zur Entwicklung des Fettgewebes. Anat. Anz. Bd. 1, S. 206–208. 1886.

Koller, H.: Ist der bindegewebig vorgebildete Knochen imstande, Knorpel zu bilden? Arch. f. Entwicklungsmechanik. Bd. 3. 1892.

Kollmann, J.: Die Entwicklung der Chorda dorsalis beim Menschen. Anat. Anz. Bd. 5. 1890.

Die Rumpfsegmente menschlicher Embryonen von 13–35 Urwirbeln. Arch. f. Anat. u. Physiol., Anat. Abt. 1891.

Korff: Uber die Entwicklung der Zahnbein- und Knochengrundsubstanz der Säugetiere. Anat. Anz. Ergh. S. 132. 1906.

Kuskow, N.: Beiträge zur Kenntnis der Entwicklung des elastischen Gewebes. Arch. f. mikr. Anat. Bd. 30, S. 32–38. 1887.

Laguesse, E:. Sur l'histogénèse de la fibre collagène et de la substance fondamentale dans la capsule de la rate chez les sélaciens. Arch. d'Anatomie microscop. Vol. 6, p. 99. 1903.

Landois, L.: Untersuchungen über die Bindesubstanz und den Verknöcherungsprozess derselben. Zeitschrift f. Zool. Bd. 16, S. 1–26. 1866.

Leboucq, H.: Etudes sur l'ossification. Evolution du Cartilage embryonnaire chez les mammifères. Bull. Acad. Roy. Belg. Vol. 14, p. 457–459. 1877.

Leser, E.: Uber histologische Vorgänge an der Ossificationsgrenze, mit besonderer Berücksichtigung des Verhaltens der Knorpelzellen. Arch. f. mikr. Anat. Bd. 32, S. 214–222. 1888.

Loisel, G.: Formation et évolution des élements du tissu élastique. Thèse de Paris 1896.

Löwe, L.: Uber die Umwandlung der Osteoklasten im Knochenmark, nebst Bemerkungen über Knochenwachstum. Arch. f. mikr. Anat. Bd. 16, S. 618–626. 1879.

Lwoff: Uber die Entwicklung der Fibrillen des Bindegewebes. Sitz.-Ber. d. Wiener Akad. d. Wiss. M.-N. Kl. Bd. 98, Abt. 3, S. 184. 1889.

Mall, F.: Das retikulierte Gewebe und seine Beziehungen zu den Bindegewebesfibrillen. Abhandl. d. K. Sächs. Gesellsch. d. Wiss. Bd. 17. 1891.

The Development of the Connective Tissues from the Connective Tissue Syncytium. Amer. Journ. Anat. 1902.

Masuoka: Die Regeneration des Knorpelgewebes. Virchow's Arch. Bd. 175. 1904.

Merkel: Zur Histogenese des Bindegewebes. Verhandl. d. anatom. Gesellschaft, Basel. S. 45. 1895.

Betrachtungen über die Entwicklung des Bindegewebes. Anat. Hefte, Bd. 38, S. 321. 1909.

Müller, Heinr.: Uber die Entwicklung der Knochensubstanz nebst Bemerkungen über den Bau rachitischer Knochen. Zeitschr. f. wiss. Zool. Bd. 9, S. 147–233. 1859.

Uber Verknöcherung. Eine Erwiderung an N. Lieberkühn. Würzburger naturw. Zeitschr. Bd. 4. 1863.

Nakai, Motokichi: Uber die Entwicklung der elastischen Fasern im Organismus und ihre Beziehungen zu der Gewebsfunktion. 1 Taf. Virchow's Arch. Bd. 182, S. 153. 1905.

Neumann: Beiträge zur Kenntnis des normalen Zahnbein- und Knochengewebes. Leipzig 1863.

Nicolas, A.: Développement et structure des os. Traité d'Anatomie humaine par Poirier et Charpy. I. Paris 1899.

Ollier: Du Perioste, 1865. Traité de la régéneration des os. 2 volumes. Paris 1867.

Pacchioni, D.: Untersuchungen über die normale Ossifikation des Knorpels. Jahrb. f. Kinderheilk. Bd. 26, S. 327–340. 1902.

Pommer, G.: Uber die Osteoklastentheorie. Virchow's Arch. Bd. 92. 1883.

Rabl, C.: Theorie des Mesoderms. Morph. Jahrb. Bd. 15. 1889.

Rambaud et Renault: Origine et développement des os. Paris 1864.

Ranvier, L.: De quelques points relatifs à préparation et aux proprietés des cellules du cartilage. Journal de la physiol. T. 6, p. 577. 1865.

Quelques faits relatifs au développement du tissu osseux. C. R. Acad. Sc. Paris. Vol. 77, p. 1105–1109. 1873.

Nouvelles recherches sur la structure et le développement des tendons. Arch. de Physiol. Vol. 6, p. 181–202. 1874.

Développement du tissu conjunctif. Traité technique d'Histologie, p. 405–409. 1875.

Renaut, J.: Sur la formation cloisonnante du cartilage hyalin foetal. C. R. Acad. Sc. Paris. T. 104, p. 1452–1455. 1887.

Sur la tramule du tissue conjunctive. Arch. Anat. Microsc. T. 6, p. 1. 1903.

Retterer, Ed.: Les découvertes récentes relatives au développement du tissu conjunctif. Journ. de l'Anat. et de la Physiol. Année 28, 1892, p. 211.

Sur le développement des cavités closes tendineuses et des bourses muqueuses. C. R. de la Soc. de Biol., Sér. 10. T. 2. 1895.

Sur le développement morphologique et histologique des bourses muqueuses et des cavités péritendineuses. Journ. de l'Anat. et de la Physiol. Année 22, p. 256. 1896.

Similitude des processus histogénétiques chez l'embryon et l'adulte. Journ. de l'Anat. et de la Physiol. Année 36, p. 358. 1900.

Evolution du cartilage transitoire. Journ. de l'Anat, et de la Physiol. Année 36, p. 467–565. 1900.

Structure et évolution du tégument externe. Journ. de l'Anat. et de la Physiol. Année 30, p. 337. 1904.

Structure et histogenèse de l'os. Journ. de l'Anat. et de la Physiol. Année 41. 1905.

Histogenèse des tissus fibreux et fibrocartilagineux. C. R. Soc. Biol. Paris. T. 58, p. 240–243. 1905.

Evolution du tissu osseux. Journ. de l'Anat. et de la Physiol. Année 42, p. 193 bis 238. 1906.

Des éléments qui servent à la croissance et à la rénovation du derme, etc. Journ. de l'Anat. et de la Physiol. Année 42, 1906.

De l'ostéogenèse et du développement variable des éléments de la substance osseuse. Compt. rend. Soc. Biol. Vol. 64. 1908.

De l'ossification infracartilagineuse ou enchondrale. Compt. rend. Soc. Biol. Vol. 64. 1908.

Rollett, A.: Entwicklung des Bindegewebes. Stricker's Handbuch. Bd. 1, S. 61, 1871.

Uber die Entwicklung des fibrillären Bindegewebes. Unters. Inst. f. Phys. u. Histolog. Graz. S. 257–265. 1873.

Salvioli, I.: Contributo allo studio dell' accrescimento del tessuto connettivo. Arch. per le Sc. Med. Torino. Vol. 13, p. 281–290. 1889.

Schultze, O.: Uber embryonale und bleibende Segmentierung. Verh. d. Anat. Ges. 1896.

Schwalbe, G.: Uber das postembryonale Knochenwachstum. Sitzungsberichte der medizin.-naturwiss. Gesellschaft zu Jena 1877. Schwalbe's Jahresbericht. Bd. 6, S. 73. 1877.

Schwegel: Die Entwicklungsgeschichte der Knochen des Stammes und der Extremitäten. Sitz.-Ber. d. Akad. Wien. math.-phys. Kl. Bd. 30. 1858.

Sharpey: Quain's Anatomy, 5th Ed. 1846.

Solger, B.: Uber pericelluläre und intercelluläre Ablagerungen im Hyalinknorpel. Arch. f. mikr. Anat. Bd. 34, S. 408–428. 1889.

Ueber Knorpelwachstum. Verh. anat. Ges. Berlin, III. S. 67–71. 1889.

Spalteholz, W.: Uber die Beziehungen zwischen Bindegewebsfasern und Zellen. Anat. Anz. Ergh. Bd. 29. 1906.

Spina: Untersuchungen über die Bildung der Knorpelgrundsubstanz. Sitzb. Wien. Akad. Bd. 81, S. 28–39. 1880.

Spuler, A.: Beiträge zur Histologie und Histogenese der Binde- und Stützsubstanz. Anat. Hefte. Bd. 7. 1897. Also Erlanger Habilit.-Schrift.

Stieda, Ludw.: Die Bildung des Knorpelgewebes. Leipzig 1872.

Studien über die Entwicklung der Knochen und des Knochengewebes. Arch. f. mikr. Anat. Bd. 11. 1875.

Strelzoff, Z. G.: Uber die Histogenese der Knochen. Unters. a. d. path. Inst. zu Zürich. Herausgegeben von C. J. Eberth, Leipzig. 1873.

Stricker: Uber die Bindesubstanzen im Allgemeinen und über die Gewebsentwicklung im Centralnervensystem. Anz. Ges. d. Arzte Wien. S. 41–46, 48–52. 1879.

Srdinko, O. V.: Beitrag zur Histologie des Knorpels. Anat. Anz. Bd. 22, S. 437 bis 446. 1903.

Studnicka, F. K.: Uber kollagene Bindegewebsfibrillen in der Grundsubstanz des Hyalinknorpels, im Dentin und im Knochengewebe. Anat. Anz. Bd. 29, S. 334. 1906.

Szily, Aurel v.: Uber das Entstehen eines fibrillären Stützgewebes im Embryo und dessen Verhältnis zur Glasköperfrage. Anat. Hefte. Bd. 35, S. 649–758 (literature). 1908.

Triepel, H.: Die Anordnung der Knochenfibrillen in transformierter Spongiosa. Anat. Hefte. Bd. 33, S. 49. 1907.

Virchow: Uber die Identität von Knochen-, Knorpel- und Bindegewebskörperchen, sowie über Schleimgewebe. Verhandl. der Würzburger phys. med. Gesellschaft. Bd. 2, S. 150 und S. 314. 1852.

Waldeyer, W.: Uber den Ossifikationsprozess. Arch. f. mikr. Anat. Bd. 1, S. 354–374. 1865.

Uber Bindegewebszellen. Arch. f. mikr. Anat. Bd. 11, S. 176–194. 1874.

Kittsubstanz, Grundsubstanz, Epithel und Endothel. Arch. f. mikr. Anat. Bd. 57, 1901.

Welker, H.: Uber Wachstum und Bau des menschlichen Schädels. Leipzig 1862.

Winhold, H.: Uber das Vorkommen von Megaloblasten im Knochenmark. Diss. Leipzig 1901.

Wolff, J.: Das Gesetz der Transformation der Knochen. Berlin 1885.

Uber die Theorie des Knochenschwundes durch vermehrten Druck und der Knochenanbildung durch Druckentlastung. Arch. f. klin. Chir. Bd. 13, S. 302 bis 324. 1891.

PART II.

Morphogenesis of the Skeletal System.

A. GENERAL FEATURES.

The definitive skeletal system is composed of bones and cartilages united to one another at joints by means of ligaments. In the lowest vertebrates a cellular rod, the chorda dorsalis or notochord, situated in the mid-axial line ventral to the central nervous system, constitutes the chief part of the axial skeleton. In the higher vertebrates a chorda dorsalis is also formed during early embryonic development, though in mammals and man it lends little or no skeletal support to the embryo and mere derivatives of it are to be found in the adult. The definitive skeleton of the higher vertebrates, including man, is differentiated from the mesenchyme of the head, trunk, and limbs. The process of differentiation is somewhat complex. As a rule, the first visible step in the process is marked by condensation in the sclerogenous mesenchyme or scleroblastema. Thus, in the development of the skeleton of the inferior extremity, condensation begins in the vicinity of the future hip-joint and from here extends distally and proximally, so that there is produced a continuous mass of condensed tissue in which pelvic, femoral, tibio-fibular, and tarsal regions and five metatarso-phalangeal rays may be distinguished. The hard parts of the skeleton are developed from centres which appear in the scleroblastema. The joints are developed in the scleroblastema which intervenes between the hard parts.

THE BONES.

It has been mentioned in the section on histogenesis that most of the bones of the body are first formed of cartilage and then, during subsequent development, bone is gradually substituted for cartilage, substitution or cartilaginous bones (Figs. 277 and 278). Other bones are formed directly in the membranous scleroblastema, membrane or investment bones. The bones of the extremities, with the partial exception of the clavicle, the bones of the spinal column and thorax, and the greater part of those of the base of the cranium, have a chondrogenous origin. The greater part of the bones of the cranial vault and of the face arise directly in the scleroblastema.

It is to be noted, however, that during the formation of many of the typical substitution bones ossification may extend into membranes attached to the cartilage, so that certain processes on these bones are membranous in origin, and that, on the other hand, certain parts of bones of membranous origin may secondarily give rise to cartilage (temporomandibular joint). Several of the definitive bones of the skull have an origin partly cartilaginous, partly membranous.

SUBSTITUTION BONES.

As a rule, a centre of chondrification appears in the midst of condensed scleroblastema. (See femur, tibia, and fibula, Fig. 275.) It may, however, appear in tissue but slightly condensed, as in case of the vertebral bodies, Fig. 273.

The cartilaginous centres expand rapidly, both by apposition from the surrounding blastema and by interstitial growth. Neighboring centres are thus soon brought into close approximation. Some of the centres fuse with one another in the region of approximation. Between other centres joints are developed. The fate of the cartilaginous centres, therefore, differs considerably in different regions.

The conditions in the *skeleton of the limbs* are the simplest. Here for each of the bones, including the pubis, ischium, and ilium, there is a single centre of chondrification (see Fig. 226 and Figs. 275 and 276). The clavicle forms an exception to the other bones in that the tissue at the centre of chondrification is not converted into typical embryonic hyaline cartilage (see pp. 380 and 388). The centres of chondrification for the pubis, ischium, and ilium soon fuse with one another so as to produce a continuous cartilaginous hip-bone, which gradually assumes definitive form (Figs. 276, 277, and 278). With the exception of a few cartilages in the wrist, the fate of which is treated elsewhere (p. 383), each of the other embryonic limb cartilages undergoes an independent development. In the region of the knee-joint, however, and possibly in some other articular regions of the limbs, independent skeletal elements become at an early period temporarily fused together by a kind of precartilage (Fig. 283). Temporary joints of this kind resemble the permanent joints of the shark's fin.

A centre of ossification appears in the main body of each of the cartilages of the skeleton of the limbs; in most of them early in fetal development, but not until after birth in those of the ankle and wrist, with the exception of the calcaneus, talus and cuboid and in the patella and other sessamoid bones. These chief centres of ossification establish bone in place of cartilage as growth proceeds. In case of all the limb bones except those of the ankle and wrist secondary epiphyseal centres of ossification appear early in childhood in those portions of the bone still cartilaginous, and as maturity is approached become fused with the main part of the bone. Growth in length of bone, as stated in the section on histogenesis (p. 311), is dependent upon the growth of the cartilaginous matrix and ceases when the epiphyses become fused with the main body of the bone. In the adult limb skeleton the only cartilage remaining is that upon the joint surfaces of the bones.

In the *vertebral column* there are two bilaterally placed centres of chondrification for the body of each vertebra and one for each half arch (Figs. 239 and 249). The arch cartilages join the body considerably before they unite dorsally so as to complete the arch about the spinal cord. The *ribs* develop from separate centres of chondrification and do not fuse with the bodies. In the cervical, lumbar, and sacral regions there are more or less distinct centres of chondrification of costal elements which quickly fuse with the cartilage of the body. In the sacral region the various cartilages fuse to form a cartilaginous sacrum. The cartilaginous vertebral bodies are at first separated by thick blastemal discs, but as development proceeds the discs near the centre become thin and partially converted into a precartilaginous tissue, so that for a brief period there is a continuous vertebral axis composed of tissue of a cartilaginous nature but in which segmentation is clearly marked.

The cartilage of the *sternum* arises mainly from the cartilage of the ribs, from which it is secondarily separated by the formation of costosternal joints.

There are primary centres of ossification for the bodies of the vertebræ, each half arch, the ribs, and some of the costal elements of the sacrum. In addition, there are many epiphyseal centres.

In the *cranial blastema* numerous centres of chondrification appear (Figs. 310 and 311). These, however, fuse to form a continuous chondrocranium, in which no blastemal sutures remain to separate one cartilaginous element from another (Figs. 312 and 313). The incus and stapes remain distinct cartilages. The malleus is long continuous with Meckel's cartilage, the cartilaginous skeleton of the mandibular arch. The cartilage of the hyoid arch becomes attached to the chondrocranium.

While the chondrocranium is being formed, centres of ossification begin to appear in various parts of the cranial scleroblastema. From these centres of ossification, partly by expansion and partly by fusion of neighboring centres, there are produced the membranous bones of the skull (Fig. 321). Meanwhile, centres of ossification appear in the chondrocranium and by expansion and fusion give rise to the substitution bones of the skull. In the definitive skull some bones, like the parietal, frontal, and maxillary, are purely membranous in origin. Some, like the ethmoid, hyoid, incus, and stapes, are fairly typical substitution bones, while many of the bones, like the occipital, sphenoid, and temporal bones, arise partly from centres which appear in membranous tissue, partly from centres which appear in the chondrocranium. In the membranous tissue in which the centres for the investment bones appear the definitive form of the skeletal part is much less clearly marked than in the chondrocranium (compare Figs. 310, 311, 312, 313, 321).

CARTILAGES.

Not all the cartilage of the embryonic skeleton becomes replaced by bones. Some of the embryonic cartilages become reduced to fibrous tissue, as in the case of the stylohyoid ligament; some give origin to the cartilages of the definitive skeleton, such as the costal cartilages and parts of the nasal capsule; some merely disappear.

JOINTS.

When first differentiated the fixed parts of the skeleton are united to one another by dense blastemal tissue in which little definite form is to be observed. In case of synarthroses this intervening blastemal tissue becomes directly or indirectly transformed into fibrous tissue (syndesmosis), into cartilage (synchondrosis), or into bone (synostosis). While, as a rule, the fibrous tissue of a syndesmosis comes fairly directly from the primitive blastema of the embryonic joint, it may arise as the result of retrograde metamorphosis of cartilage (lig. stylohyoideum). A synchondrosis is usually preceded by an embryonic blastemal syndesmosis. A synostosis is usually preceded by a syndesmosis or a synchondrosis.[6]

In a diarthrosis the joint cavity, synovial membrane, and the various ligaments characteristic of the joint are differentiated from the dense blastemal tissue which unites at first the two embryonic cartilages entering into the joint. Disci articulares and menisci articulares are also differentiated from this blastema.

In case of the few diarthroses formed between membrane bones, as for instance between the mandible and the temporal bone, the blastemal tissue has the power of giving rise to cartilage which covers the joint surfaces of the bones.

The various steps in the differentiation of a simple diarthrosis are well illustrated in the digital articulations (Figs. 226–228). In Fig. 226 are shown the cartilaginous anlages (*a*) of the three phalanges and the distal part of the metacarpal of a finger of an embryo 2.7 cm. long. These cartilaginous anlages are embedded in a dense blastema which shows lighter areas in the vicinity of the future joints (*c*). The term intermediate zone has been applied to the dense tissue lying between the two cartilages entering into a joint (*b*). As the cartilages expand they come into close approximation, as shown in the finger of a fetus 7 cm. long (Fig. 227). At this stage the cartilage is undergoing changes preliminary to ossification. The perichondrium about the joint surfaces of the cartilage entering into the joint is very dense. The joint cavity first appears at the periphery of the joint (Fig. 227). Gradually it extends in between the two cartilages entering into the joint and a variable distance over the head toward the shaft (Fig. 228, A, B, C). The form of the joint surfaces of the bones entering into the joint is highly differentiated before the joint cavity appears (Fig. 227).

In the more complex joints in which menisci or intra-articular ligaments are differentiated, as in the knee-joint and hip-joint

---

[6] The nucleus pulposus of the intervertebral fibrocartilage (disc) arises from the tissue of the chorda dorsalis (see p. 341).

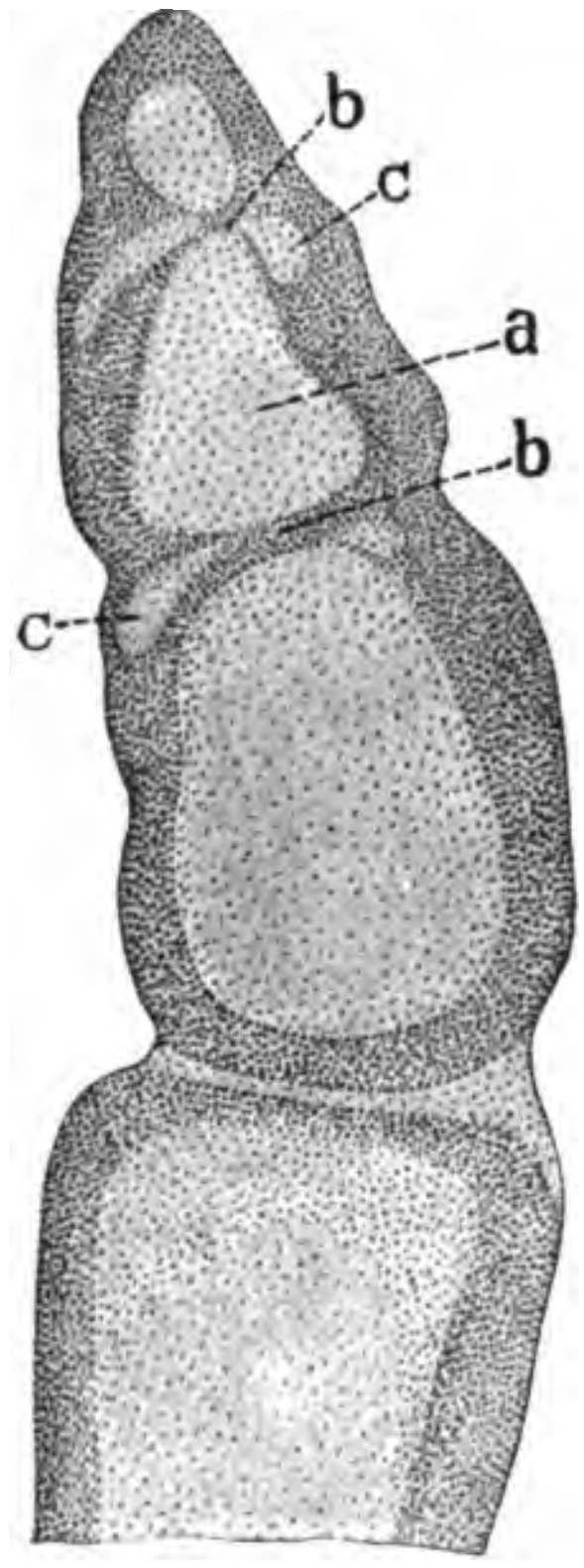

FIG. 226.

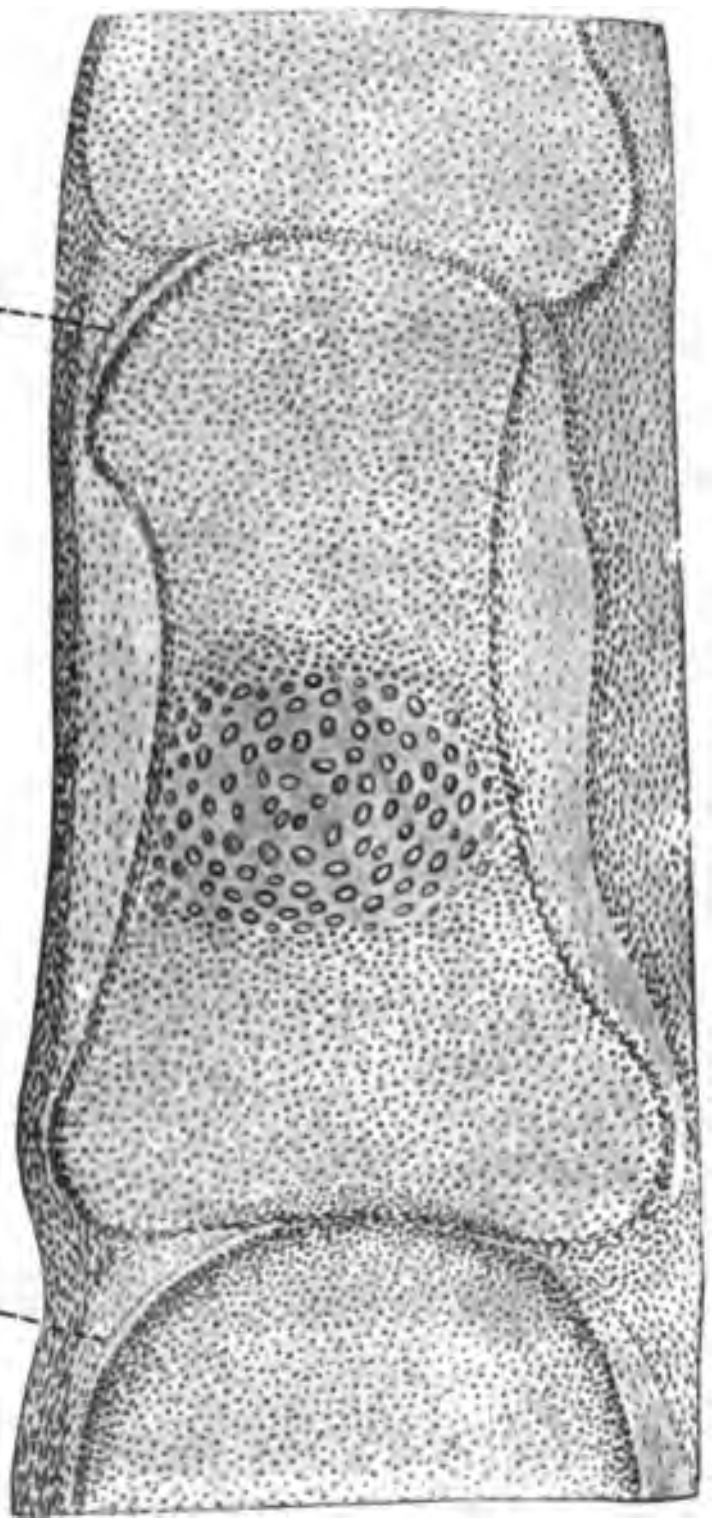

FIG. 227.

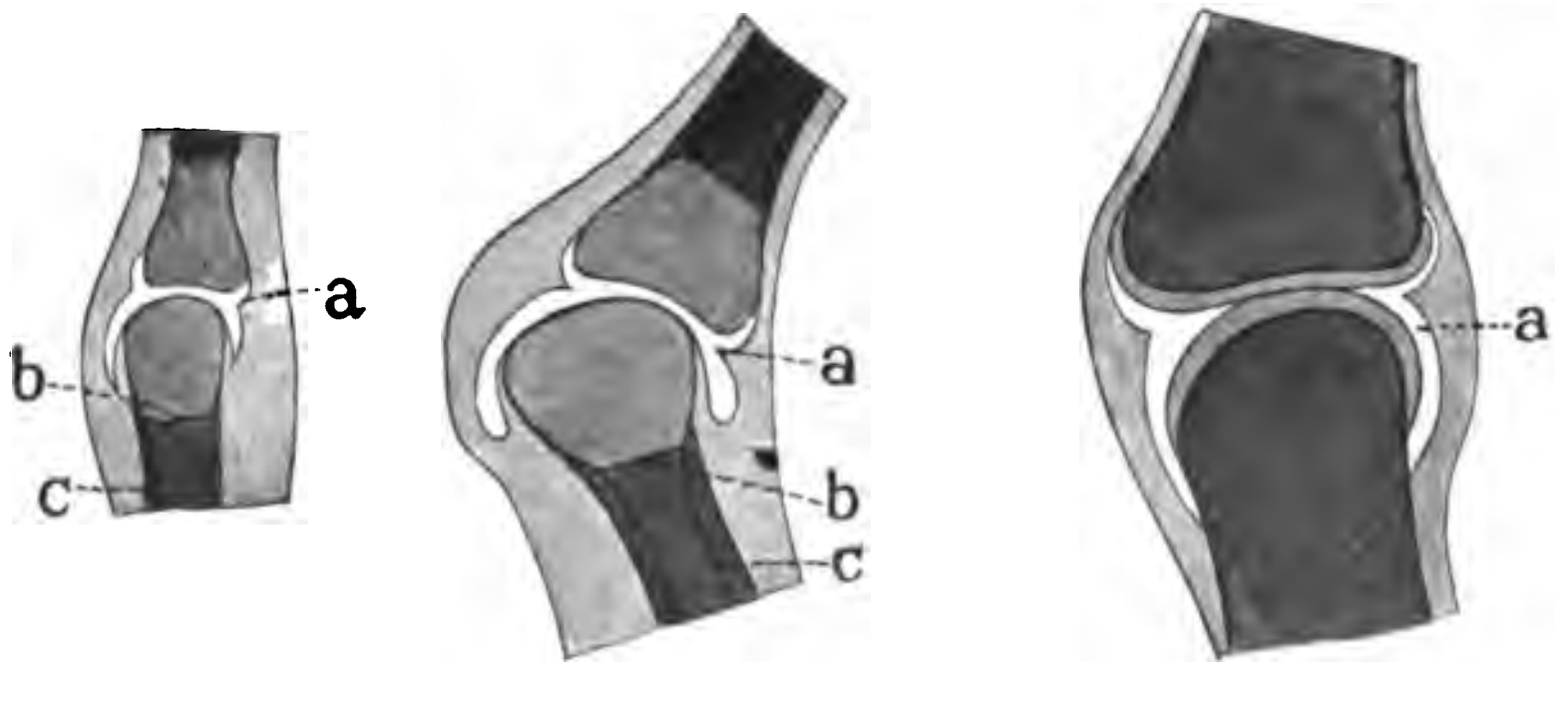

FIG. 228.

FIGS. 226–228.—(After Schulin, Archiv f. Anat. u. Physiol., Anat. Abt., 1879.)

Fig. 226. (Schulin, Fig. 1.) Finger of an embryo 2.7 cm. long. *a*, primordial cartilage; *b*, intermediate zone; *c*, region of loose tissue in preparation for the formation of a joint cavity. Fig. 227. (Schulin, Fig. 2.) Articulation of the second phalanx of the middle finger of a fetus 7 cm. long, with the basal and terminal phalanges. *a*, formation of joint cavity on the dorsal side. Fig. 228. (Schulin, Figs. 4, 5, and 8.) The first interphalangeal joint of the middle finger of a fetus 13 cm. long (A), of a fetus 20 cm. long (B), and of an adult (C). *a*, joint cavity; *b*, epiphyseal cartilage; *c*, bone.

(Figs. 281, 282, 285), the cartilages of the bones entering into the joint are less closely approximated at the time of the formation of the joint cavity than in simple joints, like those of the fingers. The external ligaments and the various intra-articular structures are differentiated directly from the intermediate zone of blastema, while the blastemal tissue next the joint surfaces of the cartilages entering into the joint becomes condensed into a dense perichondrium. The rest of the tissue becomes less dense in character and is converted into mucoid tissue with a few cells scattered through the matrix (Fig. 282). As in all diarthroses the formation of the joint cavity begins at the side and extends toward the centre of the joint. The definitive cavity may be formed by the fusion of several cavities which appear at various places in the periphery of the joint (knee-joint, p. 372). The mucoid tissue disappears as the joint cavity enlarges.

The capsular ligament which is formed from the periphery of the intermediate blastemal zone is continuous on each side of the joint at first with the perichondrium and later with the periosteum. The synovial membrane is formed on the inner surface of the capsular ligament. Synovial villi arise in the latter part of fetal life.

At the time of the appearance of the joint cavity the bones entering into the joint are composed of cartilage in the region of the articulation, although ossification may be well under way at some distance from the articulation (Figs. 227 and 228). After the appearance of the joint cavity the articulating parts undergo an elaboration in form (Fig. 228), which may be quite extensive (Figs. 286, 288). This elaboration of form is due not only to interstitial growth of cartilage, but also to the appositional growth of bone. As the result of the ossification, all the cartilage near the joint becomes entirely replaced by bone except on the joint surface, where, as a rule, a layer of hyaline cartilage remains throughout life. The thin, dense layer of blastemal perichondrium which for a short time covers the joint cartilage, as a rule disappears early, although it may give rise to a permanent film of tissue or the joint cartilage may become in part composed of fibrocartilage (sternoclavicular, temperomandibular, costovertebral, sternocostal articulations).

The relative positions of the articulating bones vary greatly in different regions at the time of the formation of the joints. The knee- and elbow-joints, for instance, are flexed at an angle of about 90° while the wrist-joint is nearly straight.

SESAMOID BONES.

Tendons are closely fused to the joint capsule in many articulations of the extremities. In certain regions where this occurs sesamoid bones are developed. The largest of the sesamoid bones is the patella. Well-marked sesamoid bones are found regularly on the flexor side of the metacarpo- and metatarsophalangeal joints, usually of the first and frequently of the other digits of the hand and foot. Dorsally placed sesamoid bones have also been seen in connection with the thumb. On the flexor surface of the thumb a sesamoid bone is frequently found at the interphalangeal joint. Fibrous interphalangeal sesamoids have been found in connection with the fingers. The sesamoid bones are better developed in some of the lower mammals than in man, and, according to Pfitzner, are more frequent in the human embryo than in the adult. They are developed at the periphery of the intermediate blastemal zone. The blastema becomes condensed, and then in the better marked sesamoid bones becomes gradually transformed into cartilage. Ossification takes place relatively late in childhood. On the intracapsular origin of the sesamoid bones see Bradley (1906).

In some tendons not intimately connected with a joint capsule a sesamoid bone may be developed in a region where the tendon is subjected to stress against a bone about which it turns. An example is the sesamoid bone often found in the tendon of the peroneus longus where this plays over the tuberosity of the cuboid. According to Lunghetti (1906), the sesamoid bone in the tendon of the M. peroneus longus develops in fibrous connective tissue, not in cartilage. It is commonly stated that it passes through a fibrocartilaginous stage before becoming ossified.

VARIATION IN THE DEVELOPMENT OF THE SKELETON.

Variations in the bones of the adult human skeleton are frequent. Thus, for instance, skeletons with only eleven or with thirteen free ribs are not uncommon. Rosenberg, Pfitzner, Thilenius, and others would ascribe some of the variations found in the adult skeleton to the chance persistence of transitory conditions normally present in the embryonic or fetal skeleton and supposedly of phylogenetic importance.

The studies of Thilenius, Bardeen, Mall, and others have shown, however, that the skeleton of the embryo is subject to fluctuating variations like those found in the adult. At present there are not sufficient data to determine definitely the relative frequency of skeletal variations in the adult compared with those in the embryo or fetus.

ABNORMALITIES IN THE DEVELOPMENT OF THE SKELETON.

The form of the skeleton as a whole and of the individual bones which compose it depends partly upon heredity, partly upon the mechanical and chemical influences to which it is subject during growth. The variations which are a normal inheritance of the race, including such extreme forms as individuals with six toes or six fingers, are to be distinguished from the abnormalities of structure due to unfavorable environment either within or without the body. In the main the shapes of the bones and joints are inherited, but to some slight extent both bones and joints are moulded by the experience of the individual. Abnormal stress of muscular or other origin, and abnormal lack of stress, as in cases of muscle paralysis, both give rise to bones and joints abnormal in form.

During development the skeleton is markedly influenced by internal chemical conditions affecting the growth or general nutrition of the body. The skeleton in some cases seems to be the part primarily affected. The skeletal lesions vary all the way from a retardation in the time of appearance of centres of ossification to the failure of a part of the skeleton to develop or to hyperplasia and abnormal form-differentiation.

Agenesis, or failure of skeletal development, may be due either to primary lack of origin of a part or to an affection which destroys the skeletal anlage after it has begun to differentiate. It is most frequently found in the cranial vault and in the vertebral arches, less frequently in the vertebral bodies and the bones of the extremities. The osseous defect is usually, but not always, associated with other marked physical deformities.

Hypoplasia, underdevelopment, of the skeleton, whether generalized or confined to a part, may be due either to prenatal or to postnatal conditions. The failure of the bones to develop normally may be due (1) to lack of active proliferation of cartilage (characteristic of cretins), (2) to inactivity in the process of ossification, membranous, subperiosteal or endochondral (see Michel, 1903, Lindemann, 1903), (3) to a premature union of epiphyses with the main part of a bone, (4) to growth of connective tissue between the growing cartilage of a bone and the region where ossification usually extends into the cartilage (micromelia chondromalacia, fetal rickets), and (5) to inflammation and other abnormal conditions affecting the growing parts of the bone.

Various congenital forms of hypoplasia are recognized,—microsomia, micromelia, micromelia chondromalacia (fetal rickets), cretinism, etc. In most instances while there is a general underdevelopment of the skeleton the long bones are especially affected and appear short and relatively thick; the pelvis and thorax are also usually abnormally small, and the root of the nose is broad and not infrequently sunken in. The causative factors of these conditions are obscure. In cretinism growth of cartilage is retarded and there is a delay in the appearance of centres of ossification and also in the fusion of epiphyses with the main parts of the bones (Wyss, 1900). In this disease there is good evidence that the failure of development of the body, including the skeleton, is due to lack of normal secretion by the thyroid gland. It is not improbable that the secretions of other glands of similar type may affect the development of the skeleton. Some diseases involving both the skeleton and the hypophysis have led to the belief that there is a relation between this gland and skeleton development. This relation has, however, been disputed (Arnold, 1894). K. Bach (1906) has recently discussed the apparent influence of the thymus on the growth of bones.

Hyperplasia, overgrowth of the bones, is due (1) to an excessive activity of membranous or subperiosteal ossification or (2) to a prolonged persistence of actively growing epiphyseal cartilages, union of epiphysis with the main part of the bone being delayed, while endochondral ossification continues beyond the usual time.

Hyperplasia may be local or general and may give rise to a well-proportioned or to disproportionate enlargement of the skeleton. It is stated that removal of the testicles early in infancy or congenital absence of the testicles may lead to an excessive prolongation of the activity of the epiphyseal cartilages and hence to gigantism (P. Launois and P. Roy, 1903, Poncet, 1903). Phosphorus and arsenic in small doses are said to promote bone growth. Partial hyperplasia is found most frequently in the skull and in the bones of the hands and feet. An irritative stimulus, such as a blow, may excite excessive growth of bone. In young people a small centre of inflammation (tuberculosis, osteomyelitis) in the diaphysis may excite activity in the processes concerned in ossification and induce abnormal growth in size of bone. If the centre of inflammation is near the epiphyseal cartilage, ossification is apt to be very irregular.

In *congenital syphilis* there are frequently, although not always, present characteristic irregularities in the deposition of calcium salts and in the formation of narrow cavities in the ossifying cartilage. This sometimes gives rise to marked abnormality of form.

In *rickets* the process of bone absorption is abnormally active, while the formation of new bone is characterized by lack of deposit of the normal amount of calcium salts. In endochondral ossification there is no well-marked zone of calcification. The bones are abnormally thick, clumsy, and heavy and may be much distorted.

In *teratomata* of various forms the skeletal abnormalities correspond with those of the rest of the body.

BIBLIOGRAPHY.

(On general features of the morphogenesis of the human skeleton.)

AEBY, CHR.: Der Bau des menschlichen Körpers. Leipzig 1871.

ARNOLD, J.: Weitere Beiträge zur Akromegaliefrage. Virchow's Arch. Bd. 135, S. 1. 1894.

BACH, K.: Zur Physiologie und Pathologie des Thymus. Jahrb. f. Kinderheilkunde. Bd. 64. 1906.

BADE, P.: Die Entwicklung des menschlichen Skeletts bis zur Geburt. Arch. f. mikr. Anat. Bd. 55, S. 245–290. 1900.

BARDEEN and LEWIS: Development of the Limbs, Bodywall, and Back in Man. Amer. Journ. of Anat. Vol. 1, p. 1. 1901.

BARDEEN, C. R.: Vertebral Variation in the Human Adult and Embryo. Anat. Anz. Bd. 25, S. 497. 1904.

BÉCLARD: Uber die Osteose oder die Bildung, das Wachstum und die Altersabnahme der Knochen des Menschen. Meckel's Arch. Bd. 6, S. 405–446. 1820.

BERNAYS, A.: Die Entwicklungsgeschichte des Kniegelenkes des Menschen mit Bemerkungen über die Gelenke im allegemeinen. Morphol. Jahrb. Bd. 4, S. 403. 1878.

BOLK: Die Segmentaldifferenzierung des menschlichen Rumpfes und seiner Extremitäten. Beiträge zur Anatomie und Morphologie des menschlichen Körpers. Morphol. Jahrb. Bd. 27. 1899. Bd. 28. 1899.

Sur la signification de la sympodie au point de vue de l'anatomie segmentale. Petrus Camper Deel 1. 1901.

BRADLEY, O. C.: A Contribution to the Development of the Interphalangeal Sesamoid Bone. Anat. Anz. Bd. 28, S. 528–536. 1906.

BRUCH, C.: Beiträge zur Entwicklungsgeschichte des Knochensystems. Neue Denkschriften der allgemeinen Schweizerischen Gesellschaft für die gesamten Naturwissenschaften. Bd. 12, S. 16. Zürich 1852.

CORRIDI, G.: Dei principale nuclei di ossificazione che possono invenirsi all' epoca della nascità. L'anomalo Napoli. Vol. 3, p. 143, 179, 231. 1891.

DE COULON, W.: Uber Thyreoidea und Hypophysis bei Cretinen, sowie über Thyroichalreste bei struma nodosa. Virchow's Archiv. Bd. 147. 1897.

DAMANY, P. LE: L'adoption de l'homme à la station debout. Journ. de l'Anat. et de la Physiol. p. 135–170. 1905.

DÖRRIEN, ERNST: Uber Riesenwuchs und Elephantiasis congenita. Diss. Leipzig 1905.

ERISSONIUS: Traité des os des enfants. Cited by Le Double, 1906.

GRAWITZ: Fetus mit kretinistischer Wachstumsstörung des Schädels und der Skelettknochen. Virchow's Arch. Bd. 100. S. 256–262. 1885.

HAGEN: Die Bildung des Knorpelskeletts beim menschlichen Embryo. Archiv f. Anat. und Physiol. Anat. Abt. S. 1–40. 1900.

HENKE u. REYHER: Studien über die Entwicklung der Extremitäten des Menschen, insbes. der Gelenkflächen. Sitzungsb. der K. Akad. der Wiss. Math.-Naturw. Klasse. Wien. Bd. 80, S. 217. 1874.

HEPBURN, D.: The Development of Diathrodal Joints in Birds and Mammals. Journ. of Anat. and Physiol. Vol. 23, p. 507. 1889.

HÜTER, CARL: Anatomische Studien an den Extremitätengelenken Neugeborener und Erwachsener. Virchow's Archiv. Bd. 25, 26, 28. 1862–1863.

KAUFMANN, E.: Untersuchungen über die sogen. fetale Rachitis. (Chondrodystrophia fetalis.) Berlin 1892.

KERCKRING, THEOD.: Spicilegium anatomicum continens osteogeniam foetuum. Amstelodami. 1670.

LAMBERTZ: Die Entwicklung des menschlichen Knochengerüstes während des fetalen Lebens dargestellt an Röntgenbildern. Fortschritte auf dem Gebiete der Röntgenstrahlen. 1. u. 2. Ergänzungsheft. 1900.

LAUNOIS, P. E., et ROY, PIERRE: Des relations qui existent entre l'état des glandes génitales mâles et le développement du squelette. C. R. Soc. Biol. T. 55. 1903.

LINDEMANN, P.: Uber Osteogenesis imperfecta. Diss. Berlin 1903.

LUBOSCH, W.: Die Stammesgeschichtliche Entwicklung der Synovialhaut und der Sehnen mit Hinweisen auf die Entwicklung der Kiefergelenke der Säugetiere. Biol. Zentralbl. Bd. 28, S. 678, 697. 1908.

LUNDVALL, HAVAR: Weiteres über Demonstration embryonaler Skelette. Anat. Anz. Bd. 27. 1905.

LUSCHKA: Die Halbgelenke des menschlichen Körpers. Berlin 1858.

LUNGHETTI, B.: Sopra l'ossification dei sesamoidi intratendinei. Monit. Zool. Ital. Anno 17, p. 321–322, 1906.

MALL, F. P.: On Ossification Centers in Human Embryos. The American Journ. of Anat. Vol. 5. 1906.

MICHEL, F.: Osteogenesis imperfecta. Virchow's Arch. Bd. 174. 1903.

MORIN: Radiographies relatives à la formation et à l'accroissement du système osseux. Assoc. Franç. pour l'Avancem. des Sc. Sess. 27, p. 678–683. Nantes 1899.

NOBILING: Uber die Entwickelung einzelner Verknöcherungskerne in unreifen und reifen Früchten. München 1899.

PFITZNER, W.: Morph. Arbeiten. 1891-1898.

PONCET, ANTONIN: De l'influence de la castration sur le développement du squelette. Recherches expérimentales et cliniques. C. R. Soc. Biol. T. 55. 1903.

RAMBAUD ET RENAULT: Origine et développement des Os. Paris 1864.

REGNAULT, F.: A propos de la morphogénie osseuse. Bull. et Mém. de la Soc. d'Anthrop, 1907.

RETTERER: Ebauche squélettogène des membres et développement des articulations. Journ. de l'Anat. et de la Physiol. Année 38, No. 5, p. 473, 580. 1902.

ROSENBERG, E.: Uber die Entwicklung der Wirbelsäule und des centrale carpi des Menschen. Morphol. Jahrbuch. Bd. 1, S. 83. 1876.

Bemerkungen über den Modus des Zustandekommens der Regionen an der Wirbelsäule des Menschen. Morphol. Jahrbuch. Bd. 36. 1907.

SCHUBERT, C.: Riesenwuchs beim Neugeborenen. Monatsschr. f. Geburtsh. u. Gynäkol. Bd. 23, S. 453–456. 1906.

SCHULIN, K.: Uber die Entwicklung und weitere Ausbildung der Gelenke des menschlichen Körpers. Arch. f. Anat. u. Physiol. Anat. Abth. S. 240-274. 1879.

SCHWEGEL: Die Entwicklungsgeschichte der Knochen des Stammes und der Extremitäten. Sitzb. Akad. Wien. Math. phys. Kl. Bd. 30. 1858. (Literature.)

Silberstein, A.: Ein Beitrag zur Lehre von den fetalen Knochenerkrankungen. Arch. klin. Chir. Bd. 70. 1903.

Thilenius, G.: Untersuchungen über die morphologische Bedeutung accessorischer Elemente am menschlichen Carpus (und Tarsus). Morph. Arbeiten. Bd. 5. 1895.

Accessorische und echte Skelettstücke. Anat. Anz. Bd. 13. 1897.

Wolff, J.: Uber die Theorie des Knochenschwundes durch vermehrten Druck und der Knochenanbildung durch Druckentlastung. Arch. f. klin. Chir. Bd. 13, S. 302 bis 324. 1891.

Wyss, von: Beitrag zur Kenntnis der Entwicklung des Skelettes von Kretinen und Kretinoiden. Fortschr. auf d. Gebiete der Röntgenstrahlen. Bd. 3. 1900.

B. ORIGIN AND FATE OF THE CHORDA DORSALIS.

The cervical region of the chorda dorsalis appears to arise from the dorsal wall of the enterovitelline sac beneath the medullary groove, although it is not probable that these cells belong primitively to the entoderm. In many mammals the tissue from which it is derived comes primarily from the mesodermal head or chordal process (see p. 47). Bonnet,[7] however, has ascribed to the yolk entoderm the origin of the tissue for the anterior tip of the chorda in the dog and sheep, although the main part of the anterior portion of the chorda in these animals is derived from tissue which has become incorporated in the entoderm through fusion of the head process with the dorsal wall of the enterovitelline sac. In the human embryo, as mentioned above (p. 293), there is at a very early period a layer of mesoderm formed between the ectoderm and entoderm in the mid-sagittal plane (Fig. 219, A). At a slightly later period (Fig. 219, B and C) the mesoderm has disappeared in this region. Possibly it is incorporated with the entoderm which now beneath the neural groove presents a plate of tissue slightly thicker than the entoderm on each side. This is the chordal plate, the anlage of the anterior end of the chorda dorsalis. Kollmann (1890) has given an account of the origin of the chorda in a human embryo 2.11 mm. long with fourteen mesodermic somites. In this embryo (Fig. 220) the neurenteric canal has disappeared. Anterior to the primitive streak in the mid-sagittal plane a longitudinal ridge of cells projects dorsally from the entoderm (Fig. 220, B). This ridge of cells gradually becomes pinched off from the entoderm (Fig. 220, C). In a slightly older embryo described by Mall (1897) (Fig. 229) the neurenteric canal is represented by a solid column of cells. The chorda extends forward from this column of cells as far as the buccopharyngeal membrane. As Seessel's pocket develops, the chorda remains for a time attached to its posterior wall. This connection is lost at about the period when the buccopharyngeal membrane is ruptured.

---

[7] Anat. Hefte, 1901.

In the embryo described by Mall the posterior end of the chorda lies opposite what is probably the eighth cervical somite. During the development of the thoracic, lumbar, sacral, and coccygeal regions of the embryo the chorda is gradually developed caudalwards. In this portion of its development the chorda is not first embedded in the entoderm and then again differentiated out, but is derived directly from the primitive streak and from the tissue which replaces the primitive streak caudalwards.

In an embryo described by His (L, 2.4 mm. long) the notochord has a distinct lumen. This is not present in older embryos.

At first there is no distinct membrane about the chorda (see Figs. 220, B, and 220, C). The cells are large, with clear protoplasm. By the end of the fourth week of development a thin structureless membrane encircles the chorda, which is now about at the height of its development. The chorda is cylindrical. The cells are polygonal and are filled with a fine granular protoplasm. During this period differentiation of the base of the skull and of the spinal column is marked by condensations in the axial mesenchyme (Fig. 231). Subsequently in the spinal region the intervertebral discs and the bodies of the vertebræ form about the chorda dorsalis. Between the chorda cells and the outer sheath of the chorda there appears an inner membrane, apparently mucoid in nature (Williams). According to Minot (1907), at the period when the axial mesenchyme begins to be differentiated into vertebræ the notochord shows slight transient dorso-ventral segmental flexures. Just before ossification begins the chorda disappears in the vertebral bodies. In the intervertebral discs it becomes transformed into the tissue of the nucleus pulposus. In the cranial region the posterior and the anterior portions of the chorda dorsalis become embedded in the skeletal tissue of the base of the skull while the intermediate portion lies between the base of the skull and the dorsal wall of the pharynx (Fig. 266). Ultimately the cranial part of the chorda completely disappears. That part of the chorda which lies in the retropharyngeal tissue gives rise to numerous projections and swellings and is the first portion of the chorda to disappear. The posterior portion of the cranial part of the chorda comes to lie on the dorsal side of the basal occipital plate and disappears at the time of ossification of the basi-occipital. The anterior extremity of the chorda persists longer than the retropharyngeal portion, but usually disappears during the ossification of the base of the skull. A description of the changes undergone by the chorda is given in connection with the development of the vertebral column and skull. Traces of the cranial part of the chorda dorsalis may persist in the adult and give rise to tumors.

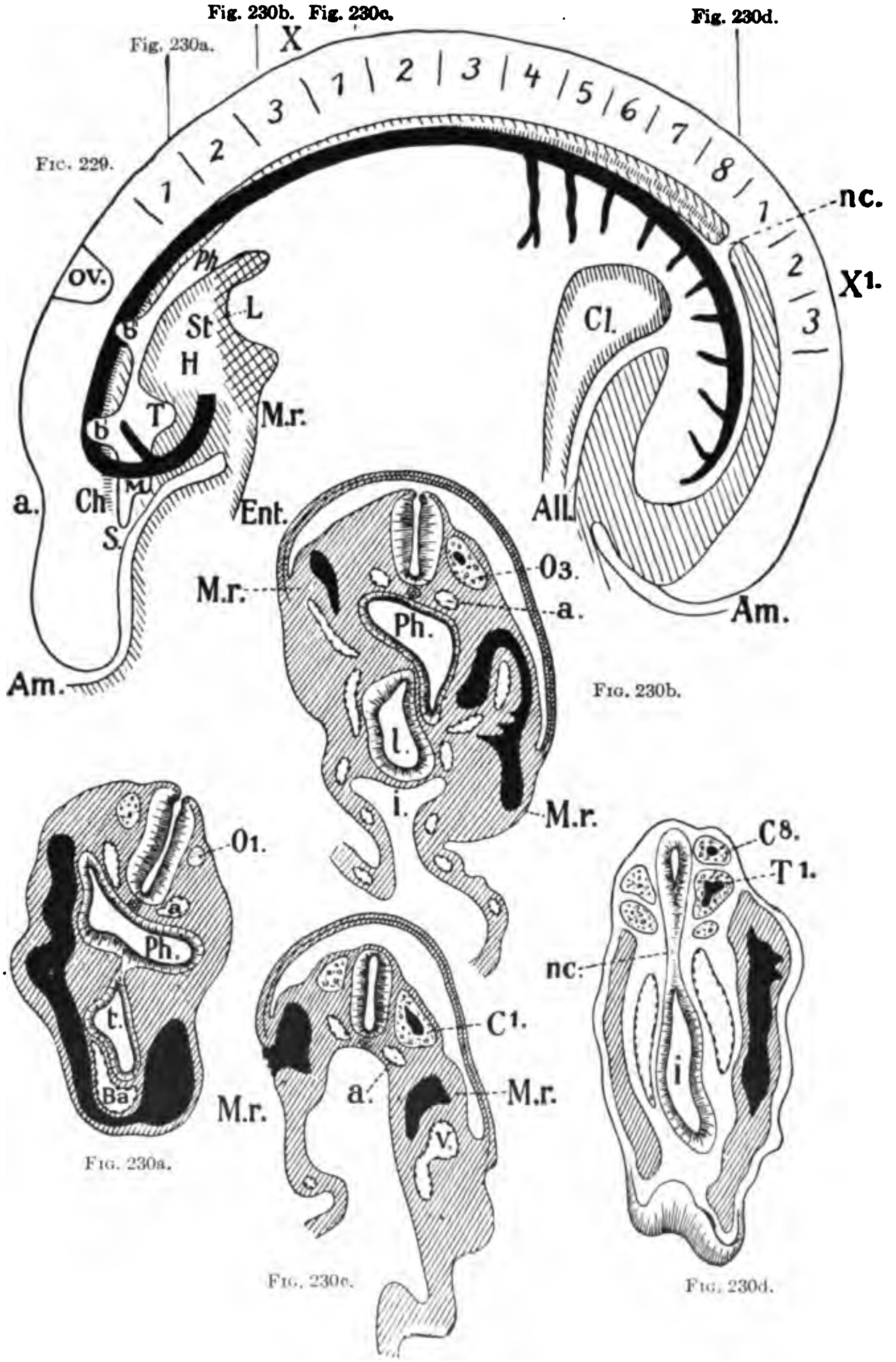

FIG. 229.—(After Mall, Journ. of Morphology, vol. 12, 1897, Fig. 16.) Outline drawing of a medial sagittal section of the model of Mall's embryo XII. Magn. 50 : 1. The heavy line is the aorta. The muscle plates are numbered for occipital, cervical, and thoracic regions respectively. The mesoderm is striated. *Am.*, amnion; *a.*, border between fore-brain and mid-brain; *X*, *X'*, extent of closure of spinal canal; *S*, Seessel's pocket; *Ch.*, chorda; *b'*, *b''*, first and second branchial pockets; *ov.*, otic vesicle; *M.*, mouth; *T.*, thyroid; *H.*, pericardial space; *Ph.*, pharynx; *Ent.*, entoderm; *St.*, septum transversum; *L.*, liver; *nc.*, neurenteric canal; *All.*, allantois; *M.r.*, membrana reuniens; *Cl.*, cœlom.

FIG. 230, a, b, c, d.—Transverse sections through the regions indicated in Fig. 229. Magn. 50 : 1. The cœlom within the body is represented black. O^1 and O^3, first and third occipital myotomes; C^1 and C^8, first and eighth cervical myotomes; T^1, first thoracic myotome; *a.*, aorta; *v.*, omphalomesenteric vein; *t.*, thyroid; *l.*, liver; *Ph.*, pharynx; *i.*, intestine; *nc.*, neurenteric canal; *M.r.*, membrana reuniens.

ENTOCHORDA.

A hypochorda or entochorda arising from the entoderm beneath the chorda dorsalis has been found in fishes, amphibia, birds, and reptiles, but apparently has not yet been described for the human embryo. In part the tissue of the hypochorda joins that of the chorda dorsalis. (See Ad. Reinhardt, Morphol. Jahrb., Bd. 32, 1904; Ph. Stöhr, Morphol. Jahrb., Bd. 23, 1895; and S. A. Ussoff, Anat. Anz., Bd. 29, 1906.)

BIBLIOGRAPHY.

The chief paper on the early development of the chorda dorsalis in man is that of Kollmann (1890). Important data concerning the chorda dorsalis are to be found in the various papers describing human embryos with fourteen somites or less.

BONNET: Beiträge zur Embryologie des Hundes. Anat. Hefte. 1897 und 1901.

ETERNOD: Communication sur un œuf humain avec embryon excessivement jeune. Arch. Ital. de Biologie. Vol. 22. 1895. See also Monitore Zool. Ital. Vol. 5, p. 70–72. 1894.

Sur un œuf humain de 16.3 mm. avec embryon de 2.1 mm. Arch. des Sciences Phys. et Nat. Année 101. 4 Période. T. 2, p. 609–624. 1896.

Il y a un canal notochordal dans l'embryon humain? Anat. Anz. Bd. 16, p. 131–143. 1899.

FRASSI, L.: Uber ein junges menschliches Ei in situ. Arch. f. mikr. Anat. Bd. 71, S. 667. 1908.

FRORIEP, A.: Kopfteil der chorda dorsalis bei menschlichen Embryonen. Beiträge z. Anat. und Embryol. Als Festgabe für Jacob Henle. 1882.

GIACOMINI, C.: Un œuf humain de 11 jours. Arch. Ital. de Biologie. Vol. 29. 1898.

HEIBERG, J.: Uber die Zwischenwirbelgelenke und Knochenkerne der Wirbelsäule. Mitt. a. d. Embryol. Inst. der K. K. Univ. Wien. I, S. 119–129. 1880.

HIS: Anatomie menschlicher Embryonen. 1880.

JANOSIK, J.: Zwei junge menschliche Embryonen. Arch. f. mikr. Anat. Bd. 30, S. 559. 1887.

KEIBEL: Zur Entwicklungsgeschichte der chorda bei Säugern. Arch. f. Anat. und Physiol. Anat. Abt. 1889.

KOLLMANN: Die Entwicklung der chorda dorsalis beim Menschen. Anat. Anz. Bd. 5, S. 308–321. 1890.

Die Rumpfsegmente menschlicher Embryonen von 13–35 Urwirbeln. Arch. f. Anat. u. Physiol. Anat. Abt. 1891.

LEBOUCQ, H.: Recherches sur le mode de disparition de la chorde dorsale chez les vertébrés supérieurs. Arch. de Biol., p. 718–736. 1880.

LUSCHKA: Die Halbgelenke, 1852; 2. Aufl. 1858.

Die Altersveränderung der Zwischenwirbelknorpel. Virchow's Archiv. Bd. 9, S. 309–327. 1856.

Uber gallertartige Auswüchse am Clivus Blumenbachii. Virchow's Archiv. Bd. 11, S. 8–12. 1857.

MALL: A Human Embryo 26 Days old. Journ. of Morph. Vol. 5, p. 459–480. 1891.

Human Cœlom. Journ. of Morph. 1897.

MINOT, C. S.: The Segmental Flexures of the Notochord. Anatomical Record, Amer. Journ. of Anat. Vol. 6. 1907.

MÜLLER, H.: Uber das Vorkommen von Resten der chorda dorsalis bei Menschen nach der Geburt. Zeitschrift f. rationelle Med. Bd. 2. 1858.

MUSGRAVE, JAMES: Persistence of the Notochord in the Human Subject. Journ. of Anat. and Physiol. Vol. 25. 1891.

Robin, C.: Memoire sur l'évolution de la notocorde. Paris, 212 pp., 1868.

Romiti, G.: Rigonfiamenti della corda dorsale nella porzione cervicale nell'embrione umano. Notizie Anat. Siena. 1886.

Spee, Graf v.: Beobachtungen an einer menschlichen Keimscheibe mit offener Medullarrinne. Arch. f. Anat. und Phys. Anat. Abt. S. 159–176. 1889.
Neue Beobachtungen über sehr frühe Entwicklungsstufen des menschlichen Eies. Arch. f. Anat. und Phys. Anat. Abt. S. 1–30. 1896.

On the development of the notochord in the higher mammals see especially:

Williams, L. W.: The Later Development of the Notochord in Mammals. Amer. Jour. of Anat. Vol. 8, p. 251. 1908.

C. VERTEBRAL COLUMN AND THORAX.

The development of the vertebral column and thorax may be divided into three overlapping periods: a membranous or blastemal, a chondrogenous, and an osteogenous.

The Blastemal Period.

The division of the axial mesenchyme into segments, sclerotomes, which correspond to the myotomes and spinal ganglia, is marked at an early stage by intersegmental arteries (Fig. 233, *A. is.*). The segmental differentiation extends into the region dorsal to the spinal cord, but ventrally it does not reach the chorda dorsalis. Each sclerotome becomes divided into two portions, a caudal half in which the tissue is condensed, and a cranial half in which the tissue is less dense (Fig. 234). In sections through hardened tissue a slight fissure, the intersegmental fissure (v. Ebner, 1888), may partially separate the two halves.[8]

From the condensed tissue of the caudal half there arises a primitive vertebra of Remak, or scleromere, with dorsal (neural) and ventral (costal) processes and chordal processes which unite these to the perichordal sheath, a dense layer of tissue forming a continuous sheath about the chorda dorsalis (Figs. 234, 237, 238, 240, 241, 242). From the tissue of the anterior halves of the sclerotomes arise "interdorsal membranes" which unite the dorsal processes of the scleromeres (*M. id.*, Figs. 236, 244, 245, 247), and "interventral membranes" which unite the bases of the ventral processes (*M. iv.*, Figs. 235, 243, 244, 245). The chordal processes become hollowed out caudalwards by a loosening up of their tissue and strengthened cranialwards by a condensation of tissue immediately bounding the intervertebral fissure (Figs. 234, 235, 243,

---

[8] Schultze (1896) has described in a corresponding position in selachians and reptiles a diverticulum which communicates with the myocoel. The fissure is apparently to be looked upon as an offshoot of the myocoel. In birds the fissure is said to arise independently of and to fuse secondarily with the myocoel. In mammals it appears after the myotome has become independent and the myocoel has disappeared.

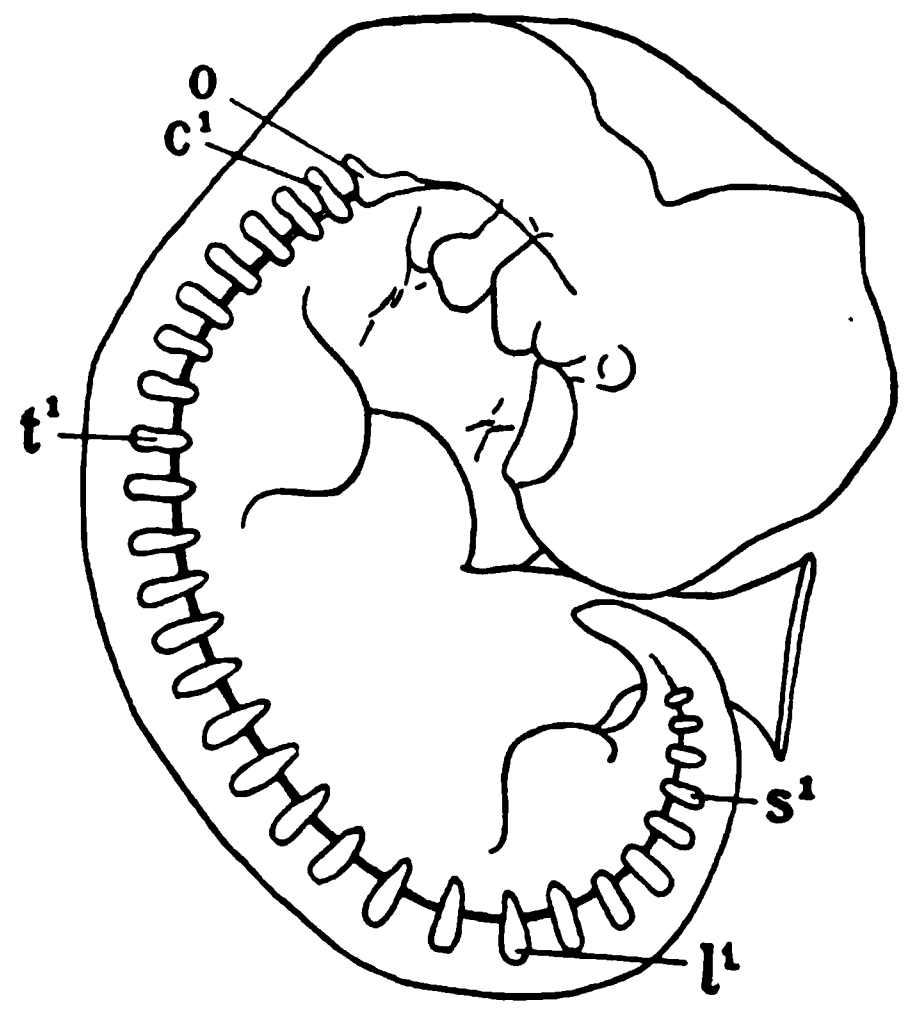

FIG. 231.

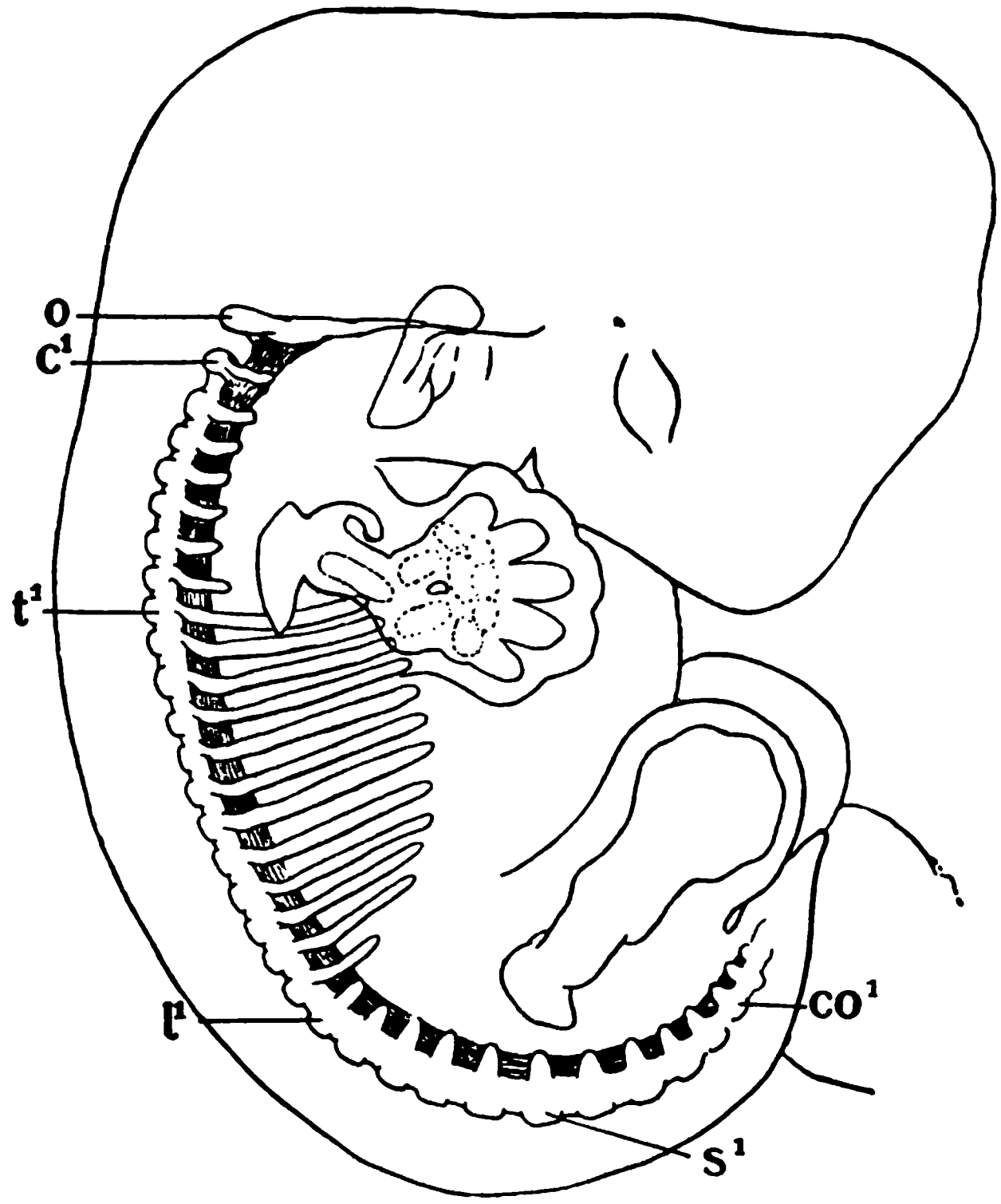

FIG. 232.

FIGS. 231 and 232.—Diagrammatic outlines to represent the development of the skeleton during the blastemal period.

Fig. 231. Embryo II, length 7.5 mm. Fig. 232. Embryo CIX, length 11 mm. *o*, occipital; c^1, first cervical; t^1, first thoracic; l^1, first lumbar; s^1, first sacral; co^1, first coccygeal vertebra.

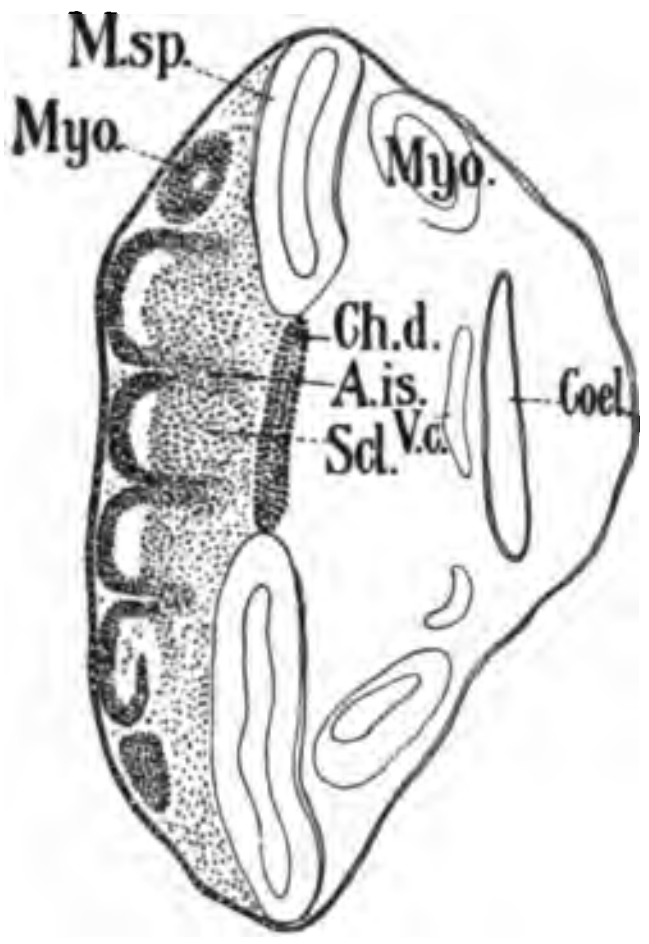

FIG. 233.

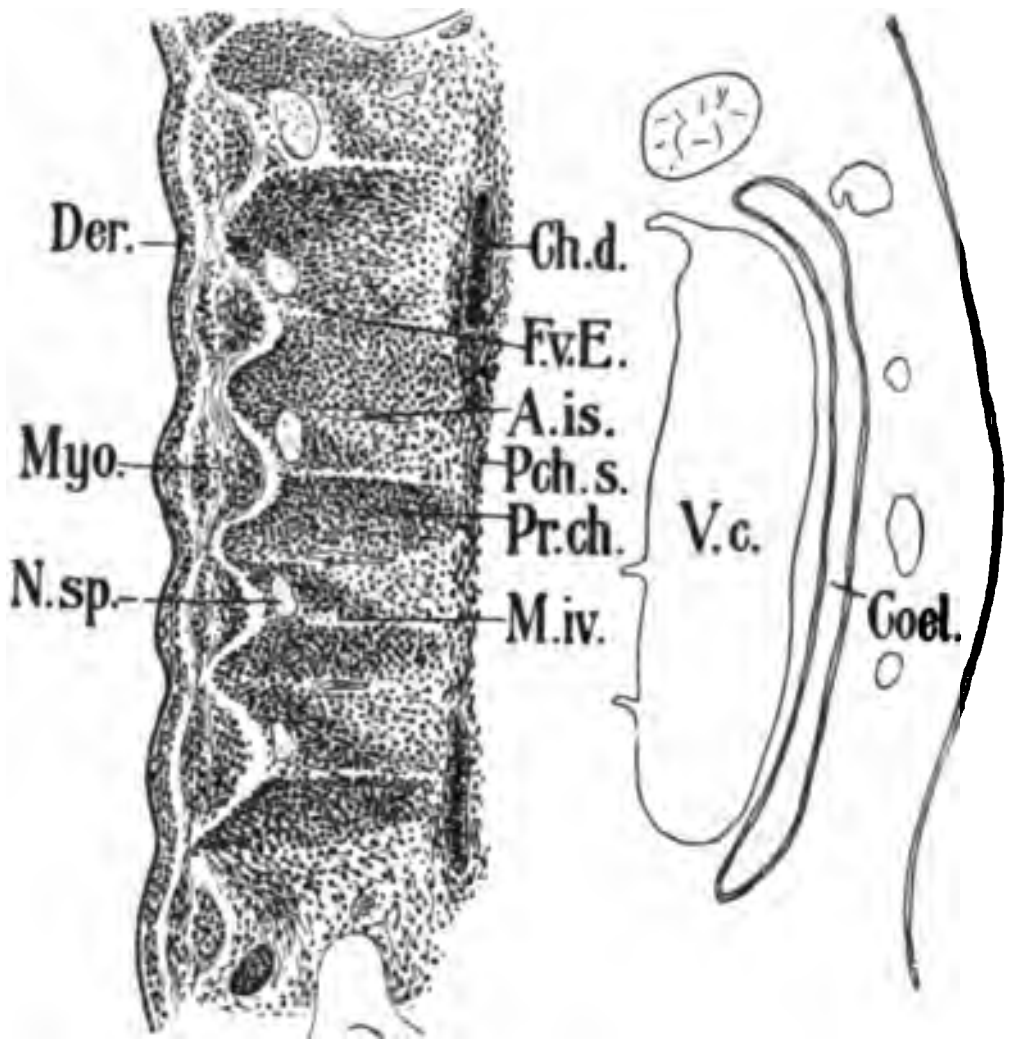

FIG. 235.

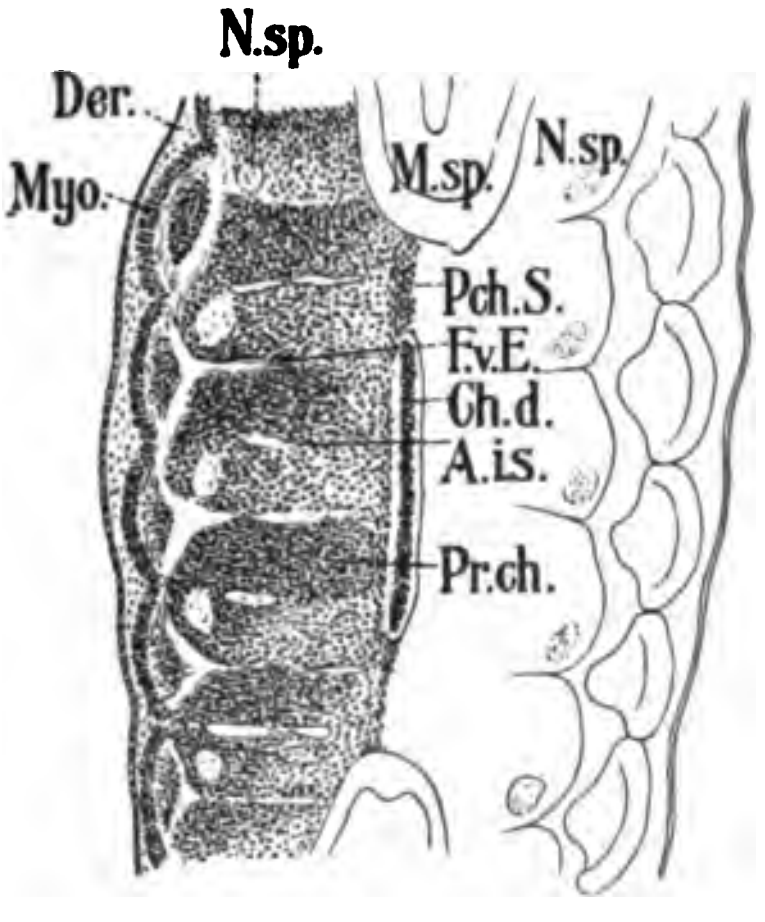

FIG. 234.

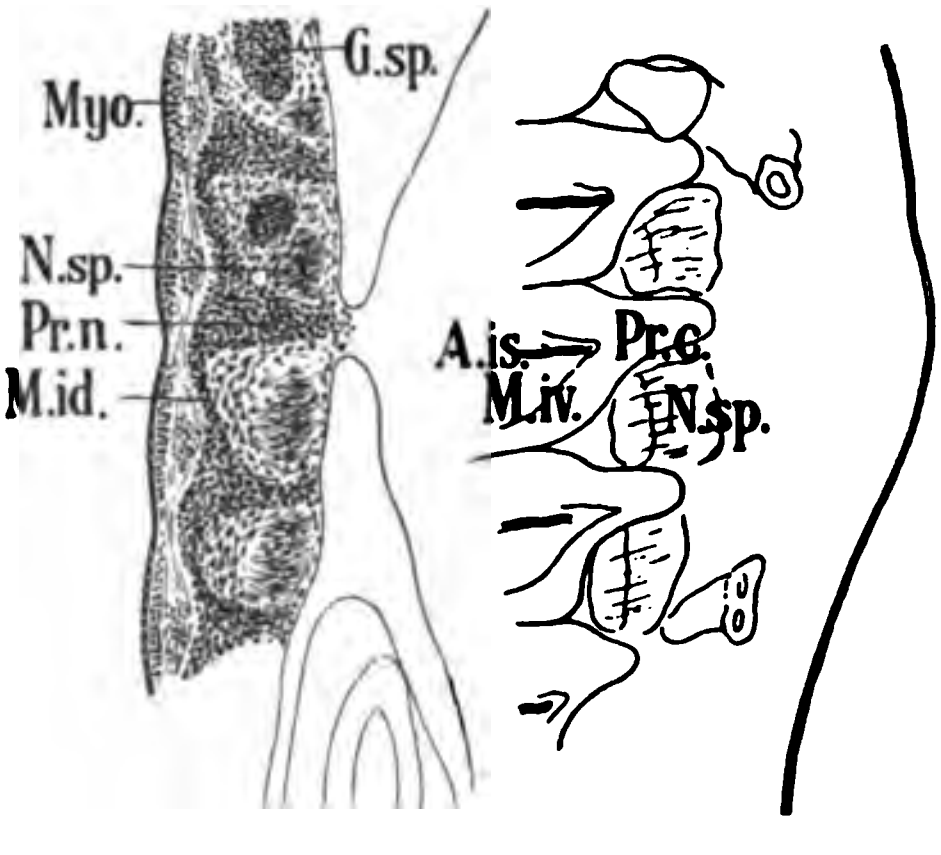

FIG. 236.

FIGS. 233–236.—(After Bardeen, Amer. Journ. of Anat., vol. iv, 1905.) Frontal sections through the thoracic region of several embryos during the blastemal period of vertebral development. Magn. 47.5 : 1.

Fig. 233. Embryo CLXXXVI, length 3.5 mm. Fig. 234. Embryo LXXX, length 5 mm. Figs. 235 and 236. Embryo CCXLI, length 6 mm. Fig. 235 through the region of the chorda dorsalis. Fig. 236 through a more dorsal plane. Figs. 233, 235, 236 represent sections cut somewhat obliquely so that the right side of the sections is ventral to the left. In Figs. 234 and 236 on the right side the bodies of several embryonic vertebræ are represented in outline. In Figs. 234 and 235, owing to artefacts, the myotomes are pulled away from the sclerotomes. *A.is.*, arteria intersegmentalis; *Coel.*, cœlom; *Ch.d.*, chorda dorsalis; *Der.*, dermis; *F.v.E.*, fissure of v. Ebner (intervertebral fissure); *M.id.*, membrana interdorsalis; *M.iv.*, membrana interventralis; *M.sp.*, spinal cord; *Myo.*, myotome; *N.sp.*, nervus spinalis; *Pch.S.*, perichordal sheath; *Pr.c.*, processus costalis; *Pr.ch.*, processus chordalis; *Pr.n.*, processus neuralis; *Scl.*, sclerotome; *V.c.*, vena cardinalis.

244, 245). There is thus formed about the intervertebral fissure a primitive intervertebral disc.[9] The tissue lying between each two discs now becomes completely surrounded by a membrane of condensed tissue, which may be termed an *interdiscal* membrane (Fig. 246, *M. iv.*). Meanwhile the perichordal sheath between each two discs becomes extended ventrodorsally, so that it gives rise to a "perichordal" septum which divides into two parts the space surrounded by the interdiscal membrane (Figs. 239, 246, 247, *Pch.s.*).

During the earlier stages of the blastemal period the scleromeres are essentially similar throughout the length of the vertebral column. The differentiation of the scleromeres begins in the cervical region and extends caudalwards. At the end of the first month of development the scleromeres present the appearance shown in Figs. 231, 240, 241, and 242, although their margins are less sharply marked than it is necessary to represent them in the model. At this period of development the interdorsal and interventral membranes have begun to appear in the cervical region, but are not represented in Fig. 231. Soon after this period the thoracic region of the spinal column becomes distinguishable from the neighboring regions through the great development of the costal process of the thoracic scleromeres (Figs. 232 and 239). Meanwhile centres of chondrification arise. These are described below.[10]

The Occipital Region.—In man, as pointed out above, the primitive axial mesenchyme in the head posterior to the otic region undergoes a partial segmentation. At the end of the first month of development there are three fairly well-marked occipital myotomes which afterwards disappear. The axial mesenchyme corresponding to these myotomes is not definitely divided into sclerotomes, although that opposite the last occipital myotome becomes divided like each of the spinal sclerotomes into a light

---

[9] I have elsewhere (1905) called the united chordal processes of the scleromere a primitive intervertebral disc, but it seems better to restrict this term to the structure here described. According to Williams the primitive intervertebral discs are to be regarded as places in which the tissue remains dense while between them the differentiation of the bodies of the vertebræ is marked by a loosening up of the tissue. According to Williams the scleromeres are not true morphological units.

[10] Charlotte Müller (1906) has described a transitory, longitudinal ridge of cells which extends between the mid-ventral surface of the spinal column and the aorta. Opposite the primitive discs this ridge is connected to the anlages of the corresponding ribs by bands of tissue (hypochordal Spangen) which are not fused to the discs. Opposite the vertebral bodies the lighter tissue of the bodies is continued into the lighter tissue of the centre of the ridge of cells. The ridge extended from the second to the ninth thoracic vertebra in a 13 mm. embryo. There is no segmentation visible in the tissue of the ridge.

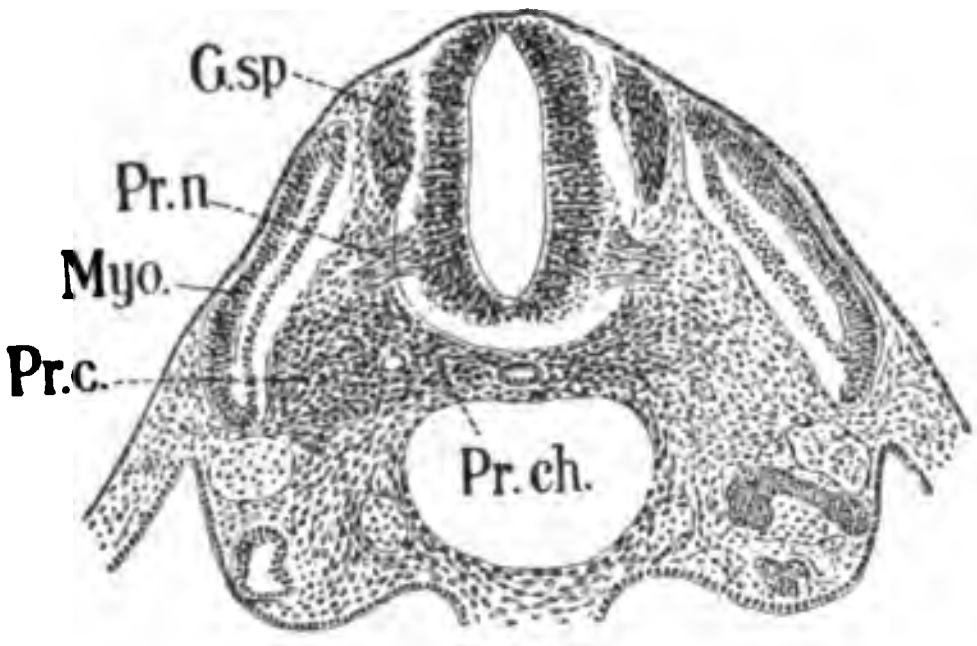

FIG. 237.

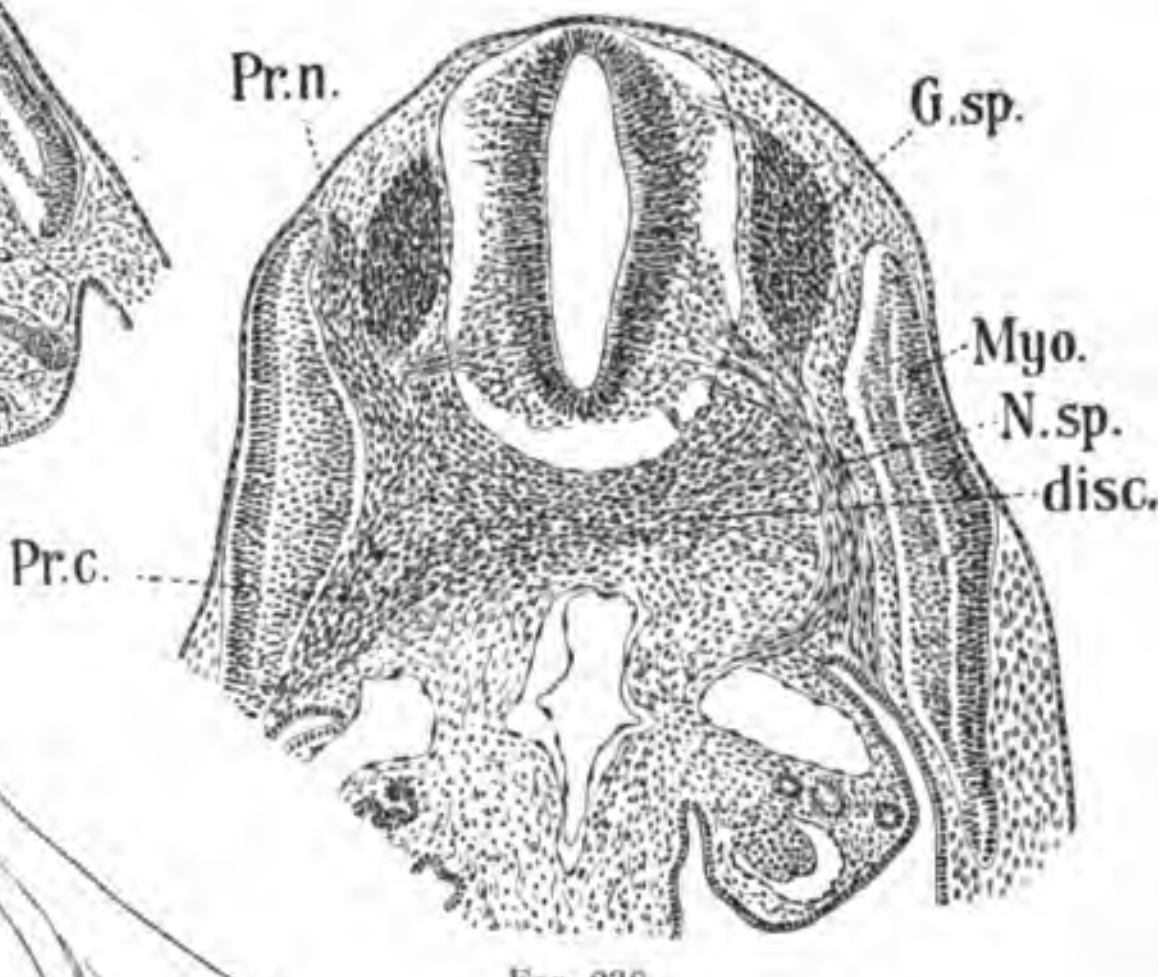

FIG. 238.

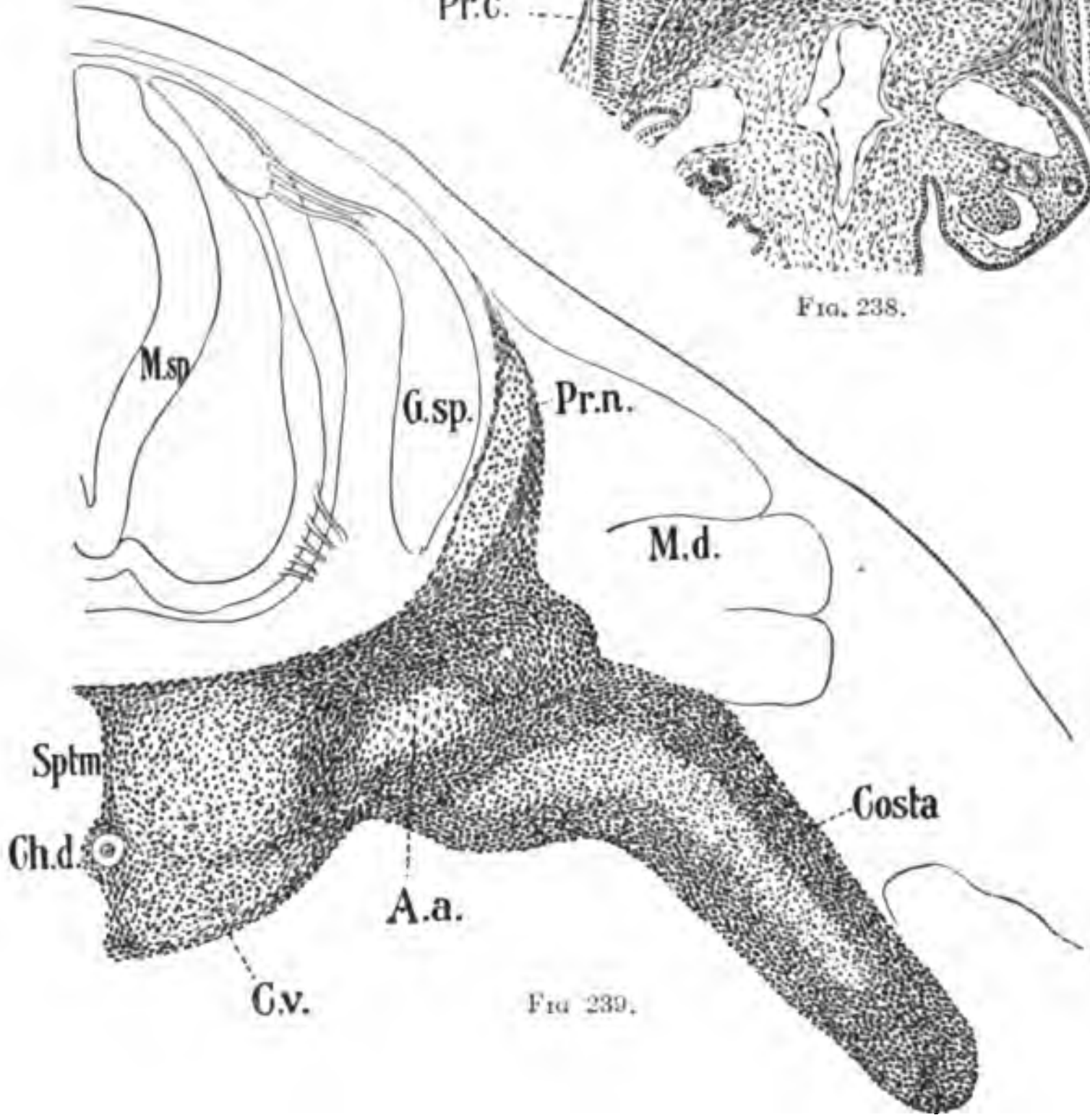

FIG. 239.

FIGS. 237–239.—(After Bardeen, Amer. Journ. of Anat., vol. iv, 1905.) Cross-sections through midthoracic segments during the blastemal period of vertebral development. Magn. 55 : 1.

Fig. 237. Embryo LXXVI, length 4.5 mm. The right side of the section passes through the middle, the left side through the posterior third of the fifth segment. Fig. 238. Embryo II, length 7 mm. Fifth thoracic segment. The right side of the drawing represents a section anterior to that shown at the left. Fig. 239. Embryo CLXXV, length 13 mm. The left half of the sixth vertebral body, neural process, and rib are drawn in detail; the body-wall, spinal cord, and spinal ganglion are shown in outline. *A.a.*, region of anastomosis of two successive intersegmental arteries; *C.v.*, corpus vertebræ; *Costa*, rib; *Ch.d.*, chorda dorsalis; *Disc*, intervertebral disc; *G.sp.*, gangl. spinale; *M.d.*, dorsal musculature; *M.sp.*, medulla spinalis; *Myo.*, myotome; *N.sp.*, nervus spinalis; *Pr.c.*, processus costalis; *Pr.ch.*, processus chordalis; *Pr.n.*, processus neuralis; *Sptm.* perichordal septum.

anterior and a condensed posterior half (scleromere). The lighter half is continuous apicalwards with the slightly condensed, unsegmented mesenchyme which lies in the region of the more anterior occipital myotomes. This in turn is continued into a thin layer of

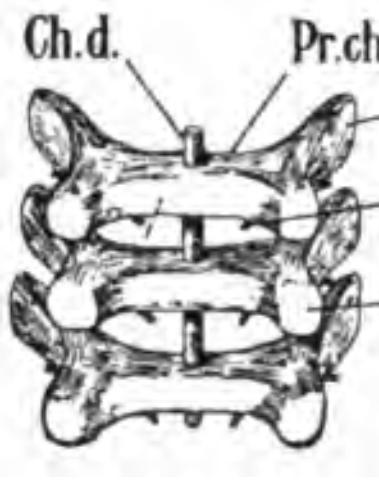

FIG. 240.

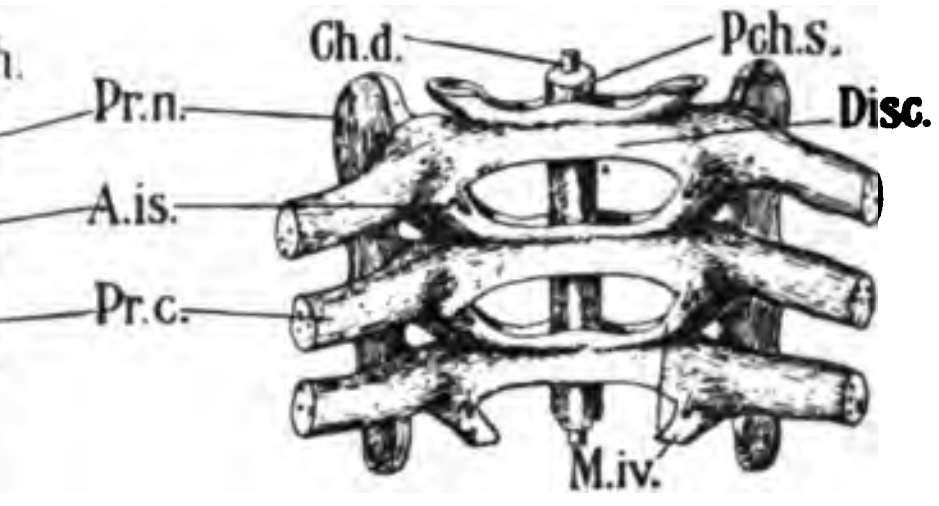

FIG. 243.



FIG. 241.

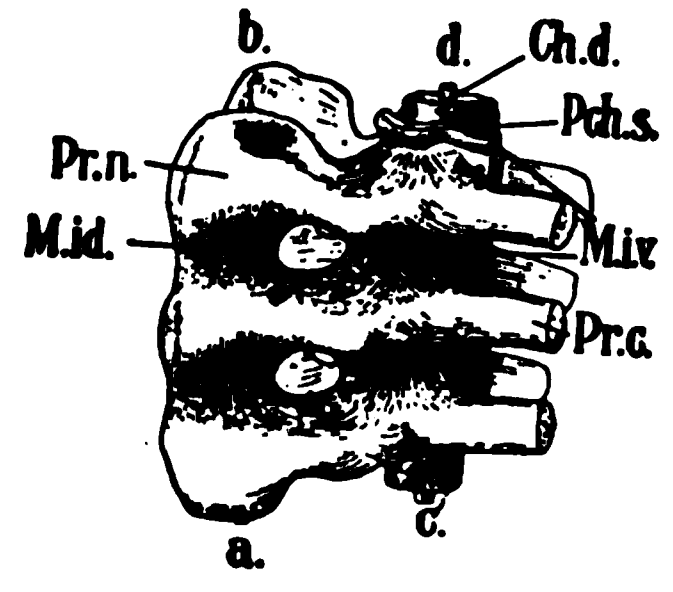

FIG. 244.

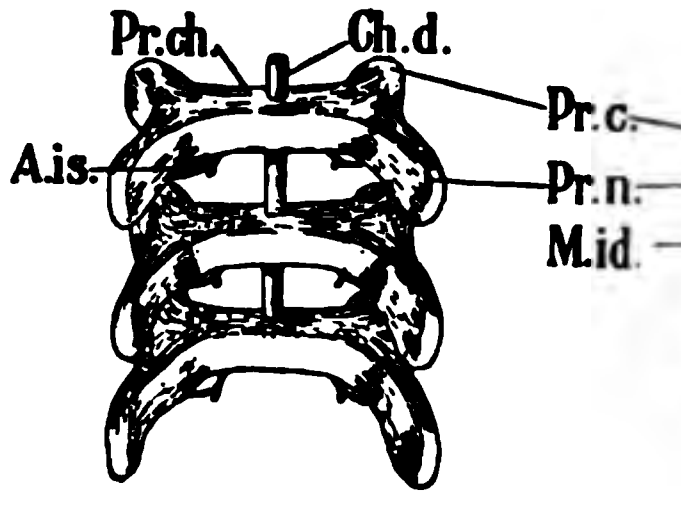

FIG. 242.

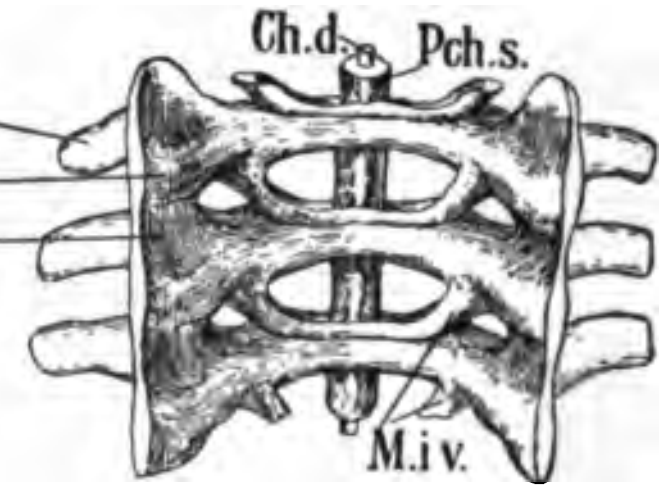

FIG. 245.

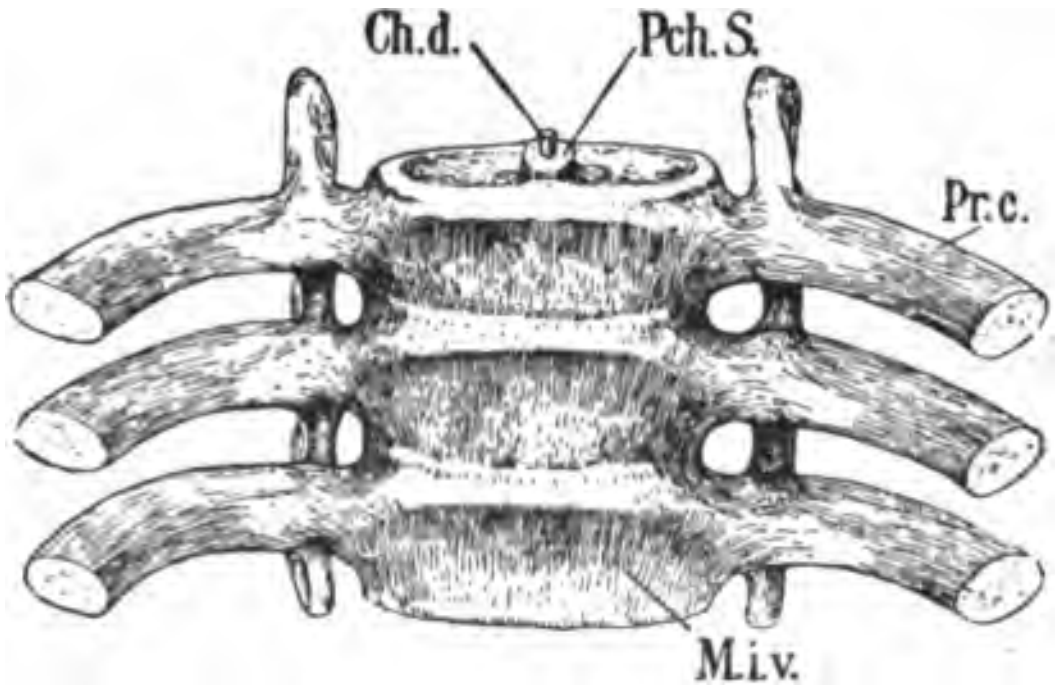

FIG. 246.

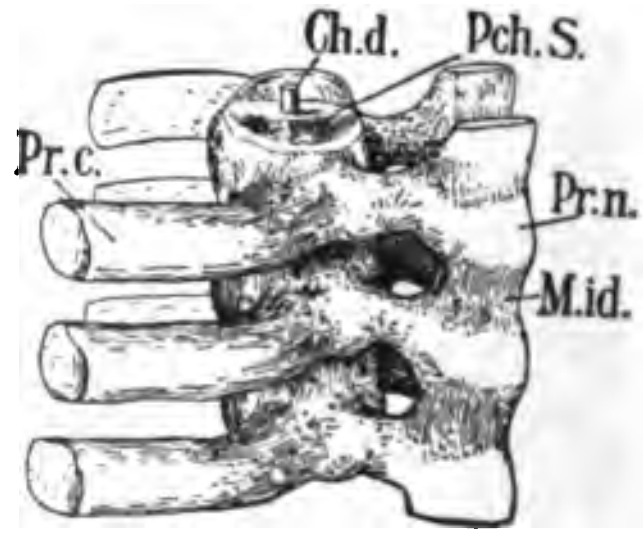

FIG. 247.

FIGS. 240–247.—(After Bardeen, Amer. Journ. of Anat., vol. iv, 1905.) Views of models representing the blastemal stage of vertebral development.

Figs. 240–242. Embryo II, length 7 mm. Magn. 33⅓ : 1. Figs. 243–245. Embryo CLXIII, length 9 mm. Magn. 23 : 1. Figs. 246, 247. Embryo CIX, length 11 mm. Magn. 25 : 1. Figs. 240, 243, 246, views from in front; Figs. 241, 244, 247, views from the side; Figs. 242, 245, views from behind. *A.is.*, arteria intersegmentalis; *Ch.d.*, chorda dorsalis; *Disc*, intervertebral disc; *M.id.*, membrana interdorsalis; *M.iv.*, membrana interventralis; *Pr.n.*, processus neuralis; *Pr.ch.*, processus chordalis; *Pr.c.*, processus costalis; *Pch.s.*, perichordal septum.

dense tissue which is closely applied to the back of the pharynx. The chorda dorsalis surrounded by a perichordal sheath is continued from the spinal region through the centre of the occipital sclerotome and the tissue in front of this into the dense tissue on the back of the pharynx, in which it may be followed to Seessel's pocket. Fig. 231 represents the sclerogenous tissue of the occipital region at the end of the first month. The posterior portion of this, corresponding in form with the first cervical scleromere, is composed of very dense tissue. Anterior to this the tissue is much looser in texture. The occipital scleromere has fairly well developed neural and chordal but has no clearly marked costal processes. No clearly defined interdorsal and interventral membranes are developed from the light half of the first cervical sclerotome. For the subsequent changes which take place in this region see p. 343.

CHONDROGENOUS PERIOD.

On each side of the blastemal vertebra three primary centres of chondrification appear at about the same time, one for the neural process, one for the costal process, and one for the vertebral body. Fig. 239 shows these centres as they appear in a cross section at an early period. Figs. 248 and 249 show the early cartilages of an embryo slightly older (length 14 mm., age five and a half weeks).

The *cartilages of the vertebral body* are formed by a transformation of the loose tissue lying between the primitive intervertebral discs and surrounded by the interdiscal membrane. At first the cartilage of the left side is separated from that of the right by the perichordal septum. Soon this is broken through and the two cartilaginous anlages of the vertebral body become united about the chorda. In the thoracic region this union seems to take place at about the same time dorsally that it does ventrally. A sagittal section through the thoracic region of an embryo at this stage is shown in Fig. 250. The chorda dorsalis is surrounded by a perichordal sheath. The latter is encircled by dense intervertebral discs which alternate with light cartilaginous bodies, surrounded by perichondrium which is less condensed than the tissue of the discs. Ventrally and dorsally longitudinal ligaments have been differentiated from the surrounding mesenchyme.

According to Schultze (1896), the cartilages of the bodies lengthen at the expense of the discs and finally fuse to form for a brief period a continuous cartilaginous column. In human embryos between 20 and 40 mm. in length the discs become very thin near the chorda dorsalis, but the centre of the disc does not become so completely differentiated into embryonic cartilage that it is not possible to distinguish the boundaries between successive ver-

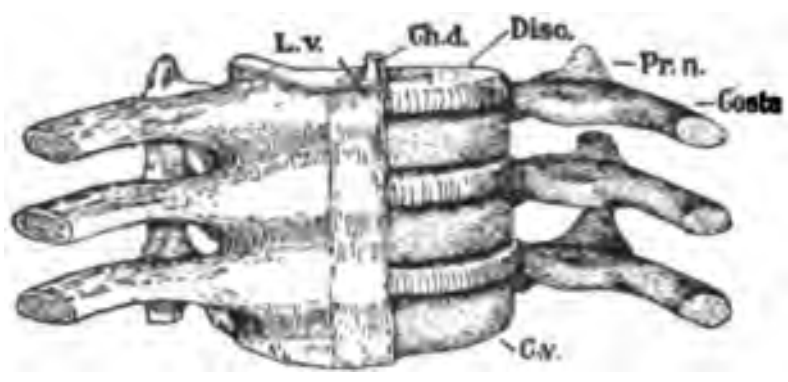

FIG. 248.

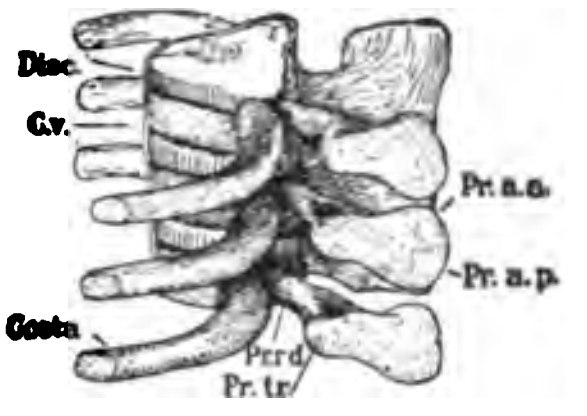

FIG. 249.

FIG. 250.

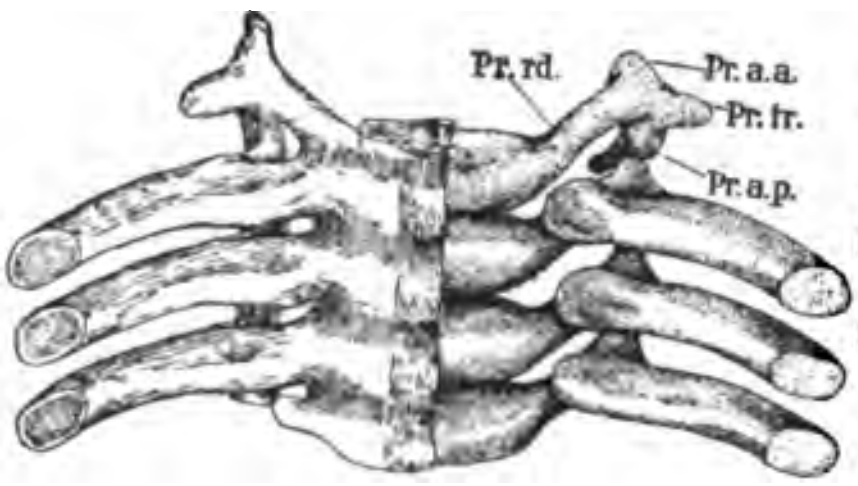

FIG. 251.

FIG. 252

FIG. 253.

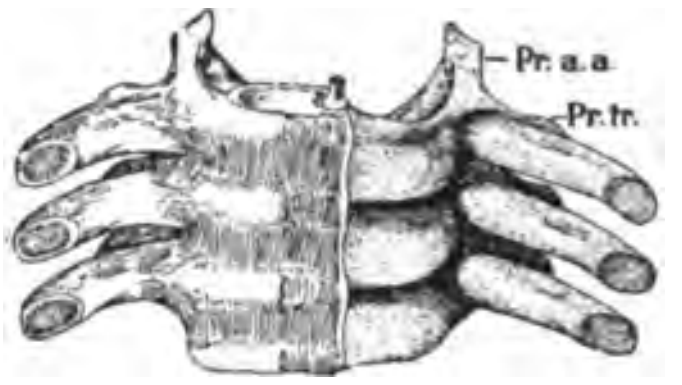

FIG. 254.

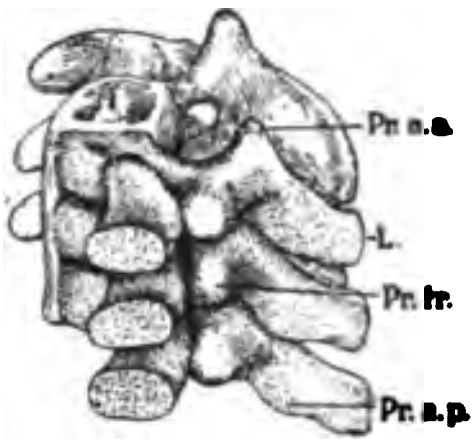

FIG. 255.

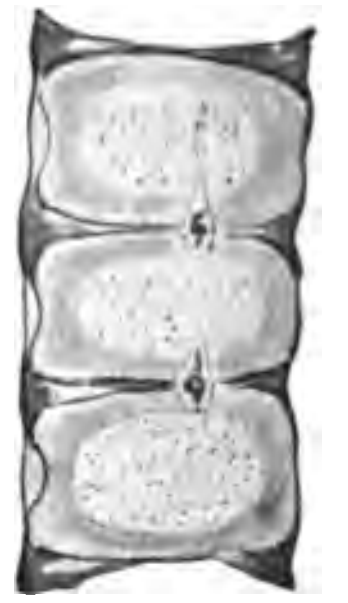

FIG. 256.

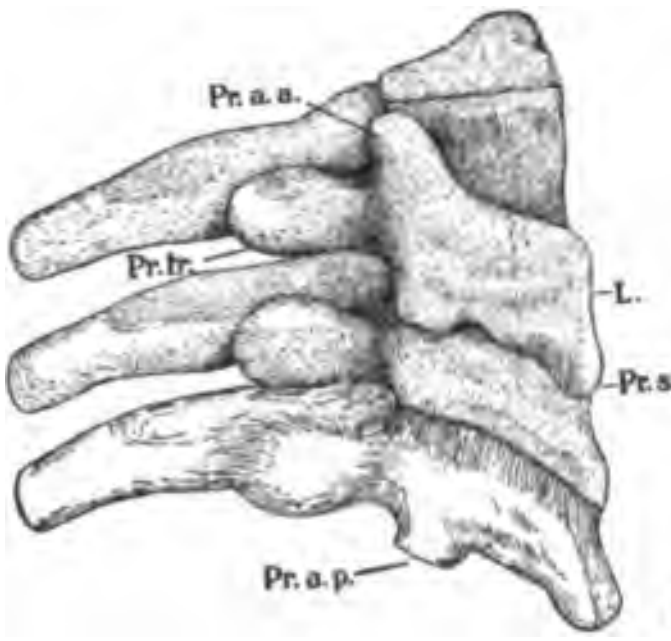

FIG. 257.

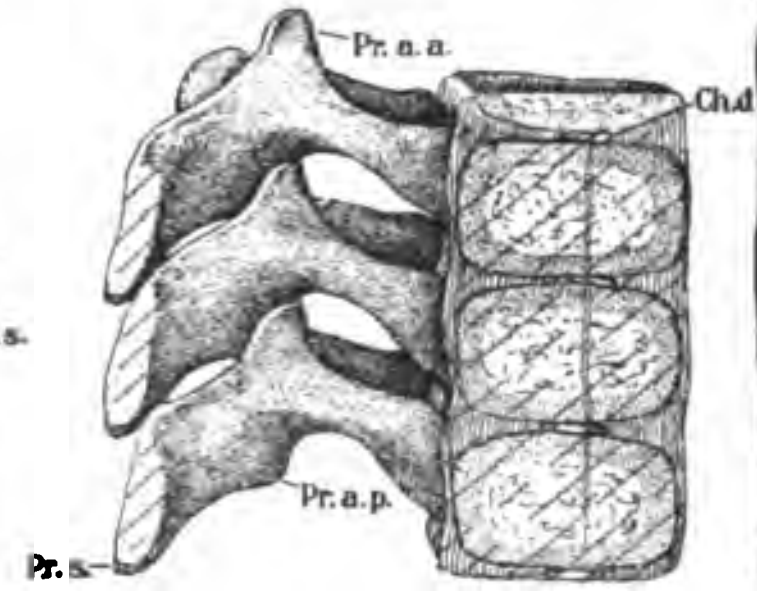

FIG. 258.

FIG. 259.

FIGS. 248–259.—(After Bardeen, Amer. Journ. of Anat., vol. iv, 1905.)

Figs. 248, 249, 251, 252, 254, 255, 257, 258. Ventral, lateral, and dorsal views of models made by the Born method to illustrate vertebral form-differentiation in the sixth, seventh, and eighth thoracic vertebræ during the chondrogenous period. On the left side the cartilaginous, on the right the enveloping fibrous tissue is shown. The latter is also shown on the eighth vertebra in Fig. 252. Figs. 248, 249. Embryo CXLIV, length 14 mm. Magn. 17 : 1. Figs. 251, 252. Embryo XXII, length 20 mm. Magn. 13 : 1. Figs. 254, 255. Embryo CXLV, length 33 mm. Magn. 9 : 1. Figs. 257, 258. Embryo LXXXIV, length 50 mm. Magn. 9 : 1. Fig. 257, dorsal view, left half. Fig. 258, median view.

Figs. 250, 253, 256, 259. Sagittal sections in the mid-line through the sixth, seventh, and eighth thoracic segments of a series of embryos from 15 to 50 mm. long. Fig. 250. Embryo CXLIV, length 14 mm. Fig. 255. Embryo CVIII, length 22 mm. Fig. 256. Embryo LXXIX, length 33 mm. Fig. 259. Embryo CLXXXIV, length 50 mm. *C.v.*, corpus vertebræ; *Costa*, rib; *Ch.d.*, chorda dorsalis; *Disc.* intervertebral disc; *L.*, lamina; *L.v.*, lig. ventrale; *Pr.a.a.*, proc. articularis ant. (sup.); *Pr.a.p.*, proc. articularis post. (inf.); *Pr.n.*, proc. neuralis; *Pr.rd.*, proc. radicularis; *Pr.s.*, proc. spinalis; *Pr.tr.*, proc. transversus.

tebral bodies. According to Charlotte Müller (1906), the intervertebral tissue near the chorda so far undergoes chondrification that capsules may be seen about the tissue cells. This stage is quite transitory. At the periphery of the discs the annulus fibrosus is meanwhile differentiated more and more into a condition resembling the adult (Figs. 250, 253, 256, 259).

The *chorda dorsalis* at the period shown in Fig. 250 is of about the same size at the level of the discs as at the centres of the bodies. It may become slightly swollen in the bodies, but as the bodies increase in size at the expense of the discs the chordal canal becomes enlarged in the intervertebral areas and constricted at the centres of the bodies (Figs. 253, 256, and 259). The chorda loses its continuity and the chordal cells become clumped in the vicinity of the discs, spread out there in the form of a flat disc (Fig. 258), increase in number, and give rise to the nucleus pulposus. Meanwhile the chorda cells lose their cell membranes and form a syncytium similar to that of the mesenchyme. About the cells mucin is formed in considerable amounts (Williams). The chordal canal long remains in the vertebral body (Figs. 256 and 259). The chordal sheath remains in the canal until the period of ossification.

The *cartilage of the bodies* in embryos of the sixth week (Figs. 248, 249, and 250) is of an early, embryonic, hyaline type. At a slightly later stage (Fig. 253) two regions may be distinguished, a central and a peripheral. The peripheral cartilage resembles that of the preceding stage, while the central cartilage is more dense. Gradually the cartilage at the centre of the body undergoes further changes. The cells enlarge and become sharply set off against the matrix, and finally an invasion of vascular tissue takes place, chiefly from the posterior surface. These changes in the cartilage are preliminary to ossification.

During the development of the vertebral bodies changes have been active in the *neural processes.* At the period represented in Fig. 239 the neural cartilage is a small, flat body situated in the dorsal process of the blastemal scleromere; from this as a centre, radicular, transverse, cranial (superior) and caudal (inferior) articular, and laminar processes are rapidly developed. This structural differentiation may be followed in Figs. 248, 249, 251, 252, 254, 255, 257, 258.

The *cartilaginous radicular processes* are at first slender rods which grow out towards and finally fuse with the corresponding vertebral bodies (Figs. 249 and 251). Froriep (1883) has shown that in the chick these processes form a more essential element of the body than in mammals. In the atlas they form a part of the ventral arch, but in the thoracic region of mammals they fuse with the posterolateral portion of the corresponding vertebral bodies.

After their junction with these the radices of the arches increase in size but otherwise show no marked alterations of form.

The *transverse processes* are at first short projections which lie at some distance from the corresponding ribs (Fig. 249). At the time tubercles are developed on the ribs the transverse processes grow outward and forward to meet them (Figs. 252 and 255). At first the developing cartilage of each rib and the corresponding vertebral transverse process are embedded in a continuous blastema, but before chondrification has proceeded far branches from successive intervertebral arteries become anastomosed in the region between the neck of the rib and the transverse process. Fig. 239, *Aa,* shows the loose tissue through which this arterial anastomosis will take place.

Between the extremity of the cartilaginous transverse process and the rib a joint cavity is developed, and the surrounding blastema is converted into the joint capsule and the costo-transverse ligaments. Similarly a joint is developed between the head of the rib and the corresponding intervertebral disc and vertebral bodies.

The *articular processes* develop slowly from the cartilage (Figs. 249, 252, and 255). Extension takes place anteriorly (*Pr. a a.*) and caudalwards (*Pr. a.p.*) in the interdorsal membranes. In an embryo of 14 mm. (Fig. 249) these cartilaginous articular plates are separated by a distinct interval. In one of 17 mm. they have approached each other very closely; and in one of 20 mm. not only do the articular processes show distinctly more form (Fig. 252), but in addition the inferior articular process of one vertebra slightly overlaps the superior process of the vertebra next posterior. This overlapping of the articular processes is distinctly more advanced in an embryo of 28 mm. and still more so in one of 33 mm. (Fig. 257). In a fetus of 50 mm. (Fig. 258) conditions essentially like the adult have been reached.

The *laminar processes* scarcely exist in an embryo 14 mm. long (Fig. 249). In an embryo 20 mm. long (Fig. 252) they have begun to project dorsal to the region of the articular processes. The dense embryonic connective tissue covering the laminar processes at this stage gives attachment to a membrane surrounding the spinal cord, membrana reuniens dorsalis, and to another one covering the dorsal musculature. In a fetus of 33 mm. the laminar processes extend well toward the mid-dorsal line (Fig. 255); in one of 50 mm. (Figs. 257 and 258) they completely encircle the spinal canal and from the region of fusion of each pair of laminar processes a spinous process extends distally, though not so far as in the adult. The completion of the spinal canal takes place earlier in the thoracic than in the cervical and lumbar regions.

Alterations in the cartilage of the neural processes preliminary to ossification begin at about the time that they take place in the vertebral bodies. They are first seen in centres which correspond to those in which the neural cartilage begins in the blastemal neural processes. In a fetus of 50 mm. calcification may be seen in the arches of the first cervical to the sixth thoracic vertebræ.

From the blastemal tissue surrounding the cartilaginous vertebræ are developed the various ligaments of the spinal column.

Summary.—Each cartilaginous vertebra is developed from four centres of chondrification. In addition a separate centre appears for each rib. In comparing these centres with the blastemal formative centres, we find that each primitive centre of blastemal condensation enters into union with tissue derived from the anterior half of the body-segment next posterior and then gives rise to three centres of chondrification, one for the neural arch, one for the rib, and one for a lateral half of a vertebral body. When ossification first takes place the centres of ossification of the neural arches and the ribs correspond to the original chondrification centres in the blastema, but the centres of ossification of the bodies in most of the vertebræ show little trace of the bilateral origin of the centres of chondrification.

REGIONAL DIFFERENTIATION.

THE THORACIC VERTEBRÆ AND THE THORAX.

The chief steps in the development of the thoracic vertebræ have been described in the preceding section. In the blastemal stage these vertebræ became differentiated from the cervical and lumbar by the greater development of the thoracic costal processes. During the chondrogenous stage this difference becomes still more marked. The distal ends of the thoracic costal processes grow rapidly forward (Figs. 260 and 261). The cartilaginous ribs which are differentiated in these blastemal processes do not fuse with the vertebræ, but are connected with them at first by dense tissue and later by joints and ligaments. The blastemal distal ends of the ribs at first take a nearly horizontal direction (Fig. 260), but later their course of development becomes altered by the heart and liver. (See Figs. 261–263.) The distal blastemal ends of the ribs become united by a blastemal tissue to form on each side a sternal plate (Fig. 261). This sternal plate proximally is fused with the anlage of the clavicle and distally extends to the blastema of the seventh rib. The fusion of the tips of the more distal true ribs into the sternal plate does not always take place in regular sequence. The eighth rib is connected near the sternal anlage with the blastema of the seventh and the ninth with that of the eighth rib. The tenth rib becomes similarly attached to the ninth. The attachment of each of the three distal ribs to the one next anterior is apical up to the latter half of the second month. After this it is marginal (Ch. Müller, 1906).

Fig. 260.

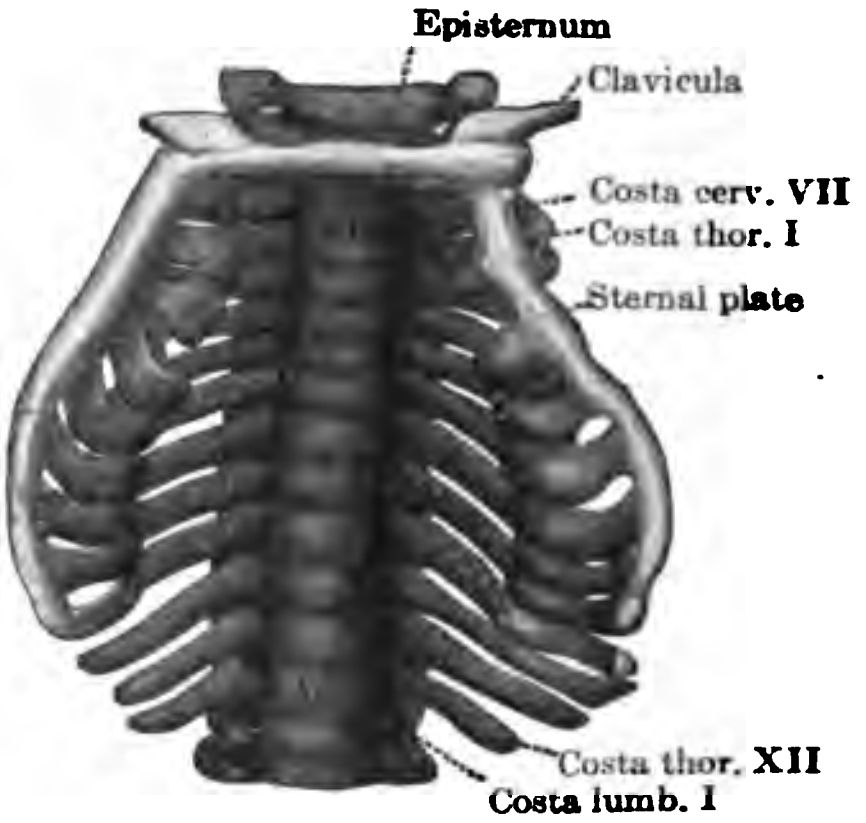

Fig. 261.

Fig. 262.

Fig. 263.

Figs. 260–263.—(After Charlotte Müller, Morpholog. Jahrb., 1906.) The development of the cartilaginous thorax.

Fig. 260. Embryo 13 mm. long. Fig. 261. Embryo 17 mm. long. Fig. 262. Embryo 15 mm. long. Fig. 263. Embryo 32 mm. long.

The sternal ends of the clavicles become united with one another by a dense band of tissue which probably represents the episternum of lower forms (Fig. 261). Later, when the heart has descended into the thoracic cavity, the cranial ends of the sternal plates become united with one another, and the episternal band becomes united to them and loses its intimate connection with the clavicles (Fig. 262). It normally disappears before the end of the second month. The sternal bands gradually become fused throughout their length to form the sternal anlage (Fig. 263). Sometimes fusion takes place distally before it is completed in the middle. The ensiform process is formed by the fusion of bands of tissue which extend distally from each sternal plate. The eighth pair of ribs does not enter into its formation (Ch. Müller). Chondrification takes place in the sternal plates at the time these begin to fuse to form the unpaired sternum. According to Ch. Müller, chondrification extends from the ends of the ribs into the sternal anlage, and the separation of the cartilaginous ribs from the sternum is a secondary process. The order of separation is not always regular. Some investigators assume that special centres of chondrification arise in the sternum.

LITERATURE.

The most important papers on the early development of the human sternum are those of G. Ruge, Morphol. Jahrbuch, Bd. 6, 1880; A. M. Paterson, Journ. of Anat. and Physiol., Vol. 35, 1901; and Ch. Müller, Morphol. Jahrb., 1906. Not infrequently the episternal rudiments, instead of fusing completely with the sternum, become ossified either as separate bones or as bony projections from the upper margin of the sternum. (H. Eggeling, Verh. Anat. Gesellsch., 1903.) Paterson describes a sternal anlage independent of the ribs. The existence of such an anlage is disputed by Ch. Müller. Krawetz (1905) describes in the mouse two sternal anlages which have an origin independent of the ribs.

CERVICAL VERTEBRÆ AND THE BASE OF THE OCCIPITAL BONE.

During the earlier stages of development the cervical vertebræ resemble those of the thoracic region. The two regions soon become differentiated from one another by the much greater development of the costal processes in the thoracic region (Fig. 232). The seventh cervical vertebra alone, as a rule, has large costal processes and these do not extend far beyond the transverse processes of the neural arches.

In the costal processes of the seventh cervical vertebra centres of chondrification are found at the period when similar centres appear in the ribs. Centres of chondrification in the rest of the cervical vertebræ appear much later, usually not until the embryo has reached a length of from 16 to 18 mm. According to Valenti (1906), there are normally no separate centres of chondrification in the costal elements of the cervical vertebræ, but chondrification extends into them from the cartilage of the bodies. There seems, however, good evidence of separate costal centres which arise near and quickly fuse with those of the bodies.

As in the thoracic vertebræ, there are two bilaterally placed centres of chondrification for each of the vertebral bodies. These soon fuse with one another ventral and dorsal to the chorda dorsalis. In the first two vertebræ the ventral fusion takes place before the dorsal fusion.

There are separate centres of chondrification for the neural processes. In the more caudally situated cervical vertebræ these centres are similar to those of the thoracic vertebræ. In the more cranially situated cervical vertebræ each neural centre of chondrification appears as a basal plate lateral to the cranial end of the body of the vertebra. With this it soon fuses. From this plate-like base chondrification extends rapidly into the main part of the arch. From the neural arches are developed laminar, articular, and transverse processes. The cartilaginous costal centres become fused medially with the bodies of the vertebræ and laterally with the tips of the transverse processes. The dorsal growth of the laminar processes and the formation of the spinous processes of the cervical vertebræ take place in the main as in the thoracic. When fully formed, however, the cartilaginous cervical vertebræ

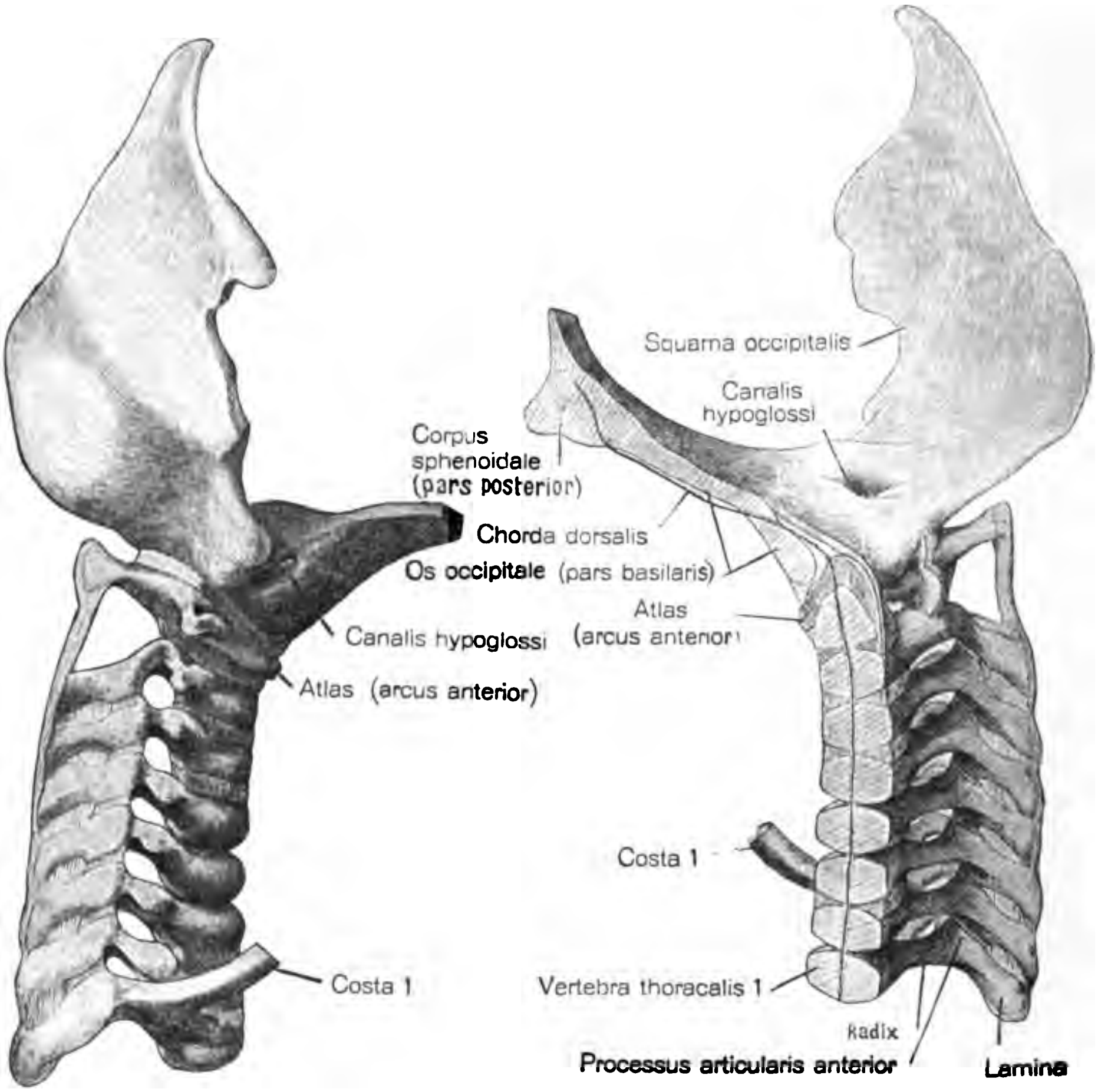

Fig. 264. Fig. 265.

Figs. 264 and 265.—Two views of a model of the cervical vertebræ and the occipital cartilage of an embryo 20 mm. long.

have essentially the shape of the adult osseous cervical vertebræ. Even before the end of the second month of development distinct cervical characters may be distinguished.

Specific mention must be made of the mode of development of the epistropheus, of the atlas, and of the basioccipital.

Epistropheus.—The general mode of development of the epistropheus is like that of the other cervical vertebræ. The dens represents the body of the first cervical vertebra. Union of the body of the first vertebra with that of the second takes place through the transformation of the intervertebral disc into hyaline cartilage, first lateral to the mid-sagittal plane, then later in this plane. Fig. 265 represents a stage where the lateral fusion is complete while the medial fusion has not yet taken place. The articulations between the superior articular processes of the epistropheus and the lateral masses of the atlas apparently are developed rather in the interventral membranes than in the interdorsal membranes. (See Fig. 264; compare with Figs. 249, 252, 255, 258.)

Atlas (Figs. 264 and 265).—The base (radicular process) of each cartilaginous arch piece of the atlas becomes temporarily fused with the cartilage of the body (14 mm. embryo). This fusion is brought about by incompletely differentiated cartilage, and soon after it takes place the precartilaginous tissue between the arch and the body becomes transformed into a dense blastemal tissue in which ligaments and a joint cavity are later developed.

Meanwhile, during the period of chondrification in the arches and bodies of the cervical vertebræ, there takes place a condensation of tissue on the ventral margin of each of the more proximal cervical intervertebral discs near the cranial end of the vertebral body which lies caudalwards from it (Fig. 266). These condensed transverse bands of tissue connect the ventral ends of the blastemal neural processes with one another. They represent the hypochordal Spangen or braces of Froriep, and may appropriately be called hypochordal arches. In their intimate relations to the intervertebral discs they apparently differ from the hypochordal Spangen described by Charlotte Müller in the thoracic region of the human embryo (see note, p. 334). In man the hypochordal arches are transitory in all except the first cervical segment. In the more distal segments the tissue composing them seems to become merged in the intervertebral discs without going beyond the blastemal stage. In the first cervical segment the hypochordal arch becomes chondrified at the time of the separation of the arches from the body after the temporary fusion mentioned above. The cartilage of the hypochordal arch becomes united on each side to that of the neural hemiarch. There are evidences of two bilaterally placed centres of chondrification in the hypochordal arch, but fusion of these centres with one another and with the cartilage of the neural hemiarches takes place as soon as chondrification is well under way. According to Froriep (1883), in the cow there is a single median centre in the hypochordal arch. In the white rat, according to Weiss, there are two bilaterally placed centres of chondrification in the hypochordal arch of the atlas. Froriep reports in the cow temporary centres of chondrification in the other cervical hypochordal arches, but no true cartilage formed, except very temporarily in that of the epistropheus. Weiss found no chondrification in any hypochordal arch in the white rat except that of the atlas.[11]

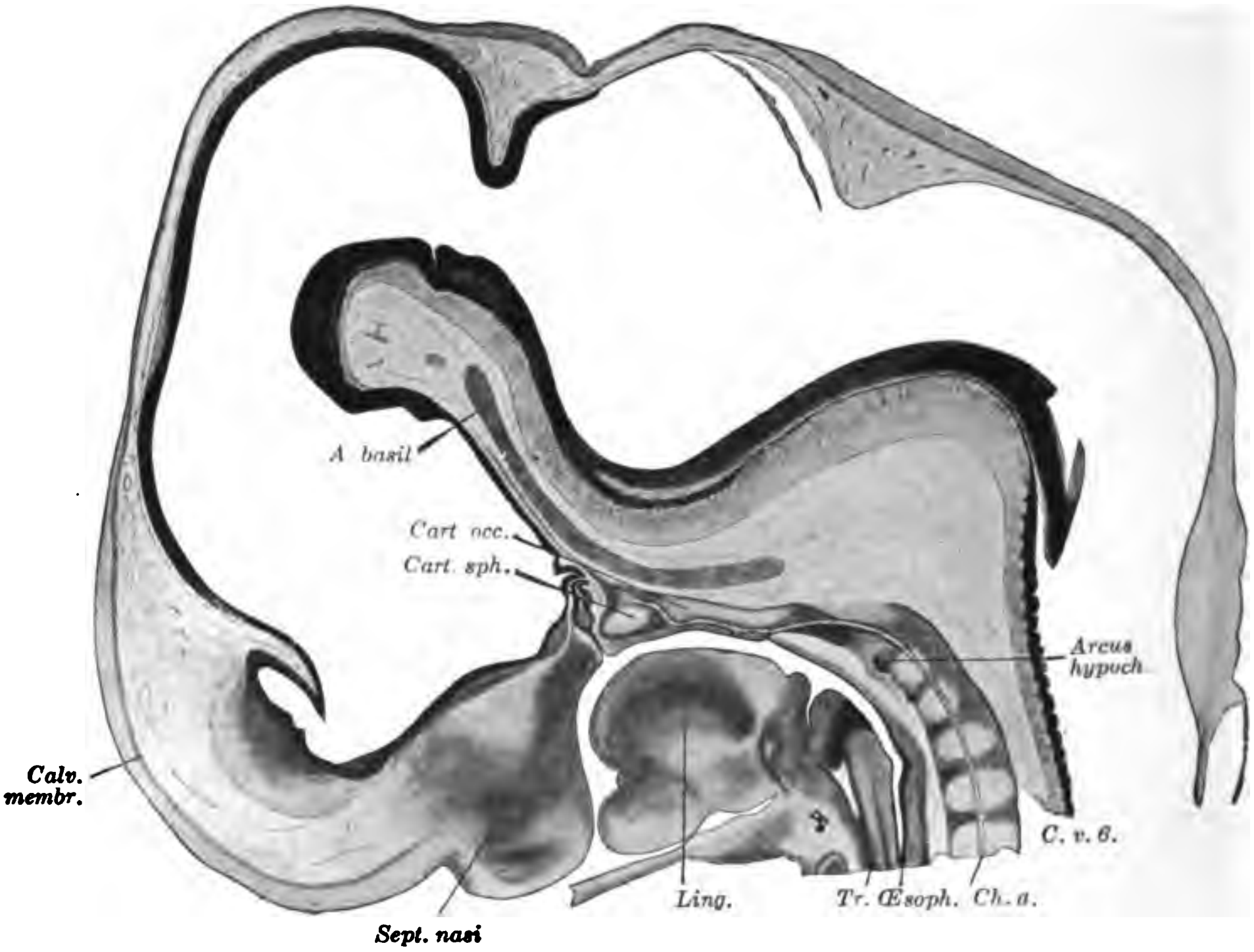

FIG. 266.—Sagittal section through the head of an embryo 14 mm. long. *Arcus hypoch.*, arcus hypochordalis, hypochordal brace or "Spange"; *A. basil.*, arteria basilaris; *Calv. membr.*, calvaria membranacea; *Cart. occ.*, cartilago occipitalis; *Cart. sph.*, cartilago sphenoidalis; *C. v.* 6, corpus vertebræ sextæ; *Ch. d.*, chorda dorsalis; *Ling.*, lingua; *Œsoph.*, œsophagus; *Sept. nasi*, septum nasi; *Tr.*, trachea.

According to Schauinsland (Hertwig's Handbuch, 1906), the neural arches of the mammalian vertebræ contain elements of both the ventral and dorsal arches found in the lower vertebrates, and the ribs belong primitively to the ventral arches. In the mammals and man, however, the presence of ventral arch elements is manifest merely in the caudal and cervical regions. In the caudal region temporary hæmal processes are developed (see p. 352). In the cervical region the ventral arches are represented by the hypochordal braces or arches. In reptiles and birds the hypochordal arches are more extensively developed than in man.

---

[11] Ganfini (1906) has reported in a number of cases the apparent rudiments of a hypochordal arch in connection with the basilar portion of the occipital.

The costal processes of the atlas become fused medially to the basilar part of the neural arches (Fig. 264).

For a brief period (14 mm. embryo) the bases of the neural arches of the atlas and epistropheus together with the tissue intervening between the atlas and occipital bone become fused into a nearly continuous mass of precartilage (Fig. 267).[12]

Basioccipital.—It has already been pointed out that opposite the last occipital myotome the axial mesenchyme is differentiated, like that of the spinal sclerotomes, into a light anterior half and a dense posterior half. The dense posterior half is called a scleromere. In the spinal region each scleromere joins with the light half of the sclerotome next posterior in giving rise to the body and arch processes of a spinal vertebra. In man the occipital scleromere is not thus associated with the light half of the first spinal sclerotome. On the contrary, it becomes associated with the lighter tissue of its own segment and with the tissue into which this is continued cranialwards. Fig. 266 may serve to illustrate this. It will be noted that the anterior half of the first spinal sclerotome is composed of light mesenchymatous tissue, while the basioccipital and the bodies of the spinal vertebræ are composed of cartilage.

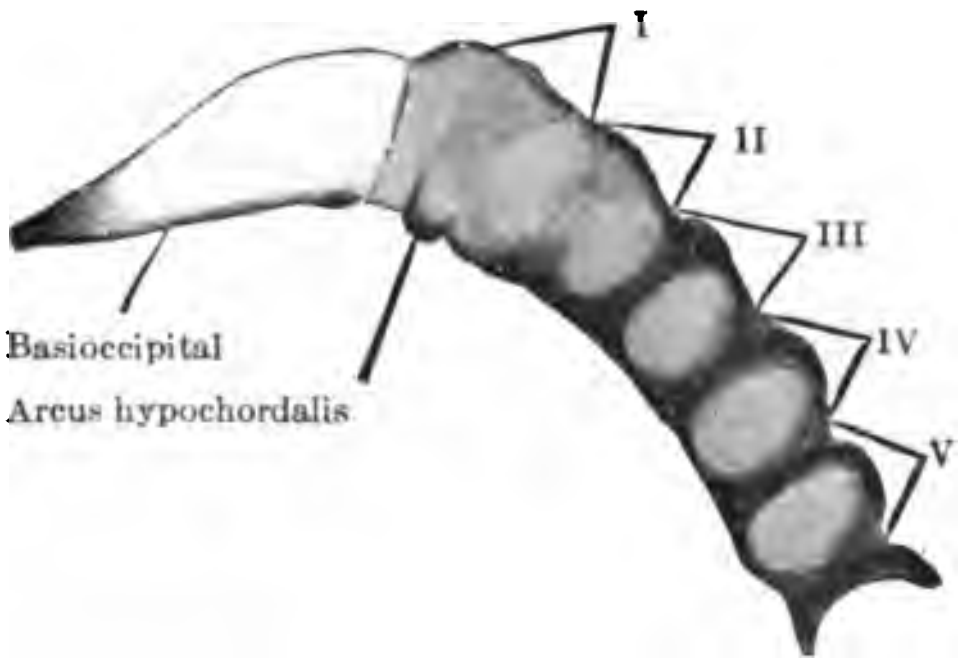

FIG. 267.—Sagittal section through the lateral part of the cervical region of the spinal column of the embryo shown in Fig. 266.

Chondrification of the base of the occipital begins in two bilaterally situated centres in the posterior portion of the occipital anlage. The union of these centres takes place caudalwards ventral to the notochord and apicalwards dorsal to the notochord. The neural processes of the caudal part of the occipital anlage seem to have separate centres of chondrification, but these centres fuse almost immediately with the centres of chondrification of the

---

[12] Hagen (1900) gives a somewhat different account of the development of the atlas and epistropheus in man. He concludes (1) that the dens epistrophei arises from the region of the body of the epistropheus and a portion of the body of the atlas, (2) that the massæ laterales of the definitive atlas arise from the rest of the primary anlage of the body of the atlas, and (3) that the short piece which unites them in front arises from the fusion of both neighboring septa. According to Weiss (1901), the light, cranial half of the first spinal sclerotome gives origin to a cartilaginous tip on the dens epistrophei. The caudal part of the occipital Weiss regards as arising from the neural processes of the last occipital scleromere. Robin (1864) gives several good pictures of early stages of the cartilaginous cervical vertebræ.

body. Figs. 264 and 265 show the appearance of the occipital cartilage toward the end of the second month of embryonic development. For further details see the subsection on the development of the skull.

Ligaments and Joints.—The atlanto-occipital like the lateral atlanto-epistropheal diarthroses are apparently formed rather in the interventral than in the interdorsal primitive membranes. From the interdorsal membranes between the atlas and the occipital bone arises the membrana atlanto-occipitalis.

From the periphery of the perichordal part of the light anterior half of the first spinal sclerotome are differentiated the cranial extremities of the anterior and posterior longitudinal ligaments, of the tectorial membrane, and of the alar and the crucial ligaments of the atlas. About the chorda dorsalis in this region the lig. apicis dentis is differentiated, probably chiefly from the perichordal tissue.

Cartilaginous and osseous nodules found occasionally in this ligament have been thought by some to represent remnants of the original tissue of the chorda (H. Müller, 1858). Albrecht (1880) advanced the view that these nodules represent the vestige of a supplementary vertebra (pro-atlas), but this view has been disputed by Cornet (1888), Chiarugi (1890), and others. Weiss states that in the white rat the perichordal tissue of this region gives rise to the tip of the dens epistrophei, but this appears not to be the case in man. The tissue between the apical ligament of the dens, and the anterior, alar and crucial ligaments of the atlas becomes converted into a fibro-adipose tissue. In this there is ventrally a slight extension of the synovial cavity between the dens and the atlas and dorsally a greater extension of the cavity between the dens and the transverse ligament.

The ligaments in the vicinity of the epistropheus are developed from the periphery of the perichordal tissue and from the interdorsal primitive membranes.

LUMBAR, SACRAL, AND COCCYGEAL VERTEBRÆ.

In the earlier stages of development the lumbar, sacral, and coccygeal vertebræ resemble the thoracic. The blastemal vertebræ arise each from the contiguous halves of two primitive segments of the axial mesenchyme. Each vertebra exhibits a body from which neural and costal processes arise. The neural processes are connected by "interdorsal" membranes.

As the blastemal vertebræ become converted into cartilage specific differentiation becomes more and more manifest. The cartilaginous vertebral bodies and the intervertebral discs are all formed in a manner similar to that of the thoracic vertebræ and except for size manifest comparatively slight differences in form. The more distal coccygeal vertebræ are, however, irregular. But the chief specific differentiation is seen in the costal and neural processes.

The development of the vertebræ of the distal half of the vertebral column may be followed in Figs. 274–278 (p. 368).

In the *lumbar vertebræ* radicular, transverse, articular, and laminar processes arise from the neural cartilages. The radicular processes resemble the thoracic but are thicker; the transverse processes are shorter, much thicker at the base, and remain bound up with the costal processes; the superior articular processes develop in such way as to enfold the inferior articular processes of the vertebra next cranialwards; the laminar processes are broad, grow more directly backward than do the thoracic, and on meeting their fellows in the mid-dorsal line fuse and give rise to the typical lumbar spines. The mammillary and accessory processes are developed in connection with the dorsal musculature and are not definitely formed in cartilage.

In the *sacral vertebræ* the neural cartilages give rise to very thick radicular processes; to articular processes, the most cranial of which develop like the lumbar, while the others long retain embryonic characteristics; to transverse processes which in development are bound up with the costal processes; and to laminar processes which are very slow to develop and of which the last fail to extend far beyond the articular processes.

In the *coccygeal vertebræ* the neural processes of the first, and rarely of the second, give rise to cartilaginous plates. From these only radicular and incomplete articular and transverse processes arise. The cornua of the adult coccyx represent fairly well the form of the embryonic neural semi-arches.

In the thoracic vertebræ *cartilaginous ribs* develop from separate centres in the blastemal costal processes.

In the lumbar vertebræ separate cartilaginous centres probably also always arise in these processes, but they are developed later than those of the thoracic vertebræ and quickly become fused with the cartilage of the transverse processes. The transverse processes of the adult lumbar vertebræ represent at the base a fusion of embryonic cartilaginous costal and transverse processes, but laterally an ossification of membranous costal processes.

In the sacral vertebræ separate cartilaginous costal centres are developed, but they soon become fused at the base with the transverse processes of the neural cartilages. Laterally by fusion of their extremities the costal processes give rise to that part of the sacrum which articulates with the ilium.

In the coccygeal vertebræ the costal processes of the first vertebra become fused with the transverse processes and develop into the transverse processes of the adult coccyx. It has not been determined whether a separate costal cartilage is developed in these processes or cartilage extends into them from the neural processes. The costal processes of the other coccygeal vertebræ have merely a very transitory blastemal existence.

For a brief period the more distal sacral and the coccygeal vertebræ have membranous *hæmal processes.* Schumacher (1906) describes a hæmal arch on the first coccygeal vertebræ which he considers present in most human embryos 3–5 months old.

Centres of ossification correspond in general with centres of chondrification, but, as in the case of the vertebral bodies and the more distal sacral neuro-costal processes, a single centre of ossification may represent two centres of chondrification.

Period of Ossification.

In the vertebræ, ribs, and sternum one may distinguish primary and secondary centres of ossification. Most of the primary centres appear early in intra-uterine life, while the cartilaginous vertebræ and thorax are assuming a definitive form. The secondary centres appear after birth.

Vertebræ.

Primary Centres.—There are three primary centres, one for the body of the vertebra and one for each hemi-arch (Fig. 268, A). These centres begin to appear at about the same time, but in the cervical region the centres of ossification in the arches appear before the centres in the bodies, while in the thoracic and lumbar regions and, as a rule, in the sacral region, the reverse is true. In the fetuses studied and tabulated by Mall (1906) the first centres found were in the second to the eighth neural arches of a fetus 33 mm. long and about 57 days old. In a fetus 34 mm. long and about 58 days old centres of ossification were found in the arches of all the cervical and thoracic vertebræ, and in the bodies from the third thoracic to the first sacral. Centres of ossification in the bodies first appear in the more distal thoracic vertebræ and the first lumbar.

The centres of ossification in the arches extend from the cervical region distally in fairly regular sequence, although not with equal rapidity in different fetuses. In one fetus 53 mm. long and about 72 days old they had extended to the third sacral vertebra (twenty-seventh spinal vertebra). On the other hand, no centres were found in the arches of this vertebra in several other fetuses, 73–105 days old. The centres in the arches of the more caudally situated vertebræ arise generally in the fifth or sixth month.

The centres of ossification in the bodies of the vertebræ extend cranialwards from the thoracic and caudalwards from the lumbar region. In a fetus 70 mm. long and about 83 days old they had extended on the one hand to the epistropheus and on the other to the last sacral vertebra (Mall). There is considerable variation, however, in the rapidity with which the centres of ossification appear in the bodies of the cervical and sacral vertebræ.

The type of ossification in the bodies is endochondral (see p. 309). The cells at the centre of the body of the vertebra enlarge and become sharply set off against the intercellular substance. Finally an invasion of blood-vessels takes place, chiefly from the dorsal periosteum. Calcium salts are deposited in the cartilage and this is followed by actual ossification in fetuses about three months of age. In the arches the process of ossification is likewise endochondral.[13]

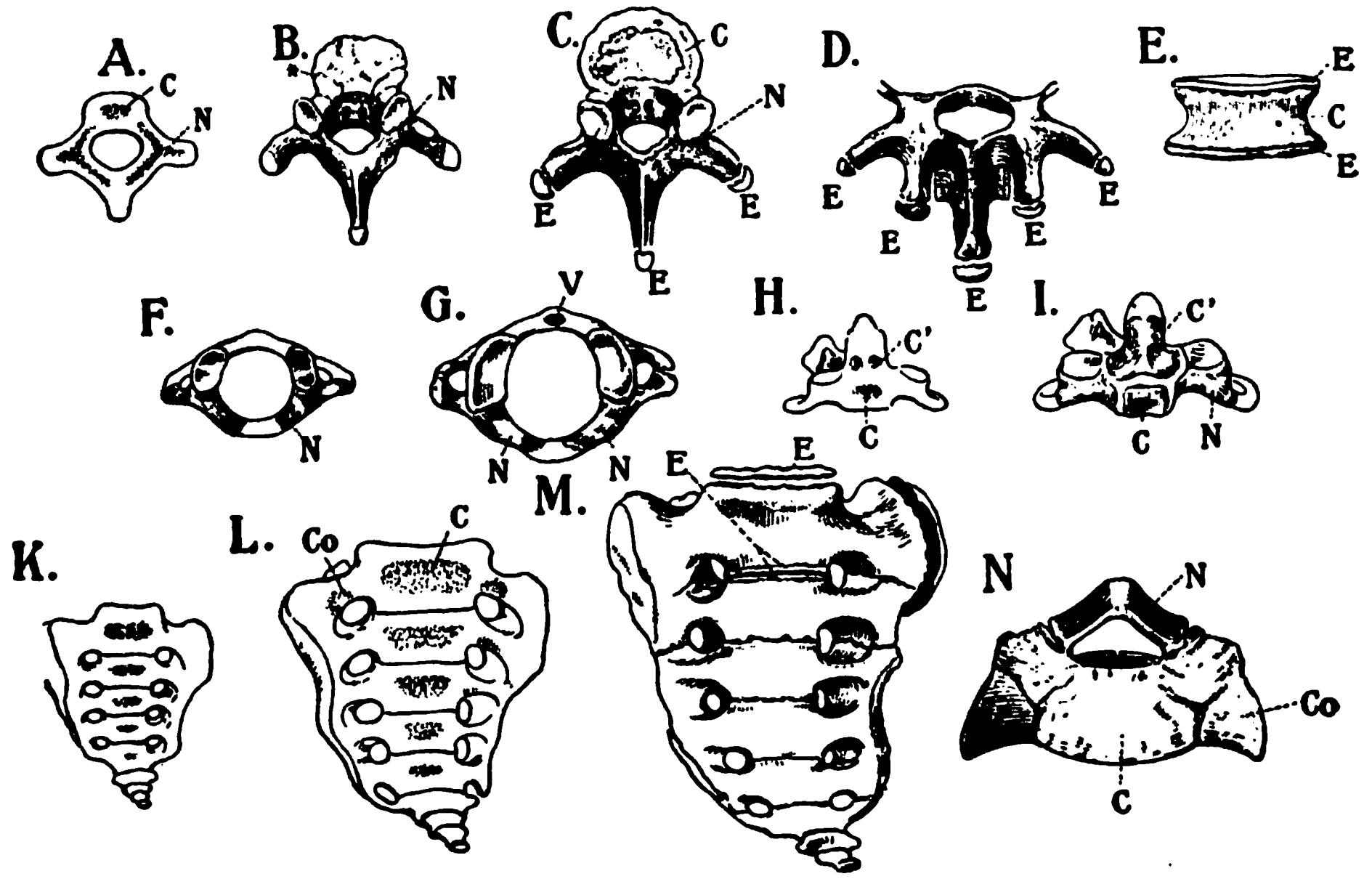

FIG. 268.—(After R. Quain, Quain's Anatomy, 10th ed., vol. ii, Pt. 1, Figs. 19, 20, 21, and 22.) Diagrams to illustrate the development of various vertebræ. A, fetal vertebra; B, thoracic vertebra of child of two years; C, thoracic vertebra in the seventeenth year; D and E, lumbar vertebra of about same age; F, atlas before birth; G, atlas in first year; H, epistropheus in fetus of seven months; I, epistropheus shortly after birth; K, sacrum before sixth month; L, sacrum at birth; M, sacrum at about twenty-third year; N (after Allen Thomson), first sacral vertebra at fourth or fifth year. *C*, centre of ossification in the body; *C'*, centre of ossification in the dens; *Co*, centre of ossification in costal element; *E*, epiphysis; *N*, centre of ossification in neural arch; *V*, centre of ossification in ventral arch of atlas.

The centre of ossification in the body of the vertebra gives rise to the greater part of the body of the definitive vertebra. Occasionally the centre may arise as or become divided into two

---

[13] In embryos cleared by the Schultze method the complementary primitive centres described by Rambaud and Renault do not appear. It is probable that they were artificially produced by the methods of preparation employed by Rambaud and Renault (Mall). The primary centres for the neural hemi-arches are single, not double. See, however, the account of the lumbar vertebræ (p. 354).

bilaterally placed centres, one for each half body. This division may persist in the adult. The centres in the arch give rise to the posterolateral part of the body of the vertebra and to the greater part of the arch with its various processes. It is in the cervical region that the centres in the arch contribute most to the body. At birth the bones arising from each of the centres of ossification of a vertebra are separated from one another by cartilage. During the first year the centres of ossification in the neural arches in most of the vertebræ become united dorsally. This fusion takes place first in the lumbar region. Between the third and sixth years the bony arches become united to the body. This fusion takes place first in the thoracic region. The neurocentral suture lies in a nearly sagittal plane in the cervical, in an oblique plane in the thoracic, and in a frontal plane in the lumbar region.

Secondary Centres; Epiphyses.—Toward the intervertebral discs the bodies of the vertebræ remain long covered by a layer of cartilage. About the seventeenth year a centre of ossification appears in the cartilage on each intervertebral surface. From each of these centres of ossification a thin epiphyseal disc of bone arises (Fig. 268, E). The discs fuse with the body about the twentieth year. The line of suture is visible usually for a year longer.

The tips of the spinous and transverse processes are covered during infancy by cartilage. In this cartilage epiphyseal centres of ossification appear between the sixteenth and the twentieth years and join the osseous arch after the twentieth year (Figs. 268, C and D). Similar secondary centres on the dorsal margins of the superior articular processes and on the costal facettes of the thoracic vertebræ have been described, but are not generally recognized. (See Poirier and Charpy, Traité d'Anatomie, vol. i, p. 342, 1899.)

Cervical Vertebræ.—In most of the cervical vertebræ, according to Leboucq (1896), the ventral limb of the transverse process is ossified by ingrowth at one end from the radix, on the other from the tip of the transverse process. In the seventh cervical vertebra frequently, in the sixth occasionally, and in the fifth and fourth rarely, there may arise during the second to the fifth month a separate centre of ossification for the costal element. While this costal element may remain free as a cervical rib, it usually becomes fused with the osseous projections from the radix and the transverse process (Figs. 269, A and B). Except in the seventh cervical vertebra the epiphyses of the spines are usually double.

Atlas.—The posterior arch and the lateral masses of the atlas are ossified from two bilaterally placed centres which correspond to the centres of the neural arches of the other vertebræ (Fig.

268, F). In the anterior arch one, or sometimes apparently two, centres of ossification appear during the first year after birth (Fig. 268, G). The dorsal union of the osseous neural arch pieces occurs between the third and fifth years. Often a separate centre of ossification appears in the spinous process before the neural arch pieces are united (Quain). The union of the posterior with the anterior arch occurs between the fifth and ninth years.

Epistropheus.—The neural arch and the body are ossified essentially as in the other cervical vertebræ except that occasionally there are two bilaterally placed centres in the body. The odontoid process becomes ossified from two bilaterally placed centres which appear in the fourth or fifth fetal month and soon fuse together (Fig. 268, H and I). These centres furnish material for a part of the superior articular processes. Between the fourth and sixth years the odontoid process becomes joined to the body and the radices of the arch, first laterally and then ventrally and dorsally. Between the centre of the base of the odontoid process and the body of the epistropheus a disc of cartilage remains till late in life. The apex of the odontoid process is formed from a separate centre of ossification, which appears in the second year and is joined to the main part of the process about the twelfth year. This apical piece probably represents an epiphysis. There are also said to be rudiments of a cranial epiphysis of the body of the epistropheus, but this statement is not generally accepted. A caudal epiphysis of the body is constant.

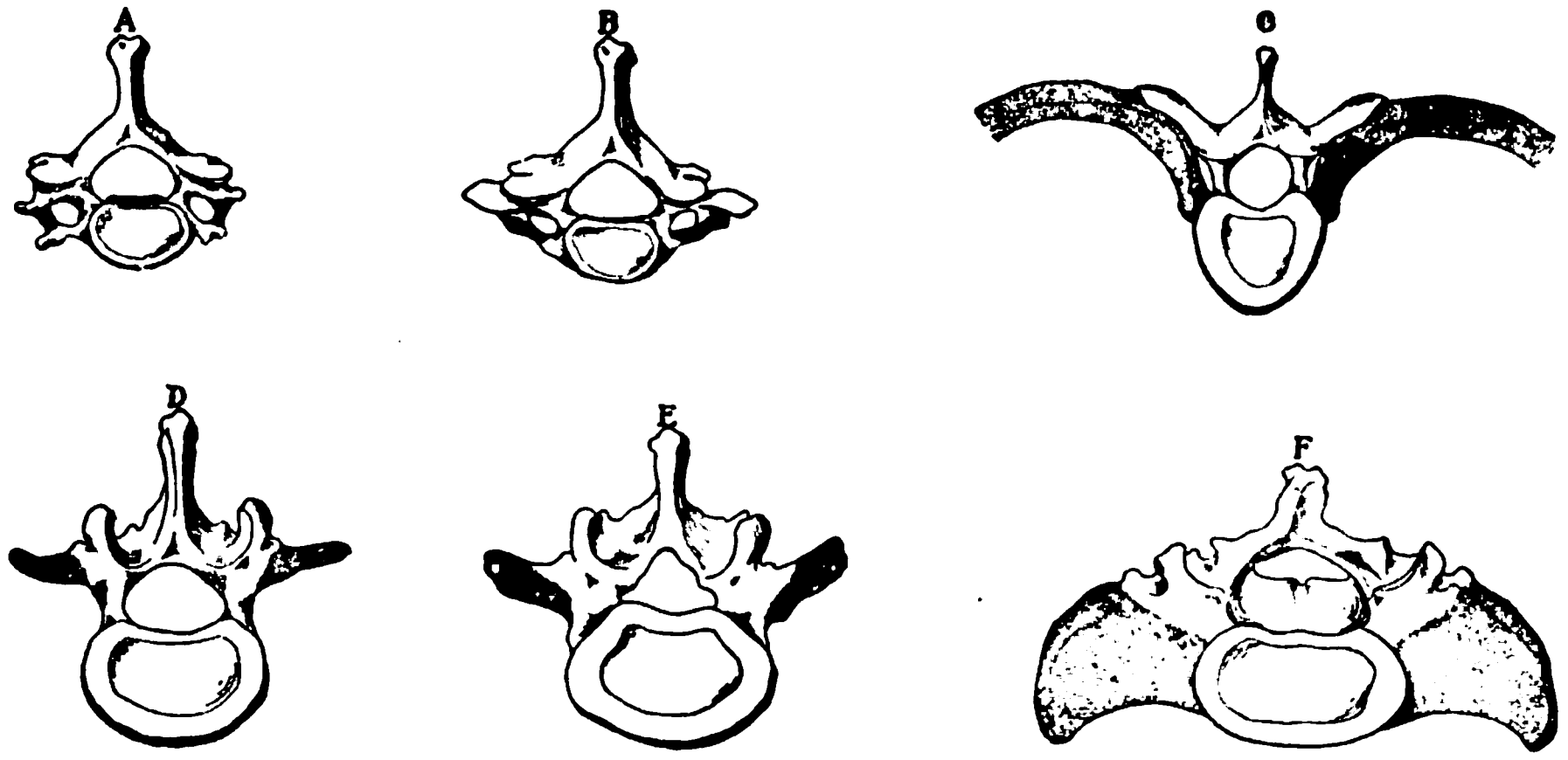

FIG. 269.—(After T. Dwight, Piersol's Human Anatomy, 1907, Fig. 158.) Diagrams illustrating the homology of the costal elements. A, sixth cervical vertebra; B, seventh cervical vertebra; C, fifth thoracic vertebra; D, second lumbar vertebra; E, fifth lumbar vertebra; F, transverse section through sacrum. The costal elements are stippled.

Lumbar Vertebræ.—The mammillary processes of the lumbar vertebræ, of the first sacral vertebra (Fawcett, 1907), and of the twelfth thoracic vertebra have special epiphyses, which appear about the time of puberty or a little later and join the rest of the vertebræ after the eighteenth year (Fig. 268, D). Somewhat rarely the costal element of the first lumbar vertebra has a separate centre of ossification, which appears early in fetal life. It may remain free as a lumbar rib. Sometimes in the fifth lumbar vertebra, and very rarely in some of the others, there are found two centres for the arch on each side; one for the radix, transverse process, and superior articular process, the other for the lamina, inferior articular process, and spine. According to Poirier and Charpy (Traité d'Anatomie, 1899), the fifth lumbar vertebra has a special epiphysis for the anterior tubercle of the transverse process.

Sacrum.—The usual primary centres are found for each of the five sacral vertebræ, one for the body and one for each neural hemi-arch. In addition there are separate centres for the costal elements of the first three or four vertebræ (Fig. 268, K and L). Sometimes, apparently, costal centres are found merely in the first two sacral vertebræ, sometimes in all five. Changes preliminary to ossification occur both in the bodies and in the neural processes of the sacral vertebræ at a period quickly following their appearance in the lumbar region. Actual ossification in these centres in the more distal vertebræ, as a rule, does not take place until a considerably later period, usually not until the fourth month in the bodies and the fifth or sixth in the arches. The centres in the arches join those of the bodies between the second and sixth years. The more caudally-situated join before the more cranially situated. Union of the laminæ with one another takes place from the seventh to the fifteenth years. It takes place first in the more cranially situated vertebræ, frequently does not occur in the fourth and seldom in the fifth. The centres for the costal elements of the first three vertebræ arise usually, according to Posth, in the fifth, sixth, and seventh fetal months respectively. That for the fourth vertebra does not usually arise until the third month after birth. There are considerable variations in the time of origin. The costal centres unite with those of the neural arches between the second and fifth years. They unite with the bodies slightly later than with the arches. Rambaud and Renault (1864) describe special centres which are said to arise in the sixth month in the transverse processes. Posth could not confirm this.

In addition to these primary centres there are epiphyseal plates for each body and two for each lateral sacral margin, one for the auricular surface and one for the rough edge distal to this (Fig. 268, M). According to Poirier (Traité, 1899), the auricular epiphyseal plates arise from the fusion of the epiphyses of the transverse processes. Fawcett (1907) describes them as arising from four costal epiphyses belonging to the first two sacral vertebræ. The tuberosities he describes as arising from the costal epiphyses of the third and fourth sacral vertebræ and transverse epiphyses of the fourth and fifth. The epiphyses of the bodies begin to arise about the fifteenth year and those of the auricular plate between the eighteenth and the twentieth years. Epiphyses for each of the tubercles of the spinous processes are described by Rambaud and Renault, 1864, and Fawcett, 1907. Fawcett describes twelve costal epiphyses, eight epiphyses belonging to the transverse processes, two to the mammillary processes and three to the spinous processes.

The sacrum begins to be consolidated about the time of puberty. The costal processes on each side fuse with one another. This is followed by union of the epiphyses with the bodies and by ossification in the intervertebral discs. The process begins caudally and extends in a cranial direction. The bodies of the first and second sacral vertebræ usually become united about the twenty-fifth year but the centres of some of the intervertebral discs may persist longer than this. The lateral epiphyseal plates unite about the twenty-fifth year.

For the recent literature on the development of the sacrum see Posth (1897) and Fawcett (1907).

Coccygeal Vertebræ.—Ossification in the coccygeal vertebræ usually takes place after birth. Each is ossified from a single centre. The centre for the first vertebra usually appears in the first year but may appear much later, that of the second appears from the fifth to the tenth year, that for the third just before and that for the fourth just after puberty. The three more distal vertebræ usually become united with one another before being joined to the first. This latter union may not occur until the thirtieth year. The first coccygeal vertebræ not infrequently becomes united to the sacrum. In old individuals the whole coccyx is often united by bone to the sacrum, more often in men than in women.

According to some authors, there are two epiphyseal plates for each of the bodies of the first four coccygeal vertebræ and in addition separate centres of ossification for each of the cornua of the first vertebræ.[14] Two centres of ossification for the fifth coccygeal vertebra, one for the body and one for an epiphysis, are also described as arising in the tenth year (Poirier and Charpy, 1899).

Ribs.

Ossification begins in the ribs before it does in the vertebræ. Centres appear in the bodies of the sixth and seventh ribs toward the end of the second month and then rapidly come to view in the

---

[14] According to Poirier, the primary centres appear in the fourth or fifth year in the first vertebra, in the sixth to the ninth year in the second, third and fourth. The epiphyseal plates appear from the sixth to the twelfth year.

other ribs. The centre in the first rib usually appears before that in the twelfth. All are usually present by the end of the second month, but that in the twelfth may not appear until later. In two specimens out of 29 fetuses with an estimated age of 55 to 110 days, Mall (1906) found a centre of ossification in the costal element of the seventh cervical vertebra.

The osseous nucleus arises near the angle of each rib and extends rapidly toward the head. At the end of the fourth month the osseous shaft of the rib bears about the same proportional relation to the costal cartilage which it has in the adult. About puberty epiphyseal centres arise, one for the articular surface of the head, one for the articular surface of the tubercle, and one for the non-articular surface of the tubercle. Frequently only one epiphysis seems to arise on the tubercle (Fig. 270). Usually no tubercular epiphysis is found on the eleventh and twelfth ribs. The union of the epiphyses with the shaft takes place after the twentieth year. The epiphysis of the head does not usually join before the twenty-fourth year.

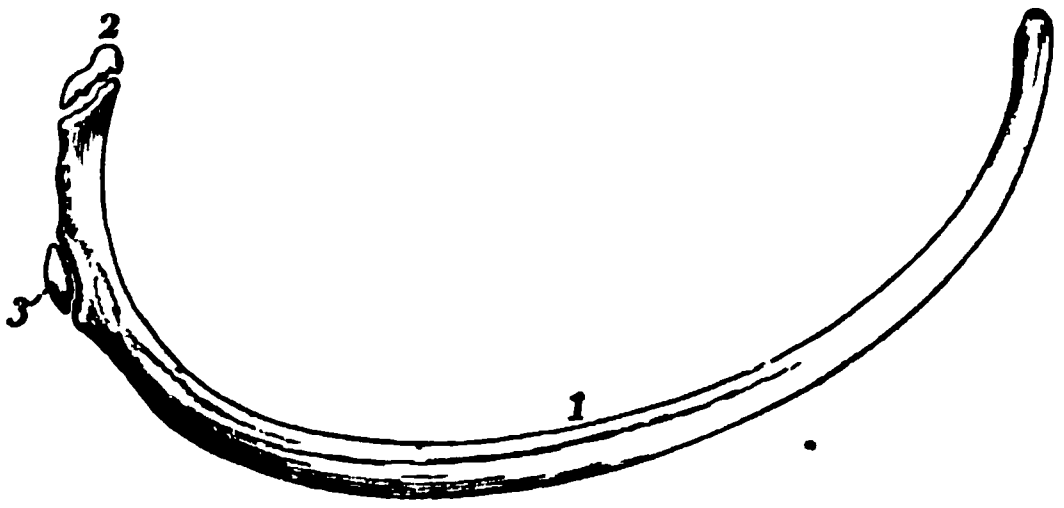

Fig. 270.—(After R. Quain, Quain's Anatomy, 10th ed., vol. ii, Pt. I, Fig. 31.) Diagram to illustrate the epiphyses of the head and tubercle of one of the mid-thoracic ribs at about the twentieth year. 1, body; 2, epiphysis of the head; 3, that of the tubercle.

The centres of ossification of the ribs are subperiosteal in character.

In the adult the first costal cartilage may become partially or completely covered by a superficial layer of bone. Late in life the other costal cartilages may become thus covered, especially on the superficial surface. This process is more frequent in men than in women (Quain).

Sternum.

Ossification in the sternum begins considerably later than in the ribs. The centres of ossification are variable in the time and place of their appearance (Fig. 271, B and D). About the middle of the sixth fetal month a centre usually appears in the manubrium. Often other accessory centres appear (Fig. 271, D). Thus Mayet (1895) in fourteen sternums out of eighteen found one or more accessory centres in the manubrium; in ten instances one extra centre situated caudalwards from the main centre; in four instances two or more accessory centres. In addition there are two epiphyseal centres next the sternoclavicular joints. These fuse with the manubrium between the twenty-fifth and twenty-eighth years. The body of the sternum is usually ossified from five or from seven centres. The segment next the manubrium is usually ossified from a single centre which appears in the seventh month. The next segment may be ossified from a single centre or from a pair of centres. The last two segments most frequently are each ossified from a pair of centres, but may be ossified from a single centre. As a rule, all the centres of ossification except those in the last segment are present at birth and these last appear during the first year after birth. By the sixth year the centres of each pair usually have become fused with one another. Generally the various osseous segments of the body of the sternum become united in the 12–25 years, but lines indicating the boundaries between them remain till late in life. The manubrium and body rarely fuse; according to Gray, in about 6 or 7 per cent. of cases after 60 years of age. There may be a foramen in the sternum due to lack of fusion of a pair of centres of ossification or to failure of a centre of ossification to develop (Fig. 271, E).

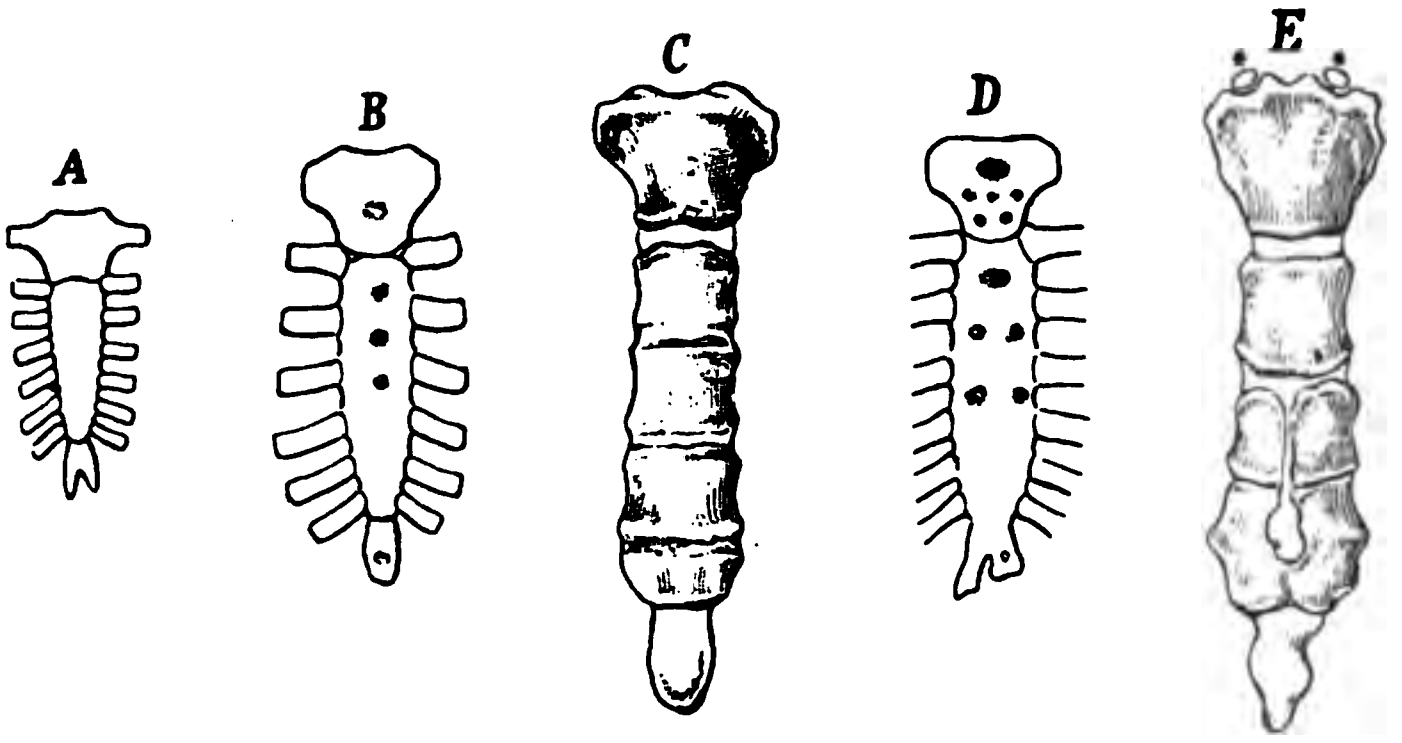

Fig. 271.—(After R. Quain, Quain's Anatomy, 10th ed., vol. ii, Pt. 1, Fig. 30.) Diagram illustrating the ossification of the sternum. A, cartilaginous sternum; B, sternum at birth, showing nuclei for manubrium and first three sternal segments; C, sternum soon after puberty; D, sternum with an unusual number of ossific centres; E, example of perforated sternum; * episternal bones.

Four times out of twelve Mayet found the bilaterally placed centres of the body fused vertically with those of their own side before the fusion of pairs across the median line had taken place.[15]

The ensiform process is ossified from a single centre which appears late, usually not before the sixth year, and rarely transforms the whole process into bone. The centre of ossification arises at the base of the process. The osseous ensiform process is usually united to the body in middle life.

---

[15] See Markowski, 1902, 1905, for a somewhat different description of the ossification of the sternum.

Relative Length of the Different Regions of the Spine during Development.

In 1879 Aeby contributed an important paper dealing with the length of the various regions of the spinal column at different ages, with the height of the constituent vertebræ and with the thickness of the intervertebral discs in man. He showed that in young embryos the cervical region is relatively much longer, the lumbar much shorter than in the adult. These results have been confirmed by Moser (1889), Ballantyne (1892), and others. It has been shown by Bardeen (1905) that, in embryos during the second and third months of development, if the length of the thoracic region be taken as 100 the length of the cervical region is about 60, the lumbar from 40 to 50, the sacral from 33 to 42.5. In the adult the cervical region has been estimated at from 41.7 to 47.5, the lumbar from about 56.3 to 71.6, the sacrococcygeal from 61 to 68. (See Ravenel, 1877, Aeby, 1879, Tenchini, 1894, Dwight, 1894 and 1901.)

Curvature of the Spinal Column during Development.

During the first month of embryonic development the spine acquires a marked ventral flexion (see 2, Fig. 272). From this period until the time of birth the cervico-thoraco-lumbar region of the spine, at first rapidly and then more gradually, becomes straighter (109, 144, 108, 145, 184, Fig. 272). The sacral region also becomes much straightened during the second and third month of embryonic development (109, 144, 108, 145, 184, Fig. 272), but subsequently acquires a second ventral flexion (*Ad,* Fig. 272). During the latter half of embryonic development there takes place a marked dorsal flexion at the lumbosacral border (184, Fig. 272). After birth and the assumption of the erect position dorsal flexion takes place in the cervical and the lumbar regions (*I* and *Ad,* Fig. 272).

Number of Vertebræ and Regional Differentiation.

At the period of greatest development of the caudal extremity of the human embryo thirty-six vertebræ usually are present. This stage is reached in embryos from 8–16 mm. in length. Occasionally the number of vertebræ may reach thirty-seven. Beyond the last vertebra the chorda dorsalis extends for some distance distally (Fig. 273).

Regional differentiation, as already pointed out, becomes well marked toward the latter part of the blastemal period. The thoracic region is clearly demarcated by the great development of the costal processes of the thoracic vertebræ. The sacral region becomes definitely marked when the blastema of the sacrum comes into contact with that of the ilium. According to Rosenberg (1877, 1899, 1906), the costal processes of the seventh cervical and the first lumbar vertebra at the period of chondrification are to be regarded as ribs, so that in subsequent development there is a reduction in the number of thoracic vertebræ. While each costal element of the seventh cervical vertebra has a centre of chondrification like a true rib, and near the body of the vertebra appears enough like a rib to be called a "rudimentary rib," one is not more likely to mistake it for the first rib than one would be to mistake the costal element of the seventh cervical vertebra in the adult for a true rib. This is even more true of the costal element of the first lumbar vertebra. Although this normally probably has a separate centre of chondrification, it has distinct characteristics which sharply demarcate it from the twelfth thoracic rib, characteristics of form as well as of size. (See Figs. 261 and 262, from an article which has been cited by Rosenberg in support of his hypothesis.)

According to Rosenberg, the sacrum is composed at first of a more distal set of vertebræ than those belonging to it in the normal adult condition; in other words, the iliac attachment of the skeleton of the limb is supposed to advance cranialwards along the spinal column during ontogeny. The studies of Holl (1882), Paterson (1893), Bardeen (1904), and others have shown that the views of Rosenberg do not correspond with the conditions found in the majority of the human embryos and fetuses, at the period under discussion, which have been carefully studied.

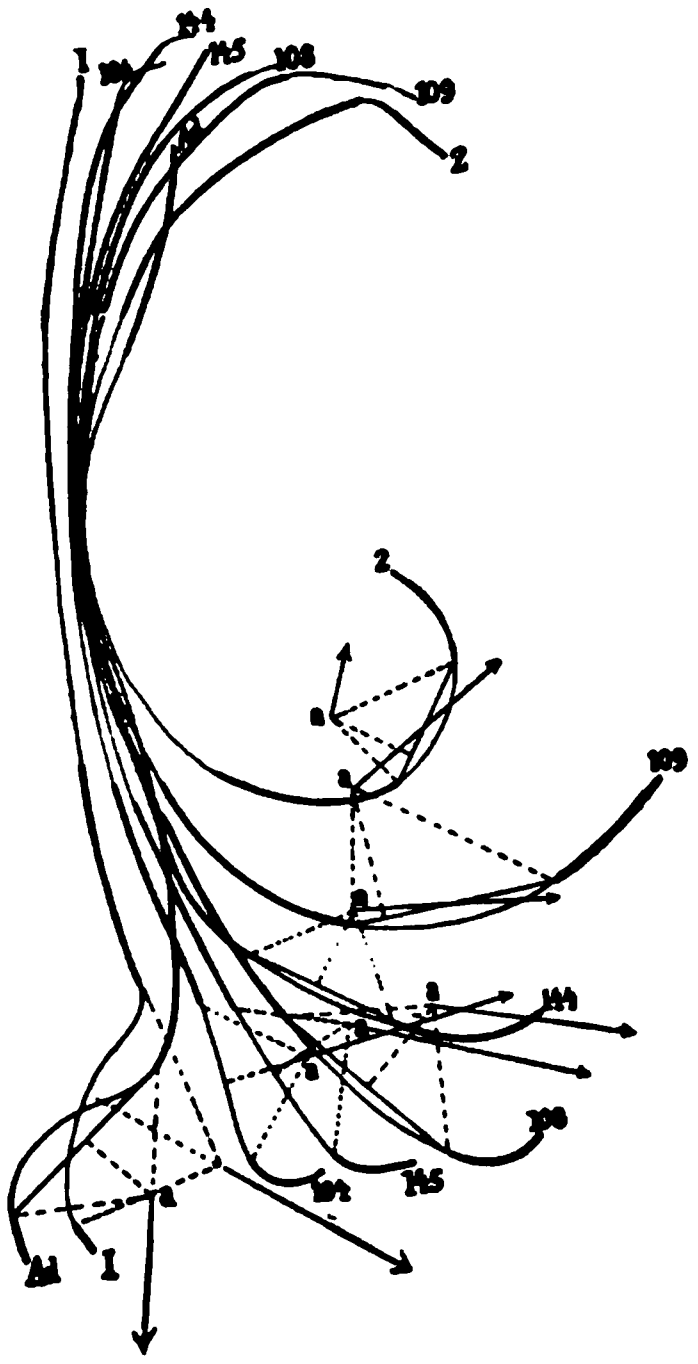

FIG. 272.—Diagram to show the curvature of the spinal column, the proportional lengths of the various regions, the relations of the acetabula to the sacral region, and the direction of the long axis of the femur in a series of embryos and fetuses 7 to 50 mm. in length, in an infant and in an adult. Each curved line represents the chorda dorsalis of an individual. The cervical, lumbar, and coccygeal regions are represented by the heavy, the thoracic and sacral by the light portions of the line. The approximate position where a line joining the centres of the two acetabula would cut the median plane is represented at *a*. For Embryo II, in which the skeleton of the inferior extremity is not yet differentiated, the position of the future acetabula is deduced from Embryo CLXIII, length 9 mm. The line passing in each instance from *a* and terminating in an arrow point represents the long axis of the femur. For Embryo II this line is pointed toward the centre of the tip of the limb-bud. From *a* in each instance a perpendicular is dropped to a line connecting the two extremities of the sacral region. The numbers refer to the following embryos and fetuses in the collection of Professor Mall: 2, II, length 7 mm.; 109, CIX, length 11 mm.; 144, CXLIV, length, 14 mm.; 108, CVIII, length 20 mm.; 145, CXLV, length 33 mm.; 184, CLXXXIV, length 50 mm.; I new-born infant; Ad, Adult.

Variation in the number of vertebræ belonging to each of the regions of the spinal column occurs in the embryo as well as in the adult. Bardeen (1904) reaches the conclusion that the frequency of variation in the embryo is probably the same as that in the adult. Before this is definitely decided a much greater number of embryos must be studied than are at present on record. Regional variation in the embryo and fetus must not be confounded with the normal changes taking place in the development of the costal elements of the vertebræ of the cervical and lumbar regions. A separate centre of chondrification in the costal element of the first lumbar vertebra does not indicate a lumbar rib unless the costal process and the centre of chondrification resemble morphologically the twelfth thoracic rib so that there is no sudden change of form from the one to the other.

Comparative Development of the Vertebræ.

For an account of the embryological development of the vertebræ in the lower vertebrates and a summary of the literature relating to the subject the excellent article by Schauinsland in Hertwig's Handbuch der Entwickelungsgeschichte der Wirbeltiere should be consulted. In the anamniotes, the chorda dorsalis plays a relatively much greater part than in the amniotes, and in the sauropsida a much greater part than in the mammals. Primitively there are apparently four arch pieces developed on each side in each sclerotome, two dorsal and two ventral. As a rule, the cranially situated dorsal and ventral arch pieces of each sclerotome are incomplete while the caudally situated arches are firmly united to the sheath of the notochord. In the amniotes the cranial arch pieces of one sclerotome unite with the caudal of the sclerotome next cranialwards to form the definitive vertebral arches and arch bases. The bodies of the vertebræ develop between the regions of attachment of the arches to the chorda. The neural and articular processes come from the dorsal arches, the transverse, costal, hæmal, and hypochordal (see p. 345) processes from the ventral arches.

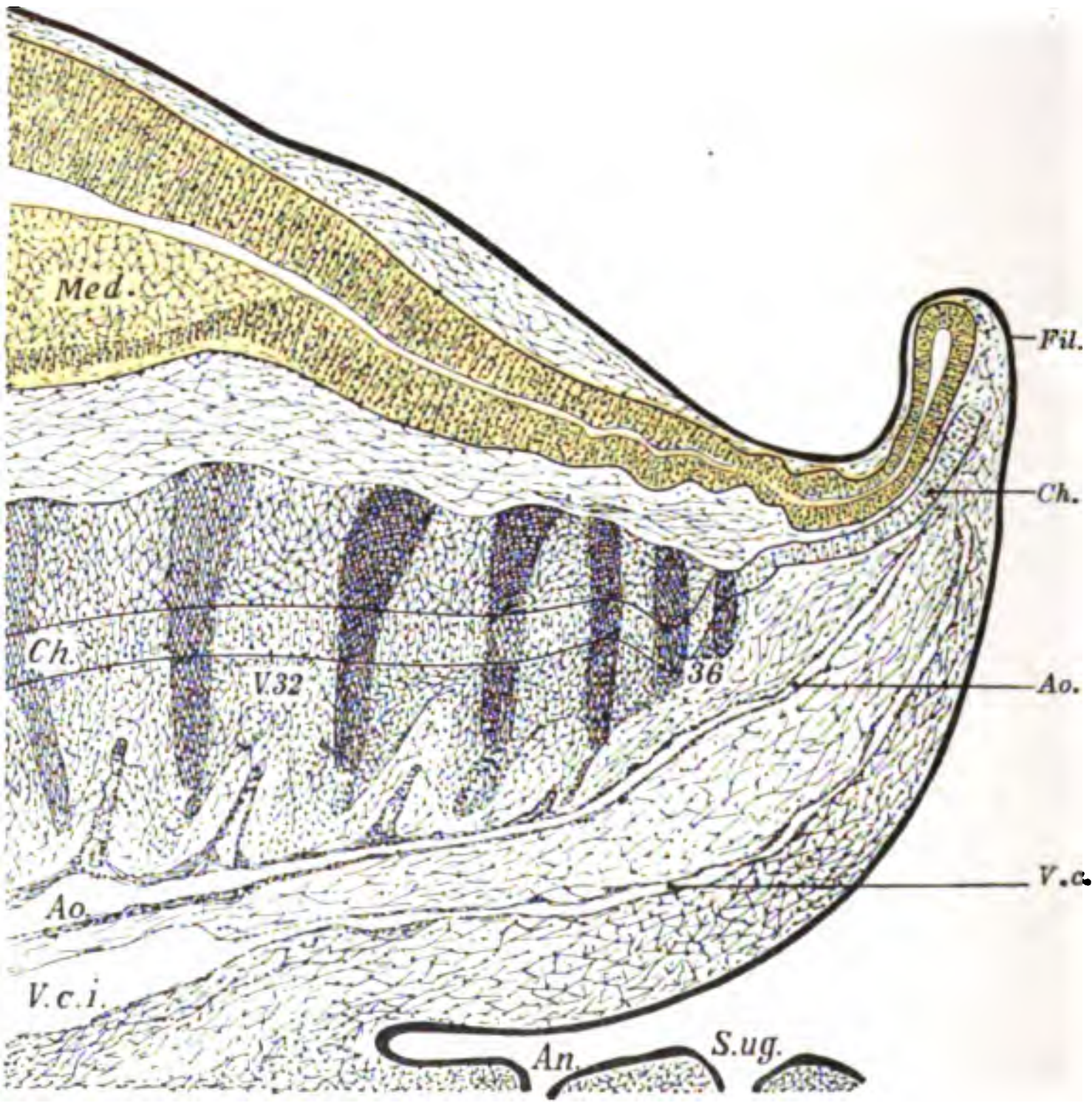

FIG. 273.—(After Harrison, 1901.) Sagittal cut through the caudal end of an embryo of 14 mm. (No. 144 of the Mall collection), combined from several sections. Magn. 91 : 1. The chorda and medullary tube extend into the rudiment of the tail. The total number of vertebræ is thirty-six, seven of which are coccygeal. These do not extend into the caudal appendage. *An.*, anus; *Ao.*, aorta caudalis (art. sacralis media); *Ch.*, chorda dorsalis; *Fil. caud.*, filum caudale; *Med.*, spinal cord; *S. ug.*, sinus urogenitalis; *V. c. i.*, vena cava inferior (v. sacralis media).

In the development of the human vertebræ the caudal dorsal and ventral arch anlages of each sclerotome arise simultaneously and are soon united by a common base or chordal process to the mesenchymal sheath about the notochord. The cranial dorsal and ventral arch anlages arise later, the dorsal becoming the interdorsal membranes, the ventral the interventral membranes. The cartilages of the bodies develop about the notochord between the bases of the cranial and caudal ventral arch anlages. But one centre of chondrification appears to give rise to the definitive vertebral hemi-arch, although a separate centre arises for the costal process.

The ossification of the definitive vertebræ varies so in different classes of vertebrates that no comparison of the process will be attempted here.

BIBLIOGRAPHY.

(On the development of the spinal column and of the thorax.)

Adolphi, H.: Uber die Variationen des Brustkorbes und der Wirbelsäule des Menschen. Morph. Jahrb. Bd. 33. 1905.

Aeby: Seltene Rippenanomalie des Menschen. Reichert's und du Bois-Reymond's Arch. f. Anat. und Physiol. 1868.

Die Altersverschiedenheiten der menschlichen Wirbelsäule. Arch. f. Anat. und Physiol. Anat. Abt. S. 77. 1879.

Albrecht, P.: Uber den Pro-atlas, einen zwischen dem occipitale und dem Atlas der amnioten Wirbeltiere gelegenen Wirbel und den N. spinalis I. s. proatlanticus. Zool. Anz. Bd. 3. 1880.

Alexander, Béla: Beiträge zur Kenntnis der Ossifizieurung der kartilaginösen Wirbelsäule. Orvosi Hetilap. Nr. 51. 1903.

Die Entwicklung der knöchernen Wirbelsäule. Arch. und Atlas der normalen und patholog. Anat. in Röntgenbildern. Hamburg 1906.

Allen: On the Varieties of the Atlas in the Human Subject. Journ. of Anat. and Physiol. Vol. 14. 1879.

Ancel et Sencert: Variation numérique de la colonne vertébrale. Comptes rend. Assoc. des Anat., p. 158–165. Lyon 1901.

Les variations des segments vertébro-costaux. Bibliogr. Anat. t. 10, p. 214–239. 1902.

De quelques variations dans le nombre des vertèbres chez l'homme. Journ. de l'Anat. et de la Physiol. Année 38, p. 217–258. 1902.

Anderson: Eight True Ribs in Man. Anat. Anz. Bd. 4. 1889.

Aron, E.: Zur Kasuistik der Halsrippen. Berlin klin. Wochenschr. Jahrg. 29. 1892.

Ballantyne: Spinal Column in Infants. Edinburgh Medical Journal. 1892.

Barchielli, Alberto: Variazione del margine superiore dello sterno umano e loro significato. Monit. Zool. Ital. Vol. 15. 1904.

Bardeen: Costo-vertebral Variation in Man. Anat. Anz. Bd. 18, p. 377. 1900.

Vertebral Variation in the Human Adult and Embryo. Anat. Anz. Bd. 25, p. 497. 1904.

Development of the Thoracic Vertebræ in Man. Amer. Journ. of Anat. Vol. 4, p. 163. 1905.

Studies of the Development of the Human Skeleton. The Development of the Lumbar, Sacral and Coccygeal Vertebræ. The Curves and the Proportionate Lengths of the Spinal Column during the First Three Months of Embryonic Development. Amer. Journ. of Anat. Vol. 4, p. 265–302. 1905.

Bardeleben, K. v.: Beiträge zur Anatomie der Wirbelsäule. Jena 1874.

Uber das episternum des Menschen. Sitzb. med. naturw. Ges. Jena. Bd. 146. 1879.

Uber Verbindungen zwischen dem fünften und sechsten sowie zwischen dem sechsten und siebenten Rippenknorpel. Anat. Anz. Bd. 15. 1898.

Bartels, M.: Uber Menschenschwänze. Arch. f. Anthrop. Bd. 13. 1881.

Bernhardt, M.: Uber das Vorkommen und die klinische Bedeutung der Halsrippen beim Menschen. Berlin. klin. Wochenschr. Jahrg. 32. 1894.

Bianchi, S.: Sull' interpretazione morfologica della prima vertebra coccigea nell' uomo. Atti della R. Accad. dei Fisiocritici in Siena. Ser. 4. Vol. 7. 1895.

Black, J.: Report of a Case of Cervical Ribs. Journ. Anat. and Physiol. Vol. 33. 1898.

Bockenheimer: Zur Kenntnis der Spina bifida. Arch. klin. Chir. Bd. 65. 1902.

Bogusat, H.: Anomalien und Varietäten des Brustbeins. Diss. med. Königsberg 1902.

Bolk: Ueber eine Wirbelsäule mit nur sechs Halswirbeln. Morph. Jahrb. Bd. 29, S. 84–93. 1901.

Zur Frage der Assimilation des Atlas am Schädel beim Menschen. Anat. Anz. Bd. 28. 1906.

Brugsch, Th.: Die Entwicklung des Ligamentum caudale beim Menschen. Diss. med. Leipzig 1903.

Chiarugi, G.: Per la storia dell' articolazione occipito-atlo assoidea. Monit. Zool. Ital. 1890.

Cornet, Y.: Note sur le prétendu pro-atlas des mammifères et de Hatteria punctata. Bull. Acad. Roy. des Sciences de Belg. 1888.

Cunningham, J.: The Neural Spines of the Cervical Vertebræ as a Race-Character. Journ. of Anat. and Physiol. Vol. 20. 1886.

Proportion of Bone and Cartilage in the Lumbar Section of the Vertebral Column of Apes and Several Races of Man. Journ. of Anat. and Physiol., Vol. 24, p. 117. 1889.

The Occasional Eighth True Rib in Man. Journ. Anat. and Physiol. Vol. 24. 1889.

Dukes, L.: Anomalies in the Cervical and Upper Thoracic Region, involving the Cervical Vertebræ, First Rib and Brachial Plexus. Journ. of Anat. and Physiol. Vol. 36. 1902.

Dwight, T.: The Sternum as an Index of Sex and Age. Journ. of Anat. and Physiol. Vol. 15. 1881.

Methods of Estimating the Height from Parts of the Skeleton. Medical Record. 1894.

Description of Human Spines. Memoirs Boston Society of Natural History. Vol. 5, p. 237–312. 1901.

A Transverse Foramen in the Last Lumbar Vertebra. Anat. Anz. Bd. 20, p. 571 bis 572. 1902.

v. Ebner: Urwirbel und Neugliederung der Wirbelsäule. Wiener Sitzungsber. Bd. 97. 3 Abt. 1888.

Uber die Beziehungen des Wirbels zu den Urwirbeln. Wiener Sitzungsberichte. Bd. 101. Abt. 3. 1892.

Eggeling, H.: Uber den oberen Rand des menschlichen Brustbeinhandgriffes. Verh. Anat. Ges. p. 41–48. Heidelberg 1903.

Zur Morphologie des manubrium sterni. Festschrift zum 70. Geburtstag von E. Haeckel. Jena 1904.

Falcone, C.: Sopra una particolarità di sviluppo della colonna vertebrale nell' embrione umano. Giorn. Internaz. Sc. Med. Anno 23, p. 543–549. 1901.

Favaro, G.: Il canale caudale nell' uomo. Verh. Anat. Ges. Padua 1906, p. 638.

Fawcett, Ed.: On the Completion of Ossification of the Human Sacrum. 6 Fig. Anat. Anz. Bd. 30, p. 414. 1907.

Fick, A. G.: Zur Entwicklungsgeschichte der Rippen und Querfortsätze. Arch. f. Anat. und Physiol. Anat. Abtl. p. 30–42. 1879.

Fischel, A.: Untersuchungen über die Wirbelsäule und den Brustkorb des Menschen. Anat. Hefte. Bd. 31. 1906.

Fischer, H.: Fissura sterni congenita mit partieller Bauchspalte. Deutsche Zeitschrift f. Chirurgie. Bd. 12. 1880.

Fol: Sur la queue de l'embryon humain. C. R. de l'Acad. de Sc., Paris. Vol. 100, p. 1469. 1885.

Froriep, A.: Kopfteil der Chorda dorsalis bei mensch. Embryonen. Festschr. f. Henle. 1882.

Zur Entwicklungsgeschichte der Wirbelsäule. Arch. f. Anat. und Physiol. Anat. Abt. S. 177–184. 1883; S. 69–150. 1886.

Funke, E.: Uber einen Processus ondontoideus atlantis hominis. Anat. Anz. Bd. 14. 1898.

Ganfini: Sopra alcune facette articolari del basi-occipitale in rapporto ai processi basilari. Monit. Zool. Ital. Vol. 17, p. 60–68. 1906.

Gaupp, E.: Die Entwicklung der Wirbelsäule. Zusammenfassende Ubersicht. Zool. Centralblatt. Bd. 3 u. 4. 1896–1897.

Gérard, G.: Anomalies osseuses. Sur la présence d'une côte cervicale articulée avec la première côte formée elle-même de la fusion des deux premières côtes thoraciques. Bibliogr. Anat. Vol. 8. 1900.

Grimme, H.: Anomalien der Halswirbelsäule, nach den dem anatomischen Institute in Göttingen gesammelten Präparaten. Inaug. Dissert. Göttingen 1904.

Gruber: Uber die Halsrippen des Menschen mit vergleich. anatomischen Bemerkungen. Mémoires de l'Acad. des Sciences de St. Pétersbourg. Vol. 13, Nr. 2. 1869.

Hagemann, Nicol.: Selten vorkommende Abnormität des Brustkorbes. Jahrb. f. Kinderheilk. 1880.

Hannover: Primordialbrusken og dens Forbening: Truncus og Extremiterne hos Menneskel för Födselen. Vidensk. Selskabs. Skr. Vol. 4. 1887.

Harrison, R. G.: On the Occurrence of Tails in Man, with a Description of the Case reported by Dr. Watson. The Johns Hopkins Bulletin. Vol. 12, p. 121–129. 1901.

Hasse, C.: Die Entwicklung des Atlas und Epistropheus des Menschen und der Säugetiere. Anat. Studien. Bd. I., S. 542–568. 1873.

Hasse, C., und Schwarck, W.: Studien zur vergleichenden Anatomie der Wirbelsäule insbesondere des Menschen und der Säugetiere. Anat. Studien, Bd. 1, S. 21–171. 1873.

Herber: Uber Halsrippen. Med. Diss. Bonn 1903.

Hoffmann: Zur Morphologie des Schultergürtels und des Brustbeins bei Reptillien, Vögeln, Säugetieren und dem Menschen. Niederl. Arch. f. Zool. Bd. 5. 1879.

Holl, M.: Uber die richtige Deutung der Querfortsätze der Lendenwirbel und die Entwicklung der Wirbelsäule des Menschen. Sitzungsb. d. K. Akad. d. Wiss. Math.-naturw. Klasse. Wien. Bd. 85, S. 181–232. 1882.

v. Jhering, H.: Uber den Begriff der Segmente bei Wirbeltieren und Wirbellosen, nebst Beobachtungen über die Wirbelsäule des Menschen. Centralbl. f. d. med. Wiss. Nr. 9. 1878.

Keibel, Fr.: Uber den Schwanz des menschlichen Embryo. Arch. f. Anat. und Physiol. Anat. Abtl. 1891.

Keith, A.: The Extent to which the Posterior Segments of the Body have been transmutated and oppressed in the Evolution of Man and allied Primates. Journ. of Anat. and Physiol. Vol. 37. 1903.

Klein, C.: Uber die Konfiguration der lumbalen Intervertebralräume. Mitt. aus der Grenzgeb. d. Med. und Chir. Bd. 12, Heft 5. 1903.

Koch, W.: Beiträge zur Lehre von der Spina bifida. Kassel 1881.

Kollmann, J.: Die Entwicklung der Chorda dorsalis bei dem Menschen. Anat. Anz. Bd. 5, p. 308–321. 1890.

Krausse, O.: Uber Halsrippen des Menschen. Med. Diss. Leipzig 1902.

Kravetz, L. P.: Entwicklungsgeschichte des Sternum und des Episternalapparats der Säugetiere. Bull. Soc. Impér. Natur. Moscou. Année 1905. Moscow 1906.

Entwicklungsgeschichte des Sacrum und des Episternalapparats der Säugetiere. Bull. Soc. Imp. Nat. Ebenda.

LAMMERS: Zur Frage der Entstehung des Promontoriums während der Fetalperiode. Diss. Strassburg 1904.

LEBOUCQ, H.: Recherches sur le mode de disparition de la chorde dorsale chez les vertébrés supérieurs. Arch. de Biol. T. 1. 1880.

De quelques anomalies des côtes chez l'homme. Extr. des Ann. de la Soc. de Méd. de Gand. 1885.

1. Zur Frage nach der Herkunft überzähliger Wirbel. 2. Die Querfortsätze der Halswirbel in ihrer Beziehung zu Halsrippen. Verhandlg. der Anat. Gesellsch. 8 Vers. Anat. Anz. Bd. 9. Erg. Heft. 1894.

Recherches sur les variations anatomiques de la première côte chez l'homme. Arch. de Biol. Vol. 15, p. 125. 1898.

LE DAMANY, P.: L'adaptation de l'homme à la station debout. Journ. de l'Anat. et Physiol. Vol. 41, p. 133. 1905.

LOVETT, R. W., DAVIS, S. R. ET MONTGOMERY, A. M.: Curve fisiologiche della spina umana, loro origine e sviluppo. Arch. ortoped. Anno 23, p. 372–389. 1906.

LOW: Description of a Specimen in which there is a Rudimentary First Rib, with Thirteen Pairs of Ribs and Twenty-five Presacral Vertebræ. Journ. of Anat. and Physiol. Vol. 34, p. 451–457. 1901.

LUSCHKA, H.: Die Halsrippen und die Ossa suprasternalia des Menschen. Denkschrift d. Kais. Akad. d. Wiss. Bd. 16, Abt. 2. Wien 1859.

MACALISTER: Notes on the Development and Variation of the Atlas. Journ. Anat. and Physiol. Vol. 27. 1893.

The Development and Varieties of the Second Cervical Vertebra. Journ. Anat. and Physiol. Vol. 28. 1894.

MALL, F. P.: On Centers of Ossification in Human Embryos less than 100 Days old. Amer. Journ. Anat. Vol. 5, p. 433. 1896.

MARCHAND: Article on Spina Bifida in Eulenburg's Realencyclopädie. Bd. 22, S. 578–601. 1899.

MARKOWSKI, J.: Uber die Varietäten der Ossification des Brustbeins usw. Poln. Arch. f. Biol. und Med. Wiss. Bd. 1. 1902.

Sollte der Verknöcherungsprozess des Brustbeins von keiner morphologischen Bedeutung sein? Anat. Anz. Bd. 26, S. 248–269. 1905.

MAYET: Recherches sur l'ossification du sternum chez les sujets normaux et chez les rachitiques. Bull. de la société anat. de Paris. Vol. 70, p. 381–384. 1895.

Note sur un nouveau procédé de recherche et d'étude des points d'ossification epiphysaire. Bull. Soc. Anat. Vol. 70, p. 375. Paris 1895.

MEYER, R.: Uber einige Abnormitäten am Schwanzende menschlicher Feten. Virchow's Arch. Bd. 180, S. 334. 1906.

MOSER: Das Wachstum der menschlichen Wirbelsäule. Diss. Strassburg 1889.

MÜLLER, CH.: Zur Entwicklung des menschlichen Brustkorbes. Morph. Jahrb. Bd. 35, S. 591–696. 1906.

NAUNYN: Spina bifida occulta. Deutsch. med. Wochenschrift. 1898.

PAPILLAULT, G.: Variations numériques des vertèbres lumbaires chez l'homme. Bull. de la Soc. d'Anthropologie de Paris. T. 9, p. 198–222. 1900.

PATERSON, A. M.: The Human Sacrum. Scientific Transactions of the Royal Dublin Society. Vol. 5, p. 123. 1893.

The Sternum; Its Early Development and Ossification in Man and Mammals. Journ. of Anat. and Physiol. Vol. 35, p. 31–32. 1900.

The Human Sternum—Three Lectures delivered at the R. College of Surgeons. London 1904.

PAULISCH, O.: Das vordere Ende der chorda dorsalis und der Frank'sche Nasenkamm. Arch. f. Anat. und Physiol. Anat. Abtl. S. 187–215. 1887.

PILLING: Uber die Halsrippen des Menschen. Diss. Rostock 1894.

PJÄTNIZKY, J. J.: Uber den Bau des menschlichen Schwanzes und über menschliche Schwänze im allgemeinen. Diss. St. Petersburg 1893. (Russian.)

PLANTEAU, H.: Développement de la colonne vertébrale. Thèse de Paris 1883.

POSTH, M.: Le Sacrum. Thèse de Paris 1897.

RABAUD, E.: Genèse des spina bifida. Arch. gén. de méd. N. s. Vol. 5, p. 283–309. 1901.

RAWZI: Zur Kasuistik der Halsrippen. Wien. Klin. Wochenschr. 1903.

RAVENEL: Die Massenverhältnisse der Wirbelsäule und des Rückenmarks beim Menschen. Zeitschr. f. Anat. und Entwicklungsg. Bd. 2, S. 334. 1877.

RECKLINGHAUSEN, F. v.: Untersuchungen über spina bifida. Virchow's Arch. Bd. 105. 1886.

RETZIUS, A.: Uber die richtige Deutung der Seitenfortsätze an den Rücken- u. Lendenwirbeln beim Menschen und bei den Säugetieren. Arch. f. Anat. u. Physiol. 1849.

ROBIN: Mémoire sur le développement des vertèbres, atlas et axis. Journ. de l'Anat. et de la Physiol. Vol. 1, p. 274–209. 1864.

Memoire sur l'évolution de la notocorde. Paris. 212 pp., 12 pls., 63 Figs. 1868.

RODENACKER, G.: Uber den Säugetierschwanz mit besonderer Berücksichtigung der kaudalen Anhänge des Menschen. Diss. Freiburg-Breisgau 1898.

ROSENBERG, E.: Uber die Entwicklung der Wirbelsäule und das centrale carpi des Menschen. Morphol. Jahrb. Bd. I, S. 83. 1876.

Uber die Entwicklung der Wirbelsäule. Sitzungsber. des Naturforschergesellschaft bei der Universität Dorpat. Bd. 7. Sitzung vom 17. Febr. 1883.

Uber eine primitive Form der Wirbelsäule des Menschen. Morphol. Jahrb. Bd. 27, S. 1-118. 1899.

Bemerkungen über den Modus des Zustandekommens der Regionen an der Wirbelsäule des Menschen. Morph. Jahrb. Bd. 36. 1907.

RUGE, G.: Untersuchungen über Entwicklungsvorgänge am Brustbein und der Sternoclavicularverbindung der Menschen. Morphol. Jahrb. Bd. 6, S. 362–414. 1880.

SCHAUINSLAND, H.: Die Entwicklung der Wirbelsäule nebst Rippen und Brustbein. O. Hertwig's Handbuch der Entw.-Lehre. Bd. 3. 1906.

SCHULTZE: Uber embryonale und bleibende Segmentierung. Verhandl. der Anat. Gesellschaft. 10 Vers. Berlin, S. 87-92. 1896.

SCHUMACHER, S. v.: Uber Haemalbogen bei menschlichen Embryonen. Verh. Anat. Ges. Rostock. Erg. Heft. Anat. Anz. Bd. 29, S. 173–178. 1906.

SCHWEGEL: Die Entwicklungsgeschichte der Knochen des Stammes und der Extremitäten. Sitz. Ber. Akad. d. Wiss. Wien. Bd. 30. 1858.

SPANJE, N. P. VAN: Een angeboren defect van het sternum. Weekblad van het Nederl. Tydschr. voor Geneesk., Nr. 6. 1904.

STADERINI, R.: Richerche statistiche sulla frequenza della varietà numeriche delle vertebre nell' uomo e considerazioni sulla loro genesi. Monit. Zool. Ital. Vol. 5. 1894.

STEINBACH: Die Zahl der Caudalwirbel beim Menschen. Diss. Berlin 1889.

STIEDA, L.: Uber Halsrippen. Virchow's Arch. Bd. 36. 1866.

STRAUCH, M.: Anatomische Untersuchungen des Brustbeins des Menschen. Diss. Dorpat 1881.

STRUTHERS, J.: On Variations of the Vertebræ and Ribs in Man. Journ. of Anat. and Physiol. Vol. 9, p. 17-96. 1875.

SWJETSCHNIKOW: Uber die Assimilation des Atlas und die Manifestation des Occipital-wirbels beim Menschen. Arch. f. Anat. u. Physiol. Anat. Abtl. S. 155–194. 1906.

SZAWLOWSKI: Uber einige seltene Variationen an der Wirbelsäule beim Menschen. Anat. Anz. Bd. 20, S. 305–320. 1901.

TENCHINI: Di una nuova maniera di compenso nelle anomalie numeriche vertebrali dell' uomo. Archivio per l'Anthropologia. Vol. 24. Firenze 1894.

Thaler, H. A.: Atypische Verhältnisse in der Steissgegend menschlicher Feten und eines Neugeborenen. Deutsche Zeitschr. f. Chir. Bd. 79, S. 112. 1906 und Jahresbericht u. Arb. d. zweiten chir. Klinik Wein, 1906, p. 140–153.

Topinard, P.: Anomalies de nombre de la colonne vertébrale chez l'homme. Revue d'Anthropologie. T. 6, p. 577. 1877.

Tourneux, F. et **Herrmann**, G.: Sur la persistance de vestiges médullaires coccygiennes pendant toute la période fœtale chez l'homme. Journ. de l'Anat. et de la Physiol. Année 23, p. 498. 1887.

Tourneux, F. et **Martin**, E.: Contribution à l'histoire du spina bifida. Journ. de l'Anat. et de la Physiol. Année 17. 1881.

Tredgold, A. F.: Variations of Ribs in Primates with Especial Reference to the Number of Sternal Ribs in Man. Journ. of Anat. and Physiol. Vol. 31. 1897.

Turner, W.: On the So-called Two-headed Ribs in Whales and in Man. Journ. of Anat. and Physiol. Vol. 5. 1871.

Unger und **Brugsch**: Zur Kenntnis der Fovea und Fistula sacro-coccygea s. caudalis etc. Arch. f. mikr. Anat. Bd. 61, S. 151–219. 1903.

Valenti, G.: Sopra il significato dell' apofisi laterale delle vertebre lombari e delle massi laterali del sacro. Rend. Accad. Sc. Istit. Bologna, Anno Accad. 1902–1903; Bull. Sc. Med. Anno 74. Mem. Accad. Sc. Istit. Bologna, Anno Accad. 1902–1903; Bull. Sc. Med. Anno 74. Mem. Accad. Sc. Istit. Vol. 10. Bologna, 1903.

Sopra un caso di costa raddoppiata osservato nell' uomo. Mem. Accad. Sc. Ist. Ser. 5. Vol. 9. Bologna 1903.

Sopra il significato delle Apofisi laterali delle vertebre cervicali nell' uomo. Ricerche embryologiche. Accad. Sc. Istit. Bologna 1906.

Voltz, W.: Uber kongenitale volkommene Synostose der Wirbelsäule in Verbindung mit Wachstumsanomalien der Extremitätenknochen. Mitt. a. d. Grenzgeb. d. Med. u. Chir. Bd. 16, S. 61–75. 1906.

Walter, F.: Uber Halsrippen. Med. Diss. Halle 1906.

Weiss, A.: Die Entwicklung der Wirbelsäule der weissen Ratte, besonders der vordersten Halswirbel. Zeitschr. f. wiss. Zool. Bd. 66, S. 492. 1901.

Wirth, A.: Zur Anatomie und Entwicklungsgeschichte des Atlas und Epistropheus. Leipzig 1884.

D. SKELETON OF THE LIMBS.

One of the most studied subjects in morphology has been the development of the vertebrate limbs. Since, fortunately, critical summaries of its literature have recently been given by several noted investigators, among whom may be mentioned Wiedersheim (1892), Mollier (1893, 1895, 1897), Gegenbaur (1898), Rabl (1901), Fürbringer (1902), Ruge(1902), and Braus (1904), no attempt will be made here to review this work except so far as it deals directly with the development of the human limb.

During the third week of embryonic life the limb buds become filled with a vascular mesenchyme. The source of this tissue is uncertain. In part it may come from the primitive body-segments, but it seems probable that in the main it comes from the parietal layer of the unsegmented mesoblast. Toward the end of the fourth week a slight condensation of the mesenchyme can be seen at the centre of the arm bud, and early in the fifth week a similar condensation may be noted in the leg bud. This condensation represents the first rudiment of the skeleton of the limb. The tissue composing it may therefore be called "scleroblastema." From the scleroblastema there is developed a membranous skeleton. In this a cartilaginous skeleton is differentiated, and this in turn is replaced by the permanent osseous skeleton. We may thus distinguish three overlapping periods, a blastemal, a chondrogenous, and an osseogenous. We shall first consider in some detail the development of the skeleton of the inferior extremity and then more briefly that of the superior extremity.

INFERIOR EXTREMITY.

Blastemal Period.

At the time when the condensation takes place in the leg bud the latter has the general form shown in outline in Fig. 274. The bud projects considerably from the body, but shows no definite resemblance to the limb to which it is to give rise. The condensed tissue, scleroblastema, is not sharply outlined. It represents the region of the acetabulum and the proximal end of the femur.

Once begun, skeleton differentiation proceeds rapidly. In an embryo 11 mm. long (Fig. 275) it may be seen that from the original centre of skeletal formation the condensation of tissue has extended both distally and proximally, but much more freely in the distal direction. Distally the scleroblastema shows femur, tibia, fibula, and a foot-plate; proximally, an iliac, a pubic, and an ischial process. A series of sections through the skeletal mass shows that in the femur, tibia, and fibula chondrification has begun. At centres in the blastema of the ilium, ischium, and pubis a still earlier stage of chondrification has made its appearance. The leg of this embryo, therefore, represents a stage of transition from the blastemal to the chondrogenous stage of development.

Chondrogenous Period.

The further development of the skeleton of the limb during the second and third months of intra-uterine life may be followed in Figs. 276, 277, and 278. For the sake of convenience the development of the several parts of the skeleton will be taken up as follows: (*a*) the os coxæ; (*b*) femur, hip-joint, tibia and fibula, and knee-joint; (*c*) ankle and foot.

(*a*) The Os Coxæ.—The pelvic scleroblastema of embryos of the stage illustrated in Fig. 275 undergoes a rapid development. Its iliac portion extends in a dorsal direction toward the vertebræ which are to give it support. The costal processes of the latter at the same time become fused into a dense mass of tissue which enters into close association with the iliac blastema (Fig. 276),

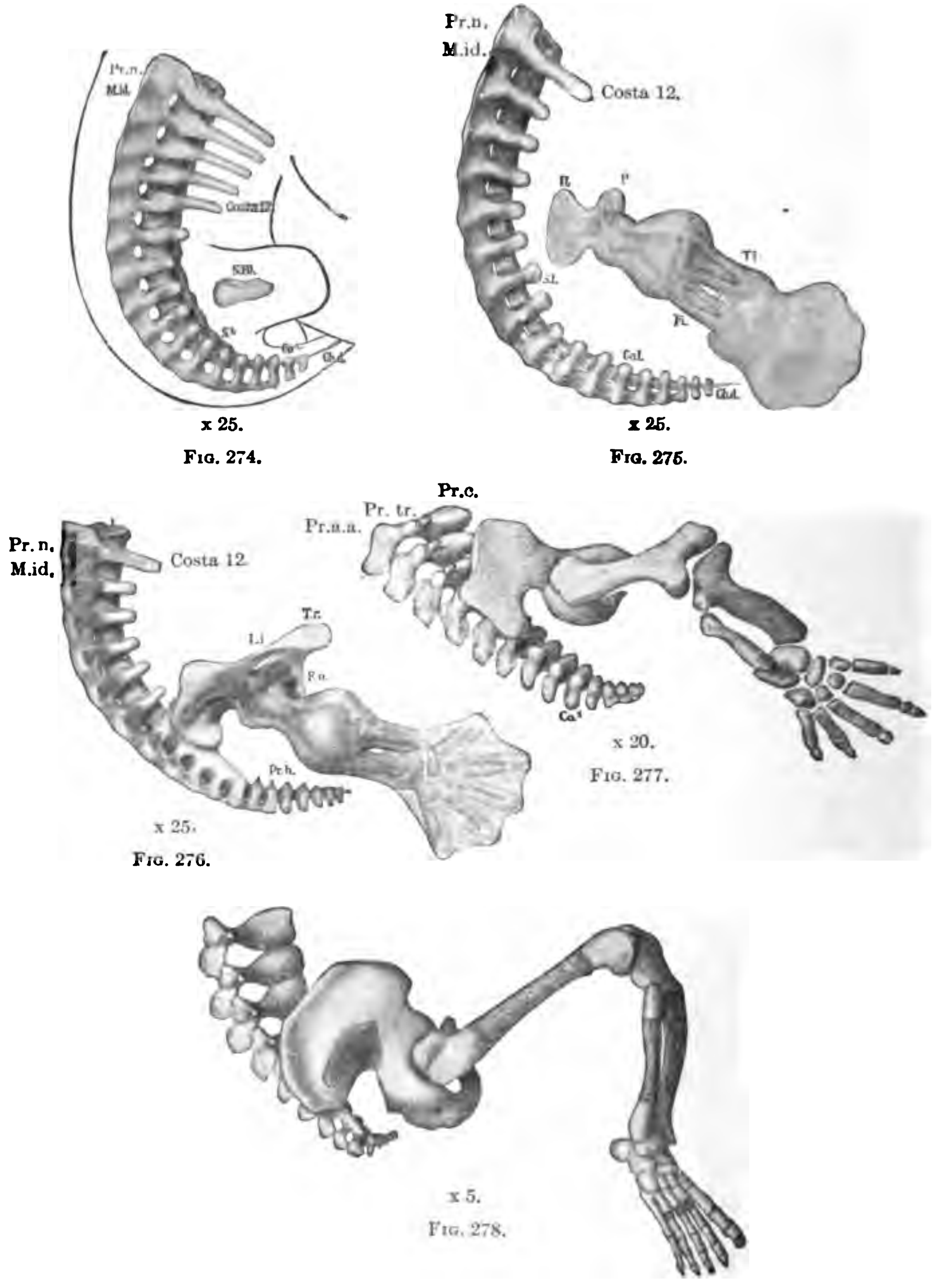

Figs. 274–278.—(After Bardeen, Amer. Journ. of Anat., 1905.) Lateral view of models to illustrate the development of the distal part of the spinal column and of the inferior extremity of embryos 9–50 mm. long. In Figs. 274, 275, and 276 the scleroblastema is shown, and in this in Figs. 275 and 276 the centres of chondrification. In Figs. 277 and 278 the cartilaginous skeleton is shown, and in this in Fig. 278 centres of ossification.

Fig. 274. Length of embryo, 9 mm. Fig. 275. Length of embryo, 11 mm. Fig. 276. Length of embryo, 14 mm. Fig. 277. Length of embryo, 20 mm. Fig. 278. Length of fetus, 50 mm. *Ch.d.*, chorda dorsalis; *Co*¹, first coccygeal vertebra; *Costa 12*, twelfth rib; *Fi*, fibula; *F.o.*, foramen obturatum; *Il.*, ilium; *L.i.*, ligamentum inguinale; *M.id.*, membrana interdorsalis; *P.*, pubis; *Pr.a.a.*, processus articularis anterior; *Pr.c.*, processus costalis; *Pr.h.*, processus hæmalis; *Pr.n.*, processus neuralis; *Pr.tr.*, processus transversus; *Ti*, tibia.

although for some time separated from this by a narrow band of tissue staining less densely than the blastema. Cranialwards the iliac blastema extends toward the abdominal musculature, to which it finally gives attachment.

While the blastemal ilium is thus becoming differentiated the pubic and ischial processes of the pelvic blastema extend rapidly forward. Ventral to the obturator nerve they become united by condensed tissue, which completes the boundary of the obturator foramen. Betwen the crest of the ilium and the ventral extremity of the pubis dense tissue is formed to give attachment to the oblique abdominal musculature. This represents the embryonic inguinal ligament and completes a femoral canal (Fig. 276).

While the blastemal pelvis is being completed the three centres of chondrification, barely visible in the 11 mm. embryo, give rise respectively to iliac, pubic, and ischial cartilages in which the adult form becomes gradually more distinct. (Compare Figs. 276, 277, and 278.) In embryos between 15 and 20 mm. long each of the three cartilages gives rise to a plate-like process over the head of the femur. These processes fuse with one another and give rise to a shallow acetabulum (Fig. 277), which during the third month gradually becomes deeper (Fig. 278). The iliac and ischial cartilages furnish a greater part of the floor of the acetabulum than the pubic cartilage and unite with one another before being joined by the pubic cartilage.

Toward the end of the second month and the beginning of the third month of development the symphysis pubis is formed. This is at first composed of dense blastemal tissue. In this tissue first hyaline and then fibrocartilage become differentiated. At the centre of the joint a slight fissure may appear in adult life (Farabeuf, 1895).

(*b*) FEMUR AND HIP-JOINT, TIBIA, FIBULA, AND KNEE-JOINT.—The rapid development of the blastemal skeleton of the lower limb has been briefly described above. Soon after the anlage of the femur makes its appearance condensation of tissue marks out the anlages of the tibia and fibula and the skeleton of the foot. This last seems to be at first a somewhat irregular continuous sheet of tissue. It is not clear whether or not the anlages of the tibia and fibula also begin as a continuous sheet which becomes divided, by ingrowth of blood-vessels, into tibial and fibular portions. The incomplete development of the interosseous fissure in an 11 mm. embryo suggests this (Fig. 275). The blastemal anlages of the tibia and fibula are here very incompletely separated.

Within the blastema of the femur, tibia, and fibula chondrification begins as soon as the outlines of the blastemal skeleton are fairly complete (Fig. 275). The embryonic cartilage appears slightly knee-wards from the centre of the shaft of each bone and then extends toward the ends. The cartilage of the femur consists of a bar largest at the knee, whence it tapers off toward the hip. The cartilages of the lower leg lie nearly in a common plane. That of the tibia is larger than that of the fibula and toward the knee it broadens out considerably. At this stage the joints consist of a solid mass of mesenchyme (Figs. 279 and 280). The tissue uniting the femur and tibia has temporarily somewhat the appearance of precartilage (Fig. 283). From this period onwards the development of the individual bones and joints is rapid.

Fig. 279.

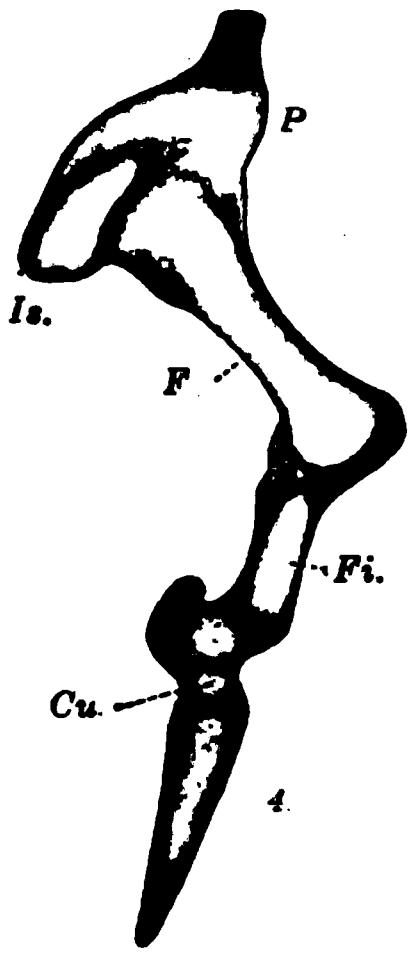

Fig. 280.

Fig. 281.

Fig. 282.

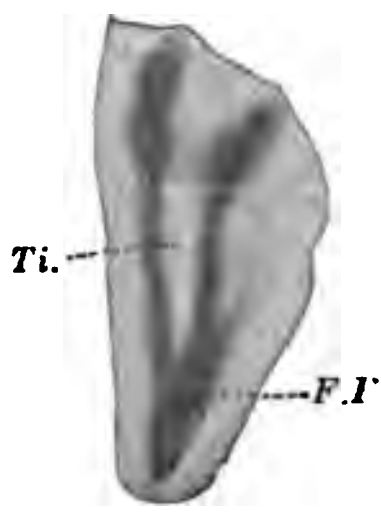

Fig. 283

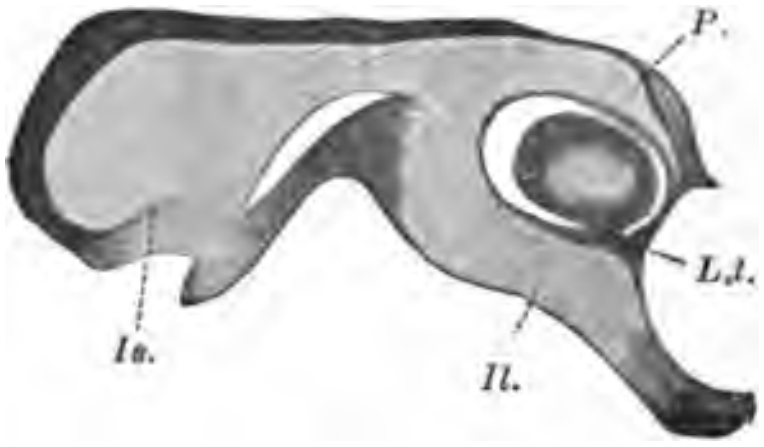

Fig. 284.

Figs. 279–284.—(After Bardeen, Amer. Journ. of Anat., 1905.)
Fig. 279. Section through the leg and foot of an embryo 18 mm. long. The section does not pass through the cartilage of the first metatarsal. Fig. 280. Section through the pubis, ischium, femur, fibula, calcaneus, cuboid, and fourth metatarsal of an embryo 16 mm. long. Fig. 281. Section through the knee-joint of an embryo 20 mm. long. Fig. 282. Section through the knee-joint of an embryo 33 mm. long. Fig. 283. Section through the knee-joint, tibia, and foot-plate of an embryo 14 mm. long. Fig. 284. Section through the hip-joint of an embryo 30 mm. long. *Cu.*, cuboid ; *F.*, femur ; *Fi.*, fibula ; *F.Pl.*, foot-plate ; *Il.*, ilium ; *Is.*, ischium ; *P.*, pubis ; *L.t.*, lig. teres ; 4, metatarsale quartum.

The *cartilaginous femur* expands at the expense of the surrounding blastemal perichondrium and at the same time acquires adult characteristics (Figs. 276, 277, and 278).

The *hip-joint* is at first completely filled with a dense blastemal tissue (Fig. 280). While the embryo is growing from 20 to 30 mm. in length, cavity formation begins in the tissue lying between the cartilaginous floor of the acetabulum and the head of the femur. The first stage in the process is marked by a condensation of the capsular tissue immediately bordering upon the joint and of the perichondral tissue which at this stage covers the cartilages on their articular surfaces as well as elsewhere. In the region of the ligamentum teres a fibrous band is likewise differentiated from the blastema of the joint. The rest of the tissue becomes looser in texture and ultimately is absorbed (Fig. 284). Henke and Reyher (1874) gave a good account of the development of the hip-joint. Moser (1893) has described that of the ligamentum teres. Schulin (1879) has given a good account of the later development of the joint cavity in its relations to the head and neck of the femur (see Figs. 286–288). It is to be noted that in the fetus 25 cm. long (Fig. 286) the joint cavity extends about the neck of the femur in a pocket lined on one side by perichondrium, on the other by the capsule of the joint, and that later the perichondral lining becomes periosteum (Fig. 288).

Fig. 285.

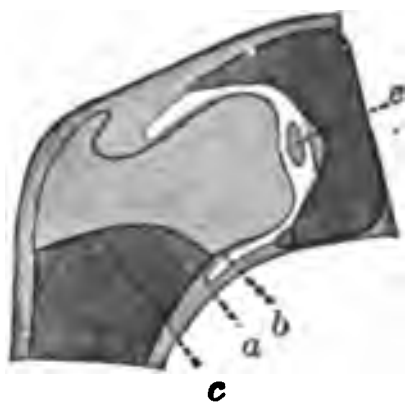

Fig. 286.

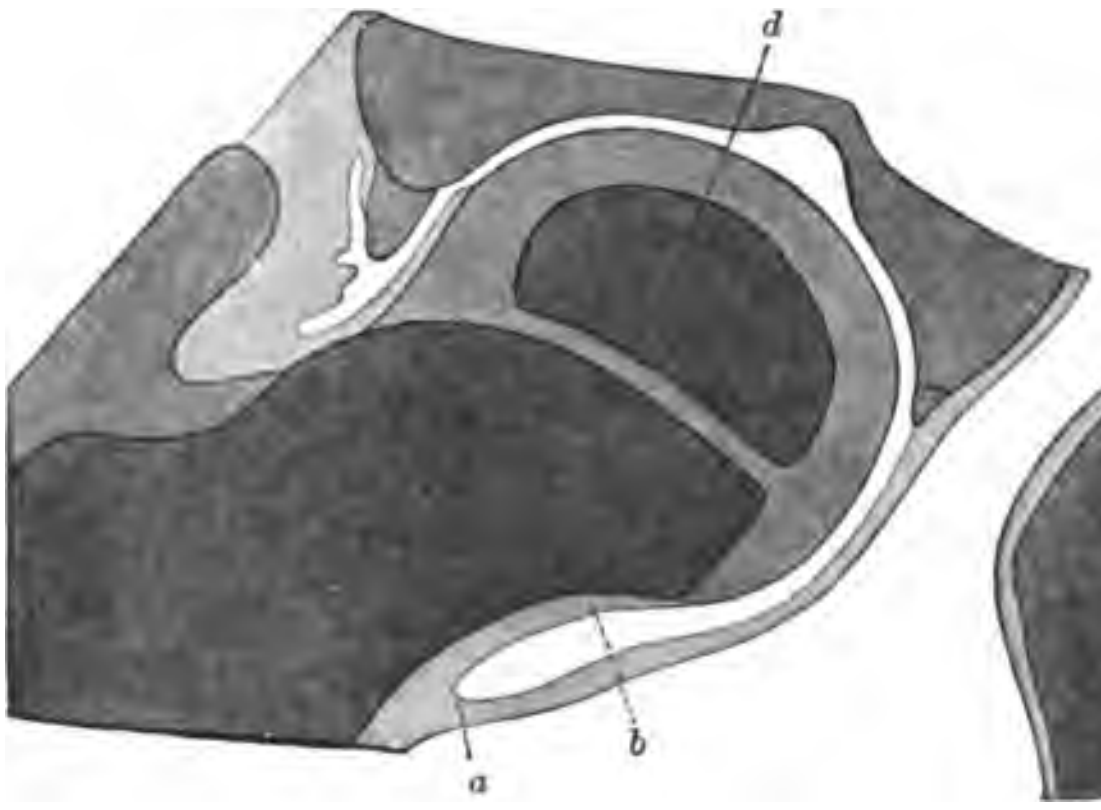

Fig. 287.

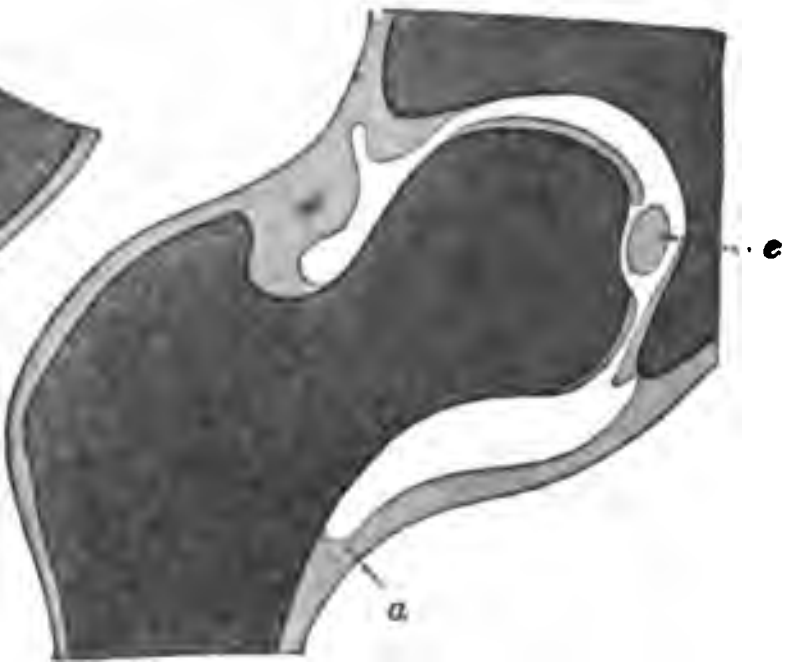

Fig. 288.

Figs. 285 to 288.—(After Schulin, Archiv f. Anatomie, 1879.)

Fig. 285. Median section through the knee-joint of a fetus 13 cm. long. *a*, patella; *b*, connective tissue over patella; *c*, lig. mucosum; *d*, lig. cruciatum post.; *e*, insertion of joint capsule on femur. Figs. 286-288. Hip-joint of a male fetus 25 cm. long, of a female child six years old, and of a male adult. *a*, region of insertion of joint capsule; *b*, intracapsular connective-tissue surface; *c*, limit of endochondral ossification; *d*, epiphyseal osseous nucleus; *e*, ligamentum teres.

The *tibia* and *fibula* at first lie nearly in the same plane (Fig. 275). As the head of the tibia enlarges toward the knee-joint it comes to lie ventral to the proximal extremity of the fibula. This may be seen in Figs. 276 and 277.

The development of the *knee-joint* in man has been studied by a number of competent observers. Bernays (1878) gave a good review of the previous work of von Baer, Bruch, Henke, and Reyher, and an accurate description of the processes which take place. Of the more recent articles those of Schulin (1879), Kazzander (1894), and Lucien (1904) deserve mention.

Until the embryo reaches a length of about 17 mm. the knee-joint is marked by a dense mass of tissue (Fig. 279). The medullary tissue at the knee, like that at the hip and other joints, is less dense than the surrounding cortical substance, so that when the cartilages of the femur, tibia, and fibula are first differentiated they seem to be connected by a tissue which, in some respects, resembles the cartilage of which they are composed (Fig. 283); but as the cartilages become more definite the apparent continuity disappears. As the musculature becomes differentiated a dense tendon for the quadriceps is formed in front of the knee-joint. At this period the joint is flexed at nearly a right angle.

In embryos of about 20 mm. the tissue immediately surrounding the cartilages becomes greatly condensed into a definite perichondrium. The peripheral blastemal tissue at the joint becomes transformed into a capsular ligament, strengthened in front by the tendon of the quadriceps. Within the joint most of the tissue begins to show signs of becoming less dense, but the menisci and the crucial ligaments, like the ligaments of the capsule, are differentiated directly from the blastema (Figs. 281 and 282). In the differentiation of the articular blastema the menisci first become distinct, then the capsule, then the crucial ligaments, the patella, and the lig. mucosum.

A knee-joint cavity first appears, in embryos about 30 mm. long, between the patella and the femur. According to Lucien, two other cavities somewhat later appear between the condyles of the femur and the menisci. These cavities secondarily communicate with the retropatellar cavity and with cavities formed between the menisci and the tibia. The cavity of the knee-joint is primitively partly divided into two parts by a median septum (lig. mucosum), which becomes greatly reduced in fetuses 10–12 cm. long (Fig. 285, C) and in the adult is replaced by a fat pad.

The shafts of the *tibia* and *fibula* are incompletely separated in the blastemal stage. The cartilages which arise in the scleroblastema are, on the other hand, separated by a distinct interval (Fig. 279). At first short and thick, the shafts become gradually more slender in proportion to their length. The fibula, at all times smaller, becomes increasingly more slender in comparison with the tibia. In fetuses 50 mm. long (Fig. 278) both bones, and especially the fibula, are still relatively thick compared with the adult bones.

During a period of rapid development, in embryos of 15 to 20 mm., the tibia and fibula, like the femur, may extend so rapidly in length as to become temporarily distorted by resistance at the ends. This is often especially marked in hardened specimens. Holl (1891), Schomburg (1900), and others have called attention to this distortion.

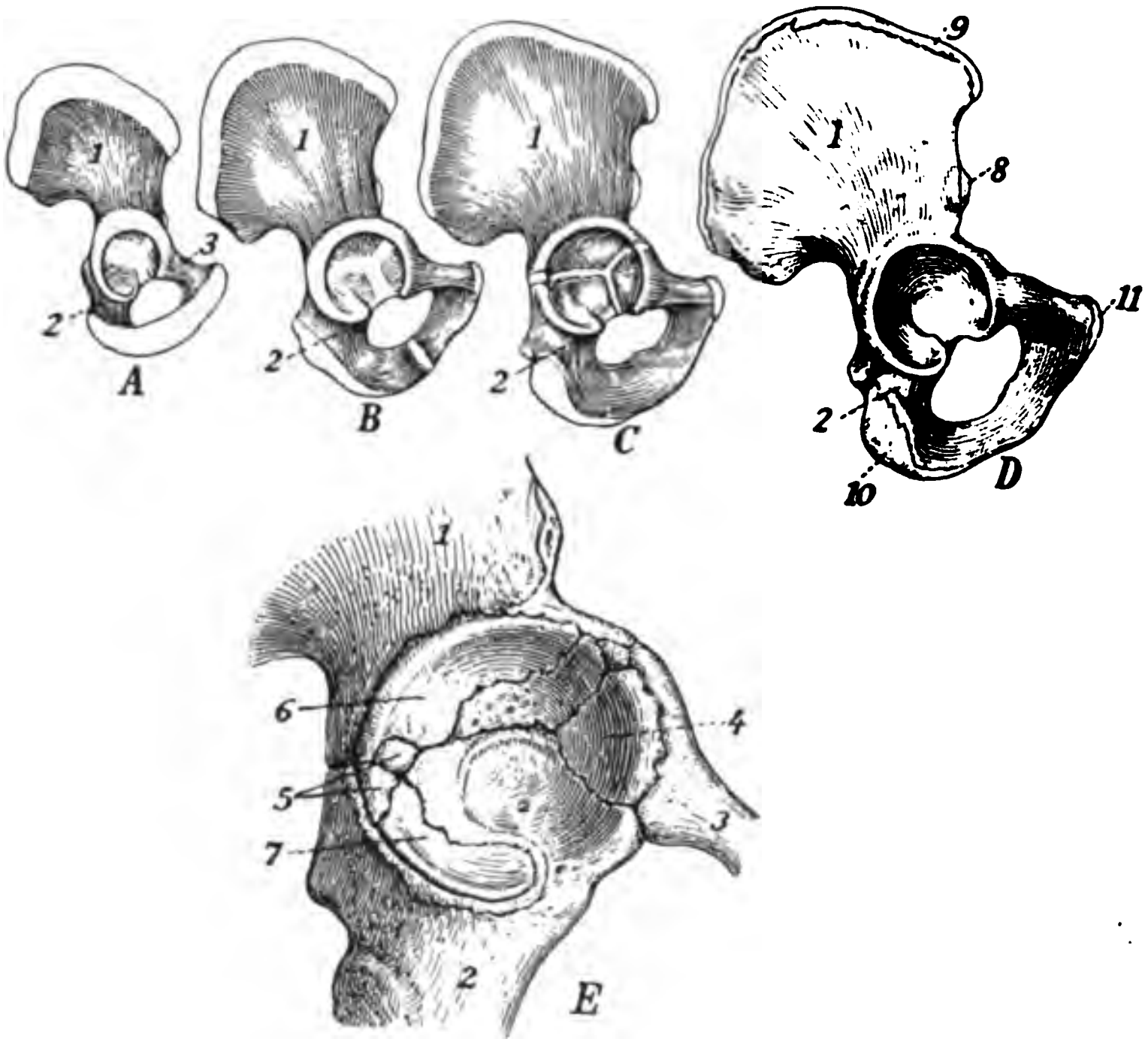

FIG. 289.—(After R. Quain, Quain's Anatomy, 10th ed., vol. ii, Pt. I, Figs. 157 and 158.) Ossification of the os coxæ.

A. Bone at birth. B. Child under six years of age. C. Child two to three years older than B. D. Person of about twenty years. E. Acetabular region of hip-bone at fourteen years of age. 1, ilium; 2, ischium; 3, pubis; 4, os acetabuli; 5, bony nodules between ilium and ischium; 6 and 7, epiphyseal laminæ on ilium and ischium; 8, 9, 10, 11, epiphyses of anterior inferior iliac spine, iliac crest ischial tuberosity, and symphysis pubis.

(*c*) ANKLE AND FOOT.—Of the papers dealing with the early development of the skeleton of the human foot the more important are those of Henke and Reyher (1874), Leboucq (1882), v. Bardeleben (1883, 1885), Lazarus (1896), and Schomburg (1900).

During the fifth week of embryonic development the free extremity of the limb bud becomes flattened and differentiated into a foot-plate (Fig. 275). Toward the end of the fifth week the anlages of the individual bones of the ankle and foot begin to become marked by specific condensation of the blastemal tissue. Within these anlages precartilage soon appears. The digital rays are marked at first by condensed bars of tissue, in which segmentation into metatarsals and phalanges appears during the period of chondrification (Fig. 276). The metatarsal cartilages become differentiated before the tarsal cartilages. The phalangeal cartilages appear relatively late.

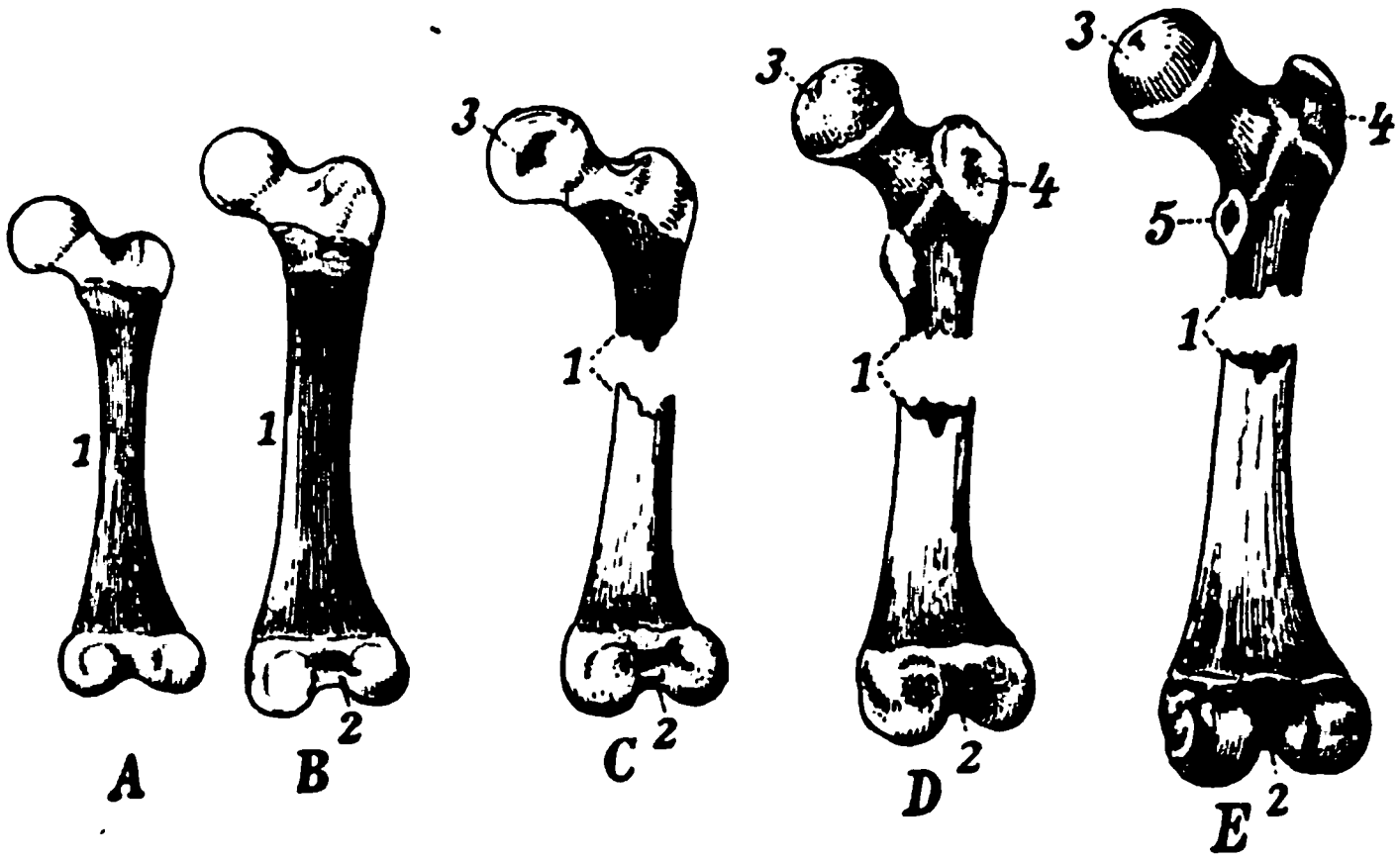

FIG. 290.—(After R. Quain, Quain's Anatomy, 10th ed., vol. ii, Pt. I, Fig. 159.) Ossification of the femur. A. Before the eighth month. B. At birth. C. About a year old. D. At about the fifth year. E. Near the age of puberty. 1, diaphysis; 2, distal epiphysis; 3, head; 4, great trochanter; 5, small trochanter.

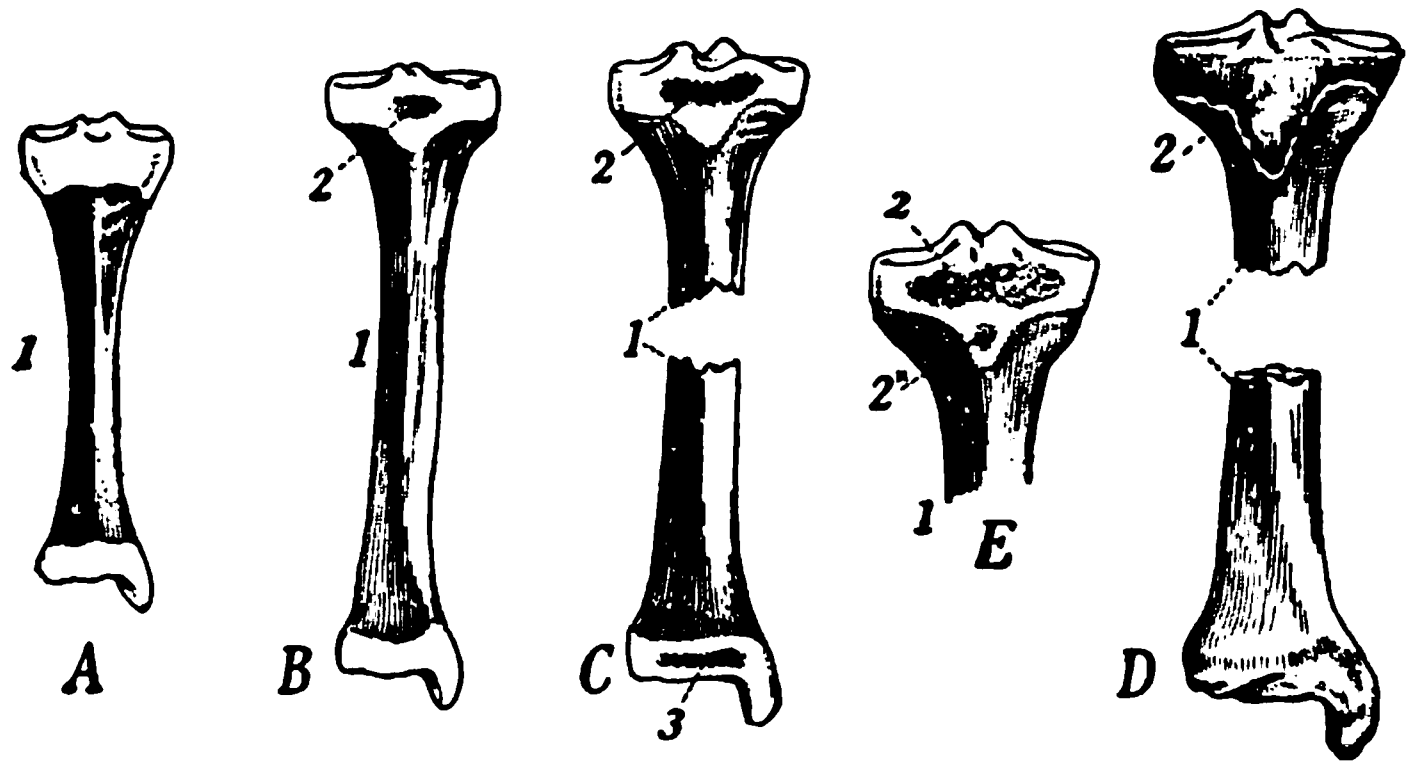

FIG. 291.—(After R. Quain, Quain's Anatomy, 10th ed., vol. ii, Pt. I, Fig. 160.) Ossification of the tibia. A. Some weeks before birth. B. At birth. C. At the third year. D. Between the eighteenth and twentieth years. E. Example of separate centre for tuberosity. 1, diaphysis; 2, proximal epiphysis; 2*, epiphysis of tuberosity; 3, distal epiphysis.

The earliest appearance of the tarsal cartilages is found in an embryo about 14 mm. long (Fig. 276). Toward the end of the second month these cartilages become much more distinct (Fig. 277). By the middle of the third month the cartilages of the foot have a form distinctly corresponding to the adult. The similarity is still better marked at the end of the third month (Fig. 278).

The joint cavities begin to develop while the embryo is growing from 25 to 30 mm. in length. As in other cases, so here the blastemal tissue in which the cartilages are developed becomes condensed at their articulating ends and about the joint, while in the region of the joint the tissue becomes less dense and finally disappears, leaving a joint cavity. In embryos of about 30 mm. the joint cavities of the foot are filled with a loose fibrous tissue; in fetuses of 50 mm. definite cavities are to be made out.

During the progress of form differentiation above described, the shape of the foot is markedly altered. At the beginning of the development of the foot the tarsal and metatarsal bones lie nearly, though not quite, in the same plane as the bones of the leg. They are so arranged, however, that the foot is convex on its dorsal surface and concave on the plantar, and the projections of the calcaneus and talus serve to deepen the plantar fossa. The metacarpals spread widely apart. As differentiation proceeds, the metatarsals come to lie more nearly parallel to one another, and the tarsal elements become compacted in such a way as to give rise to the tarsal arch. The foot at the same time is dorsally flexed at the ankle and slightly everted. The toes are flexed. In the further development of the skeleton of the foot the various constituent structures are elaborated, and the foot gradually becomes more flexed dorsally and turned toward the fibular side.

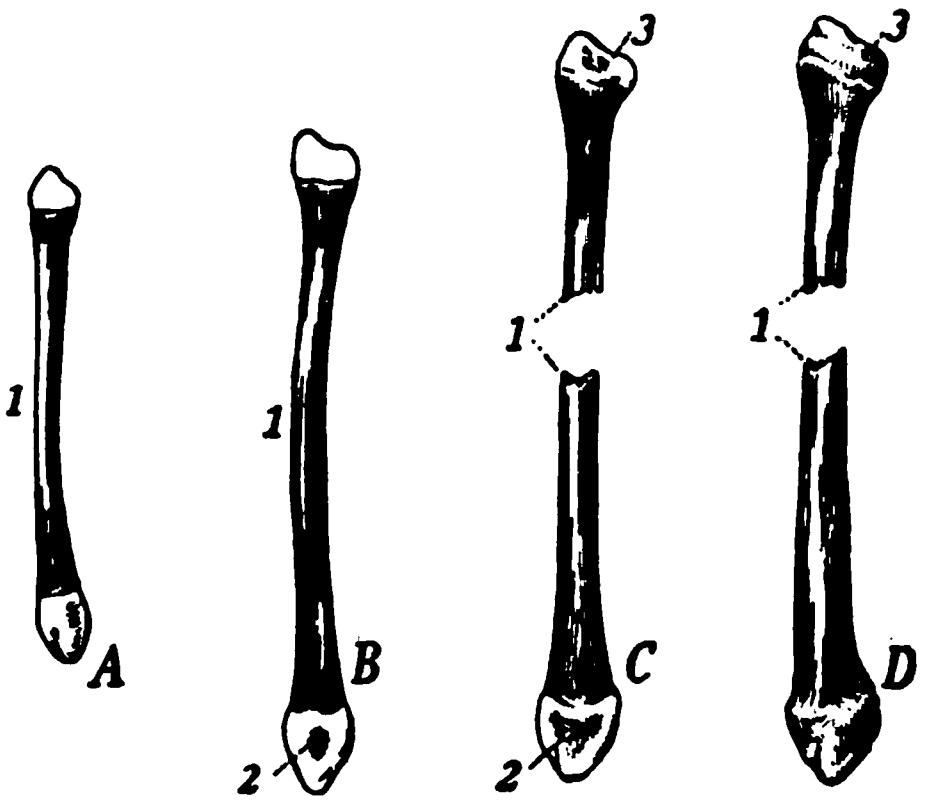

FIG. 292.—(After R. Quain, Quain's Anatomy, 10th ed., vol. ii, Pt. I, Fig. 161.) Ossification of the fibula. A. At birth. B. At about two years. C. At about four years. D. At about twenty years. 1, diaphysis; 2, distal epiphysis; 3 proximal epiphysis.

PERIOD OF OSSIFICATION.

The hip-bone is ossified from three primary centres, one for each of its constituent parts, the ilium, ischium, and pubis, and from several epiphyses. There is one primary centre of ossification for each of the other bones of the inferior extremity, and in addition most of the bones have one or more epiphyses. In the tarsus the calcaneus alone regularly has an epiphysis. The patella has no epiphysis. With the exception of those of the tarsal bones and of the various sesamoid bones the primary centres of ossification appear relatively early in intra-uterine life. At birth there are usually centres of ossification present in the calcaneus, talus, and cuboid, but not in the other tarsal bones. Ossification in these latter tarsal bones and in the sesamoid bones and the various epiphyses appears after birth. In the talus, according to Sewell (1906), dark-staining regions in the hyaline cartilage of which it is composed in the sixth fetal month indicate structural features characteristic of the adult bone. The following tables and the accompanying figures illustrate the process of ossification in the inferior extremity. Authors differ in the data which they give concerning the time of ossification of the various bones. When not otherwise indicated the tenth edition of Quain's Anatomy is followed in the tables.

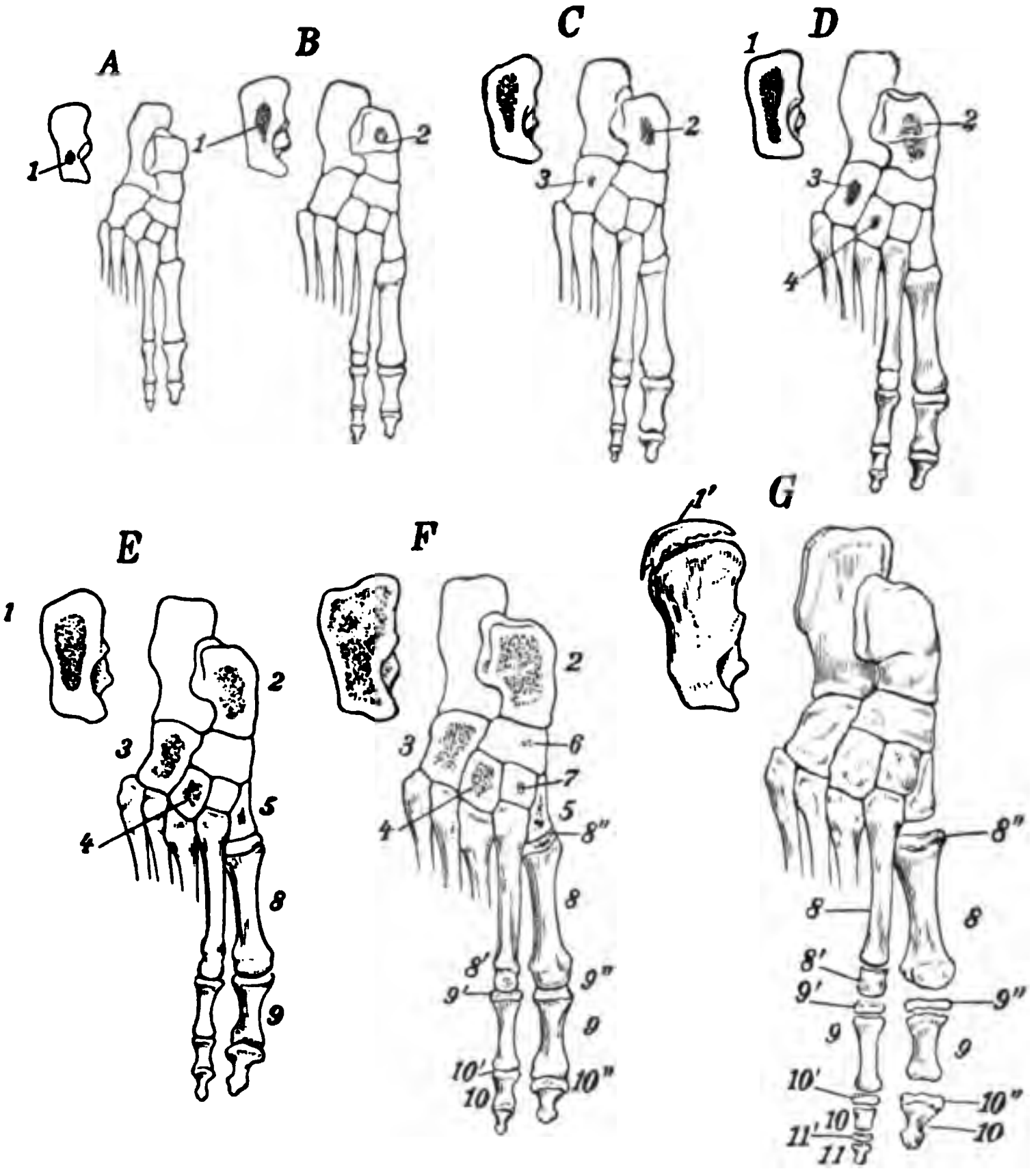

FIG. 293.—(After R. Quain, Quain's Anatomy, 10th ed., vol. ii, Pt. I, Fig. 162.) Ossification of the bones of the foot. A. Right foot of a fetus of six months. The shafts of the metatarsal bones and digital phalanges are ossified. The tarsus is cartilaginous except for the centre of ossification in the calcaneus. B. Fetus of 7–8 months. Nucleus in talus. C. At birth. Nucleus in cuboid. D. End of first year. Nucleus in third cuneiform. E. In third year. Nucleus in first cuneiform. F. Fourth year. Ossification in middle cuneiform and navicular bones and in epiphyses of metatarsals and phalanges. G. About the age of puberty. Ossification nearly complete in tarsal bones. Epiphysis on tuberosity of calcaneus. Epiphyses of metatarsals and phalanges not yet united to shafts. 1, nucleus of the calcaneus; 1', in G, the epiphysis of the calcaneus; 2, nucleus of the talus; 3, of the cuboid; 4, of the third cuneiform; 5, of the first cuneiform; 6, of the navicular; 7, of the second cuneiform; 8, metatarsal bones; 8', distal epiphysis of the second metatarsal bone; 8" proximal epiphysis of the first metatarsal bone; 9, first phalanx of the second toe; 9', proximal epiphysis of this phalanx; 9", that of the first phalanx of the great toe; 10, second phalanx; 10', the epiphysis of this phalanx; 10", epiphysis of the terminal phalanx of the great toe; 11, terminal phalanx; 11', its epiphysis.

TABLE OF OSSIFICATION OF THE BONES OF THE INFERIOR EXTREMITY.

(Days and weeks refer to the prenatal, years to the postnatal period.)

Bone.	Centres.	Time of appearance of centre.	Time of fusion: general remarks.
Os coxæ	Os ilium	56th day (Mall)	The rami of the ischium and the pubis are united by bone in the 7th or 8th year (Quain) (12–14 year, Sappey). In the acetabulum the three hip bones are separated by a Y-shaped cartilage until after puberty. In this cartilage between the ilium and pubis the "os acetabuli" appears between the ninth and twelfth years. This bone, variable in size, forms a greater or less part of the pubic portion of the articular cavity. Leche (1884), Krause (1885), and many others consider it primarily an independent bone. About puberty between the ilium and ischium and over the acetabular surfaces of these bones small irregular epiphyseal centres appear. The os acetabuli becomes united to the pubic bone about puberty and soon afterwards the acetabular portions of the ilium and ischium and the ischium and pubis begin to become united by bone. The acetabular portions of the pubis and ilium are united a little later. Osseous union takes place earlier on the pelvic than on the articular surface of the acetabulum. The union of the several primary centres and the epiphyses is usually completed about the twentieth year.
	Os ischii	105th day (Mall)	
	Os pubis	4th to 5th fetal month	
	Os acetabuli	9th to 12th year	
	Epiphyses: Those of the acetabulum	Soon after puberty	
	Crest of ilium	Soon after puberty	Fuses with main bone 20th to 25th year.
	Tuberosity of ischium	Soon after puberty	Fusion begins in the 17th year and is completed between the 20th and 24th years (Sappey).
	Ischial spine	Soon after puberty	18th to 20th year (Poirier).
	Ant. inf. spine of ilium	Soon after puberty	18th to 20th year (Poirier).
	Symphysis end of os pubis (1 or 2 centres)	18th to 20th year (Sappey)	After the 20th year.
Femur	Diaphysis	42d day (Mall)	
	Epiphyses:		
	Distal end	Shortly before birth.[16]	20th to 24th year.
	Head	1st year	18th to 19th year.
	Great trochanter	3d to 4th year. (Osseous granules soon after birth, Poirier)	18th year.
	Small trochanter	13th to 14th year	17th year (Quain).
		8th year (Sappey)	Proximal epiphysis 18th to 22d year (Poirier).
Patella		3d to 5th year	The osseous patella reaches its definitive form soon before puberty.
Tibia	Diaphysis	44th day (Mall).	
	Epiphyses:		
	Proximal end	About birth	19th to 24th year (Sappey).
	Distal end	2d year	16th to 19th year.
	Tubercle (occas.)	13th year	Fuses with epiphysis of the proximal end and then with this to the diaphysis.
Fibula	Diaphysis	55th day (Mall).	
	Epiphyses:		
	Distal end	2d year	20th to 22d year.
	Proximal end	3d to 5th year	22d to 24th year.
Calcaneus	Chief centre	6th fetal month	The chief nucleus is endochondral. A periosteal nucleus appears frequently in the 4–5 fetal month (Hasselwander).
	Epiphysis (distal end)	10th year (Quain)	15th–16th year (Quain).
		7th–8th year (Sappey)	16th–18th year (Poirier).
			♂ 17–21, average 20 years.
			♀ 13–17, average 16 years (Hasselwander)

---

[16] Poirier, Traite d'Anatomie, vol. 1, page 227, gives a summary of the literature on the time of the appearance of this epiphysis. The epiphysis has some medico-legal importance, since its presence or absence has been utilized to determine whether a child is born at term. Schwegel found it to appear between birth and the third year; Casper in the ninth fetal month. Hartmann found it lacking in 12 per cent. of cases at birth and in 7 per cent. of cases present as early as the eighth fetal month.

Bone.	Centres.	Time of appearance of centre.	Time of fusion: general remarks.
Talus		6th fetal month (Hasselwander).	In the 7th–8th year the posterior part of the talus, the os trigonum, is frequently ossified from a special centre (v. Bardeleben). It fuses about the 18th year.
Cuboid		About birth	
Cuneiform III.		1st year.	
Cuneiform I.		2d–3d year.	
Cuneiform II.		3d–4th year.	
Navicular		4th–5th year.	According to v. Bardeleben a second centre of ossification appears much later than the primary in the navicular, and finally about the time of puberty a medial epiphyseal centre arises.
Metatarsals	Diaphyses	8th–10th week	
	Epiphyses	3d–8th year.	The centre for the 2d metatarsal usually appears first, then come the 3rd, 4th, 1st and 5th. The epiphysis of the 1st metatarsal appears at the proximal end of the bone; the other epiphyses arise at the distal ends of the metatarsals. There may be a distal epiphysis in the first metatarsal also.[17] In some instances a proximal epiphysis is formed on the tuberosity of the fifth metatarsal (Gruber). The epiphyses unite with the shafts in the 17–21 year in males and in the 14–19 year in females. (Hasselwander).
Phalanges:			
Terminal row	Diaphyses	58th day (Mall).	
	Epiphyses (distal)	4th year	♂ 13–23, average 16–21 year. ♀ 13–17, average 14–17 year (Hasselwander).
Middle row	Diaphyses	4th–10th fetal month	
	Epiphyses	3d year	♂ 15–19 year. ♀ 13–16 year (Hasselwander).
Proximal row	Diaphyses	3d fetal month	
	Epiphyses	3d year	♂ 15–17 year. ♀ 14–15 year (Hasselwander). The centres for the shafts of the phalanges often appear double, one for the dorsal and one for the plantar surface. The centres for the medial phalanges in each row usually appear before the more laterally placed centres. The centre for the 5th terminal phalanx appears much later than the other centres in this row (Mall). According to Rambaud and Renault the epiphyses arise each from two centres which fuse together. In the terminal phalanx of the great toe the ossification centre of the epiphysis often appears as early as the second or even the first year. (Hasselwander).
Sesamoid bones of the great toe		♂ 14th year. ♀ 12th–13th year	Ossification may begin in the 8th year in females, in the 11th in males (Hasselwander).

---

[17] Mayet has described two centres of ossification for the proximal epiphysis of the first metatarsal, one of which represents the real metatarsal of the first digit.

INFANTILE CHARACTERISTICS OF THE SKELETON OF THE INFERIOR EXTREMITY. —In the infant the pelvis is small in proportion to the size of the body and contains a smaller proportion of the abdomino-pelvic viscera than in the adult. The cavity of the infantile pelvis is cone-shaped and diminishes in diameter from the entrance to the outlet (Fehling, 1876, Hennig, 1880). The blades of the ilium are relatively slightly developed. In the first half of fetal life the sacropelvic angle is similar to that of quadrupeds, but during the latter half and after birth the angle becomes greater, expanding from 55° to 90–110° in the adult (Le Damany).[13]

The acetabulum is relatively shallow in the new-born as compared with the adult. The shafts of the long bones are relatively shorter and thicker. The neck of the femur is but slightly developed at birth. The infantile foot has certain ape-like characteristics and is strongly flexed and inverted. The head of the talus is directed more medialwards than in the adult, the first metatarsal is relatively short and inclined medialwards by the oblique articular surface of the first cuneiform (Leboucq, 1882).

SUPERIOR EXTREMITY.

BLASTEMAL AND CHONDROGENOUS PERIODS.

In general the development of the superior extremity resembles that of the inferior extremity. The various stages of differentiation begin in the former a little earlier than in the latter. W. H. Lewis (1902) has described the earlier stages in the development of the arm. His description is closely followed here.

In an embryo at the end of the fourth week the scleroblastema of the limb bud is marked by a slight condensation of the tissue near the future head of the humerus. Early in the fifth week this condensation has extended to the distal part of the limb bud and the anlages of the scapula, humerus, radius, and ulna are distinguishable (see Fig. 294). The skeleton of the wrist and hand is marked by a plate of condensed tissue. There are no distinct centres of chondrification at this stage.

In an 11 mm. embryo marked alterations have taken place in the skeleton of the superior extremity (Fig. 295). Centres of chondrification appear.

The scapula is composed of precartilage surrounded by a dense blastema. It lies opposite the lower four cervical and the first one or two thoracic vertebræ. From the superior border there springs a large curved acromion process. On the medial (costal) surface, at the junction of the humerus with the scapula; arises a large hooked coracoid process. A slight ridge on the medial surface marks the future anterior border. The perichondrium is well marked only on the medial surface.

The clavicle is an ill-defined mass of condensed tissue which extends from the acromion about a third of the distance to the

---

[13] For recent accounts of the development of the pelvis, see Merkel (1902) and Falk (1908). Fehling recognized sexual differences in the pelvis early in fetal life.

tip of the first rib. The coracoclavicular ligament is partially differentiated.

The humerus is short and thick. The shaft is composed of embryonic cartilage surrounded by a dense layer of perichondrium. Towards each end of the shaft the central tissue is precartilaginous in character. The surrounding perichondrium is continued directly into the dense tissue of the neighboring skeletal parts.

There is more flexion at the elbow than during the preceding stage. The forearm is midway between supination and pronation. The core of the shaft of each bone is composed of hyaline cartilage.

The hand-plate is composed of condensed mesenchyme. There are several centres of increased condensation which probably correspond to the carpal bones. The digits are marked by condensed tissue in which no segmentation into metacarpals and phalanges is visible.

In an embryo of 14 mm. the skeleton of the superior extremity is well advanced in development (Fig. 296). The form of the scapula is shown in this figure. It is composed mainly of cartilage, covered by a thick layer of perichondrium. It has migrated caudalwards so that less than one-half of it lies anterior to the level of the first rib. The clavicle is a rod composed of dense tissue. It extends from the acromion to the tip of the first rib, where it is continued into the sternal anlage. It contains a small core of a peculiar precartilaginous tissue. The acromioclavicular ligament is distinct.

The humerus is larger and more slender than at the preceding stage and has expanded at each end. It is composed chiefly of cartilage surrounded by a thick perichondrium which is continuous with that of the lateral angle of the scapula. There are no signs of a joint cavity at the shoulder.

The ulna and radius are likewise composed of cartilage surrounded by a thick perichondrium continuous at one end with that of the humerus and at the other with that of the wrist. There are no joint cavities at the elbow.

The carpus is composed of a dense tissue in which are embedded cartilages which represent the bones of the wrist with the exception of the lunar and the pisiform. These are still composed of condensed tissue.

The metacarpals are represented by five slender cartilages surrounded by a dense perichondrium. The first metacarpal is only about half the length of the others.

The phalanges of the first row, with the exception of that of the thumb, have cartilaginous cores. The basal phalanx of the thumb is composed of condensed tissue. At the tip of each digit is a mass of condensed tissue. There are no joint cavities present in the hand.

In an embryo 20 mm. long the cartilaginous anlages of various bones of the superior extremity are all well marked, except those of the distal row of the phalanges of the fingers. The clavicle extends from the acromion to the sternum. It is composed of a peculiar kind of precartilaginous tissue. The general shape of the other cartilages may be seen from Fig. 297. The spine of the scapula is not yet distinct. There are distinct coracoclavicular, costoclavicular, and interclavicular ligaments. There is no joint cavity at the shoulder, but a capsular and a coraco-humeral ligament may be distinguished. The humerus has well-marked tuberosities and condyles. The ulna and radius are larger and longer than at the preceding stage. The olecranon, coracoid, and styloid processes are composed of cartilage and condensed tissue. The perichondrium about the ulna and radius is quite thick. The capsular and annular ligaments are present, but there are no joint cavities.

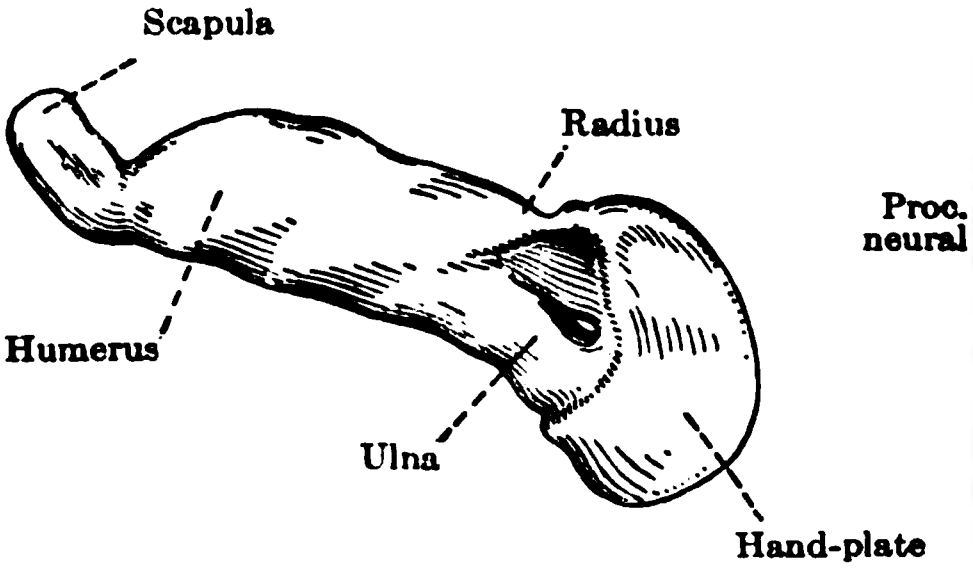

Fig. 294.

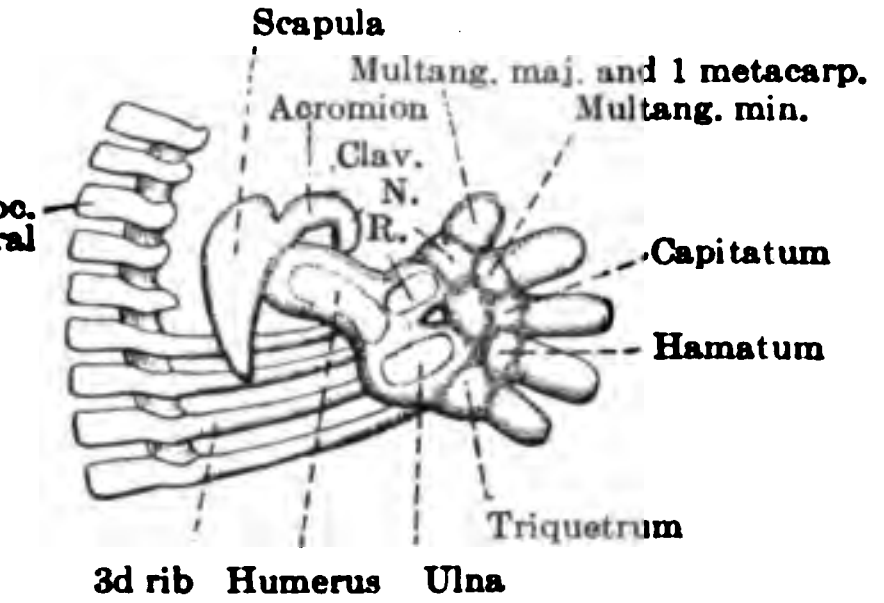

Fig. 295.

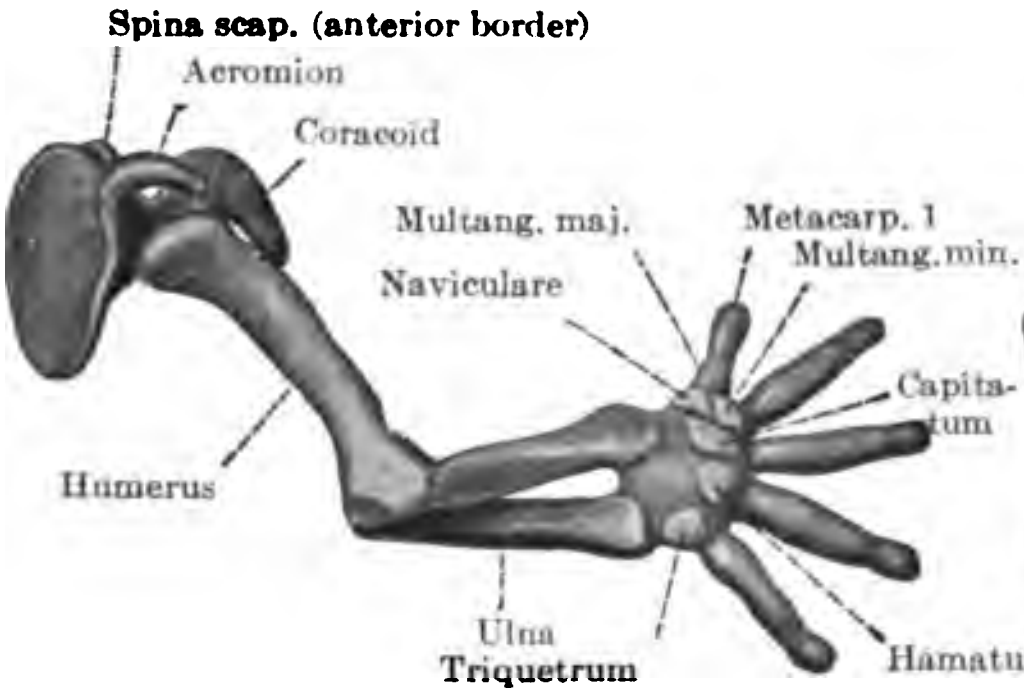

Fig. 296.

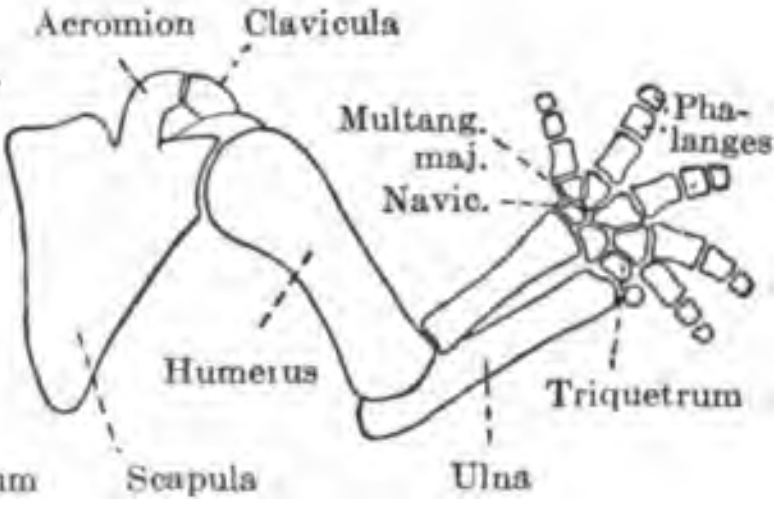

Fig. 297.

Fig. 294.—(Based on Figs. 6 and 7 by Lewis, Amer. Journ. of Anat., 1902.) Lateral view of the skeleton of the superior extremity in a 9 mm. embryo. Magn. 30 : 1. Fig. 295.—(After Lewis, 1902, Fig. 9.) Skeleton of the brachial region in an 11 mm. embryo. Magn. 8 : 1. Fig. 296.—(After Lewis, 1902, Fig. 12, mirror view.) Cartilaginous skeleton of a 16 mm. embryo. Magn. about 13 : 1. Fig. 297.—(After Lewis, 1902, Fig. 13.) Cartilaginous skeleton of the superior extremity of a 20 mm. embryo. Magn. about 8 : 1.

All the bones of the carpus have cartilaginous centres. There are no joint cavities in the hand.

During the third month of development the cartilages of the superior extremity assume more and more the form characteristic of the adult bones; in several ossification begins; the joint cavities appear at this time.

The early development of the bones of the forearm and hand, and especially those of the wrist, has engaged the attention of several investigators. The following details are based upon the recent paper of Graefenberg (1906).

FOREARM.

The form and relations of the cartilaginous radius and ulna in the fifth, sixth, and the seventh weeks of embryonic life are shown in Figs. 298, 299, 300. The two cartilages are at first some distance from one another. The proc. styloideus of the ulna begins to develop during the latter part of the second month. It extends at first to the dorsal side of the triquetrum and becomes relatively large. Later the process becomes smaller, and is carried proximally and volarwards.

The discus articularis arises from a mass of tissue which lies between the radius and the styloid process of the ulna. This mass of tissue gives rise to a special centre of chondrification, which by some is supposed to represent the os intermedium antebrachii of the lower vertebrates.

THE CARPUS.

Os Centrale.—Most of those who have studied the development of the human carpus have described a cartilage which is homologous with the os centrale of the carpus of lower vertebrates. The position of this element is shown in Figs. 298, 299, and 300. It later disappears. In the process of retrograde metamorphosis it may become divided into several parts. According to Graefenberg it does not fuse with any of the other carpalia.

The Proximal Row of Bones.—The *navicular* arises from two centres of chondrification. It is homologous with the radiale of lower forms. The *lunar* is the last of the carpalia to be differentiated. According to Gegengaur and some other investigators, it is homologous with the os intermedium of the lower vertebrates. In man, however, there are no indications of its wandering from the forearm into the wrist. The *triquetrum* is relatively small when first differentiated, but grows rapidly in size (Figs. 298, 299 and 300). Perna has found it arising from two centres of chondrification. The *pisiform* is relatively large in embryonic stages. It is a canonic carpal element and not a sesamoid bone. It arises later than the triquetrum. During its development it wanders from the ulnar margin to the volar surface of the triquetrum.

The Distal Row.—The cartilages of the distal row are at first relatively large compared with those of the proximal row

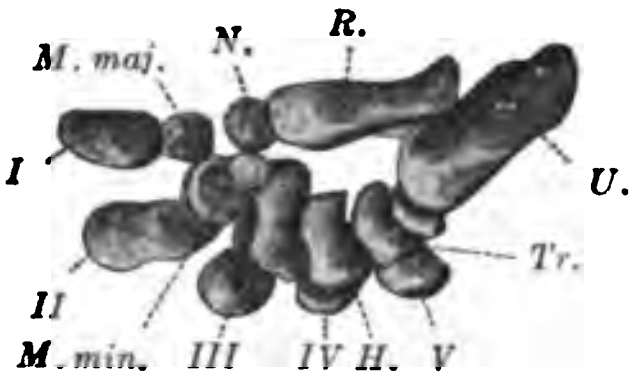

Fig. 298.

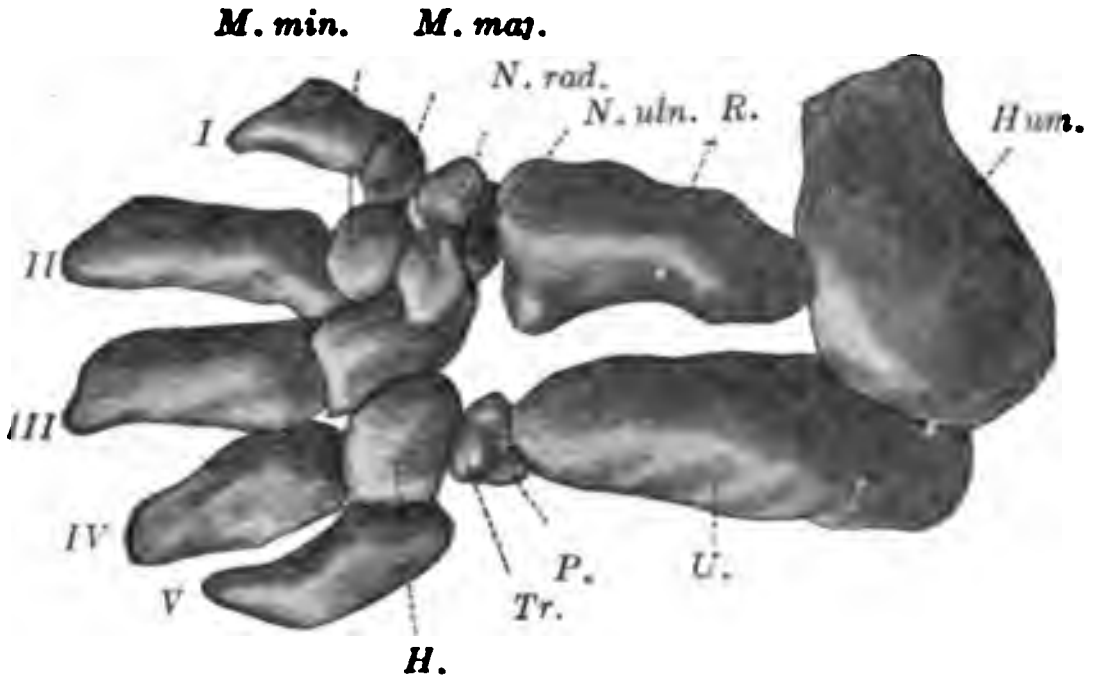

Fig. 299.

Fig. 298.—(After Gräfenberg, Anatomische Hefte, 1906, Fig. 1.) Dorsal view of a model of the skeleton of the forearm and hand of a five-weeks human embryo. Magn. 70 : 1.

Fig. 299.—(Ebenda, Fig. 2.) Dorsal view of a model of the skeleton of the forearm and hand of a six-weeks human embryo. Magn. 70 : 1. *H.*, hamatum; *Hum.*, humerus; *M. maj.*, multangulum majus; *M. min.*, multangulum minus; *N.*, navicular, *rad.*, pars radialis, *uln.*, pars ulnaris; *P.*, pisiforme; *R.*, radius; *Tr.*, triquetrum; *U.*, ulna. The capitatum lies between the hamatum and the multangulum minus; the centrale between the capitatum and the navicular.

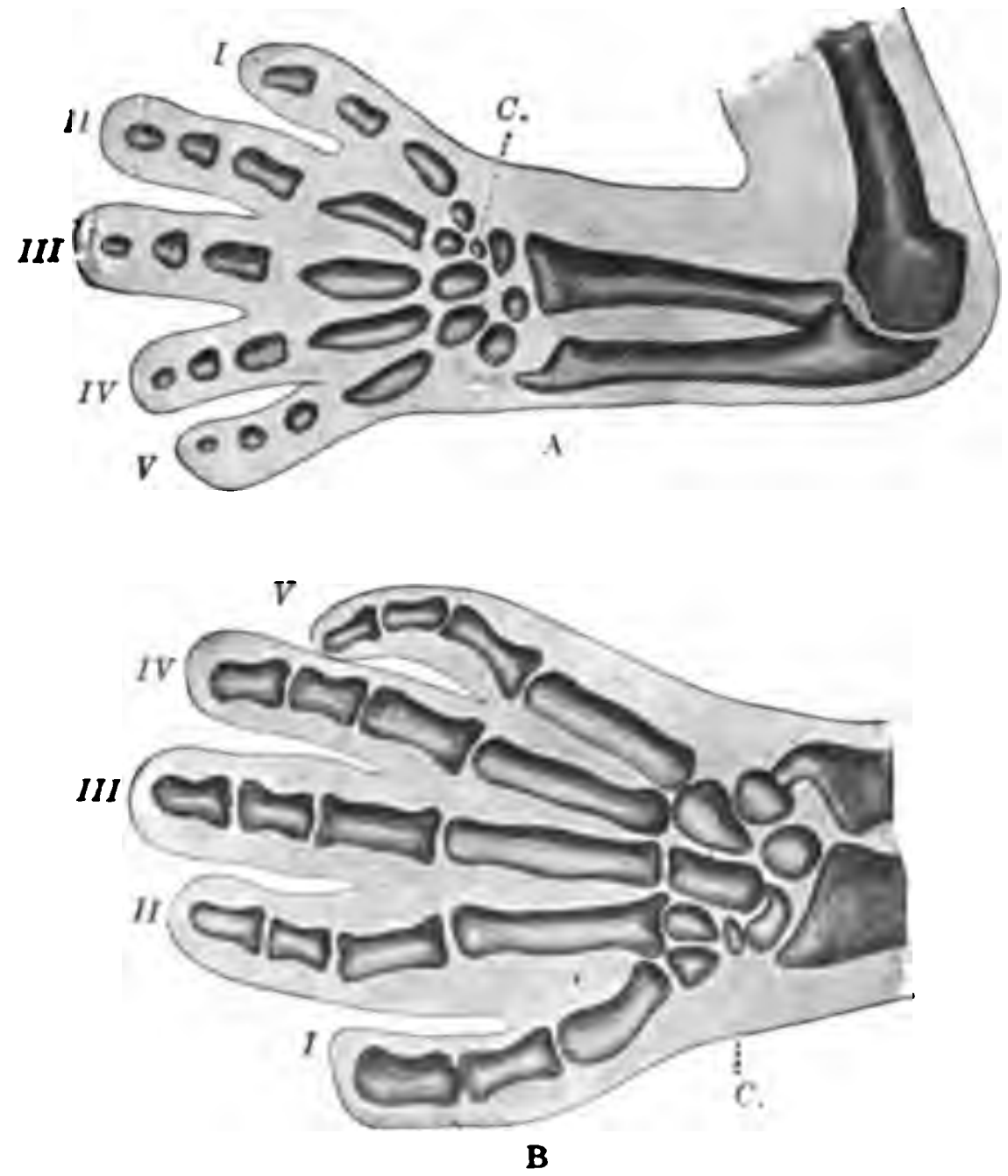

Fig. 300.—A. (After Gräfenberg, 1906, Fig. 5.) Dorsal view of the skeleton of the left forearm and hand of a seven-weeks human embryo. *C.*, os centrale. B. (Ebenda, Fig. 6.) Dorsal view of the skeleton of the right hand of a ten-weeks human fetus. *C.*, os centrale.

(Figs. 298 and 300). The capitatum is the largest, next comes the hamatum. The multangular carpalia are small; the M. majus is for a time considerably smaller than the M. minus. The capitatum and hamatum are the first elements of the carpus to undergo chondrification. The hamulus ossis hamati is differentiated from a special centre of chondrification.

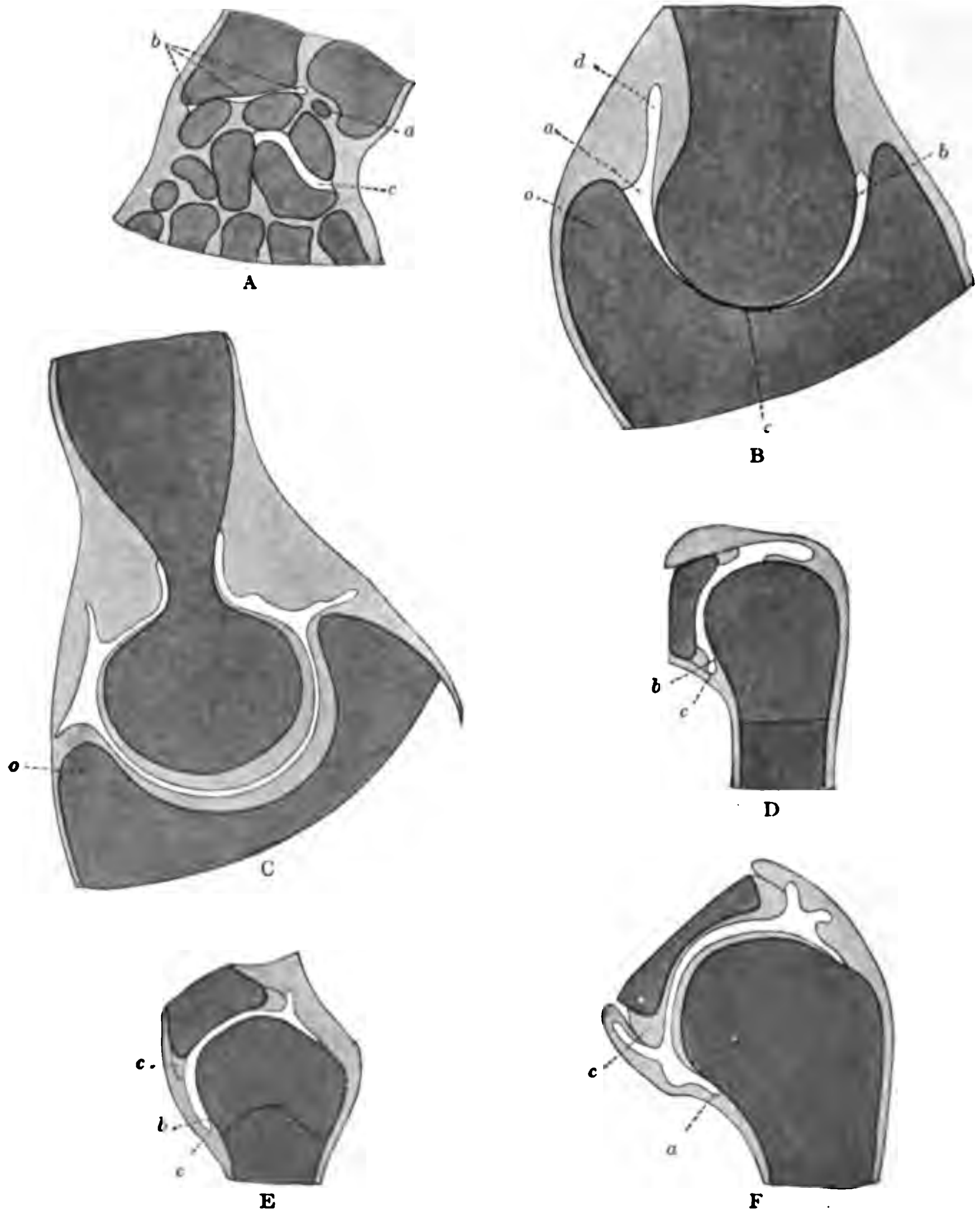

FIG. 301, A–F.—(After Schulin, Arch. f. Anat., u. Physiol., Anat. Abt., 1879.) Figures to illustrate the development of some of the joints of the superior extremity.

A. Horizontal section through the carpus of a fetus 7 cm. long. *a*, cartilaginous nucleus in the discus articularis; *b*, commencement of the fissure formation in the radiocarpal joint in three places; *c*, fissure between the triquetrum and hamatum. B. Elbow-joint of a fetus 7 cm. long. *a*, sinus; *b*, mesochondral part of joint cavity; *c*, central union; *d*, perichondral part of joint cavity; *o*, olecranon. C. Elbow-joint of an adult. *o*, olecranon. D, E, F. Shoulder-joint of a fetus 13 cm. long, of a new-born infant, and of an adult. *a*, insertion of capsule; *b*, intracapsular connective tissue; *c*, labrum glenoidale.

Metacarpalia.—These are at first relatively large. The first metacarpal, according to some investigators, represents a basal phalanx. Galen was the first to express the view that the metacarpal of the thumb is not present. Others have thought that a phalanx is missing from the thumb, but Graefenberg accepts the view of Galen. The other four cartilaginous metacarpals arise at some distance from one another (Fig. 298). They spread apart distally. The bases are first brought into contact with one another, and later the distal ends. The fifth metacarpal articulates at first with the triquetrum (Fig. 298) and later with the hamatum (Fig. 299).

The *phalanges* are differentiated in serial order, the basal row appearing first, the terminal row last. According to Graefenberg, the terminal phalanges show evidence of being composed of two elements, a proximal and a distal. The latter is composed of cartilage, the cells of which rapidly enlarge. It may represent a fourth phalanx. Primitively the digits were probably composed of many phalanges. The terminal phalanges are at first smaller than those of the middle row, but then develop faster so as to exceed them in length. After a time retrograde metamorphosis overtakes the distal ends of the terminal phalanges, so that the middle row once more exceeds the terminal in length. The tuberositas unguicularis is composed of fibrous tissue which becomes transformed directly into bone.

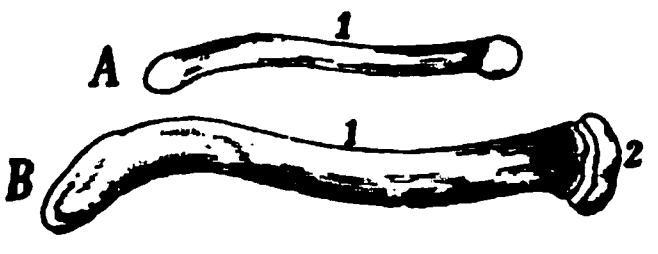

Fig. 302. (After R. Quain, Quain's Anatomy, 10th ed., vol. ii, Pt. 1, Fig. 115.) Ossification of the clavicle. A. Clavicle at birth. B. At about the twenty-third year. 1, shaft; 2, epiphysis.

The *sesamoid bones*, according to Thilenius, are more numerous in the fetus than in the adult. The following table, after Pfitzner and cited by Dwight (1907) illustrates this. This table is based on a study by Thilenius of 30 hands of fetuses of the fourth month, and of 1440 hands by Pfitzner of individuals from fourteen to eighty-nine years of age. The Roman numerals indicate the metacarpophalangeal joints opposite which sesamoid bones were found, and the Arabic numerals represent the percentage of frequency with which the bones were found.

	I.		II.		III.		IV.		V.	
	R.	L.	R.	L.	R.	L.	R.	L.	R.	L.
Embryos	(100	100)	(46	23)	(30	15)	(23	36)	(8	84)
Adults	(99.9	100)	(48	0.1)	(1.4	0)	(0	0.1)	(2.1	82.5)

JOINTS.

Schulin (1879) has given some account of the development of the joints of the upper extremity.

At the shoulder-joint (Fig. 301, D, E, F) a joint fissure arises in the periphery of the intermediate zone and thence extends inwards between the head of the humerus and the glenoid fossa (Fig. 301, D). The joint cavity extends into the perichondrium for some distance on each side of the head of the humerus, so that there is from a very early period a well-developed layer of intracapsular connective tissue (*b*). The labrum glenoidale is differentiated at an early period. After the joint cavity appears the

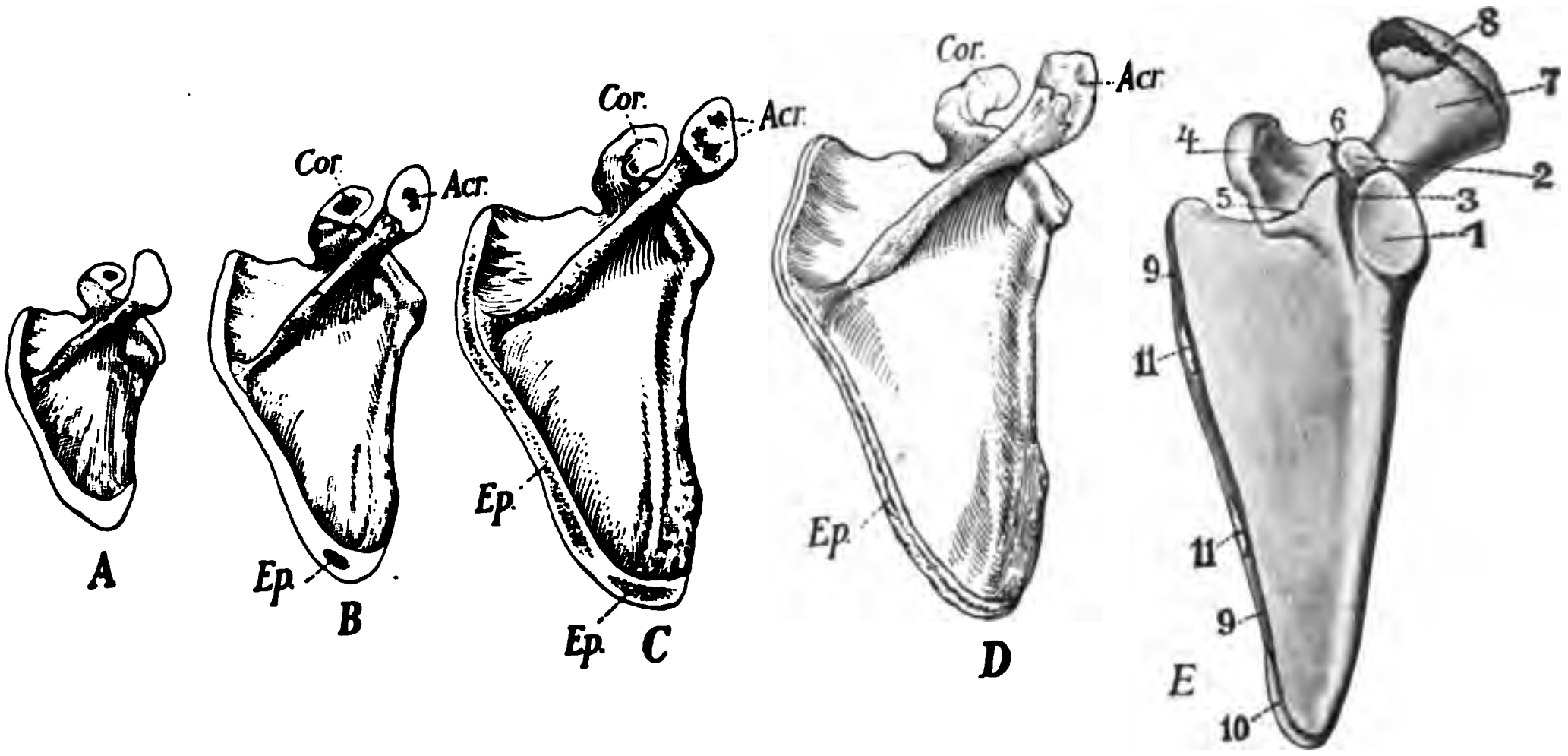

FIG. 303.—(A, B, C, D. After R. Quain, Quain's Anatomy, 10th ed., vol. ii, Pt. I, Fig. 116. E. After Sappey, Traité d'Anatomie, T. 1, Fig. 145.) Ossification of the scapula. A. At one year. B. At 15 or 16 years. C. At 17 or 18 years. D. At 22 years. *Acr.*, centres in acromion; *Cor.*, centre in coracoid process; *Ep.*, epiphysis. E. Epiphyses of scapula. 1, part of glenoid cavity ossified from primary centre; 2, subcoracoid; 3, inconstant epiphysis; 4, coracoid; 5, cartilage between the coracoid process and the body of the scapula; 6, cartilage between coracoid and subcoracoid; 7, acromion; 8, epiphysis of acromion; 9, cartilaginous border of scapula; 10, epiphysis of inferior angle; 11, osseous nuclei in cartilaginous border of scapula.

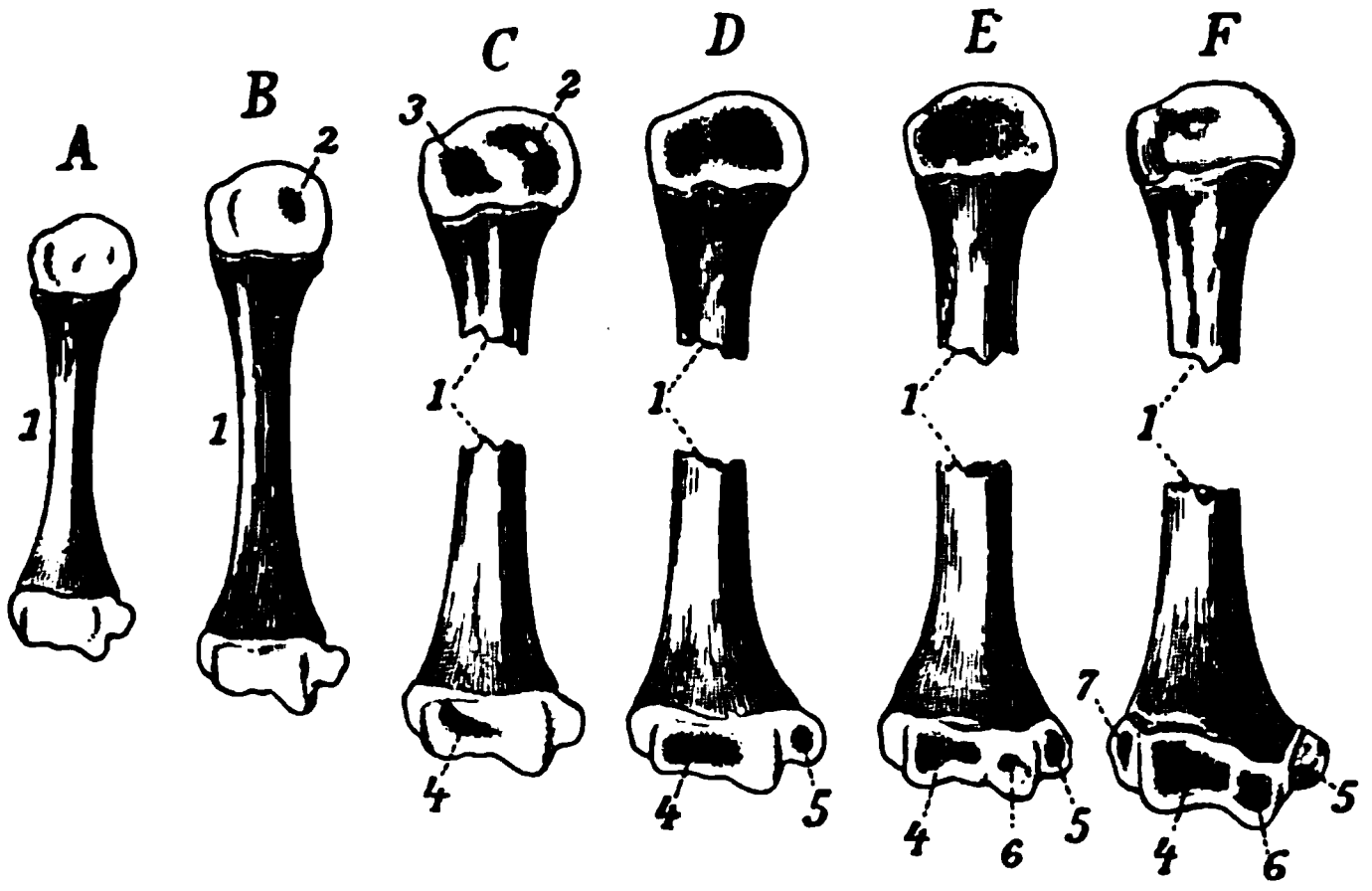

FIG. 304.—(After R. Quain, Quain's Anatomy, 10th ed., vol. ii, Pt. I, Fig. 118.) Ossification of the humerus. A. At term. B. At 1 year. C. At 3 years. D. At 5 years. E. At 12 years. F. At puberty. 1, shaft; 2, nucleus of head; 3, nucleus of tuberculum majus; 4, nucleus of capitulum; 5, nucleus of medial epicondyle; 6 nucleus of medial part of trochlea; 7, nucleus of lateral epicondyle.

head of the humerus undergoes considerable development. (Compare D, E, F, Fig. 301.) During fetal development the tendon of the long head of the biceps sinks in through the capsule of the joint. For a time it is covered by a layer of synovial membrane which attaches it to the capsule, but in the third or fourth month it becomes free in the joint cavity (Welcker, 1878).

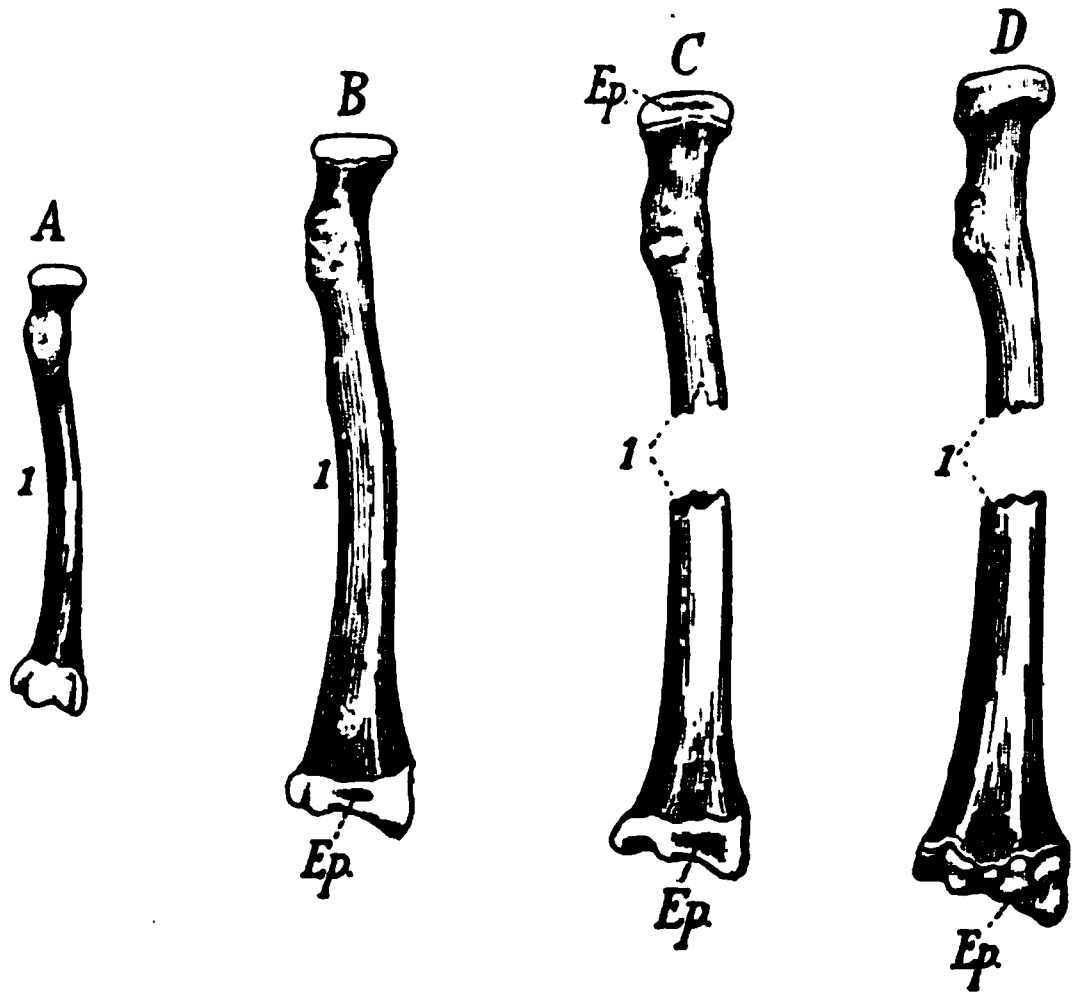

Fig. 305.

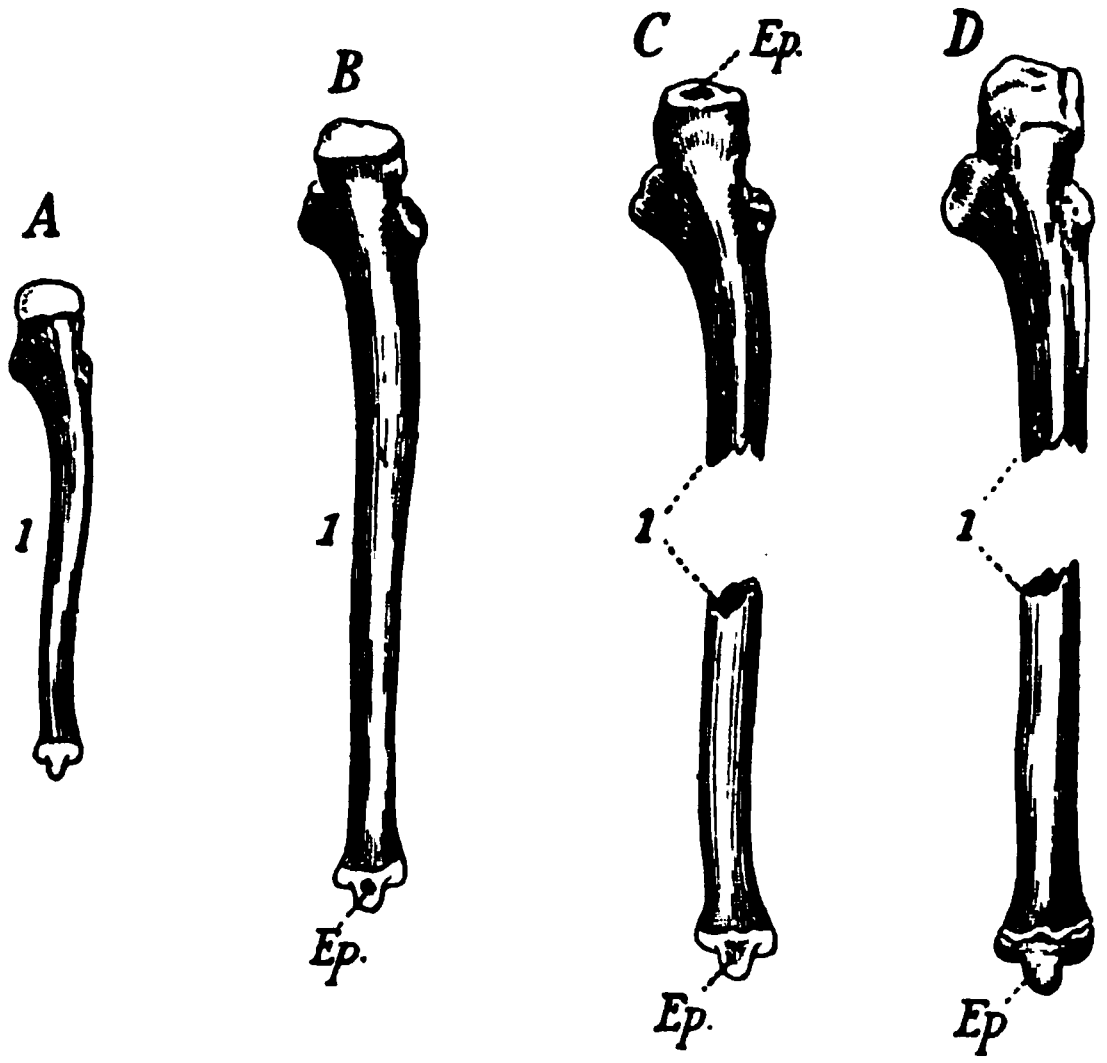

Fig. 306.

Figs. 305 and 306.—(After R. Quain, Quain's Anatomy, 10th ed., vol. ii, Pt. I, Figs. 119 and 120.) Ossification of the radius and ulna. Fig. 305. Radius. A. At term. B. At 2 years. C. At 5 years. D. At 18 years. Fig. 306. Ulna. A. At birth. B. At the end of the fourth year. C. At 12 years. D. At 19 to 20 years. *Ep.*, epiphysis.

The elbow-joint (Fig. 301, B and C) develops in a position of flexion at about 90°. The perichondral part of the joint cavity

(Fig. 301, B, *d*) develops before the intercartilaginous part. The distal end of the humerus undergoes marked alterations in form during the development of the joint (Fig. 301, C).

In the wrist-joint cavities appear during the third month (Fig. 301, A). At the radiocarpal joint the joint cavity arises from three separate fissures (*b*).

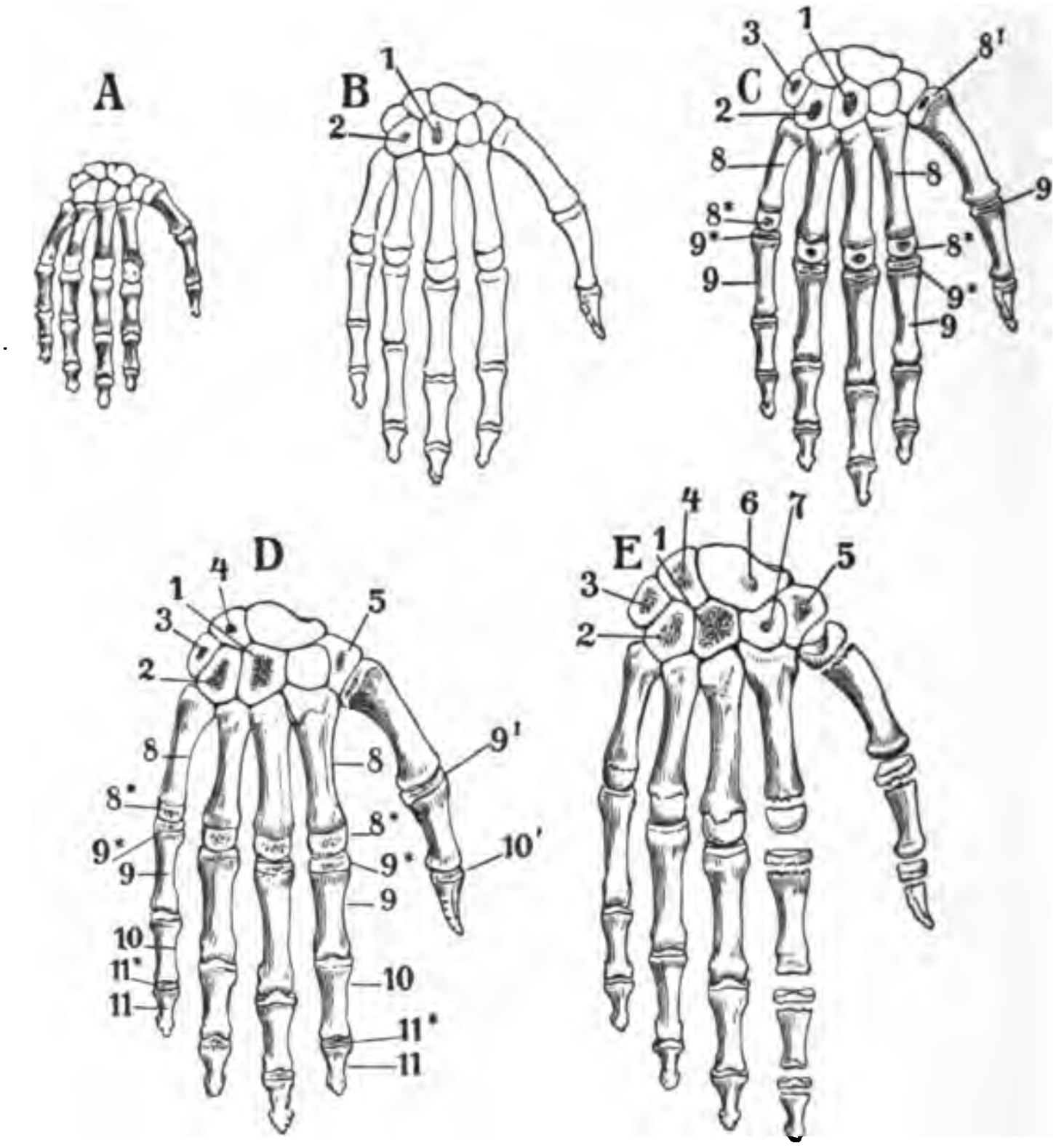

FIG. 307.—(After R. Quain, Quain's Anatomy, 10th ed., vol. ii, Pt. I, Fig. 121.) Ossification of the bones of the hand. A. At birth. The carpus is cartilaginous. The shafts of the metacarpals and phalanges are ossified. B. At the end of the first year. C. About the third year. D. At the fifth year. E. At the ninth year. 1, capitatum; 2, hamatum; 3, triquetrum; 4, lunatum; 5, multangulum majus; 6, navicular; 7, multangulum minus; 8, metacarpal shafts; 8*, four metacarpal epiphyses; 8¹, that of the thumb; 9, basal phalanges; 9*, their epiphyses; 9¹, that of the thumb; 10, middle phalanges; 10', epiphysis of terminal phalanx of thumb; 11, terminal phalanges of the fingers; 11*, their epiphyses.

The development of the digital joints has been previously described (Figs. 226–228).

PERIOD OF OSSIFICATION.

With the exception of the clavicle the bones of the superior extremity pass through a stage of embryonic hyaline cartilage before becoming ossified. The shaft of the clavicle, which is the first bone in the body to exhibit a centre of ossification, is ossified in a peculiar kind of cartilage (Mall). The ends of this bone exhibit the more usual type of ossific cartilage. The following table gives the approximate periods when the various centres of ossification appear and the time of fusion of the various centres which unite to form the individual bones. Authors differ considerably concerning these data. When not otherwise indicated, the data included in this table are based upon those given in Quain's Anatomy, 10th edition, vol. 2, p. 106.

According to Pryor (1906), the epiphyses of the hand appear earlier and unite to the shaft earlier in females than in males and in the first-born children earlier than in those born later. "The fully developed hand of the female is at least two years in advance of the male." Similar conditions have been found by Hasselwander in the skeleton of the foot.

TABLE OF OSSIFICATION OF THE BONES OF THE SUPERIOR EXTREMITY.

(Days and weeks refer to the prenatal, years to the postnatal period.)

Bone.	Centres.	Time of appearance of centre.	Union of primary and secondary centres; remarks.
Clavicle	Diaphysis	6th week	There are two centres in the shaft, a medial and a lateral. These blend on the 45th day (Mall). Shaft and epiphysis unite between the 20th and 25th years.
	Sternal epiphysis	18th to 20th year.	
Scapula	Primary centres:		The chief centre appears near the lateral angle. The subcoracoid centre appears at the base of the coracoid process and also gives rise to a part of the superior margin of the glenoid fossa. The coracoid process joins the body about the age of puberty. The acromial epiphyseal centres (two or three in number) fuse with one another soon after their appearance and with the spine between the 22d and 25th years (Quain); 20th year (Wilms). The subcoracoid and the epiphyses of the coracoid process, the glenoid fossa, the inferior angle, and the vertebral margin join between the 18th and 24th years in the order mentioned (Sappey).
	1. That of the body, the spine, and the base of the glenoid cavity.	8th week (Mall).[19]	
	2. Coracoid process	1st year.	
	3. Subcoracoid	10th to 12th year.	
	Epiphyses:		
	Acromial epiphyses	15th to 18th year.	
	Epiphysis of the inferior angle.	16 to 18th year.	
	Epiphyses of the vertebral border.	18th to 20th year.	
	Epiphyses of upper surface of coracoid.	16th to 18th year.	
	Epiphysis of surface of glenoid fossa.	16th to 18th year.	
Humerus	Diaphysis	6th to 7th week (Mall)	The epiphyses of the head, the tuberculum majus and the tuberculum minus (the last is inconstant) unite with one another in 4th–6th year and with the shaft in 20th–25th year. The epiphyses of the capitulum, lateral epicondyle, and trochlea unite with one another and then in the 16th–17th year join the shaft. The epiphysis of the medial epicondyle joins the shaft in the 18th year.
	Epiphyses:		
	Head	1st to 2d year.	
	Tuberculum majus	2d to 3d year.	
	Tuberculum minus	3d to 5th year.	
	Capitulum	2d to 3d year.	
	Epicondylus med.	5th to 8th year.	
	Lateral margin of trochlea.	11th to 12th year.	
	Epicondylus lat.	12th to 14th year.	

---

[19] According to Poirier, Traité d'Anatomie, p. 138, two centres appear in the eighth week, and unite in the third month to form a centre of ossification for the body of the scapula.

Bone.	Centres.	Time of appearance of centre.	Union of primary and secondary centres; remarks.
Radius	Diaphysis	7th week (Mall)	The superior epiphysis and shaft unite between the 17th and 20th years. The inferior epiphysis and shaft about the 21st year (Pryor); ♀ 21st year, ♂ 21st–25th year (Sappey). Sometimes an epiphysis is found in the tuberosity (R. and R.) and in the styloid process (Sappey).
	Epiphyses:		
	Carpal end	♀ 8th month. ♂ 15th month (Pryor).	
	Humeral end	5th–7th year.	
Ulna	Diaphysis	7th week	The centre for the shaft of the ulna arises a few days later than that for the radius. The proximal epiphysis is united to the shaft about the 17th year; the inferior epiphysis between the 18th and 20th years; ♀ 20th–21st years, ♂ 21st–24th years (Sappey). There is sometimes an epiphysis in the styloid process (Schwegel) and in the tip of the olecranon process (Sappey).
	Epiphyses:		
	Carpal end	♀ 6th–7th year. ♂ 7th–8th year (Pryor.	
	Humeral end	10th year.	
Carpus	Os capitatum	♀ 3d–6th month ♂ 4th–10th month.	The navicular sometimes has two centres of ossification (Serres, Rambaud and Renault). Serres and Pryor have described two centres of ossification in the lunatum. Debierre has described two centres in the pisiform, one in a girl of eleven, the other in a boy of twelve. The os hamatum may have a special centre for the hamular process. Pryor has found two centres in the triquetrum. Pryor (1908), describes the centres of ossification of the carpal bones as assuming shapes characteristic of each bone at an early period.
	Os hamatum	♀ 5th–10th month. ♂ 6th–12th month.	
	Os triquetrum	♀ 2d–3d year. ♂ about 3 years.	
	Os lunatum	♀ 3rd–4th year. ♂ about 4 years.	
	Os naviculare	♀ at 4 years, or early in 5th year. ♂ about 5 years.	
	Os mult. maj.	♀ 4th–5th year. ♂ 5th–6th year.	
	Os mult. min.	♀ 4th–5th year ♂ 5th–6th year.	
	Os pisiforme	♀ 9th–10th year. ♂ 12th–13th year.	
Metacarpals	Diaphyses	9th week (Mall)	The centres for the shafts of the second and third metacarpals are the first to appear. There may be a distal epiphysis for the first metacarpal and a proximal epiphysis for the second. Pryor (1906), found the distal epiphysis of the first metacarpal in about 6 per cent. of cases. It is a family characteristic. It arises before the 4th year and unites later. Pryor found the proximal epiphysis of the second metacarpal in six out of two hundred families. It unites with the shaft between the 4th and 6th–7th year; sometimes, however, not until the 14th year. In the seal and some other animals all the metacarpals have proximal and distal epiphyses (Quain). The epiphyses join the shafts between the 15th and 20th years. There may be an independent epiphysis for the styloid process of the 5th metacarpal. The epiphysis of the metacarpal of the index finger appears first. This is followed by those of the 3d, 4th, 5th, and 1st digits.
	Proximal epiphysis of the first metacarpal	3d year.	
	Distal epiphyses of the metacarpals.	2d year.	
Phalanges	Diaphyses	9th week (Mall)	The shafts of the phalanges of the second and third fingers are the first to show centres of ossification. The phalanges of the little finger are the last. The epiphysis in the middle finger is the first to appear. This is followed by those of the 4th, 2d, 5th, and 1st digits.
First row	Proximal epiphyses	1st–3d year (Pryor).	
Middle row	Diaphyses	11th–12th week (Mall)	The centres in the shafts of this row are the last to appear. The epiphysis of the phalanx of the middle finger is the first to appear. This is followed by those of the ring, index, and little finger (Pryor).
	Proximal epiphyses	2d–3d year.	
Terminal row	Diaphyses	7th–8th week	The terminal phalanx of the thumb is the first to show a centre of ossification in the shaft. This is the first centre of ossification in the hand. It is developed in connective tissue while the centres of the other phalanges are developed in cartilage (Mall). The epiphysis of the ungual phalanx of the thumb is followed by those of the middle, ring, index, and little fingers. The fusion of the epiphyses of the phalanges with the diaphyses takes place in the 18th–20th year.
	Proximal epiphyses	2d–3d year.	
Sesamoid bones			Ossification begins generally in the 13th–14th years, and may not take place until after middle life (Thilenius). For table of relative frequency in the embryo and adult see p. 385.

BIBLIOGRAPHY.

(On the development of the skeleton of the extremities in man. A few recent articles on variations and congenital deformities are included.)

Adrian, C.: Uber kongenitale Humerus- und Femurdefekte. Beiträge zur klin. Chir. Bd. 30. 1901.

Alexander, Bela: Die Entwicklung des knöchernen Handskelettes vom Beginn der ersten Knochenpunkte. Wiener klin-therap. Wochenschrift Nr. 27–28. 1905.

Die Entwicklung des menschlichen Handskeletts. Arch. für physikal. Med. Bd. 1. 1906.

Alsberg, M.: Die statisch-mechanischen Prinzipien der Extremitätenbildung beim Menschen und bei den Festlandtieren. Polit. Anthropol. Revue. Bd. 5, S. 605–611. 1907.

Anthony, R.: L'évolution du pied humain. Bull. et Mém. Soc. d'Anthrop. Sér. 5, T. 3, p. 818–835. Paris 1903.

Rev. Scientif. Ser. 4, T. 19, p. 129–139. 1903. Transl. in Annual Report of the Smithsonian Institution. p. 519–535. 1904.

Appraillé, G.: Malformations congénitales de l'extrémité supérieure du radius. Thèse. Paris 1901.

Bade, P.: Die Entwicklung der menschlichen Fussknochen nach Röntgogrammen. Sitz. Ber. Niederrhein. Ges. Bonn 1896.

Die Entwicklung des menschlichen Skeletts bis zur Geburt. Arch. mikr. Anat. Bd. 55. 1899.

Entwicklung des menschlichen Fussskeletts von der neunten Embryonalwoche bis zum 18. Jahre nach Röntgenbildern. Verh. d. Gesellsch. deutscher Naturf. und Arzte. S. 463–466. 1899–1900.

Barchielli, Alberto: Variazioni del margine superiore dello sterno umano e loro significato. Monit. Zool. Ital. Vol. 15. 1904.

Bardeen, Charles R.: Studies of the Development of the Human Skeleton. Amer. Journ. of Anat. Vol. 4, p. 265–305. 1905.

Bardeen, Charles R. and Lewis, W. H.: Development of the Limbs, Body-wall and Back in Man. Amer. Journ. of Anat. Vol. 1. 1901.

Bardeleben, v.: Das Intermedium tarsi beim Menschen. Sitzungsber. d. Jenaischen Gesellschaft für Med. und Naturw. 1883.

Zur Entwicklung der Fusswurzel. Sitzungsber. d. Jenaischen Gesellschaft für Med. und Naturw. Suppl. Bd. 19. 1885.

Hand und Fuss. Verhandl. d. anat. Gesellsch. auf der achten Versammlung. 1894.

Bernays, A.: Die Entwicklungsgeschichte des Kniegelenkes des Menschen mit Bemerkungen über die Gelenke im allgemeinen. Morphol. Jahrbuch. Bd. 4, p. 403. 1878.

Blencke: Uber kongenitalen Femurdefekt. Zeitschrift orthopäd. Chirurgie. Bd. 9. 1901.

Blomme, G.: Considérations sur la Polydactylie. Thèse de doctorat en méd. Paris 1901.

Bokay, L.: Untersuchungen an der Handwurzel menschlicher und einiger Säugerembryonen. Magyar Orvosi Anthr. Bd. 5. 1904.

Bolk, L.: Beziehungen zwischen Skelett, Muskulatur und Nerven der Extremitäten, dargelegt am Beckengürtel. Morphol. Jahrbuch. Bd. 21. 1894.

Die Segmentaldifferenzierung des menschlichen Rumpfes und seiner Extremitäten. Morphol. Jahrbuch. Bd. 26–28. 1898, 1899.

Bradley, O. C.: A Contribution to the Development of the Interphalangeal Sesamoid Bone. Anat. Anz. Bd. 28, p. 528–536. 1906.

Braus: Die Entwicklung der Form der Extremitäten und des Extremitätenskeletts. Hertwig's Handbuch der Entwicklungsgeschichte der Wirbeltiere. 1906 (appeared 1904).

Broom, R.: On the Arrangement of the Epiphyses of the Mammalian Metacarpals and Metatarsals. Anat. Anz. Vol. 28, p. 106–108. 1906.

Bruch, C.: Beiträge zur Entwicklungsgeschichte des Knochensystems. Neue Denkschriften der allg. Schweizerischen Gesellschaft für die gesamten Naturwissenschaften. Bd. 12. Zürich 1852.

Brunn, A. v.: Das Verhältnis der Gelenkkapseln zu den Epiphysen der Extremitätenknochen. Leipzig 1881.

Brunner, K.: Uber Genese, kongenitalen Mangel und rudimentäre Bildung der Patella. Virchow's Arch. Bd. 124. 1891.

Corson, E. R.: A Skiagraphic Study of the Normal Membral Epiphyses at the Thirteenth Year. Annals of Surgery. Vol. 32, p. 621–647. 1900.

Damany, P. le: Les torsions osseuses, leur rôle dans la transformation des membres. Journ. de l'Anat. et de la Physiol. Année 34, No. 2, p. 126–165, No. 3, p. 313 bis 337. No. 4, p. 426–450. No. 5, p. 534–545. 1903.

Une nouvelle théorie pathogénique de la luxation congénitale de la hanche. Rev. Chir. p. 175–179, 370–397. 1904.

La cavité cotyloïde. Evolution ontogénique comparée de sa profondeur chez l'homme et les animaux. Journ. de l'Anat. et de la Physiol. Année 40, No. 1. 1904.

L'Angle sacro-pelvien. Journ. de l'Anat. et de la Physiol. Année 42, p. 153. 1906.

Davies, W.: Zur Frage der Fingermissbildungen. Dissert. Greifswald 1900.

Debierre: Contribution à l'étude de l'ossification et de l'homotypie des pièces du carpe et du tarse chez l'homme. Journ. de l'Anat. et de la Physiol. T. 22. 1886.

Dixey, F. A.: On the Ossification of the Terminal Phalanges of the Digits. Proc. Roy. Soc. Vol. 31, p. 63–71. 1881.

Drehmann: Uber kongenitalen Femurdefekt. Zeitschrift orthop. Chir. Bd. 2, S. 220 bis 233. 1902.

Dwight, T.: Variations of the Bones of the Hand and Foot. 1907.

Eggeling, H.: Uber den oberen Rand des menschlichen Brustbeinhandgriffes. Verhdl. Anat. Ges. (Heidelberg). 1903. Anat. Anz. Bd. 23. Erg.-Heft. 1903.

Engel: Uber kongenitale Ankylosen an den Gelenken der Hände und Füsse. Inaug.-Diss. Berlin 1902.

Falk, E.: Zur Entwicklung des knöchernen Beckens. Verh. Berl. med. Ges. Bd. 30, S. 290–292. 1899.

Die Entwicklung und Form des fetalen Beckens. 6 Abbildungen und 5 Tafeln. Berlin 1908.

Farabeuf, Lop.: Gaz. Hop. (Cited in Poirier et Charpy, Traité. Vol. 1, p. 702). 1895.

Fargeas, J. B.: Etude sur l'absence congénitale de la rotule. Thèse. Paris 1900.

Fawcett, E.: The Presence of Two Centres of Ossification in the Olecranon Process of the Ulna. Journ. of Anat. and Physiol. Vol. 38, p. xxvii. 1904.

Fehling, H.: Die Form des Beckens beim Fetus und Neugeborenen und ihre Beziehung zu der beim Erwachsenen. Archiv für Gynäkologie. Bd. 10, p. 1–80. 1876.

Féré, O. und Papin, Ed.: Fractures ou anomalies de développement de la clavicle. Rev. Chir. Année 23. 1903.

Fischel, A.: Untersuchungen über die Wirbelsäule und den Brustkorb des Menschen. Anat. Hefte. Bd. 31. 1906.

Franz, K.: Zur Entwicklung des knöchernen Beckens nach der Geburt. Beitrag zur Geburtsh. und Gynäkol. Bd. 13, S. 12–29. 1908.

Fürbringer, M.: Morphologische Streitfragen. Morpholog. Jahrbuch. Bd. 30, S. 85. 1902.

Gallois, E., et Cade, A.: Recherches anatomiques sur la date d'apparition et le développement du ligament ou membrane interosseuse de l'avant-bras. Journ. de l'Anat. et de la Physiol. Année 39, p. 39–44. Paris 1903.

Gegenbaur, C.: Ein Fall von erblichem Mangel der Pars acromialis claviculae mit Bermerkungen über die Entwicklung der Clavicula. Jen. Zeitschrift. Bd. 1, S. 1 bis 16. 1864.

Vergleichende Anatomie der Wirbeltiere mit Berücksichtigung der Wirbellosen. Bd. 1. Leipzig 1898.

Gräfenberg, E.: Die Entwicklung der Knochen, Muskeln und Nerven der Hand und der für die Bewegungen der Hand bestimmten Muskeln des Unterarms. Anat. Hefte. Bd. 30, S. 1–154. 1906.

Grashey, R.: Basale Epiphyse des Metacarpale I. und Pseudoepiphysen. Zeitschrift für Morphol. und Anthropol. Bd. 10, S. 94–97. 1906.

Gross, Alfr.: Uber angeborenen Mangel des Schlüsselbeins. Münch. med. Wochenschrift. Bd. 50, S. 1151–1153. 1903.

Gruber, W.: Vorläufige Mitteilung über die sekundären Fusswurzelknochen des Menschen. Archiv für Anat. und Physiol. 1884.

Grynfeltt, E.: Sur les premiers stades de la formation de la cavité articulate du genou chez l'homme. Bull. Soc. Anat. Paris, Vol. 79, sér. 7. 1904.

Note sur le développement de l'articulation du genou chez l'homme. Montpellier méd. No. 25, p. 613–624; No. 26, p. 641–655; No. 27, p. 13–21. 1904.

Guldberg, G. A.: Uber die Krümmung des Oberschenkels. Internat. Monatsschrift Anat. und Physiol. Bd. 21. 1904.

Hagen, W.: Die Bildung des Knorpelskelettes beim menschlichen Embryo. Arch. für Anat. und Physiol. 1900.

Hagmeister, Ed.: Uber angeborenen Mangel der Fibula. Inaug.-Diss. Kiel 1902.

Hagopoff: De l'origine et du mode de développement embryonnaire de l'articulation de la hanche. Compt. Rend. Soc. Biol. Paris, Vol. 5, p. 51–54. 1898.

Hahn, Herm.: Röntgographische Untersuchungen über das Verhalten der Epiphysen der Unterschenkelknochen während des Wachstums. Festschrift zum 70. Geburstag v. C. von Kuppfer. Bd. 3, S. 731. Jena 1899.

Hasselwander: Untersuchungen über die Ossifikation des menschlichen Fussskeletts. Zeitschrift für Morphologie und Anthropologie. Bd. 5, S. 438–508. 1903.

Uber die Ossifikation des Fussskeletts. Anat. Anz. Bd. 32, S. 608. 1908.

Hassenstein, W.: Zur Reifebestimmung des Fetus aus dem Knochenkern der Oberschenkelepiphyse. Zeitschrift für Medizinalbeamte. 1892.

Heimann, Alfr. und Potpeschnigg, K.: Uber die Ossifikation der kindlichen Hand. Jahrbuch für Kinderheilkunde. Bd. 65, S. 437–456. 1907.

Heine, Otto: Uber den angeborenen Mangel der Kniescheibe. Berl. klin. Wochenschrift. Bd. 41. 1904.

Henke und Reyher: Studien über die Entwicklung der Extremitäten des Menschen insbes. der Gelenkflächen. Sitzungsb. d. K. Akad. der Wiss., Wien. Math.-naturw. Klasse. Bd. 70, 3. T., S. 217. Wien 1874.

Hennig, C.: Das kindliche Becken. Arch. für Anat. und Physiol. Anat. Abt. 1880.

Hepburn, D.: The Development of Diarthrodal Joints in Birds and Mammals. Journ. of Anat. and Physiol. Vol. 23, p. 507. 1889.

Hissbach, Friedr.: Uber Polydactylie, deren Wesen und Bedeutung. Med. Diss. Leipzig 1902.

HOFFMANN, C. K.: Zur Morphologie des Schultergürtels und des Brustbeines bei Reptilien, Vögeln, Säugetieren und beim Menschen. Niederländ. Archiv für Zoologie. Bd. 5. 1879.

HOLL, M.: Uber die Entwicklung der Stellung der Gliedmassen des Menschen. Sitzungsb. d. K. Akad. d. Wiss. Wien Math.-naturw. Klasse. Bd. 100, 3 T., S. 12. Wien 1891.

HUETER, C.: Virchow's Arch. Bd. 25, 26, 28, 36. See also Klinik der Gelenkkrankheiten. S. 9. 1870.

HULKRANTZ, J. W.: Das Ellenbogengelenk und seine Mechanik. Jena 1897.

HUMPHREY: The Angle of the Neck with the Shaft of the Femur at Different Periods of Life and under Different Circumstances. Journ. of Anat. and Physiol. Vol. 23, p. 273, 387. 1889.

JENKINS: The Morphology of the Hip Joint. Brit. Med. Journ. No. 2393, p. 1702. 1906.

JOACHIMSTHAL, G.: Uber Brachydactylie und Hyperphalangie. Virchow's Arch. Bd. 151. 1898.

Die angeborenen Verbildungen der oberen Extremitäten. Röntgenbilder. Fortschritte auf dem Gebiet der Röntgenstrahlen. Ergänzungsh. 1900.

Die angeborenen Verbildungen der unteren Extremitäten. Röntgenbilder. Fortschritte auf dem Gebiet der Röntgenstrahlen. Ergänzungsh. Bd. 8. 1902.

Uber angeborene Defektbildungen am Oberschenkel. Beitrag zur Gynäkol. und Geburtshilfe. Festschrift f. Leopold Landau. Berlin 1902.

Verschiedene Formen angeborener Fussdeformitäten. Verh. d. Deutsch. Gesellschaft für Chir. Bd. 1, S. 66–67. 1906.

JOHNSTON, H. M.: Epilunar and Hypolunar Ossicles, Division of the Scaphoid and Other Abnormalities in the Carpal Region. Journ. of Anat. and Physiol. Vol. 41, p. 59–65. 1906.

JULIEN, A.: Loi de l'apparition du premier point épiphysaire des os longs. Compt. Rend. Acad. Sc. T. 114, p. 926–929. Paris 1892.

KASTSCHENKO, N.: Uber die Entwicklung der Finger beim menschlichen Embryo. Charkow 1884. (Russian.)

KAZZANDER, G.: Beitrag zur Lehre über die Entwicklungsgeschichte der Patella. Med. Jahrbuch. Bd. 1, S. 59–78. Wien 1886.

Sullo svilluppo dell' articolazione del ginocchio. Monitore Zool. Ital. Vol. 5, p. 220. 1894.

Uber die Entwicklung des Kniegelenkes. Archiv f. Anat. und Physiol. Anat. Abt. S. 161. 1894.

KESKINEFF, G.: Contribution à l'étude des hypertrophies congénitales des membres. Thèse. Nancy 1900.

KINDL, J.: Fünf Fälle von angeborenen Defektbildungen an den Extremitäten. Zeitscht. für Heilkunde. Bd. 38, S. 110–138. 1907.

KIRCHNER, A.: Die Epiphyse am proximalen Ende des os metatarsale V. nebst Bemerkungen zur Calcaneus-Epiphyse. Anat. Hefte. Bd. 33, p. 513–551. 1907.

KLAATSCH, H.: Die wichtigsten Variationen am Skelett der freien unteren Extremität des Menschen und ihre Bedeutung für das Abstammungsproblem. Ergebnisse der Anatomie und Entwicklungsg. Bd. 10, S. 599–719. 1900.

KLAUSSNER, FERD.: Uber Missbildungen der menschl. Gliedmassen und ihre Entstehungsweise. Wiesbaden 1900.

KOLLMANN, J.: Handskelett und Hyperdactylie. Verhdl. Anat. Ges. (Würzburg). 1888. (Diskussion zu diesem Vortrag: A. Froriep, M. Fürbringer.) Anat. Anz. Bd. 3. 1888.

KONIKOW, M.: Zur Lehre von der Entwicklung des Beckens und seiner geschlechtlichen Differenzierung. Arch. für Gynäkologie. Bd. 45, S. 19. 1894.

KRAUSE, W.: Os acetabuli. Internationale Monatsschrift für Anatomie und Histologie. S. 150. 1885.

LAMBERTZ: Die Entwicklung des menschlichen Knochengerüstes während des fetalen Lebens, dargestellt an Röntgenbildern. Fortschr. auf d. Gebiet d. Röntgenstrahlen. 1900.

LAZARUS: Zur Morphologie des Fussskeletts. Morphol. Jahrbuch. Bd. 24. 1896.

LEBOUCQ, H.: Le développement du premier métatarsien et de son articulation tarsienne chez l'homme. Archives de Biologie. T. 3, p. 335. 1882.

Uber die Entwicklung der Fingerphalangen. Verhdl. Anat. Ges. (Tübingen) 1899. Anat. Anz. Bd. 16. Erghft. 1899.

Recherches sur le développement des phalanges terminales des doigts chez l'homme et les mammifères. Ann. soc. med. Gand. T. 89. 1904.

LECKE, W.: Das Vorkommen und die morphologische Bedeutung des Pfannenknochens (os acetabuli). Intern. Monatschr. f. Anat. u. Physiol. Bd. 1, p. 363. 1884.

LEWIS, W. H.: Development of the Arm in Man. Amer. Journ. of Anat. Vol. 2, page 145. 1902.

LUBSEN, J.: Zur Morphologie des Ilium bei Säugern. Petrus Camper, Dl. II. 3 Aufl. 1903.

LUCIEN, M.: Développement de l'articulation du genou et formation du ligament adipeux. Bibl. Anat. Suppl. T. 13. 1904.

LUDLOFF: Uber Wachstum und Architektur der unteren Femurepiphyse und oberen Tibiaepiphyse. Ein Beitrag zur Röntgendiagnostik. Beiträge klin. Chir. Bd. 38, S. 64–75. 1903.

Die Entwicklung der unteren Femurepiphyse und oberen Tibiaspitze im Röntgenbild. Ver. wissensch. Heilk. Königsberg 1903.

MALL, F. P.: On Ossification Centers in Human Embryos Less than One Hundred Days Old. Amer. Journ. of Anat. Vol. 5, p. 433. 1906.

MAYET: Développement de l'extrémité du premier métatarsien. Bull. de la Société Anat. de Paris. Année 70, p. 384–388. 1895.

MEHNERT, E.: Untersuchungen über die Entwicklung des Beckengürtels bei einigen Säugetieren. Morphol. Jahrbuch. Bd. 16; S. 97–112. 1889.

MERKEL: Beckenwachstum. Anat. Hefte. Bd. 1, S. 121–150. 1902.

MOLLIER: Die paarigen Extremitäten der Wirbeltiere. Anat. Hefte. Bd. 8, 16 und 24. 1893–97.

MOSER: Uber das ligamentum teres des Hüftgelenkes. Schwalbe's Morphol. Arbeiten. Bd. 2, S. 36. 1893.

NEUHAUSER, H.: Die Beckendrehung. Zeitschrift für Morphol. u. Anthropol. Bd. 3. Stuttgart 1901.

NOLTE, AD.: Ein Fall von kongenitalem totalem Tibiadefekt. Diss. Leipzig 1903.

PAGENSTECHER, E.: Beiträge zu den Extremitätenmissbildungen. Deutsche Zeitschrift für Chir. Bd. 60. 1901.

PARKER and SHATTUCK: Pathology and Etiology of Club-Foot. Trans. Path. Soc. of London. Vol. 35. 1884.

PATERSON, A. M.: Development of the Sternum and Shoulder Girdle in Mammals. Brit. Med. Journ. 1902.

PERNA, G.: L'os trigonum ed il suo omologo nel carpo. Arch. Ital. Anat. e Embriol. Vol. 2, p. 237–254. 1903.

PETERSEN: Untersuchungen zur Entwicklung des menschlichen Beckens. Arch. für Anat. und Physiol. Anat. Ab. S. 67–96. 1893.

PFITZNER, W.: Beiträge zur Kenntnis der Missbildungen und Variationen des menschlichen Extremitätenskeletts. Morphol. Arb. Bd. 1–8. 1892–1898.

Uber Brachyphalangie und Verwandtes. Verh. Anat. Ges. Anat. Anz. Bd. 14, Erghf. 1898.

Die morphol. Elemente des menschlichen Handskeletts. Zeitschrift für Morphol. und Anthropol. Bd. 2. 1900. Bd. 4. 1901.

Picqué: Formule de l'ossification des phalanges, des métacarpiens de la clavicule et des côtes. Compt. rend. soc. biol. Paris. Vol. 4, p. 247–248. 1892.

Preleitner, K.: Zwei Fälle von angeborenem partiellem Claviculardefekt. Wiener klin. Wochenschrift. Bd. 16. 1903.

Pryor, J. W.: The X-ray in the Study of Congenital Malformations. Medical Record. Nov. 1906.

Ossification of the Epiphyses of the Hand. X-ray Method. Bulletin of the State College of Kentucky. Series 3, No. 4. 1906.

The Chronology and Order of Ossification of the Bones of the Human Carpus. Bulletin of the State University, Lexington, Ky. April 1908.

Pye, W.: On the Growth Rate of the Bones of the Lower Extremities with Especial Reference to Rickety Curvatures. Journ. of Anat. and Physiol. Vol. 23, p. 116. 1889.

Rabl: Gedanken und Studien über den Ursprung der Extremitäten. Zeitschrift für wiss. Zool. Bd. 70, S. 474–558. 1901.

Rabl: Uber einige Probleme der Morphologie. Verh. anat. Ges. Anat. Anz. Bd. 23. Ergänz.-Heft. 1903.

Ranke, W.: Die Ossification der Hand unter Röntgenbeleuchtung. Münch. med. Wochenschr. S. 1365. 1898.

Reiner, M.: Uber die kongenitalen Femurdefekte. Zeitschrift für orthopäd. Chirurgie. Bd. 9. 1901.

Rieder, H.: Uber gleichzeitiges Vorkommen von Brachy- und Hyperphalangie an der Hand. Deutsch. Arch. klin. Med. Bd. 66, S. 330–348. 1899.

Retterer: De l'ossification du pisiforme de l'homme, du chien et du lapin. C. R. Soc. Biol. Paris. T. 5. 1898.

Ebauche squelettogène des membres et développement des articulations. Journal de l'Anat. et de la Physiol. Année 38, p. 473–509, 580–623. 1902.

Retzius, G.: Uber die Aufrichtung des fetal retrovertierten Kopfes der Tibia bei Menschen. Zeitschrift Morphol. und Anthrop. Bd. 2. 1900.

Robertson, W. G.: A Case of Supernumerary and Webbed Fingers. Edinburgh Medical Journal. Vol. 14, p. 535–536. 1900.

Romiti, G.: Sui caratteri sessuali nel bacino del neonato. Atti della Società Toscana di Science Naturali. Vol. 8. Pisa 1892.

Rosenberg, E.: Uber die Entwicklung der Wirbelsäule und das Centrale Carpi des Menschen. Morphol. Jahrbuch. Bd. 1. Leipzig 1876.

Rückert: Ossifikation des menschlichen Fussskeletts. Sitzungsb. d. König. Bay. Akad. Math.-nat. Kl. S. 65–72. München 1901.

Ruge, Ernst: Die Entwicklung des Skeletts der vordenen Extremität von Spinax niger. Morphol. Jahrbuch. Bd. 30, S. 1–27. 1902.

Sachs, Adalb.: Uber angeborene Defekte der Schlüsselbeine. Diss. Leipzig 1902.

Schickele, G.: Beitrag zur Lehre des normalen und gespaltenen Beckens. Beiträge Geburtsh. und Gynäkol. Bd. 4, S. 243–272. 1901.

Schomburg, H.: Untersuchungen der Entwicklung der Muskeln und Knochen des menschlichen Fusses. Dissertation. Göttingen 1900.

Schrenk v. Notzing, Alb. Frh.: Beiträge zur Kenntnis der angeborenen Luxationen im Sprunggelenk. Diss. Leipzig 1902.

Schulin, K.: Uber die Entwicklung und weitere Ausbildung der Gelenke des menschlichen Körpers. Arch. f. Anat. u. Physiol. Anat. Abt. S. 240–274. 1879.

Schwegel: Die Entwicklungsgeschichte der Knochen des Stammes und der Extremitäten. Sitz. Ber. Akad. d. Wiss. Wien. Bd. 30, S. 337–388. 1858.

Sewell, R. B. S.: Lamellæ in Fœtal Astragalus. Journ. of Anat. and Physiol. Vol. 41, p. 45–48. London 1906.

SICK, C.: Entwicklungsgeschichte der Knochen der unteren Extremitäten. Mit 58 Röntgenbildern. 1902. Also in Arch. und Atlas der normalen und patholog. Anatomie in typischen Röntgenbildern. Fortschritte aus dem Gebiete der Röntgenstrahlen. Ergänzungsband. Bd. 9. 1902.

SPITZY, H.: Uber Bau und Entwicklung des kindlichen Fusses. Jahrbuch für Kinderheilk. Bd. 57, S. 731–762. 1903.

Uber das Fussgewölbe. Wiener klin. Wochenschrift. Bd. 16, S. 890. 1903.

STIEDA, ALFR.: Zur Kenntnis der Sesambeine der Finger und Zehen. Beitr. klin. Chir. Bd. 42. 1894.

STEINHAUS, F.: Kongenitaler Tibiadefekt. Virchow's Arch. Bd. 163. 1902.

THILENIUS, G.: Die überzähligen Carpuselemente menschlicher Embryonen. Anat. Anz. Bd. 9, S. 665. 1894.

Die metacarpo-phalangealen Sesambeine menschlicher Embryonen. Anat. Anz. Bd. 9. 1894.

Zur Entwicklungsgeschichte der Sesambeine der menschlichen Hand. Morphol. Arbeiten. Bd. 5. Jena 1896.

Das os intermedium antebrachii des Menschen. Ebenda. Bd. 5. 1896.

Untersuchungen über die morphologische Bedeutung accessorischer Elemente am menschlichen Carpus. Ebenda. Bd. 5. 1896.

Accessorische und echte Skelettstücke. Anat. Anz. Bd. 13. 1897.

THOMSON, A.: The Sexual Differences of the Fetal Pelvis. Journal of Anat. and Physiol. Vol. 33, p. 3 and 359–380. 1899.

TORNIER, G.: Das Entstehen der Gelenkformen. Arch. für Entw.-Mech. Bd. 1. Leipzig 1895.

VEIT: Die Entstehung der Form des Beckens. Zeitschrift für Geburtsh. und Gynäkologie. Bd. 9, S. 347. 1889.

VIANNAY: Destot et Gallois, Note sur l'ossification des epiphyses du coude. Bull. Soc. Anat. Paris 1904.

VUILLAUME, G.: Contribution à l'étude l'absence congénitale du tibia. Thèse de doctorat en méd. Lyon 1898.

WALKHOFF, E.: Die Architektur des menschlichen Beckens im Lichte der Entwicklungsmechanik. S.-B. phys. med. Ges. Würzburg 1904.

WELCKER: Die Einwanderung des Bicepssehne in das Schultergelenk. Arch. für Anat. und Physiol. Anat. Abt. S. 20. 1878.

WHITELY and PEARSON: Data for the Problem of Evolution in Man. 1. A First Study of the Variability and Correlation of the Hand. Proc. R. Soc. Vol. 65. 1899.

WIEDERSHEIM, R.: Das Gliedmassenskelett der Wirbeltiere. Jena 1892.

WILGRESS, J. H. F.: A Note on the Development of the External Malleolus. Journ. of Anat. and Physiol. Vol. 34. 1900.

WILMS: Die Entwicklung der Knochen oberen Extremitäten, dargestellt in Röntgenbildern. Arch. und Atlas der normalen und patholog. Anatomie in typischen Röntgenbildern, Fortschritte auf dem Gebiete der Röntgenstrahlen. Ergänzungsband. Bd. 9. 1902.

WITTFELD, E.: Uber angeborenen Hochstand der scapula. Diss. Bonn 1901.

WRIGHT, WILLIAM: Case of Accessory Patellæ in the Human Subject, with Remarks on Emargination of the Patella. Journ. of Anat. and Physiol. Vol. 38. 1903.

WUTH, E. A.: Uber angeborenen Mangel sowie Herkunft und Zweck der Kniescheibe. Arch. klin. Chir. Bd. 58. 1899.

E. THE SKULL, HYOID BONE, AND LARYNX.

General Features.

We may distinguish in the skull, considered purely topographically, a neural and a visceral region. The neural region serves to protect and support the brain and sense organs; the visceral, for the alimentary and respiratory tracts. A sharp demarcation between the two regions is not possible. Thus the base of the skull, especially its axial portion, has relations to both regions, and through change of function changes in the two regions may be brought about (ear ossicles). We shall begin with a description of the axial part of the skull, which generally is counted a part of the neural region.

The axial region is that portion which is continued forward from the vertebral axis. It includes the basal portion of the occipital bone and the body of the sphenoid. In the embryo the chorda dorsalis extends anteriorly to the hypophysis. The axial region of the skull is thus divisible into chordal and prechordal portions, the former lying posterior, the latter anterior to the hypophysis. The chordal portion is further divisible into an otic part, which corresponds roughly with that portion of the base of the skull which articulates with the temporal bone, and a postotic part, which extends to the otic part from the spinal column. The prechordal region supports the orbitotemporal and ethmoidal portions of the skull.

The neural region lies dorsal, lateral, and apical from the axial region with which it is intimately associated. It serves to encapsulate the brain (cranial cavity) and the organs for hearing, smell, and vision (petrous portion of the temporal bone, orbital and nasal cavities).

The visceral region lies chiefly ventral and ventrolateral to the axial region. In part it is closely associated with the neural region. It includes the pterygoid processes of the sphenoid, the hard palate, the bones of the upper and lower jaws, and the hyoid bone. From the primitive visceral skeleton of the head are also derived the bones of the middle ear and the cartilages of the larynx.

In the development of the complex skeletal apparatus of the head, overlapping blastemal or membranous, chondrogenous, and osseogenous stages may be distinguished.

The origin of the mesenchyme of the head has already been described (p. 297). It is at first rather loose in structure, but soon becomes condensed in various regions. This condensation usually marks the beginning of the differentiation of the mesenchyme into muscles and into various connective-tissue structures of more or less definite form, tendons, fascias, dermis, submucous coats, membranes of the brain, and portions of the organs of special sense and the anlages of the skull and the larynx. The membranous anlage of the skeleton of the head is gradually developed from several centres of condensation. In part it is transformed into cartilage, forming the chondrocranium.

The chondrocranium arises through the fusion of a considerable number of cartilages which originate from independent centres of chondrification. Some of these centres of chondrification arise in mesenchymatous tissue which shows no well-marked condensation preceding the formation of cartilage. The transformation of membranous tissue into cartilage in some instances takes place very rapidly, in other instances slowly.

The chondrocranium reaches its highest relative development in the third month of intra-uterine life. At this period it comprises the axial region of the skull, the auditory and olfactory capsules, the orbital wings and the bases of the temporal wings of the sphenoid, the occipital condyles, and the tectum posterius which lies dorsolateral to the occipital and temporal regions (Figs. 312 and 313). In the first and second branchial arches well-marked cartilaginous skeletal structures are formed; in the first the malleus and incus; in the second, the stapes and the styloid process of the temporal bone. Ventrally the second, third, fourth, and fifth branchial arches give origin to a cartilaginous hyoid bone and to some of the cartilages of the larynx.

Ossification begins during the second month in man. The skeleton of the head at this period, with the exception of the chondrocranium described above, is composed of membranous tissue. Ossification takes place in part directly in the membranous tissue of the skull, in part in the chondrocranium.

Most of the individual bones of the human skull arise from two or more centres of ossification, and many of them are partly membranous, partly cartilaginous in origin. Neither the centres of ossification nor the bones developed from them correspond very perfectly with the centres of chondrification from which the chondrocranium arises.

The chondrocranium is mainly, but not completely, replaced by bone. The cartilages of the septum and alæ of the nose, and the fibrocartilago basalis, for instance, represent remnants of the chondrocranium. Parts of the primitive cartilaginous skeleton are converted into fibrous tissue instead of into bone. The stylohyoid ligament is an example of this.

Gaupp has shown that the cavum cranii of mammals is not quite homologous with that of reptiles. On each side there lies a space, the cavum epitericum, above the ala temporalis, which in reptiles is outside of and in mammals forms a part of the cranial cavity (Mead, 1909, Voit, 1909).

We may now consider the more important stages in the development of the skull in somewhat greater detail.

BLASTEMAL PERIOD.

At the end of the second week of intra-uterine development the chorda dorsalis extends to the dorsal margin of the buccopharyngeal membrane (Fig. 229). On each side of it mesenchyme fills in the space between the brain, pharynx, and ectoderm. As the head develops the mesenchyme increases in amount. It extends dorsally and apicalward so as to surround completely the brain and its appendages. When the flexures of the brain appear, mesenchyme extends into the fissures between the various segments of the neural tube. An especially large fold of mesenchyme Mittelhirnpolster) is formed beneath the midbrain flexure (Fig. 266). The chorda dorsalis for a time remains attached to the ectoderm of the caudal wall of the hypophyseal pocket, then loses this connection and terminates free in the tissue immediately behind the hypophysis beneath the midbrain flexure.

Toward the end of the fourth week the post-otic portion of the axial region of the skull becomes marked by a condensation of mesenchyme. This condensed tissue or "occipital plate" is not sharply outlined. It consists of a blastemal central portion with two lateral processes on each side, a caudal rod-like "neural" process and a flat apical process (see Fig. 231). Between these two processes run the roots of the hypoglossal nerve. The chorda dorsalis, surrounded by a perichordal sheath, lies in the sagittal axis of the plate. At this period it may still be united to the epithelium of the pharyngeal vault.

It has been previously pointed out that the post-otic axial region of the mammalian head may be considered to be composed of at least three segments comparable to the spinal segments. This segmentation is best marked by the myotomes which develop in the lateral portions of these segments. That part of the occipital plate which lies in the most distal of the segments resembles in some respects a spinal sclerotome (see p. 334).

The apical end of the occipital plate extends into a thin layer of dense tissue which surrounds the dorsal portion of the pharynx. The chorda dorsalis extends forward in this tissue nearly to the hypophysis. The tissue in which the chorda runs becomes much thicker near the hypophysis than where it lies opposite the otic labyrinth. The latter is surrounded by a layer of condensed tissue connected for a short distance with the retropharyngeal tissue.

The mesenchyme in the visceral region of the head is much condensed, but as yet no skeletal structures are definitely outlined.

The chorda dorsalis is composed of densely packed cells surrounded by a very faint sheath. Outside of the chordal sheath there is a well-marked layer of mesenchyme cells or perichordal membrane. In the region of the spine and of the occipital plate a space is seen between the chordal sheath and the perichordal membrane. This space is not seen apical to the occipital plate.

During the early part of the second month the membranous anlage of the skull becomes extensively developed.

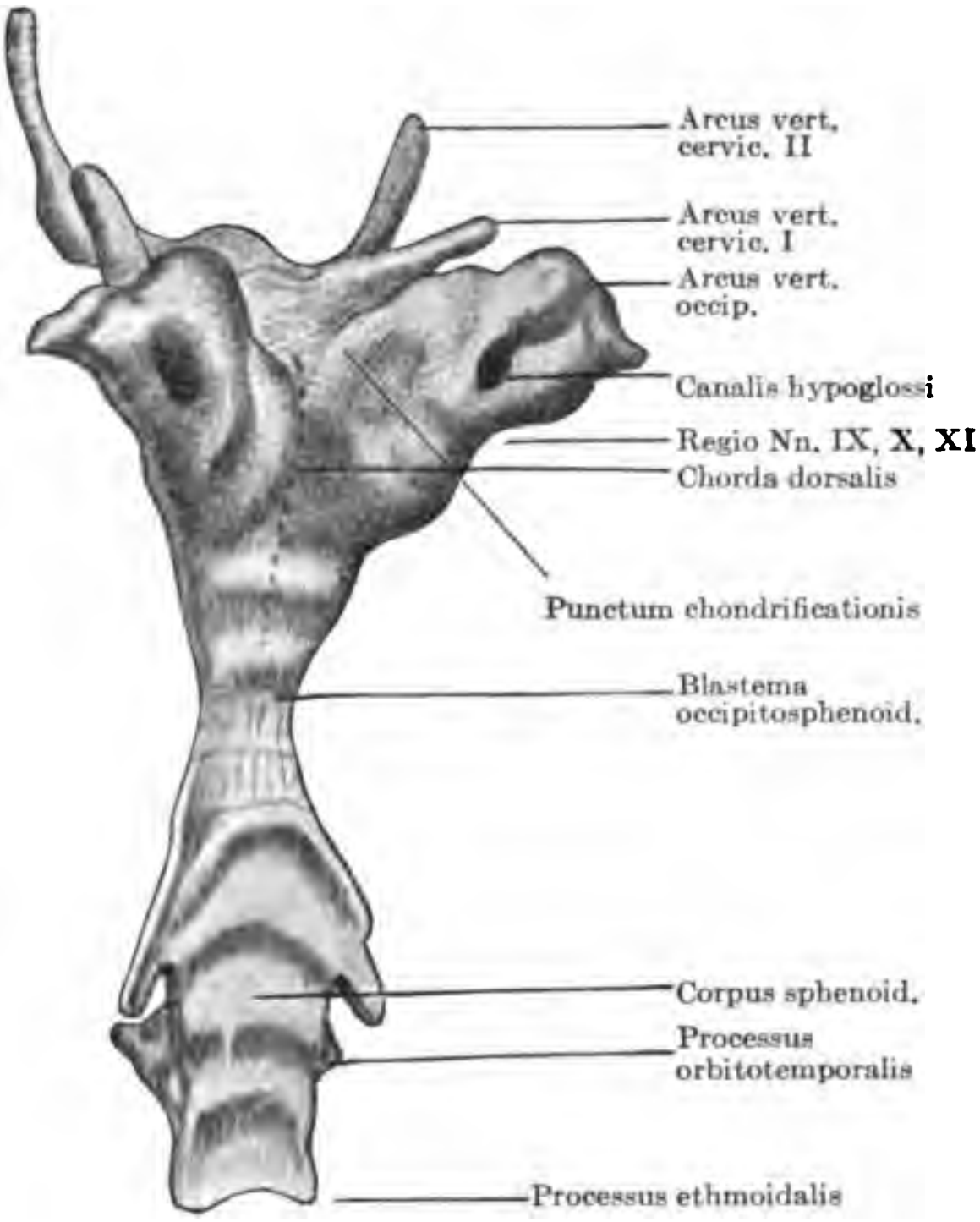

Fig. 308.—(After G. Levi, Arch. f. mikr. Anat. u. Entwicklungsgeschichte, 1900, vol. lv, Fig. 1.) Membranous skull of an embryo 13 mm. long.

The anterior and posterior lateral processes of the occipital plate become united lateral to the hypoglossal nerve, so that the hypoglossal foramen is completed and the membranous pars lateralis of the occipital is formed. This pars lateralis is continued into the membranous vault of the skull, the origin of which is described below.

The condensed tissue of the post-hypophyseal region increases in amount and extends about the hypophyseal pocket into the region apical from this, thus completing the anlage of the body of the sphenoid (Fig. 308). This gives rise to orbitotemporal and ethmoidal processes.

The orbitotemporal process is first marked by a mass of dense mesenchyme which extends ventrolaterally toward the ectoderm caudal to the optic cup. It is connected with dense tissue which surrounds the anlage of the orbit and with the anlages of the membranous floor and vault of the skull. In it are developed the orbital and temporal wings of the sphenoid, the origin of which will be described in connection with the chondrocranium. The ethmoidal process extends anteriorly in the median line from the anlage of the body of the sphenoid into the region between the nasal fossæ. It forms the anlage of the nasal septum and gives rise to parts of the membranous floor of the cranial cavity and the roof of the mouth (Fig. 310).

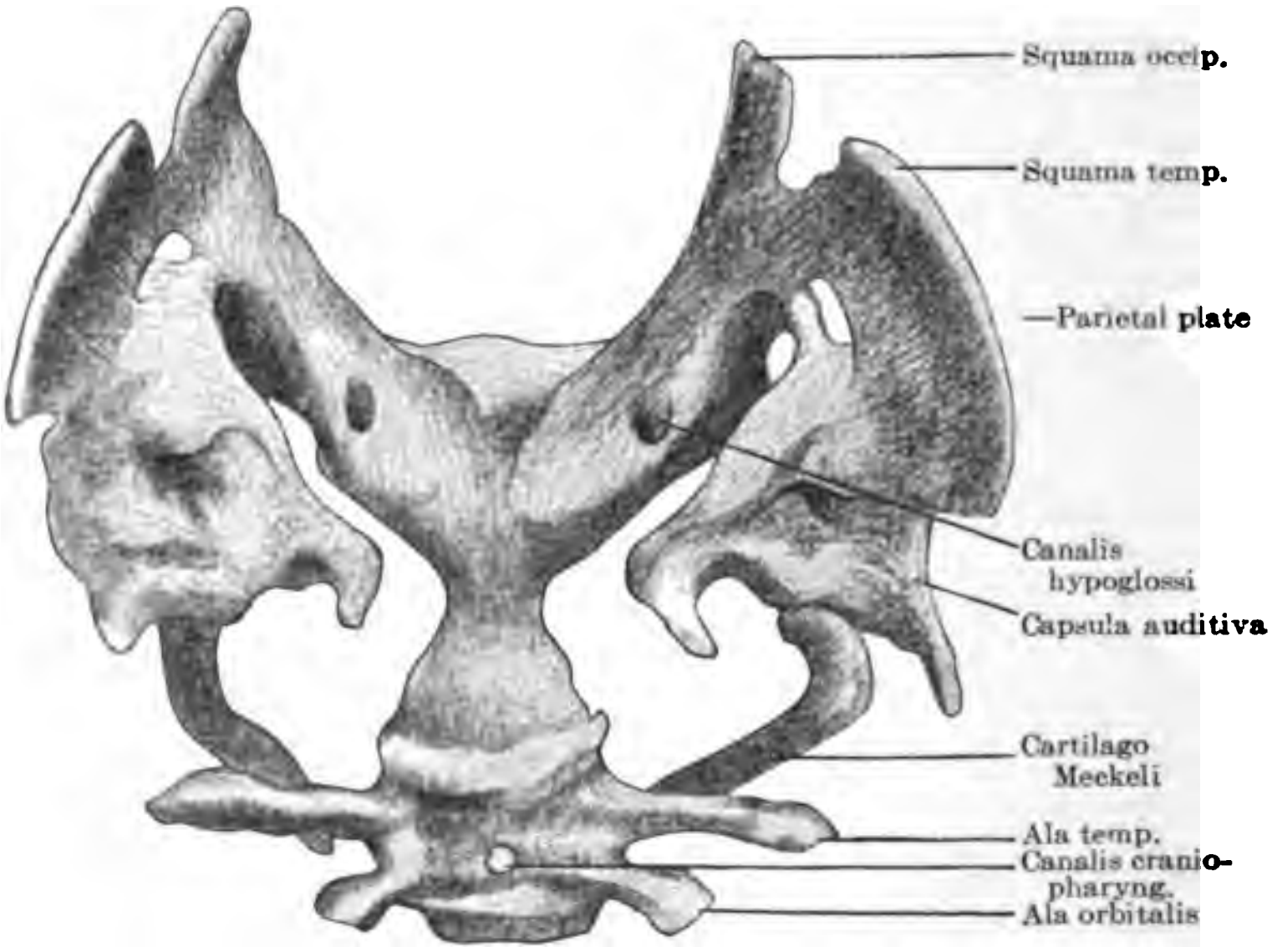

Fig. 309.—(After G. Levi, Arch. f. mikr. Anat. u. Entwicklungsg., 1900, vol. lv, Fig. 2.) Skull of an embryo 14 mm. long.

The tissue of the capsules of the labyrinth increases in amount as the labyrinth becomes differentiated. The tissue which encloses the region of the semicircular canals and the vestibule forms an oval mass the outlines of which do not conform to that of the enclosed canals (Fig. 309). This tissue is less dense than most parts of the membranous skeleton of the head and at an early period becomes transformed into embryonic cartilage (see p. 407). The cochlear portion of the labyrinth (Fig. 310) is enclosed by a dense mesenchyme which becomes converted into cartilage at a later period.

Lateral from the nasal fossa the tissue becomes generally somewhat condensed, though less so than the tissue in the septum. In the perinasal tissue condensation gradually marks out the lateral and ventral portions of the nasal capsule and the membranous floor of the ethmoidal and orbital portions of the cranial cavity (Fig. 310). From the lateral wall membranous processes project into the nasal fossa. These are the anlages of the conchæ.

The floor of the cranial cavity at this period is formed posteriorly by the occipital plate with its lateral processes and by the capsule of the labyrinth. Between the two is a fissure for the passage of the glossopharyngeus, vagus, and spinal accessory nerves and the jugular vein (Fig. 309). Apically the floor is formed by a thin sheet of condensed tissue, which is slightly marked over the ethmoidal region where the olfactory nerve passes through it and is better marked on the anterior medial portion of the roof of the orbit. This portion is connected caudally with the orbital wing of the sphenoid (Fig. 310).

Between the orbital region and the capsule of the labyrinth, in the vicinity of the Gasserian ganglion, the floor of the cranial cavity is incomplete. More medially the floor of the cranial cavity is formed by two membranes, one of which arises from the anterior margin of the auditory capsule and the neighboring part of the body of the sphenoid, and the other from the posterior margin of the orbital wing of the sphenoid. These two membranes extend upwards into the midbrain fold, fuse, and furnish a short central skeletal support for the mesenchyme in this fold (Fig. 266). They enclose the lateral process of Rathke's pocket. They form no part of the definitive skeleton.

The roof of the cranial cavity is formed by a dense membranous layer which first becomes marked at the side of the head in embryos 9–11 mm. in length. At this stage there is a plate of dense tissue formed between the caudolateral margin of the orbit and the caudal lateral process of the occipital plate. It lies lateral to the Gasserian ganglion and the capsule of the labyrinth, with the latter of which it comes in contact. Below it is connected with the orbitotemporal process and the dense tissue of the region of the branchial clefts.

This membrane gradually extends so that it forms a complete membranous vault. Ventrally it is continuous with the ventrolateral margin of the membranous covering of the ethmoidal and orbital portions of the floor of the cranial cavity. Laterally it becomes connected with the temporal wing of the sphenoid, the auditory capsule, and the lateral part of the occipital. Caudally it is continued into the much thinner membrana reuniens dorsalis of the spinal canal.

During the period under consideration the brain only partially fills the cranial cavity. A large amount of loose mesenchyme intervenes between the brain and the floor and vault of the cranial cavity. This tissue is especially abundant in the region of the flexures of the brain and about the hemispheres (Fig. 266). In it the falx cerebri and other membranous supports of the brain are developed. During the latter part of the second month an extensive plexus of vessels develops on the cerebral side of the membranous vault.

The anlages of the alveolar borders of the upper and lower jaws become marked by condensation of tissue along the upper and lower margins of the entrance into the oral cavity. This condensed tissue at first forms a flat plate, but later sends processes in an aboral direction.

Chondrogenous Period.

A large amount of study has been devoted to the development of the chondrocranium or primordial cranium in the different vertebrates. An excellent summary of the chief literature on the subject is given by Gaupp (1906). The chief work on the development of the human chondrocranium has been done by Dursy, Spoendli, Hannover, Froriep, v. Noorden, Jacoby, O. Hertwig, and Levi.

The development of the chondrocranium in man begins early in the second month. Its relatively most complete differentiation is reached toward the end of the third month, although some parts of it undergo a still greater elaboration before conversion into bone.

At the end of the third month (see Figs. 312 and 313) the caudal half of the chondrocranium forms a ring of cartilage about the posterior portion of the brain. The thick ventral portion of this ring comprises medially the basilar portion of the occipital and laterally the capsule of the labyrinth and the partes laterales of the occipital. The dorsal portion of the ring is composed of a thin plate of cartilage, the tectum posterius, the only part of the cranial vault which becomes cartilaginous in man. In the partes laterales of the occipital the hypoglossal foramina may be seen. The processes which bound them anteriorly serve as the posterior boundaries of the jugular foramina.

The caudal portion of the chondrocranium is united to the apical portion by the relatively slender body of the sphenoid. At the junction between the two is a large dorsum sellæ.

The apical portion from above appears somewhat quadrangular. The caudal angle of the quadrangle forms the body of the sphenoid; the apical angle, the ventral end of the nasal capsule; and the lateral angles, the tips of the alæ orbitales of the sphenoid. In the mid-line a well-developed nasal septum extends forward from the body of the sphenoid. Seen from the side (Fig. 312) the dorsal surface of the body of the sphenoid and the dorsal and anterior margins of the nasal septum form three sides of a hemihexagon. At the junction of the dorsal and anterior margins of the nasal septum there is a prominent crista galli.

From the body of the sphenoid the temporal and orbital wings project laterally. On each side of the dorsal margin of the nasal septum there may be seen a quadrangular cribriform plate, the lateral margins of which are united to the ala orbitalis by plates of cartilage (cartilagines spheno-ethmoidales) which extend over the orbit. There is also a plate of cartilage which extends to the ala orbitalis from the dorsal surface of the axial region of the chondrocranium near the junction of the sphenoidal and ethmoidal regions.

The nasal fossæ are bounded laterally by a plate of cartilage which is united posteriorly to the anterior extremity of the body of the sphenoid, dorsally to the lateral edge of the cribriform plate, and anteriorly to the nasal septum. The inferior margin of this lateral plate curves inwards, but does not extend to the nasal septum. The inferior surface of the nasal fossa thus is not closed off by cartilage. Anteriorly, however, the inferior aperture is rendered very narrow by a paraseptal cartilage (see p. 413). From the lateral nasal cartilage there arises a short process which encircles a part of the nasolachrymal duct (processus paranasalis).

The orbit is bounded above by the orbital wing of the sphenoid and the processes attached to this; posteriorly by the lateral extremity of the ala temporalis, much of which has already become ossified; and medially by the lateral nasal cartilage. The floor and the lateral part of the roof of the orbit are formed of membrane bone. At this period the parietal, frontal, nasal, and lachrymal bones, the maxilla, the zygomaticum and the squama temporalis, the tympanicum, the laminæ mediales of the pterygoid process of the sphenoid, the vomer, and the palatine bones are beginning to become ossified as membrane bones (see Fig. 321).

Those portions of the skeleton of the head derived from the visceral arches are shown in Figs. 311, 312, and 314. From the mandibular arch are derived Meckel's cartilage, the malleus, and the incus. The malleus and incus have nearly their definitive form, although relatively far greater in size than in the adult skull. Meckel's cartilage, which is continued from the capitulum of the malleus into the mandible, is a temporary structure which disappears at a later period. It is at this time flanked by a mandible formed of membrane bone.

The stapes, which at this period has its characteristic form, and the styloid process of the temporal bone are derived from the second branchial arch. The cartilaginous hyoid bone and the chief laryngeal cartilages are clearly outlined, although the hyoid bone is not thus represented in the model. These cartilages are derived from the second, third, fourth, and fifth branchial arches.

The skeleton of the rudimentary head of amphioxus is composed of the chorda dorsalis, membranous tissue, and a few scattered structures, cartilaginous in character. The cyclostomes have a rather complicated chondrocranium, the roof of which is formed of membrane except for a slender tectum synoticum. The occipital region is missing and the cranium terminates caudally in the labyrinth region. In selachians the cranial cavity of the cartilaginous skull has a complete roof, side walls, and floor, but is open in front and behind (f. magnum). In the vertebrates above the selachians a chondrocranium is formed during embryonic development, but the degree of its elaboration and the extent to which it is retained in the adult skull vary greatly in the different classes of vertebrates. In the higher vertebrates the chondrocranium is largely replaced by bone, partly of the investment (membranous), partly of the substitution (cartilaginous) type. In man the chondrocranium is relatively slightly developed and the investment bones are relatively extensive.

Having considered briefly the cartilaginous skeleton of the head at the height of its development, we may now take up in more detail the development of its component parts.

OCCIPITAL REGION, THE CAPSULE OF THE LABYRINTH, AND THE TECTUM POSTERIUS.

Base and Partes Laterales of the Occipital.—A brief description of the development of the posterior part of the occipital has already been given in connection with the description of the cervical vertebræ. Early in the second month a centre of chondrification appears in the posterior part of the blastemal anlage of the occipital on each side of the median line (Fig. 308). Apparently a separate centre arises in the caudolateral (neural) process, but this very quickly fuses with the main parachordal centre, and it is possible that it is not always present. Each parachordal cartilage extends forward at the side of the chorda dorsalis until the region is reached where the chorda dorsalis enters the dense retropharyngeal mesenchyme. Here the two parachordal plates fuse dorsal to the chorda into a single median plate which extends forward to the sphenoidal region (Fig. 266). At first the parachordal cartilages are separated from one another posteriorly by dense tissue (Fig. 266) and the median plate is similarly separated from the sphenoidal cartilage. Before the end of the second month, however, the posterior extremities of the parachordal cartilages become united ventral to the chorda and the median occipital plate becomes fused to the sphenoidal cartilage, at first laterally and then in the sagittal plane. The chorda dorsalis at this period runs in dense tissue in a dorsal groove in the occipital cartilage, then through this cartilage into the retropharyngeal tissue, thence dorsalwards in the line of suture between the occipital plate and the sphenoidal cartilage and terminates dorsal to the sphenoid cartilage (Fig. 266).

Laterally a cartilaginous process extends out in the blastema on each side of the hypoglossal nerve. The process caudal to this nerve, as above mentioned, apparently, at times at least, has a separate centre of chondrification, like the neural process of a spinal vertebra, but this becomes much more quickly fused with the body than does the latter. The apical lateral cartilaginous process is formed considerably later than the caudal.

The hypoglossal foramen is at first completed by blastemal tissue. In this tissue ventrolateral to the foramen there appears a separate centre of chondrification. The cartilage arising here soon becomes fused to the processes extending out from the median plate on each side of the hypoglossal nerve, thus completing the cartilaginous boundary of the foramen and the pars lateralis of the occipital cartilage. From it there extends in an apico-ventral direction, lateral to the jugular foramen, a prominent jugular process. The condyloid process is developed on the caudal side of the posterior lateral process of the occipital (Fig. 264, p. 344).

Chorda Dorsalis.—The suboccipital portion of the chorda dorsalis becomes more and more irregular in form during the third month. Small processes are given off, some of which become separated from the chorda. In this region the chorda remains longest united to the pharyngeal epithelium. Some processes of the chorda are found, even in the second month, connected with processes of the pharyngeal epithelium. The connections are probably partly primary and partly secondary (Fig. 266). In the fourth month the chorda usually becomes discontinuous in places. After this it is gradually absorbed. During the chondrification of the basioccipital the chorda tissue is pressed back between the dorsal side of the occipital plate and the tip of the dens epistrophei. Chordomata may arise here.

The Labyrinth.—While the semicircular canals are being differentiated the mass of tissue in which they are embedded becomes somewhat loose in texture and gradually from without medialwards becomes transformed into a peculiar kind of precartilage, the cells of which long remain nearer to one another than in most cartilage (Fig. 310). The cochlear portion of the capsule becomes chondrified much later than the capsule of the canalicular part. The semicircular canals are lined by epithelium which abuts directly against the surrounding cartilage. The fibrous coat of the labyrinth is gradually differentiated from the cartilage. The oval and round foramens become distinct during the period of chondrification, because the tissue which covers them remains membranous while the surrounding tissue is converted into cartilage.

The capsule of the labyrinth is at first incomplete (Fig. 310). At the end of the second month the geniculate ganglion and the facial nerve lie in a slight groove on the vestibular portion of the capsule (Fig. 310), while the cochlear and vestibular ganglia extend into the large dorsal fissure between the canalicular and cochlear portions of the capsule. As development proceeds the anterolateral extremity of the dorsal edge of the cochlear portion of the capsule extends in a dorsolateral direction so as to cover the two auditory ganglia. At the same time the groove containing the geniculate ganglion and the neighboring portion of the facial nerve becomes converted into a canal (Fig. 313). The saccus endolymphaticus is not included in the otic capsule (Fig. 310). Lateral from the foramen endolymphaticum, in which the ductus endolymphaticus is enclosed, lies the fossa subarcuata (Fig. 313).

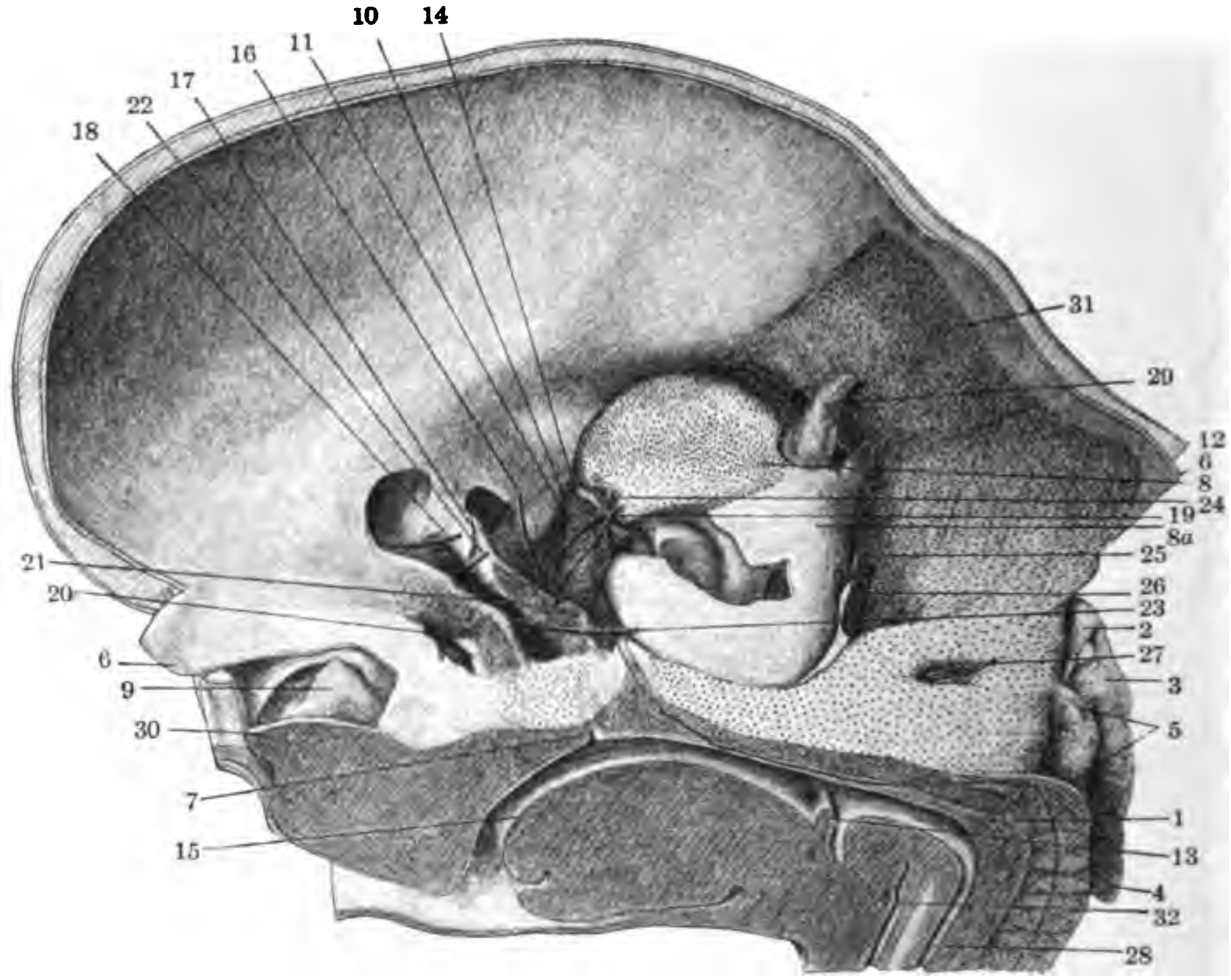

Fig. 310.—Model of the right half of the skull of an embryo 20 mm. long. The model is viewed from above and the medial side. The courses of some of the nerves are indicated. 1, arcus anterior; 2, hemiarch of the first cervical vertebra; 3, hemiarch of the second cervical vertebra; 4, hemiarch of the first thoracic vertebra; 5, blastema between the first two vertebræ and the skull; the intermediate portion has been removed so as to expose the arch of the epistropheus; 6, calvaria membranacea—membranous cranial vault; 7, canalis craniopharyngeus in corpus sphenoidale; 8, capsula auditiva (pars canalicularis; 8a, pars cochlearis); 9, capsula nasalis; 10, cartilago Meckeli; 11, chorda tympani; 12, ectoderm; 13, epiglottis; 14, incus; 15, lingua; 16, nervus mandibularis; 17, nervus maxillaris passing through the ala temporalis; 18, nervus ophthalmicus; 19, nervus petrosus superfic. major, near the geniculate ganglion; 20, course of optic nerve through optic foramen; 21, course of the oculomotor nerve as it passes beneath the ala orbitalis of the sphenoid; 22, course of the trochlear nerve as it passes beneath the ala orbitalis of the sphenoid; 23, nervus abducens; 24, course of the facial nerve between incus and auditory capsule; 25, course of the glossopharyngeal nerve; 26, course of vagus and spinal accessory nerves; 27, course of the hypoglossal nerve; 28, œsophagus; 29, saccus endolymphaticus; 30, septum nasi; 31, tectum posterius; 32, trachea.

In the human chondrocranium it is not deep. In the petrosa of children of from 2 to 10 years of age it is much deeper; in adults it again becomes shallow (Mead).

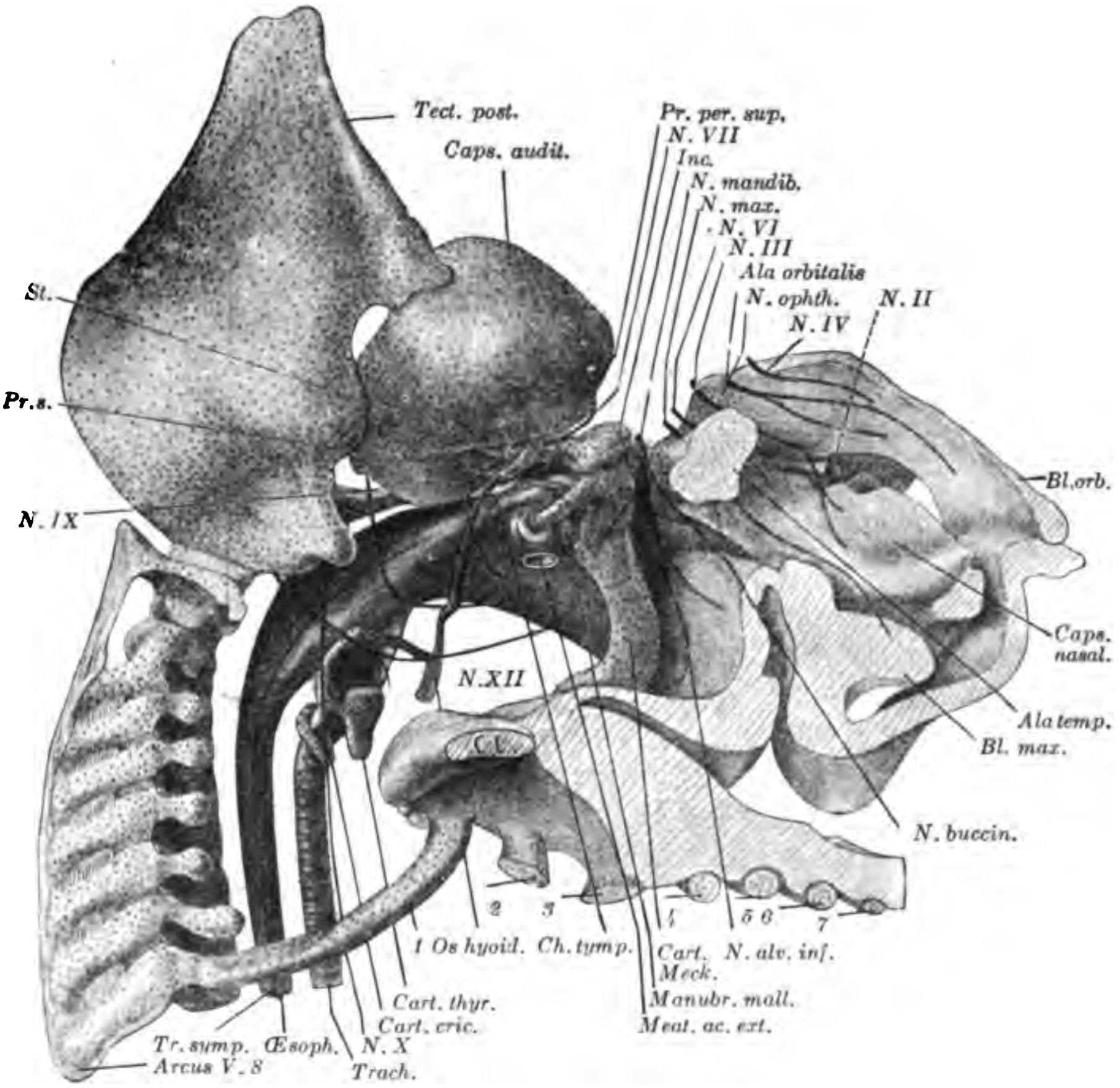

FIG. 311.—Lateral view of a model of the skull of an embryo 20 mm. long. The courses of some of the nerves are indicated. *Ala orbitalis*, ala orbitalis; *Ala temp.*, ala temporalis; *Arcus V.* 8, arch of first thoracic vertebra; *Bl. orb.*, blastema orbitale; *Bl. max.*, blastema maxillare; *Caps. audit.*, capsula auditiva, pars canalic.; *Caps. nasal.*, capsula nasalis; *Cart. cric.*, cartilago cricoidea; *Cart. Meck.*, cartilago Meckeli, crossed in front by the auriculotemporal nerve, behind by the lingual nerve; *Cart. thyr.*, cartilago thyreoidea; *Ch. tymp.*, chorda tympani; *C.* 1–7, costæ I–VII; *Inc.*, incus; *Manubr. mall.*, manubrium mallei; at the tip of the manubrium a part of the dense tissue which encases the whole manubrium is shown; medial to this the cavum tubotympanale may be seen; *Meat. ac. ext.*, meatus acusticus externus; *N. alv. inf.*, nervus alveolaris inferior; *N. buccin.*, nervus buccinatorius; *N. mandib.*, nervus mandibularis; *N. max.*, nervus maxillaris, under cover of the ala temporalis gives off sphenopalatine nerves; *N. ophth.*, course of the ophthalmic nerve; *N. II*, course of the optic nerve; *N. III*, course of the oculomotor nerve; *N. IV*, course of the trochlear nerve; *N. VI*, course of the abducens nerve; *N. VII*, course of the facial nerve; *N. IX*, course of the glossopharyngeal nerve; *N. X*, course of the vagus nerve; *N. XII*, course of the hypoglossal nerve; *Œsoph.*, œsophagus; *Os. hyoid.*, os hyoideum; beneath this, the clavicle; *Pr. per. sup.*, processus perioticus superior; *Pr. s.*, processus styloideus; *St.*, stapes; *Tect. post.*, tectum posterius; *Trach.*, trachea; *Tr. symp.*, course of the truncus sympathicus.

From the capsule of the labyrinth above the ossicles a process grows forward (P. perioticus superior Gradenigo) (Figs. 311, 312, 313). Ventrally this extends into a plate composed of fibrous connective tissue. This plate is connected with the pars cochlearis.

The tegmen tympani is formed from the cartilaginous process and the accompanying fibrous plate. The cartilaginous process is well shown in Fig. 313.

Into the finer details of the development of the skeleton of the internal ear we cannot here enter.

The cochlear portion of the capsule of the labyrinth is long connected by a fairly dense mesenchyme with the median plate of the occipital. After the chondrification of this portion of the capsule it becomes fused to the cartilage of the median plate, forming with it a continuous cartilaginous structure (Fig. 313). Across the jugular foramen somewhat irregular bars of cartilage may be formed (Fig. 313, right side).

In vertebrates below birds and mammals the auditory capsules lie in the lateral wall rather than in the floor of the cranial cavity. In man the basal position of the auditory capsules is more marked than in any of the lower mammals.

Tectum Posterius.—The cranial vault, as previously pointed out, is formed at first by a thin dense layer of membranous tissue, which is closely applied to the lateral side of the capsule of the labyrinth and extends ventrally into the dense tissue of the branchial region. Posteriorly and inferiorly it is attached to the pars lateralis of the occipital. This membrane at first completes the f. jugulare. In the sixth week cartilage begins to extend into it from the posterior lateral (neural) process of the occipital. This cartilage extends as a flat band rapidly in an anterior direction in the membranous vault. In a 14 mm. embryo it has extended anteriorly above the otic region, but lies at some distance from the dorsolateral margin of the otic capsule. Soon after this it extends in a ventral direction so as to be closely applied to the otic capsule posteriorly and dorsally (Fig. 311), but even toward the end of the second month it is still distinctly separated from this by a narrow band of membranous tissue. Later the two become fused (Fig. 313). Between the capsule and the margin of the cartilaginous vault there are several apertures for the passage of blood-vessels.

During the third month the vault cartilages of each side extend dorsally and become united so as to complete a flat bridge of cartilage between the right and left occipitotemporal regions. This bridge of cartilage is called the tectum posterius or synoticum.

The description here given of the development of the tectum posterius differs in several respects from those of Levi, Bolk, and some other investigators. It is based on a study of several embryos between 11 and 20 mm. in length which the writer has had at his disposal. Possibly there are individual variations in the mode of the development of the tectum.

Levi describes a squama occipitalis which arises from a separate centre of chondrification, fuses with the pars lateralis of the occipital, and extends in an anterodorsal direction in the membranous vault; and a squama temporalis, which arises from a separate centre, fuses with the auditory capsule, and extends dorsally into the membranous vault (Fig. 309). The squama occipitalis and squama temporalis become fused and the temporal squama greatly reduced at the expense of the occipital squama. The occipital squamæ fuse to form the tectum posterius. According to Bolk, there is first formed a cartilaginous band, anterior interotic band, between the auditory capsules or the parietal plates applied to these. The posterior margin of this band extends into the membrana spinoso-occipitalis, which is attached laterally to the ear capsules and to the partes laterales of the occipital and posteriorly extends into the membrana reuniens dorsalis. Posterior to the interotic band of cartilage a second band is formed by outgrowth of cartilage from the partes laterales of the occipital and the caudal part of the otic capsule. This latter cartilaginous band is separated from the former by a membranous interval in which temporarily a pair of cartilages appear. There also appears in front of the anterior interotic band a temporary centre of chondrification. In the lower mammals there has frequently been described a cartilaginous lamina parietalis lying above the auditory capsule and united to the commissura orbito-parietalis.

ORBITOTEMPORAL REGION.

In man the cartilage of the orbitotemporal region forms the basis for the ossification of the body, of the orbital and temporal wings, and of the laminæ laterales of the processus pterygoidei of the sphenoid. These parts have special centres of chondrification which at first are separate but which fuse later.

The chondrification of the body of the sphenoid begins in the median line anterior and ventral to the apical end of the chorda dorsalis in embryos between 12 and 13 mm. long. The position of this cartilage in a 14 mm. embryo is shown in Fig. 266. From this centre an arm of cartilage (Rathke's Schädelbalken) extends forward on each side of the hypophyseal pocket. In front of this the two processes unite to form the anterior part of the body of the sphenoid.

In the lower vertebrates a pair of cartilages, trabeculæ, are formed, one on each side of the hypophysis. These cartilages usually unite with one another apically and with the occipital parachordal cartilages caudally. It is a question whether or not these trabeculæ are homologous with the sphenoidal cartilage above described (see Gaupp, 1906, p. 826).

The caudal part of the body of the sphenoid becomes fused with the apical end of the median occipital plate and sends a process, the dorsum sellæ, upward toward the midbrain fold. The apical end of the chorda comes to lie in the cartilage at the base of the dorsum sellæ or between the cartilage and the perichondrium of the sella turcica or of the dorsum sellæ. In the cartilage the chorda soon disappears; under the perichondrium it persists longer than elsewhere in the cranium and may give rise to chordomata (Williams). The cartilaginous body of the sphenoid gradually assumes the shape characteristic of the adult bone. During the third month the fossa hypophyseos, the tuberculum sellæ, and the sulcus chiasmatis become fairly distinct (Fig. 313).

The hypophyseal canal is at first relatively large and is much broader than it is long. The tissue immediately about is very slowly converted into cartilage during the third month. Occasionally a patent canal is found in the adult bone.

The cartilaginous ala temporalis (see Fig. 310) arises in the orbitotemporal blastema some distance below the membrane which forms the floor of the cranial cavity. It is only at a much later period that the temporal wing helps to bound the cranial cavity. During the latter half of the second month two portions may be distinguished in the ala temporalis, a medial and a lateral (Figs. 309 and 310).

The medial portion (processus alaris, Hannover) lies in the plane of the body of the sphenoid. It consists at first of blastemal tissue which extends from the body of the sphenoid opposite the hypophysis laterally and then posteriorly so as partially to enclose the internal carotid artery. It has a special centre of chondrification. It approaches closely but does not fuse with the otic capsule (30 mm. fetus). A closed foramen caroticum is found in several mammals, but is transitory when present, and probably is not constant in the human embryo (Levi).

The lateral part of the ala temporalis arises in a plane ventral to the medial part. The condensed blastema of which it is at first formed becomes fused to the ventral surface of the medial part near where this turns posteriorly about the internal carotid artery. The lateral part of the ala temporalis is small where it joins the medial part, but expands rapidly as it extends laterally, anterior to the otic capsule and ventral to the cranial border of the trigeminus ganglion. It has a separate centre of chondrification. The lateral part becomes cartilaginous later than the medial but becomes ossified much sooner (Fig. 313). From the ventral surface of the medial end of the lateral portion of the ala temporalis a short process extends ventralwards. This represents the anlage of the lateral lamella of the pterygoid process.

The ganglion of the trigeminus lies at first caudal to the lateral part of the ala temporalis, and the first and second branches of this nerve as well as the motor nerves of the eye pass forward medial to this process. During the period of chondrification the second branch of the trigeminus becomes enclosed in the foramen rotundum. The third division of the trigeminus at first passes down between the ala temporalis and the otic capsule. It later becomes embedded in a groove on the posterior margin of the ala temporalis. This groove is converted into the foramen ovale before or during the period of ossification. The foramen spinosum is similarly formed about the middle meningeal artery.

The ala orbitalis is differentiated from the orbitotemporal blastema first by condensation of tissue and then by chondrification. It is larger at first than the ala temporalis. In a 14 mm. embryo a blastemal process, the tænia metoptica of Gaupp, arises from the side of the body of the sphenoid, extends up behind the optic nerve and then over this into a plate of membranous tissue which forms the roof of the orbit and the floor of the cranial cavity. A second blastemal process, tænia preoptica, extends from the side of the anterior extremity of the body of the sphenoid in front of the optic nerve laterally into the orbital plate. Chondrification (Fig. 310) appears first in the tænia metoptica in the region posterior to the optic nerve, and from here extends medialwards to fuse with the anterior part of the body of the sphenoid and lateralwards into the orbital plate (Fig. 313). The orbital plate has a separate centre of chondrification. The tænia preoptica apparently becomes chondrified through extension of cartilage into it from the body of the sphenoid. Chondrification begins later in this than in the tænia metoptica and the orbital plate. During the third month the ala orbitalis becomes fused into a single piece of cartilage and at the same time joined by bands of cartilage (cartilago spheno-ethmoidalis) to the lateral edge of the cribriform plate of the ethmoid (Fig. 313).

In many mammals the outer end of the ala orbitalis is connected with the cartilage of the cranial vault dorsal to the otic capsule (parietal plate) by a bridge of cartilage, the commissura orbitoparietalis (Gaupp). This bridge, which is lacking in man, encloses a large (sphenoparietal) foramen.

ETHMOIDAL REGION AND THE NASAL CAPSULE.

The ethmoidal region and the nasal capsule are the last portions of the chondrocranium to become cartilaginous. In an embryo 20 mm. long and in the eighth week of development (Figs. 310 and 311) the tissue is still membranous, although both the nasal septum and the lateral wall of the nasal capsule are evidently in a precartilaginous stage. In the third month the cartilaginous capsule is extensively developed (Figs. 312 and 313).

The chondrification of the septum apparently takes place by anterior extension from the cartilage of the ventral part of the body of the sphenoid. The septum is at first relatively thick, especially on the ventral margin. From the anterior part of this thickened ventral margin of the septum a "paraseptal" cartilage becomes isolated on each side (third month).

In many of the lower mammals the anterior part of the ventral margin of the septum becomes joined to the lateral wall by a band of cartilage, the lamina transversalis anterior, thus separating the "fossa narina" from the "fenestra basilaris." The paraseptal cartilage in these mammals extends from the posterior margin of the lamina transversalis anterior into the fenestra basilaris. In man the lamina is not developed, so that a long fissura rostroventralis is present in the nasal capsule. The paraseptal cartilage primitively in mammals, but not in the reptiles, forms a sheath for Jacobson's organ, but in man it has lost this function. It, however, persists until after birth (E. Schmidt).

According to Mihalkovics, several isolated pieces of cartilage found in the third month lateral to the inferior margin of the nasal septum may indicate rudiments of the L. transversalis anterior.

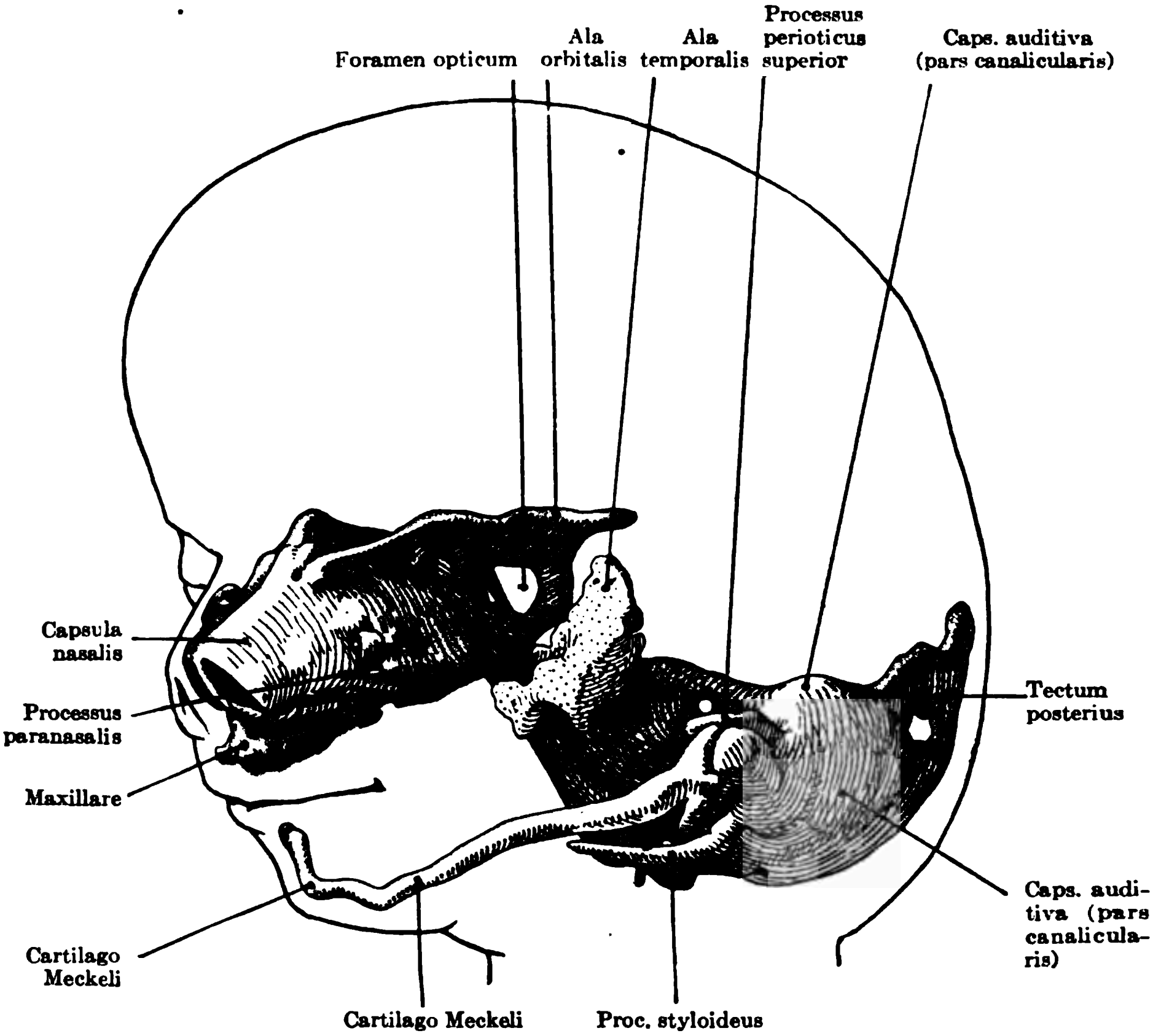

FIG. 312.—(After Hertwig's model, from Kollmann, Handatlas, 1907, Fig. 262.) Primordial cranium of a human fetus at end of the third month (8 cm. long).

Posteriorly the cartilage of the nasal septum is much narrower than it is anteriorly. It does not extend into the blastemal septum between the nasopharyngeal passages.

The chondrification of the lateral walls (C. paranasalis) of the nasal fossæ seems to take place independently, but the lateral cartilage is soon joined to the nasal septum, anteriorly forming the cartilaginous roof and sides of the nose, tectum nasi, and paries nasi, and somewhat later it is posteriorly united to the region where the sphenoidal cartilage passes over into the cartilage of the septum. Through infolding of its inferior margin the lateral wall of the nasal fossa posterior to the narina nasi furnishes the anlage of the maxillary turbinate, concha inferior. This is at first simple in form though later more complicated. Late in the third month it develops an accessory process curved upwards, and in the fifth month exhibits extensive folds (Mihalkovics). It becomes separated from the lateral wall when the latter undergoes retrograde metamorphosis (seventh month, Killian).

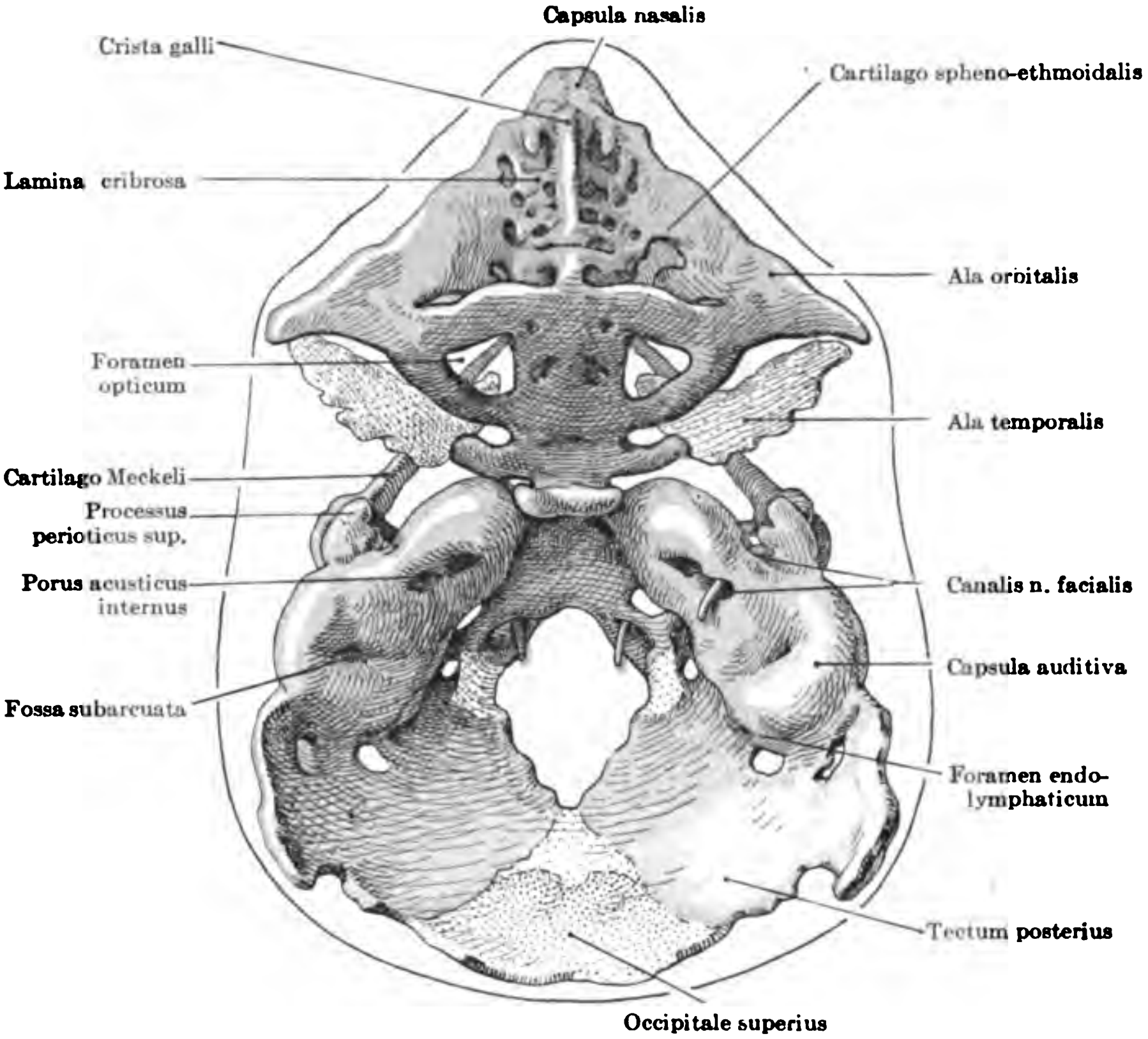

FIG. 313.—(After Hertwig's model from Kollmann, Handatlas, 1907, Fig. 264.) Primordial cranium of a human fetus at end of third month.

During the blastemal period folds in the surrounding mesenchyme project into the nasal fossa. On the posterior dorsal part of the lateral wall there is formed a fold of tissue which, according to Peter (1902), may be looked upon as having been derived from the caudodorsal part of the median wall. This fold gives rise to the anlage of the middle turbinate, concha media. The anlage of the superior turbinate arises in a manner similar to the middle. Following this there are formed much later the anlages of three more turbinate processes. Thus there are five chief ethmoidoturbinate processes in addition to the maxilloturbinate already described. Apicalwards, between the concha media and the concha inferior, there appears a rudimentary nasoturbinate which gives rise to the agger nasi and the uncinate process. (See Killian, 1895, 1896; Peter, 1902.)

Besides the chief turbinates there are numerous accessory turbinates. The bulla ethmoidalis arises from accessory processes in the meatus beneath the middle turbinate. The complicated changes which take place in the nasal turbinates cannot be entered upon in detail in this section.[20]

Chondrification of the ethmoidal turbinates, of the uncinate process, and of the bulla ethmoidalis begins in the fourth month.

The cartilaginous capsule of the nose at first is open toward the olfactory bulb, but during the third month the cribriform plate is formed by chondrification of tissue between various nerve bundles (Fig. 313). The lamina cribrosa is characteristic of mammals, but is not present in all.

In most of the lower mammals the caudal margin and the caudal part of the inferior margin of the lateral wall of the nasal capsule bend towards the nasal septum and then forwards so as to bound a cupola-shaped recess (the sinus terminalis) at the caudodorsal extremity of the nasal fossa. In man this recess, the anlage of the sinus sphenoidalis of the osseous cranium, is not much developed and has no ventral cartilaginous wall. A membranous septum is, however, formed between the meatus nasopharyngeus and the cupola-shaped recess. The septum becomes ossified, forming the floor of the sphenoidal sinus. The paranasal cartilage bounds the recess laterally, but does not bound the meatus nasopharyngeus. The latter becomes bounded laterally by a membrane bone (os pterygoideum).

In the third to fourth month a short cartilaginous process (proc. paranasalis) arises from the lateral wall of the nasal capsule and encircles the lachrymal duct.

The fate of the cartilaginous nasal capsule is varied. Parts become ossified, parts are converted into connective tissue or disappear, and parts pass over into the cartilaginous portion of the skeleton of the adult nose. The greater part of the posterior portion of the capsule becomes ossified as the ethmoid bone. The dome-shaped wall of the sinus terminalis gives the basis for the concha sphenoidale (ossiculum Bertini). The maxilloturbinate (concha inferior) and a part of the nasal septum likewise become ossified. Parts of the septum and of the inferior portion of the lateral wall above the maxilloturbinate, however, disappear and are replaced by parts of the neighboring membrane bones. The cart. paraseptalis remains till after birth. A large part of the septum and parts of the roof of the nose remain cartilaginous throughout life. The C. alares majores become separated by

---

[20] See the description of the development of the nose in the section on the organs of special sense.

development of connective tissue from the rest of the nasal capsule during the fourth to fifth month of intra-uterine life. The C. alares minores and the C. sesamoidiæ are differentiated from the C. alares majores. The cartilago spheno-ethmoidalis, the orbital wing of the cartilaginous ethmoid, which during the third month extends as a broad plate between the lateral margin of the lamina cribrosa of the ethmoid and the ala orbitalis of the sphenoid (Fig. 313), in the fourth to fifth month is broken up into several pieces and absorbed.

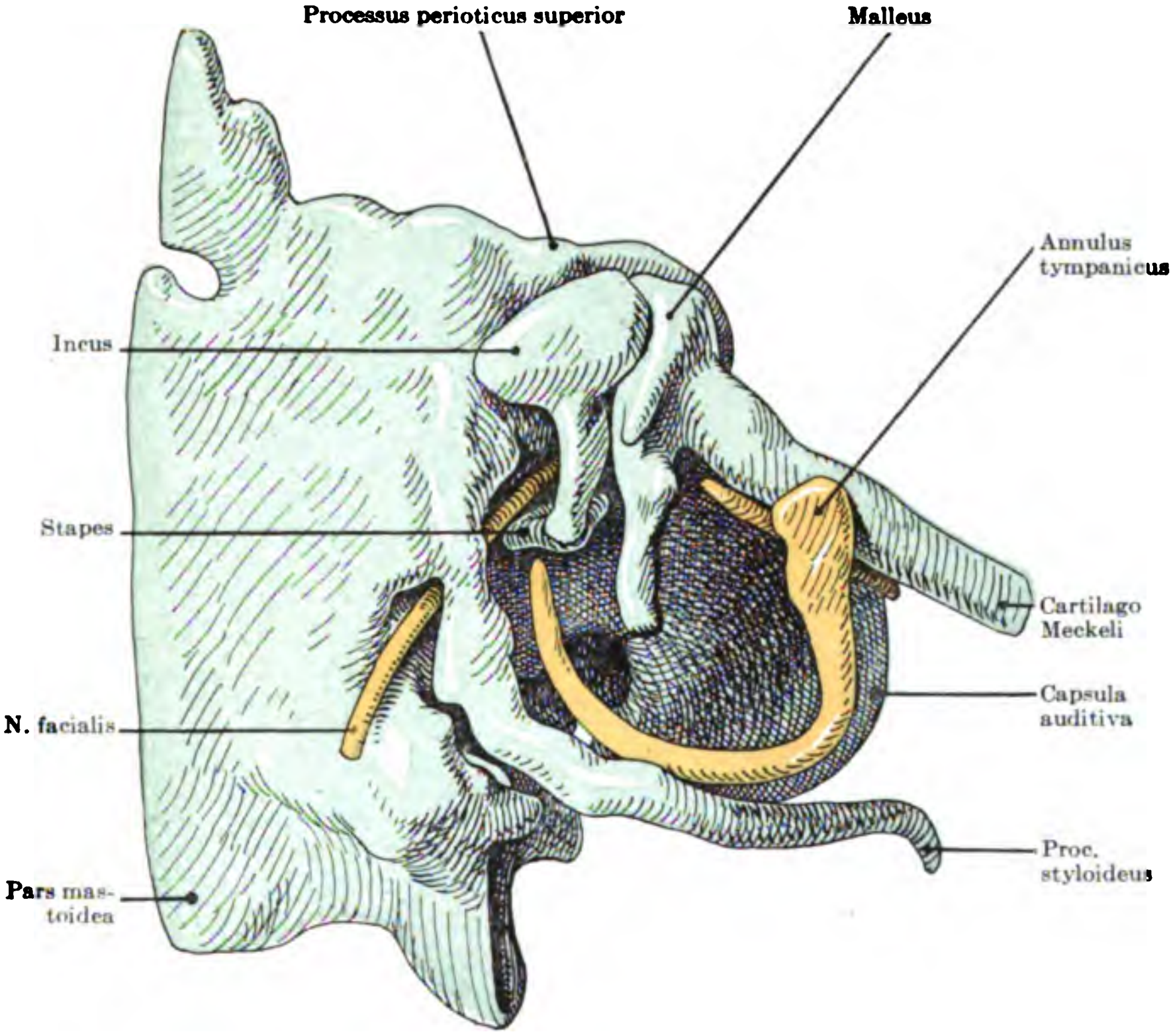

Fig. 314.—(After Hertwig's model, from Kollmann, Handatlas, 1907, Fig. 266.) Visceral skeleton of the labyrinth region of a human fetus 8 cm. long.

DERIVATIVES OF THE VISCERAL ARCHES.

From the visceral arches are derived the bones of the middle ear, the styloid process of the temporal bone, the stylohyoid ligament, the hyoid bone, and the cartilago thyroidea. In the human embryo the formation of the blastemal ossicles and of the hyoid bone is a fairly direct process, but their relations to the embryonic skeleton of the mandibular and hyoid arches (Meckel's and Reichert's cartilages) are more or less clearly marked. The relations of the laryngeal cartilages to the visceral arches are not so definite.

Toward the end of the first month the tissue in the branchial arches, in the lateral region of the head immediately dorsal to these, and about the larynx becomes much condensed. According to I. Broman, the tissue in the dorsal part of the mandibular arch region is divided by the third division of the fifth nerve into lateral and medial portions, while that in the hyoid arch region is similarly divided by the seventh nerve. The relations of these divisions of the blastema of the first two arch regions to the auditory ossicles are described as follows:

The proximal portion of the lateral part of the blastema of the mandibular arch region gives rise to the anlage of the incus. From this in a 14 mm. embryo a process of condensed tissue may be followed anteriorly, lateral to the fifth nerve, into the anlage of the maxilla. This later disappears. The anlage of the incus soon fuses with the blastema of the otic capsule (Fig. 315, A), but becomes separated again at the time of chondrification. The proximal part of the lateral division of the blastema of the hyoid arch region gives rise to the anlage of the tympanohyale (laterohyale). This in turn becomes fused to the capsula auditiva and to the styloid process (Fig. 311).

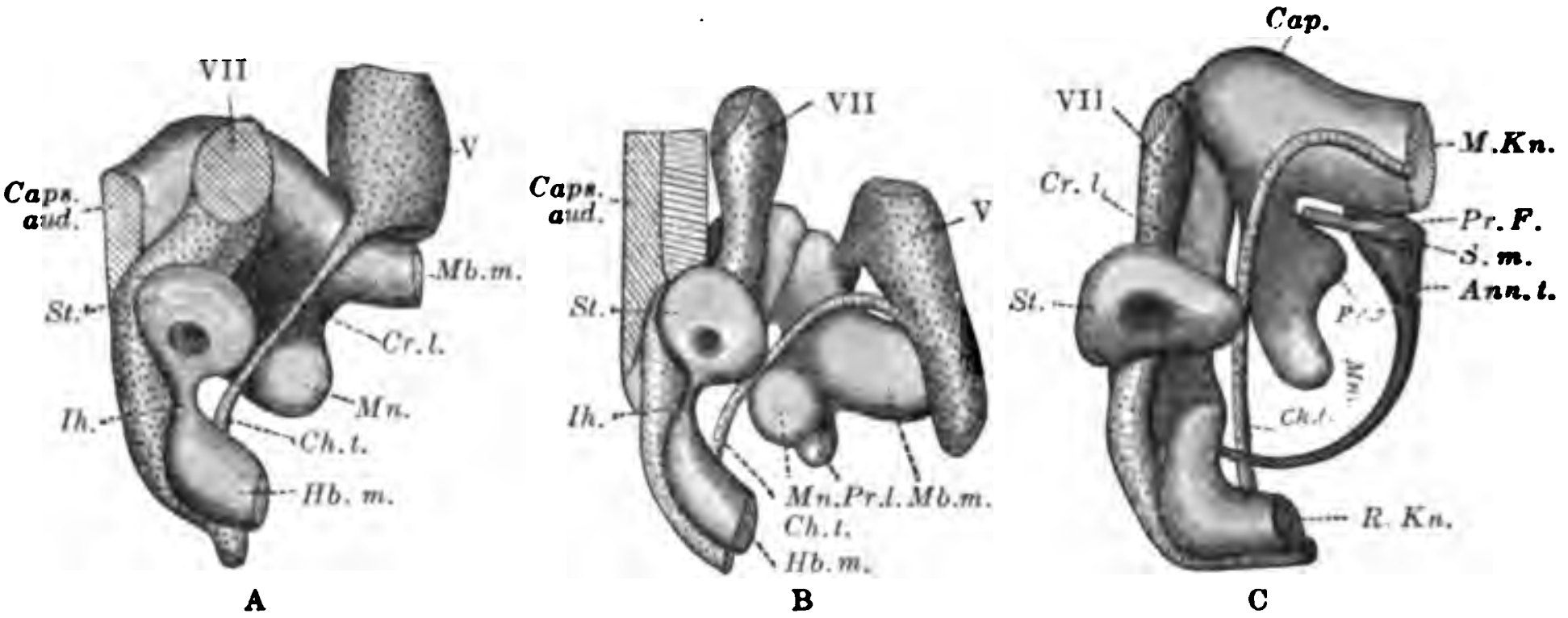

FIG. 315.—(After Broman, Anatomische Hefte, 1897, vol. xi, Taf. C, Figs. 5, 7, and 9.) Three figures to illustrate the development of the bones of the middle ear. The models are viewed from the medial side. Fig. A. From an embryo 16 mm. long; magn. 1 : 30. Fig. B. From an embryo 20.6 mm. long; magn. 1 : 30. Fig. C. From a fetus 55 mm. long; magn. 1 : 15. *Ann. t.*, annulus tympanicus; *Ch. t.*, chorda tympani; *Cap.*, capitulum mallei; *Caps. aud.*, capsula auditiva, pars canalicularis; *Cr. l.*, crus longum incudis; *Hb. m.*, hyoid arch, medial portion; *Ih.*, interhyale; *Mb. m.*, mandibular arch, medial part; *Mn.*, manubrium mallei; *M. Kn.*, Meckel's cartilage; *Pr. F.*, processus longus (folii) mallei; *Pr. l.*, processus lateralis mallei; *R. Kn.*, Reichert's cartilage; *S. m.*, sulcus malleolaris; *St.*, stapes; *V*, N. trigeminus; *VII*, N. VII facialis.

The cartilage of the external ear is differentiated from the blastema of the dorsolateral region of both the mandibular and the hyoid arches.

The proximal end of the medial part of the blastema of the mandibular arch region is checked in development by the vena jugularis primitiva. The portion beyond this gives rise to the anlage of the malleus (Fig. 311), and this is continued into a condensed band of tissue that may be followed in the mandibular arch to the mid-ventral line. This band is the anlage of Meckel's cartilage and appears in an embryo 11 mm. long as a rod of dense tissue.

The proximal end of the medial part of the blastema of the hyoid arch region gives rise to the anlage of the stapes (Fig. 311).[21] This anlage is from the first connected by a band of blastemal tissue with the anlage of the incus. The band of tissue develops into the crus longum incudis (Fig. 315, C).[22]

Immediately ventral to the anlage of the stapes there is formed a small band of tissue (interhyale, Broman; lig. hyostapediale, Fuchs), which connects this anlage with the main hyoid arch. It lies beneath the facial nerve (Fig. 315, A and B). It forms a partial sheath for this nerve. In the second month it disappears, so that the stapes anlage is no longer connected with the main hyoid scleroblastema. The latter is a rod-like process which extends from the tympanohyale (laterohyale) medialwards to the anlage of the body of the hyoid bone. It is visible in an 11 mm. embryo.[23] It gives rise to the styloid process, the stylohyoid ligament, and the lesser cornu of the hyoid bone.

It is convenient to consider the development of the ossicles and of Meckel's cartilage separately from the development of the hyoid bone, the styloid process, and the laryngeal cartilages.

THE OSSICLES AND MECKEL'S CARTILAGE.

During the latter half of the second month Meckel's cartilage becomes chondrified. Its position at this period is shown in Fig. 311. It does not reach quite to the mid-ventral line. Later it sends a process upwards parallel to the medial line (see Figs. 312–324).

Dorsally Meckel's cartilage is continued into the capitulum of the malleus (Figs. 311, 314, 315, B and C).[24]

Toward the end of the second month the malleus is fairly well differentiated (Figs. 311 and 315, B). The manubrium extends medialwards in a dense mass of tissue which intervenes between

---

[21] According to Hugo Fuchs (1905), in the rabbit the anlage of the stapes lies dorsal and anterior to the hyoid arch region and arises not in connection with the hyoid arch but rather in connection with the otic capsule. There is later formed a temporary connection between the anlage of the stapes and that of the skeleton of the hyoid arch, the "ligamentum hyo-stapediale."

[22] According to Fuchs (1905), in the rabbit the anlage of the crus longum of the incus arises apparently independently of the main anlage of the incus.

[23] According to Fuchs (1905), in the rabbit it first appears in the region of the hyoid bone and thence extends dorsalward.

[24] According to Fuchs (1905), there is a common malleus-incus anlage in the rabbit, which arises independently, chondrifies from a separate centre, and becomes secondarily fused to Meckel's cartilage. The latter arises, according to Fuchs, from a centre which lies in the region where the temporo-mandibular joint is later dif-

the lateral extremity of the tubotympanic cavity and the medial end of the external auditory meatus.[25]

In Fig. 311 the most medial part of this tissue and the medial extremity of the external auditory meatus are shown. From the manubrium a "lateral" process is at first directed downwards. As development proceeds the manubrium comes to be directed downwards and the lateral process is turned outwards. The crista mallei arises during the fourth month. It is not due to the outgrowth of a process, but rather to absorption of the underlying cartilage. The joint surfaces between the malleus and incus have from the first two chief facets, as in the adult. The greater facet is at first directed laterally, the smaller dorsally. When rotation takes place the greater facet faces dorsally, the smaller medially. At the beginning of the third month the accessory facets of the joint surface and the "Sperrzahn" of Helmholtz appear. The cartilaginous malleus is at first joined to the cartilaginous incus by dense tissue, in which later a joint cavity arises.

The incus (Figs. 311, 314, and 315, B and C) becomes chondrified during the latter half of the second month. It has a special centre of chondrification, which first appears in the head and then extends to the processes. The head at this period is embedded in dense membranous tissue (Fig. 310).

Cartilage extends into the crus longum as far as the joint between it and the stapes. This joint is at first composed of dense tissue but is later differentiated into a true joint. The crus brevis is formed when chondrification starts in the anlage of the incus. At this period the head of the incus becomes somewhat separated from the capsule of the labyrinth, with which it has been temporarily fused. A short blastemal process is left which extends dorsally from the incus to the capsule. Into this process the cartilaginous crus breve extends. In Fig. 311 the space between the crus breve and the auditory capsule is shown slightly too wide in order to reveal the deeper structures. The processus lenticularis is not formed until the crus longum has begun to ossify. At the beginning of the third month the crus breve, crus longum, and the manubrium of the malleus lie nearly in a plane, a condition noted by Helmholtz in the adult. The malleus and Meckel's cartilage are homologous with the skeleton of the lower jaw in

---

ferentiated, and from which the articular part of the squamosum also arises. According to Fuchs, the mandibular joint of mammals is homologous with the quadrato-articular joint of the lower forms. According to most investigators, the quadrato-articular joint is homologous with the malleus-incus joint in mammals, a view originally advanced by Reichert. See Gaupp (1906), Van Kampen (1905), Mead (1909).

[25] According to Fuchs (1905), in the rabbit the manubrium arises separately from the anlage of the head of the malleus, to which it extends from the hyoid arch region.

the inferior vertebrates. The incus is homologous with the quadrate portion of the palato-quadrate. The palate portion is not represented.[26]

The first definite differentiation of the stapes is seen when the cells of the anlage form a ring of tissue concentrically arranged about the stapedius artery. This is at first separated from the capsule of the labyrinth by loose tissue, but later becomes fused to it, although still distinguishable by the arrangement of the cells. When chondrification sets in, it becomes still more clearly marked off. From the first it has an oblique position (about 45° to the horizon). Chondrification begins during the latter part of the second month. At the end of the third month the hitherto circular stapes begins to take its definite form. The artery persists to the end of the third month. As the foot-plate of the stapes becomes differentiated the lamina fenestris ovalis becomes thin.

TYMPANOHYALE, REICHERT'S CARTILAGE, THE HYOID BONE, AND THE LARYNGEAL CARTILAGES.

The tympanohyale (laterohyale) arises from the proximal part of the lateral blastema of the hyoid arch region. It becomes chondrified from a separate centre and then proximally fuses to the cartilaginous otic capsule, while distally it becomes fused with the chief cartilage of the hyoid arch. The part of the otic capsule with which the tympanohyale fuses is a process that lies on the ventrolateral surface of the promontory of the lateral semicircular canal, the crista parotica. The processus perioticus superior is developed at the apical end of this crest. The proximal end of the tympanohyale is enclosed in the tympanic cavity and utilized in the formation of the wall of a canal containing the nervus facialis, the musculus stapedius, and a few blood-vessels (foramen stylomastoideum primitivum, Broman).

The chief blastemal skeletal element of the hyoid arch is a rod of tissue which is proximally connected both with the anlage of the stapes and with that of the tympanohyale. Distally it extends to the lateral margin of the anlage of the body of the hyoid bone. It loses its proximal connection with the stapes, becomes chondrified from a separate centre and finally fused with the distal end of the cartilaginous tympanohyale (Figs. 311, 314). It is now known as Reichert's cartilage. Subsequently it becomes transformed into the lesser cornu of the hyoid, the stylohyoid ligament, and the styloid process.

It has been pointed out above that the mesenchyme of the visceral arches toward the end of the first month becomes very dense and that a dense mass of tissue surrounds the anlage of

---

[26] See, however, note 24, p. 419, and note 43, p. 141.

the larynx. This mass of tissue is especially developed ventral and lateral to the larynx and is connected with the dense blastema of the hyoid and of the more posterior visceral arches. During the second month there are developed in this tissue the anlages of the body and of the greater cornua of the hyoid bone and of the laminæ and the cornua of the thyroid cartilage of the larynx.

The appearance of the structures mentioned above toward the end of the second month is shown in Fig. 311. Their appearance about the middle of the second month is shown in Fig. 316.

The body of the hyoid is developed from the ventral part of this dense tissue in front of the proximal end of the larynx. It may be barely distinguished in an 11 mm. embryo. Precartilage appears in it in a 14 mm. embryo. At about this time it has the form shown in Fig. 316, A and B. The form is essentially similar at the end of the second month (Fig. 311), but it is still composed largely of dense tissue and precartilage. During the third month it becomes more highly differentiated. The body of the hyoid bone probably represents a copula of a visceral arch or the fusion of two such copulæ. Kalliüs found in the cow an anterior and a posterior anlage, the former of which may represent a hyoid, the latter a third visceral arch copula. No such double anlage has been found in man.

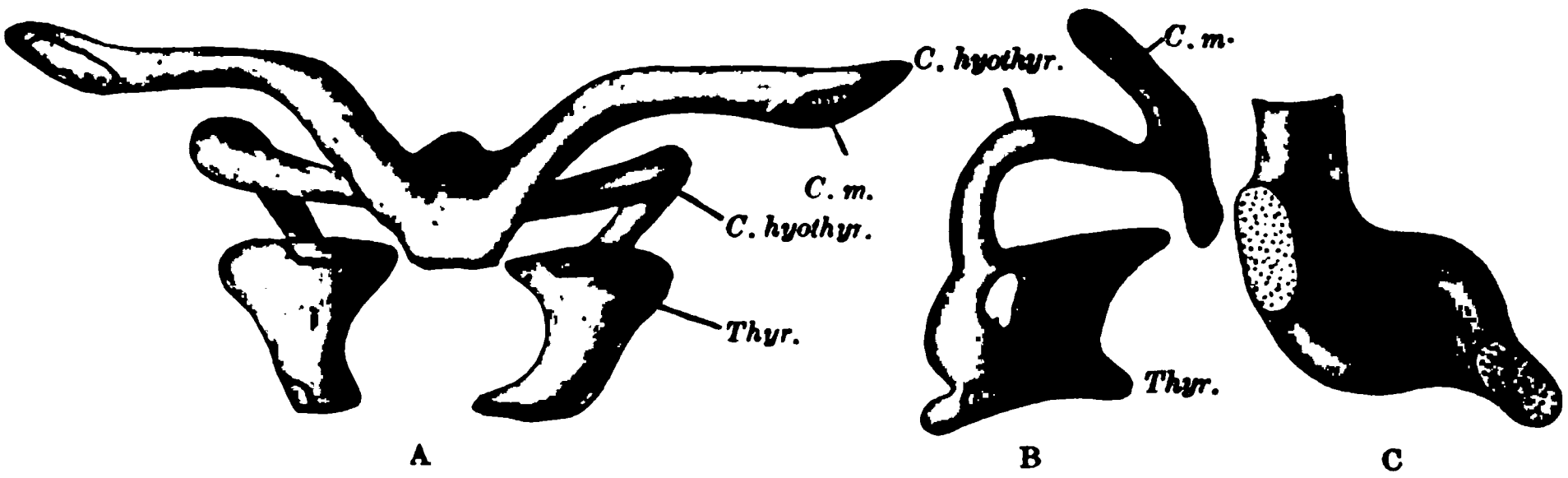

Fig. 316.—(After Kallius, Anatomische Hefte, 1897, vol. ix, Taf. XXVI, Figs. 20, 21, and 22.) Three figures to illustrate the development of the hyoid bone and the laryngeal cartilages. A and B, hyoid, hyothyreoid, and thyroid cartilages, from an embryo 39–40 days old: A, ventral view; B, lateral view. C. Medial view of the cricoid cartilage of an embryo 40–42 days old. The centres of chondrification are outlined by heavy lines. *C. m.*, cornu minus; *C. hyothyr.*, cartilago hyothyreoidea; *Thyr.*, cartilago thyreoidea.

The anlage of Reichert's cartilage in the 11 mm. embryo above mentioned is more highly developed than the body of the hyoid. It is composed of a very dense tissue, which is connected with the blastema of the body. When chondrification takes place Reichert's cartilage long remains separated from the cartilage of the body of the hyoid by a narrow band of dense tissue which forms a kind of primitive joint. Finally the two cartilages become fused.

Between the body of the hyoid bone and the laminæ of the thyroid cartilage in the dense tissue lateral to the larynx there is developed a curved cartilaginous bar, which we may call the hyothyroid cartilage (Figs. 311, 316, A and B). Ventrally this bar is joined at first by dense tissue, later by cartilage, to the back of the body of the hyoid. Dorsally it becomes fused to the cartilage of the lamina of the thyroid. It is invisible in an embryo of 11 mm. and becomes chondrified apparently from a single centre at about the time of the chondrification of Reichert's cartilage. It represents the skeleton of the third and a part of the fourth visceral arches. Its ventral portion becomes the greater cornu of the hyoid bone and its dorsal inferior portion the superior cornu of the thyroid cartilage. The two portions become discontinuous at the end of the third month, so that a small cartilago triticea is separated on the one side from the great cornu of the hyoid bone and on the other from the superior cornu of the thyroid cartilage. Connective tissue serves at the same time to form connecting ligaments, but the definite lig. hyothyroideum is not well developed until after birth, when the hyoid bone becomes further separated from the thyroid cartilage.

The blastemal laminæ of the thyroid cartilage appear about the middle of the second month. One appears on each side at the periphery of the dense tissue surrounding the ventral part of the larynx. This anlage has the form of a slightly curved quadrilateral plate in which a foramen may be seen (Fig. 316, B). There are two centres of chondrification, one cranial and the other caudal to the foramen. The cranial centre is continuous with the hyothyroid cartilage and later becomes united on each side of the foramen to the cartilage of the caudal centre. The foramen is usually closed by cartilage, but occasionally remains patent throughout life. The inferior cornu is developed from the dorsal part of the caudal margin of the lamina. Ventrally the laminæ of each side become united by the membranous tissue into which the cartilages of the cranial and caudal margins of the laminæ extend, and finally unite in the mid-ventral line. Between the two margins there is an orifice closed merely by membrane. In this a special centre of chondrification appears. This medial cartilage eventually becomes united to the cartilage of the laminæ, so that the central orifice is closed in the tenth to thirteenth week (according to Kallius). The cranial margin of the thyroid cartilage is at first nearly level. The incisura arises through the rapid development of the laminæ lateral to the median line. The cornu inferius, the tuberculum superius and inferius, and the linea obliqua are developed during the latter part of the fourth month.

The thyroid cartilage is supposed to be derived from the fourth and fifth visceral arches. The central cartilage probably represents copulæ.

The cricoid cartilage is the first of the cartilages of the larynx to show definite hyaline tissue. About the lower part of the larynx there is formed a dense band of tissue. In this tissue a semicircular cartilaginous process appears. (In Fig. 316, C, the cartilage is surrounded by dark lines.) It is bilaterally better developed than in the mid-line, but if there are two bilaterally placed centres these quickly fuse ventrally. The cartilage slowly develops in the dorsal direction. Fig. 311 shows it at the end of the second month. In the third month the ring is completed and the posterior lamina is developed.

The arytænoid cartilage develops from the blastema continued cranialward from the cricoid cartilage (Fig. 316, C). A special centre of chondrification appears in the seventh week. The first part of the cartilage developed represents the posterior portion, chiefly the proc. muscularis. From this the processus vocalis grows ventrally. This process, however, is long blastemal and does not reach its definitive form till the end of the fourth month (Kallius). The apex of the cartilage grows cranialwards, so that the definitive form of the cartilage, with the exception of the proc. vocalis, is approached by the end of the third month. There is regularly present in later fetal life on the arytænoid cartilage ventral to the cart. corniculata a process which disappears after birth. Its place is marked by the origin of the ligament which extends to the cartilago cuneiformis. It is probable that it represents the cartilaginous process which connects the arytænoid and cuneiform cartilages in some animals (Kallius).

The blastemal anlage of the cart. corniculata is continuous with that of the cart. arytænoidea. Toward the end of the third month it chondrifies from a special centre.

The cartilage of the epiglottis does not appear until the end of the fifth month. It has a single median centre.

The cuneiform cartilages develop in the blastema of the plicæ aryepiglotticæ. They appear toward the end of the seventh or early in the eighth month.

PERIOD OF OSSIFICATION.

In the human skull the membrane bones are extensively developed, compared with those in lower forms. Some of the centres of ossification in the membranous tissue arise before any of the centres in cartilage. Thus Mall (1906) has found centres of ossification for the mandible (39th day), maxilla (39th day) and premaxilla (42d day), before any centre of ossification has appeared in the chondrocranium. The first centres of ossification to appear in the chondrocranium are those in the occipitale laterale (56th day), the basioccipital (65th day), orbitosphenoid (83d day), and basisphenoid (83d day).

The complexity of the ossification of the bones of the skull makes it advisable to discuss briefly the development of each of the individual bones recognized in the human skull rather than to treat of the bones in classified groups. Most of the bones of the human skull arise from two or more centres of ossification, some of which represent individual bones in the lower vertebrates.

OS OCCIPITALE.

In the occipital bone five elementary parts may be distinguished, a basal (basioccipital), two condylar (occipitalia lateralia, exoccipitals), an occipitale superius (squama, inferior part), and an interparietal (squama, superior part). The interparietal arises in membranous tissue, the other parts in cartilage.

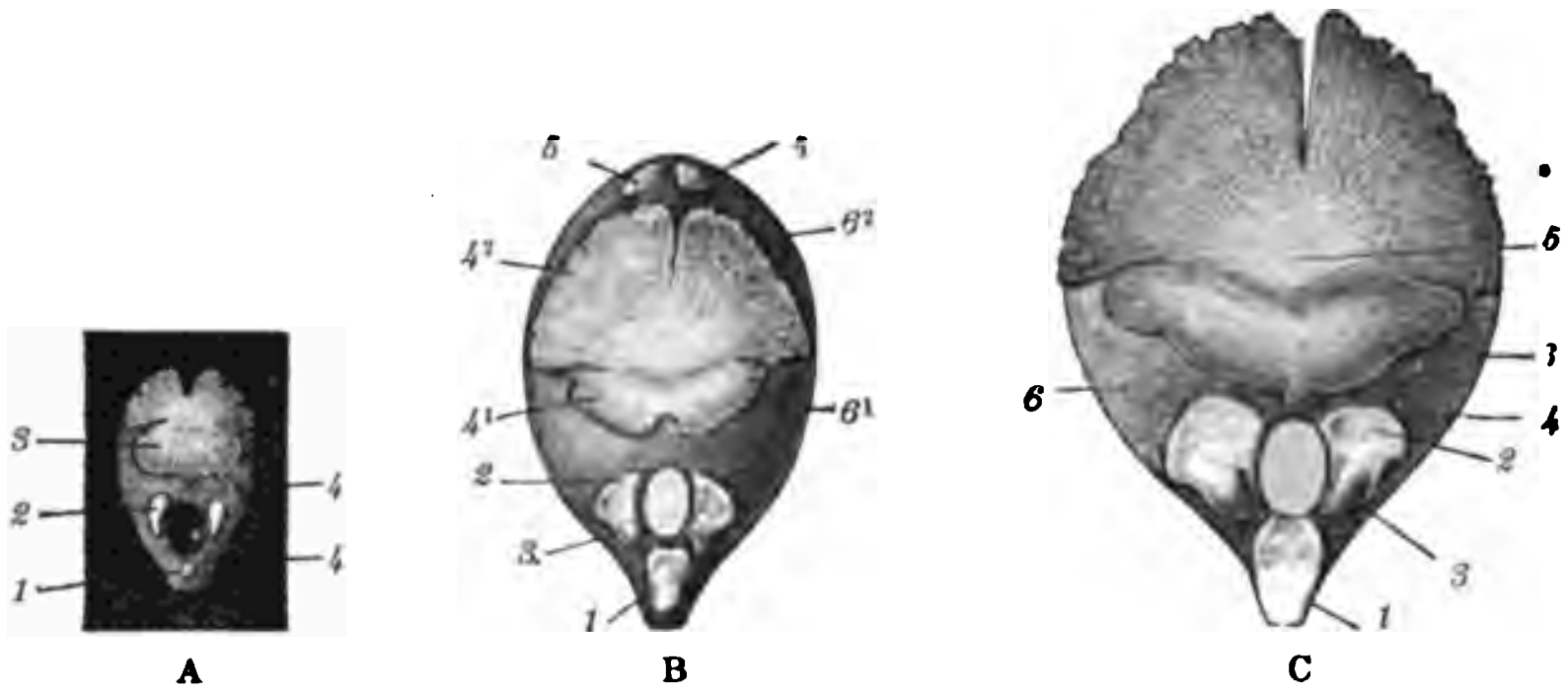

FIG. 317.—(After Sappey, Traité d'Anatomie, Fig. 12.) Development of the occipital bone. A. Embryo of two months: 1, ossification in the basioccipital; 2, ossification of lateral occipital; 3, occipitale superius; 4, cartilage. B. Fetus of three months: 1, basioccipital; 2, occipitale laterale; 3, condyle; 4^1, occipitale superius; 4^2, interparietale; 5, preinterparietale; 6^1, cartilage; 6^2, membranous portion of occipital. C. Fetus of four months: 1, basioccipital; 2, occipitale laterale; 3, condyle; 4, ossiculum of Kerckringi; 5, external occipital protuberance; 6, cartilage.

The basioccipital and the two occipitalia lateralia arise each from a separate centre of ossification in the chondrocranium, and at birth are still separated from one another by cartilage (Fig. 317, A, B, C). The centres for the occipitalia lateralia appear on the 56th day and that for the basioccipital on the 65th (Mall).

The occipitale superius and the interparietal are at birth fused into a single plate of bone.[27] The occipitale superius arises from four, the interparietal from two centres of ossification (Mall). According to Mall, the first centres of ossification to appear are two bilaterally placed centres for the occipitale superius which arise in the cartilage immediately dorsal to the foramen magnum (55th–56th day). These two centres soon unite across the mid-

---

[27] By some authors the bone here called occipitale superius is designated infra-occipital; and the bone here called interparietal is called supra-occipital. (See Poirier, Traité d'Anatomie, vol. i, p. 408–409.)

line,[28] and are joined by two secondary centres, one of which arises on each side. Occasionally an additional unpaired median centre appears on the dorsal margin of the foramen magnum.[29] More often, however, there arises a small process, on the inferior margin of the squama in the medial line (Fig. 317, C, 4). This process, later enclosed by bone, gives origin to the crista occipitalis interna (Lengnick, 1898).

The two bilaterally placed interparietal centres appear on the 57th day in the membranous tissue which extends anteriorly from the occipitale superius. They are rectangular in form and unite on the 58th day to form the interparietal bone. The interparietal unites with the occipitale superius in the first half of the third month of intra-uterine life to form the squama of the occipital. Fusion takes place in the median line before it does laterally; at birth the lateral fusion is usually incomplete. The interparietal may remain partially or wholly separated from the occipitale superius throughout life. In many of the lower mammals the interparietal normally remains distinct from the supraoccipital. According to Ranke, the squama occipitalis arises from four pairs of centres of ossification. Various investigators differ considerably in the number of centres which they ascribe to this part of the occipital. Anterior to the interparietals a pair of pre-interparietal bones (Fig. 317, B) are apparently not infrequent. The osseous union of the occipitale superius and the occipitalia lateralia begins in the first or second year and is completed in the second to fourth year; that of the basioccipital and the occipitalia lateralia begins in the third or fourth but is not completed until the fifth or sixth year or later. The basioccipital forms the anterior fourth or fifth of the condyles. Some authors describe condylar epiphyses. The basioccipital is united to the basisphenoid by cartilage up to about the twentieth year (16th to 20th, Toldt). Ossific union is completed one or two years later (Quain's Anatomy, 10th ed.). Epiphyseal discs like those which complete the bodies of the vertebræ are described as arising and fusing with the contiguous surfaces of the basisphenoid and basioccipital before the two bones become united by synostosis. At the centre of the synostosis a mass of fibrocartilage frequently long persists. Remnants of the chorda dorsalis may likewise persist here and give rise to tumors. (See Poirier, Virchow, Welcker, Luschka, Steiner.)

---

[28] According to Toldt, instead of two there may be a single medially placed centre. According to Bolk (1903), the ossification arises in the membranous part of the tectum synoticum.

[29] Ossiculum Kerckringii, Kerckring, 1670, Manubrium ossis occipitalis, R. Virchow. Ranke showed that it arises in cartilage and membranous tissue. Bolk found in one instance an independent cartilaginous nucleus in this region.

Considerable variation is found at the base of the occipital bone. (See Swjetschnikow, 1906, p. 155.) Variations of this kind are associated with variations of the atlas.

OS SPHENOIDALE.

In man the sphenoid bone arises chiefly from ossification centres which appear in the orbitotemporal region of the chondrocranium. To it several bones of membranous origin become fused. In the sphenoid one may distinguish fourteen centres of ossification: four in the basisphenoid, two presphenoid, two alisphenoid, two orbitosphenoid, two pterygoid, and two intertemporal. In addition to these centres there are several in the ossicula Bertini which in part fuse with the presphenoid after birth. (See below.)

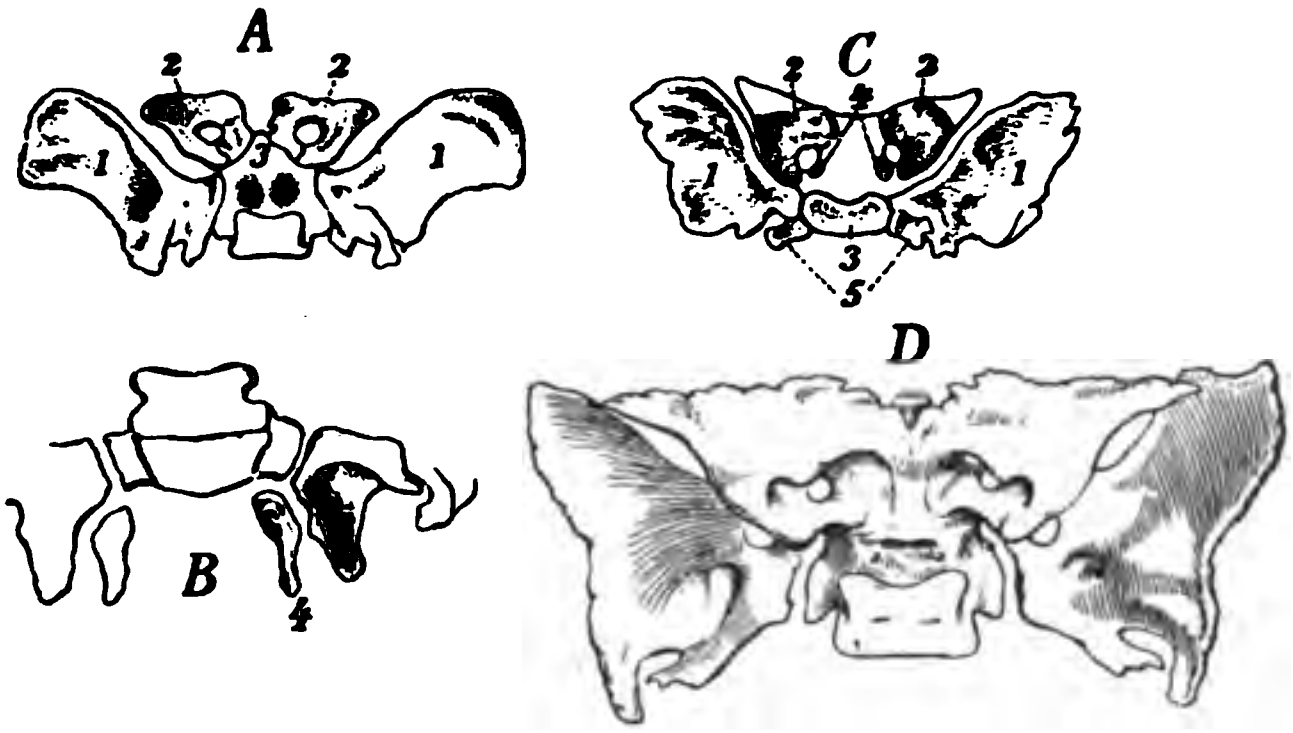

Fig. 318.—(After Quain, Quain's Anatomy, 10th ed., vol. ii, Pt. I, Fig. 78.) Ossification of sphenoid bone. A. Sphenoid bone at an early period, seen from above: 1, the alæ temporales ossified; 2, the alæ orbitales in which the ossification has encircled the optic foramen, and a small suture is distinguishable at the posterior and inner side; 3, nuclei of basisphenoid. B. Back part of the bone shown in A: 4, medial pterygoid plates still separate. C. (Copied from Meckel, Archiv, vol. i, tab. vi, Fig. 231, and stated to be from a fetus of six months): 4, nuclei of presphenoid; 5, separate lateral processes of the body (lingulæ): the other indications are the same as in A. D. Sphenoid at birth. The great wings are still separate. The presphenoids are now joined to the basisphenoid and the medial pterygoid plates (not seen in the figure) are united to the lateral.

In each of the *greater wings,* alisphenoids, a centre of ossification appears toward the end of the second month in the chondrocranium between the maxillary and the mandibular nerves. From this centre ossification extends into the lateral lamina of the pterygoid and into the lateral portion of the greater wing (Figs. 322 and 318, A and C). From the main centre a lamella of bone is usually formed about the mandibular branch of the trigeminal nerve, thus separating a foramen ovale from the foramen lacerum. According to some authors, there are two centres of ossification in the alisphenoid and external pterygoid which fuse together at an early period (Sappey).

In the latter part of the third month (Mall) a bilaterally placed pair of centres appears in the basisphenoid (Fig. 322 and Fig.

318, A). The two centres unite in the fourth month. After this union two other centres arise (sphenotics, Sutton, 1885), give origin to the lingulæ, and fuse with the body (Fig. 318, C). The superior margin of the alisphenoid is strengthened by a membranous bone (Hannover, 1880). This bone, called the os intertemporale by Ranke, occasionally persists as an independent structure or may be fused to the squama temporalis or to the frontalis.

The nuclei for the *medial pterygoid* plates appear in the second month (57th day, Mall) (Fig. 318, B). They fuse with the nuclei of the greater wings in the fourth month. They are said to arise in cartilage, which develops in membranous tissue independent of the chondrocranium (Hannover, Graf v. Spee). According to Fawcett (1905), however, the main part of the medial pterygoid plate is ossified in membrane, although the hamulus is transformed into cartilage before ossification. According to Gaupp, there is questionable propriety in applying the term os pterygoideum to the lamina medialis if thereby one would imply homology with the os pterygoideum of reptiles. One should probably homologize it with the lateral part of the parasphenoid.

Each of the *lesser wings,* orbitosphenoids, is ossified from a centre which appears in the ninth week lateral to the optic foramen (Fig. 318, C). On the medial side of each optic foramen a centre of ossification, presphenoid, appears early in the third month (Fig. 318, C). The centre for the orbital wing fuses with the corresponding presphenoid centre in the fourth month. The two presphenoid centres fuse with one another in the eighth month. Acccording to Hannover (Gaupp, 1906), there are four presphenoid centres. Toldt and Sutton describe but two.

The presphenoidal centres become partially united to the basisphenoids in the seventh or eighth month. At birth, however, there is a ventral wedge of cartilage between the two portions of the bone. This does not disappear till late in childhood.[30] The greater wings become joined to the body of the sphenoid during the first year after birth. The base of the great wing spreads out over the side of the body of the sphenoid. Between it and the presphenoid there may be formed a small canalis craniopharyngeus lateralis (Sternberg, 1890). Occasionally the hypophyseal canal persists as a canalis craniopharyngeus medius.

The posterior end of the nasal septum (crista sphenoidalis and rostrum sphenoidale) is ossified by extension of bone from the presphenoid.

The concha sphenoidalis (ossiculum Bertini) arises through

---

[30] In many mammals the sphenoid remains permanently divided into two parts, a presphenoid, which comprises the apical end of the body and the lesser wings, and a postsphenoid, which comprises the sella turcica, the great wings, and the pterygoid processes.

ossification of the posterior cupola (Kuppel) of the cartilaginous nasal capsule (see p. 416). Ossification begins in the fifth intra-uterine month in the medial (paraseptal) wall of the cupola, and in the seventh to eighth month a secondary centre arises in the lateral wall. In the membranous floor of the cupola toward the end of intra-uterine life further centres of ossification arise and fuse with the bone originating in the two primary centres. By the third year each terminal nasal sinus is surrounded by bone except toward the nasal fossa, where an opening called the "sphenoidal foramen" persists. Each bone lies on the inferior surface of the presphenoid, lateral to the crista sphenoidalis and the rostrum sphenoidale, to which it is united by connective tissue. About the fourth year the superior and medial parts of the capsule begin to be absorbed, so that the presphenoid comes to bound the sinus terminalis. Laterally absorption of the bony capsule also takes place while the inferior portion and that surrounding the sphenoidal foramen become fused with the ethmoid. In the ninth to twelfth year, however, this portion fuses with the sphenoid and the sinus terminalis extends into the body of the latter (Gaupp, 1906; Cleland, 1863; Toldt, 1882).

OS ETHMOIDALE.

The ethmoid bone arises from one medial and two lateral primary and from several secondary centres in the cartilaginous nasal capsule. The ossification of the posterior cupola of the cartilaginous nasal capsule in man as the ossiculum Bertini has been described in connection with the sphenoid bone. In the quadrupeds this portion of the nasal capsule is ossified in conjunction with the ethmoid (Gaupp, 1906).

In each lateral wall of the nasal capsule a centre appears in the fifth to sixth fetal month. It gives rise to the lamina papyracea, and in the seventh and eighth months ossification extends into the conchæ and the lamina cribrosa. The ethmoidal cells are closed off by folds of mucous membrane which arise in the latter half of fetal life and extend between the lamina cribrosa and the upper concha and between the conchæ (Fig. 319). Into these folds of mucous membrane ossification extends from the conchæ so as to give rise to osseous walls for the ethmoidal cells.

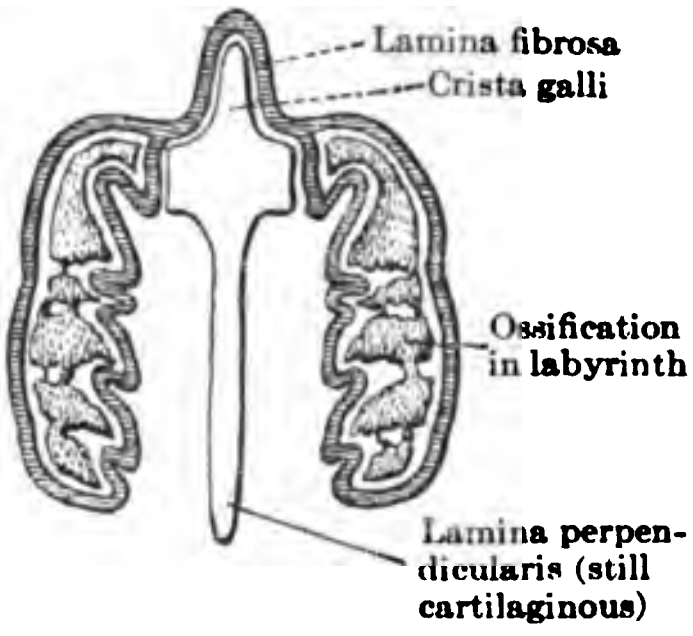

FIG. 319. — (After Rambaud and Renault, from Poirier, Poirier and Charpy, Traité d'Anatomie, vol. i, Fig. 462.) Ossification of the ethmoid bone; transverse section at time of birth.

Ossification begins late in the first year[31] independently in the superior portion of the nasal septum (lamina perpendicularis). It extends into the crista galli, the cribriform plate, and the lamina perpendicularis. Sappey and Poirier, following Rambaud and Renault, describe several centres on each side of the upper margin of the lamina perpendicularis at the base of the crista galli. From these centres ossification extends successively to the crista galli, the lamina cribrosa, and the lamina perpendicularis. In the crista galli in the second year a secondary nucleus arises. Ossification of the process is not completed before the fourth year. In the second year two accessory nuclei appear in the anterior part of the lamina cribrosa. By the sixth year the lateral parts of the ethmoid become united to the medial part (v. Spee and most authors).[32] Ossification of the ethmoid is not completed until the sixteenth year. Synchondrosis exists between the lamina cribrosa and the sphenoid until toward puberty. About the fortieth to forty-fifth year the lamina perpendicularis becomes united to the vomer.

CONCHA INFERIOR.

This arises in cartilage from a separate centre of ossification which appears in the latter half of fetal life (seventh month, Toldt; fifth month, Quain, Graf v. Spee).[33]

VOMER.

The vomer arises from a bilaterally placed pair of nuclei which appear during the eighth week (Quain, Mall), near the back of the inferior margin of the cartilaginous nasal septum. These centres unite beneath the inferior margin of the septum, but superiorly they extend on each side of the nasal septum so as to enclose the cartilaginous septum between two thin plates of bone. The two plates of bone gradually become coalesced from behind forwards. Union is completed about the age of puberty (Quain). On the anterior and superior margins a permanent groove remains for the attachment to the lamina perpendicularis ossis ethmoidalis and the cartilago septi nasi. Although the vomer develops on each side of the cartilaginous nasal septum and at its expense, it is regarded as a true membrane bone.

---

[31] According to v. Spee, before birth.

[32] The lamina cribrosa ossifies in part through extension of ossification from the crista galli and from the lateral ossific centres and in part from accessory centres. According to Sappey, Poirier, Toldt, and some other authors, the central part of the ethmoid becomes united to the lateral parts through ossification in the lamina cribrosa at the end of the first or in the second year.

[33] Third or fourth month after birth (Sappey, Testut, Poirier).

OS PALATINUM.

The os palatinum (a membrane bone) arises from a single centre of ossification which appears in the eighth week (Kölliker, Le Double, Mall, Fawcett) in a region corresponding with the angle between the horizontal and vertical parts, or, according to Fawcett, in the region of the vertical plate. Rambaud and Renault, Sappey, Cruveilhier, and others describe two or more centres. The vertical part extends upwards on the medial surface of the lateral wall of the cartilaginous nasal capsule and by this is separated for some time from the maxilla. It extends between the cartilaginous inferior and middle conchæ and the cartilaginous lateral wall of the nasal capsule, thus separating the posterior extremities of the former from the latter. The pars horizontalis appears much earlier than the processus orbitalis and the processus sphenoidalis.

OS NASALE.

This is a membranous bone which develops on the surface of the cartilaginous nasal capsule. The underlying cartilage is still present at birth, but subsequently becomes absorbed. It is usually stated that there is a single centre of ossification which appears at the end of the second month. Zuckerkandl (1895) has suggested that the anomalies of development shown by the nasal bone indicate that it may arise at times from two or even three centres of ossification. According to Perna (1906), the nasal bone arises from two anlages, a lateral membranous and a small medial cartilaginous. Remnants of the suture between the two may exist as an incisura nasalis.

OS LACRYMALE.

This is a membrane bone which arises on the lateral wall of the posterior part of the cartilaginous capsule of the external nose. The centre of ossification appears in the third month (83d day, Mall). The facies lacrymalis ossifies first, then the crista and hamulus, and lastly the facies orbitalis. In the adult the bone varies greatly in form (see MacAllister, v. Spee, Zabel, Le Double, etc.). Occasionally the bone in the adult is bipartite, indicating an accessory centre of ossification.

OS TEMPORALE.

The human temporal bone is the result of the fusion of several distinct elements, petrosal (periotic), squamosal, tympanic, tympanohyale, and stylohyale. In addition it encloses the three bones of the middle ear. At birth it consists of three pieces, a squamosum, a petrosum and a tympanicum. These become fused together during the first year.

The squamosum (Figs. 320, 321) is ossified from a single centre of ossification which appears in the membranous tissue in the region near the base of the zygomatic process of the squama (Mall, 1906).[34] From the posterior part of the squamosum a post-auditory process grows downwards beneath the region of the linea temporalis between the tympanic and petrosal portions of the bone. It forms the superior anterior part of the mastoid. The squamosum encloses laterally the cavum tympani and the antrum mastoideum, from which the subsequently develop.[35]

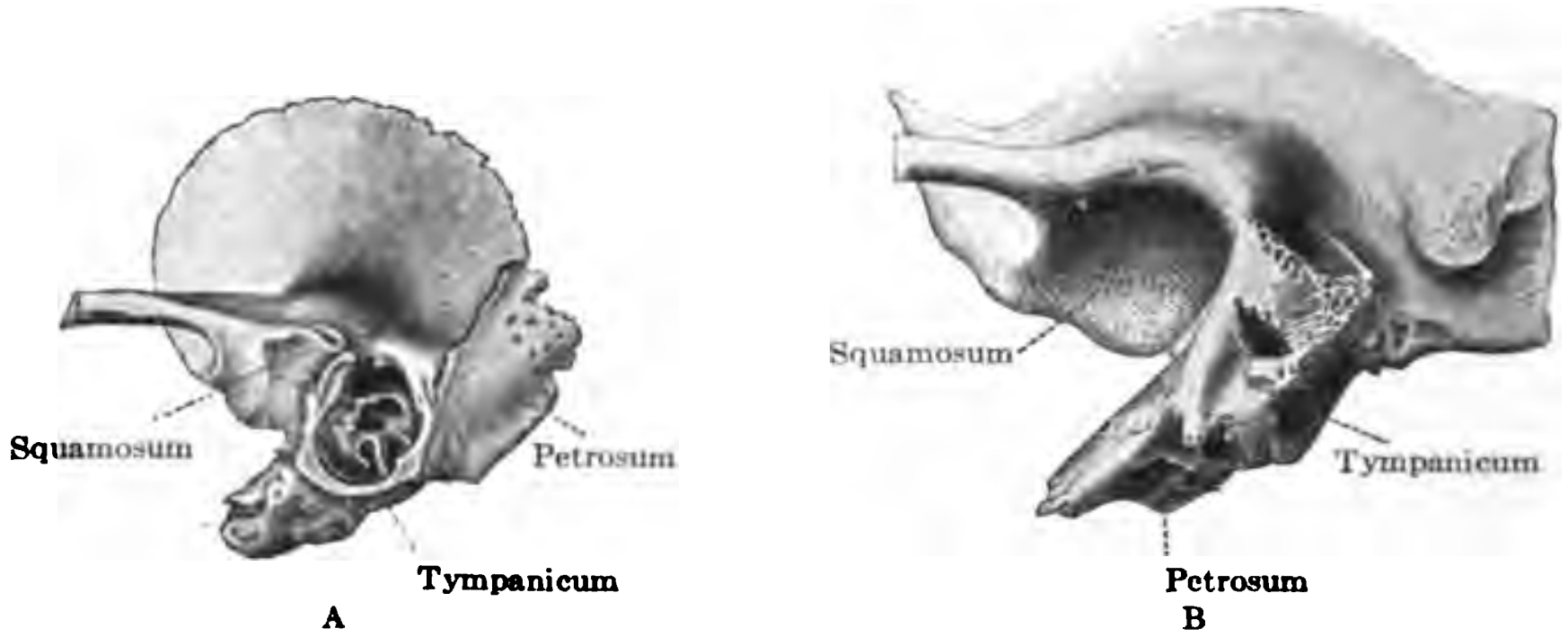

Fig. 320.—(After Sappey, Traité d'Anatomie, Figs. 32 and 33.) A. Temporal bone of a new-born infant. B. Temporal bone of an infant of two years.

The *tympanicum* (Figs. 320, 321, 324) is a membrane bone. Its centre of ossification appears toward the end of the third month in the anterolateral part of the external membranous wall of the cavum tympani, near the angle between the capitulum of the malleus and Meckel's cartilage. It has a concave surface turned toward the latter. From this centre a band of bone grows first downwards, medialwards, and backwards and then upwards and lateralwards so as to form a semicircular bone surrounding the tympanic membrane. In the tenth fetal month first the free ends of the bone fuse with the squamosum and then the under part fuses with the petrosum. By addition of osseus tissue to the lateral

---

[34] According to Rambaud and Renault, Toldt, Poirier, and others, the squamosum arises from three centres of ossification, one at the base of the zygomatic process, one in the squamosa, above this, and one behind the tympanicum. Among the variations found in the squamosal portion of the temporal bone are a division into a superior and an inferior part or into an anterior and a posterior part.

[35] Fuchs (1905–1907), chiefly from the study of rabbit embryos, has come to the conclusion that the squamosum of mammals is composed of three parts, a squamous and a zygomatic (quadrato-jugale) part, each ossified in membrane, and an articular part preformed in cartilage (pars articularis quadrati).

and medial margins of the bone, the primary narrow band becomes converted by the third year into a broad rolled-up plate of bone, which medially forms the ventral wall of the cavum tympani and laterally the ventral wall of the meatus acusticus externus. At this period the inferior surface of the tympanicum presents an aperture of some size which usually but not always becomes closed. According to Rambaud and Renault, Hammar, and others, the bone arises from several centres of ossification.

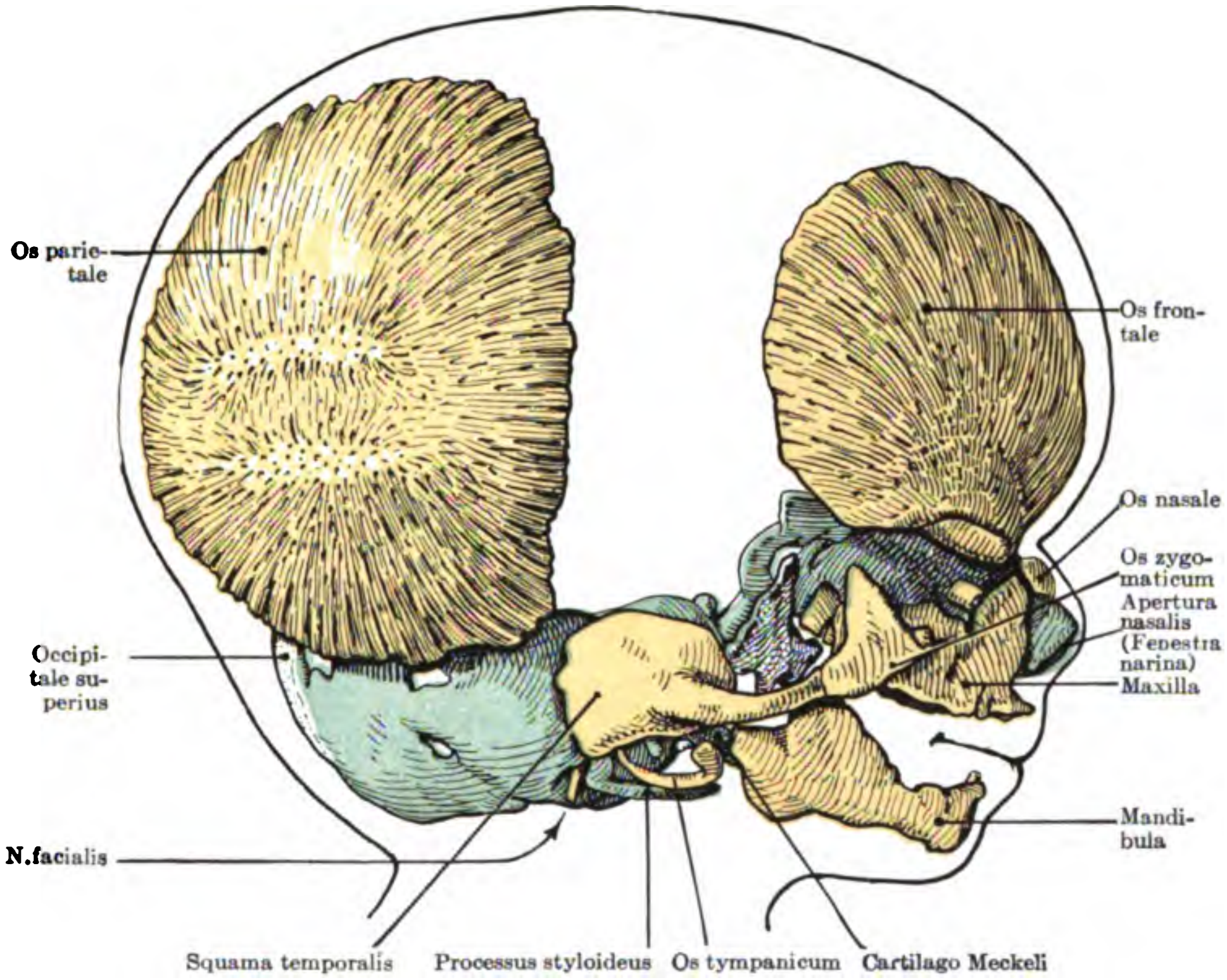

Fig. 321.—(After Hertwig's model, from Kollmann's Handatlas, 1907, Fig. 263.) Lateral view of the cranium of a human fetus 80 mm. long. The chondrocranium and the overlying membrane bones are shown. The parietal shows two centres of ossification.

Tympanohyale (laterohyale) and *stylohyale.* See p. 439.

The *periotic portion,* os petrosum (Fig. 322), arises from the ossification of the cartilaginous otic capsule. There are several centres of ossification. These centres arise during the fifth month and become fused with one another in the sixth. The descriptions of the centres of ossification in the labyrinth given by various authors differ considerably. That of Vrolik, as adopted by Gaupp (1906), is here chiefly followed. The first centre to appear is one in the region of the promontory between the fenestra vestibuli and the fenestra cochleæ in a fetus 17 cm. long. Ossification extends from here around the fenestra vestibuli and forms that part of the petrous bone which lies below the porus acusticus internus and the fenestra cochlearis. A second centre appears on the dorsolateral surface of the central part of the capsule over the superior semicircular canal. Ossification extends from this into the region of the processus perioticus superior. It forms most of the cranial surface of the petrous bone, gives rise to the superior boundaries of the internal auditory meatus and the fenestra cochlearis, and also to a portion of the superior medial part of the mastoid. A third centre arises at the anterior proximal part of the cochlea near the incisura pro-otica. More caudally, medial to the fossa subarcuata, there arises a fourth centre of ossification. The fifth centre appears on the outer surface of the posterior part of the capsule in the region of the posterior semicircular canal; the sixth centre arises slightly in front of the fifth. From the last

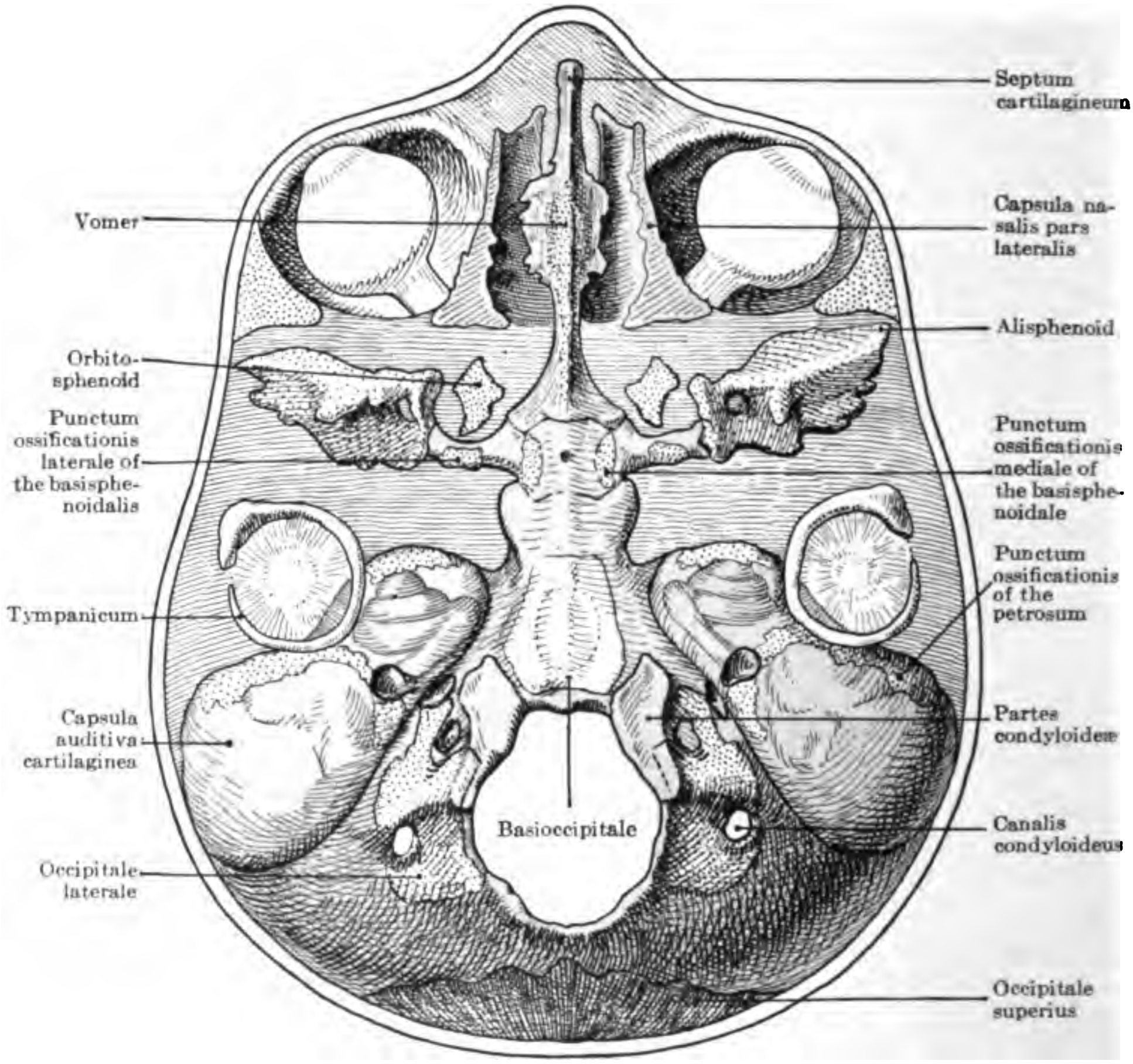

FIG. 322.—(After Kollmann, Handatlas, 1907, Fig. 271.) Visceral surface of the base of the skull of a human fetus 18 cm. long. The mandible and maxilla have been removed.

two centres ossification extends into the parietal plate and the pars mastoidea of the tectum posterius. At the end of the sixth month the labyrinth is completely enclosed by bone.

The tegmen tympani is ossified partly in membrane, partly in the cartilage of the processus perioticus superior by extension from the periotic capsule. There is occasionally found in man a separate bone in the anterior part of the tegmen tympani. This perhaps represents the ossiculum accessorium malleoli, which in some mammals has an independent centre of origin on the upper side of the proximal end of Meckel's cartilage (van Kampen, 1905).

The embryonic epithelial labyrinth at first lies in a cavity surrounded by cartilage. The inner surface of this cartilage becomes transformed into membranous tissue, and this in turn in part furnishes a membranous covering for the labyrinth, and in part becomes ossified, forming the inner lining of the bony labyrinth, including the modiolus, the lamina modioli, and the lamina spiralis ossea. (See Kölliker, 1879; Böttcher, 1869.)

The canalis caroticus is represented by a slight groove in the cartilaginous skull. It becomes converted into a canal during the period of ossification. At birth the central part only is roofed over.

Between the apex pyramidis and the sphenoid a part of the chondrocranium persists as the fibrocartilago basalis, which lies in the foramen lacerum.

Formation of mastoid cells does not begin until after birth, but in the second year they extend from the antrum into the mastoid process.

The Canalis Facialis.—The short facial canal in the chondrocranium is equivalent merely to the first part of the facial canal in the adult (part from the porus acusticus int. to the region of the geniculate ganglion). Before the chondrocranium is replaced by bone the nerve passes out from the canal above mentioned, then beneath the crista parotica and over the stapes, and thence backwards and downwards beneath the tympanohyale, and then outwards and ventralwards toward the surface of the body (Fig. 311). The nervus petrosus sup. major leaves the main trunk near the lateral orifice of the cartilaginous canal[36] and runs forward on the lateral wall of the capsule. The chorda tympani separates from the main trunk behind the stylohyale, runs forwards lateral to this cartilage and then between the malleus and incus. It is not enclosed in a canal in the chondrocranium. When the lateral wall of the auditory capsule becomes ossified, the facial nerve is en-

---

[36] In the human fetus and in Talpa through a special opening in the external orifice of the facial canal (E. Fischer).

closed at first in a groove and later in a canal. While the facial nerve is being enclosed bony lamellæ likewise enclose the stapedius muscle and the chorda tympani. The facial nerve and Reichert's cartilage may be looked upon as caught between the tympanicum and the mastoid part of the petrosum, the chorda tympani and Meckel's cartilage as caught between the tympanicum and the squamosum, the tuba auditiva (Eustachii) as enclosed between the tympanicum and the pars cochlearis of the petrosum (van Kampen).

OS PARIETALE.

The parietal arises as a membrane bone from two centres (Toldt), a superior and an inferior, which soon fuse into a single centre which lies in the region of the tuber parietale. The centres appear toward the end of the second month and apparently sometimes arise as a single centre. The ossification radiates outwards from the combined centre of ossification toward the sphenoidal and occipital angles, so as to give rise for a time to an hourglass-shaped plate of bone (Mall). At a later period a notch is left in the sagittal margin of the bone in front of the occipital angle. The notches of the bones of the opposite sides together form the sagittal fontanelle, which toward the end of fetal life usually becomes closed, but may sometimes be recognized after birth.

OS FRONTALE.

This has two centres of ossification, one on each side of the body in the region of the tuber frontale (Fig. 321). These centres arise toward the end of the second month (56th day, Mall). From each a lateral half of the bone is formed. The orbital part of the bone appears in the ninth week. Toldt found no secondary centres, but these have been described by Rambaud and Renault, Serres, Jhering, v. Spee, and others. These accessory centres include, on each side of the bone, one for the spina trochlearis, one for the processus zygomaticus, one for the posterior part of the orbital region, and one which arises late in the spina frontalis lateral to the foramen cæcum. The two lateral halves of the bone are separated at birth, but during the first year become approximated in the midsagittal line. The middle part of the frontal suture becomes ossified in the second year. By the eighth year the suture is usually obliterated except inferiorly. Near the root of the nose the frontal suture is sometimes widened to form a fontanella metopica, in which an os metopicum may be formed. Ossicles may appear also in other parts of the frontal suture (Schwalbe, 1901; Fischer, 1901). The frontal sinuses begin to be developed early (first year, Toldt), but develop very slowly until toward puberty. They increase in size until late in life.

FONTANELLES.

The chief fontanelles are spaces covered by membranes which lie between the incomplete angles of the parietal and the neighboring bones.[37] The anterior fontanelle (fonticulus frontalis) is situated between the frontal angles of the parietal and the postero-superior angles of the two parts of the frontal bone. It remains open until the third year. The posterior fontanelle (fonticulus occipitalis) is situated between the occipital angles of the parietal bones and the superior angle of the occipital. This fontanelle at birth is nearly obliterated, but the bones which bound it are still separated by membrane and are movable. It becomes closed between the third and sixth month. The lateral fontanelles (fonticulus mastoideus, fonticulus sphenoidalis) are situated between the sphenoidal and mastoidal angles of the parietal and the neighboring bones. The fonticulus mastoideus closes during the first half of the second year, the fonticulus sphenoidalis in the third year. The flat bones of the skull are united by definitive sutures by the end of the fourth year.[38] Special small bones (Wormian bones) may develop in the fontanelles during the process of ossification.

MAXILLA.

The human maxilla consists of two distinct parts, a medial, the incisivum (premaxilla) of lower forms, and a lateral, or maxilla proper. According to Mall (1906), each of these parts of the bone ossifies from a single centre. The two centres appear at the end of the sixth week and become united at the end of the second or early in the third month. Each of the centres gives rise to a part of the frontal process. The alveolar borders of the two bones unite before the frontal processes do. Authors differ greatly in the number of centres which they ascribe to the bone. The number given varies from two to six. Hertwig's model and

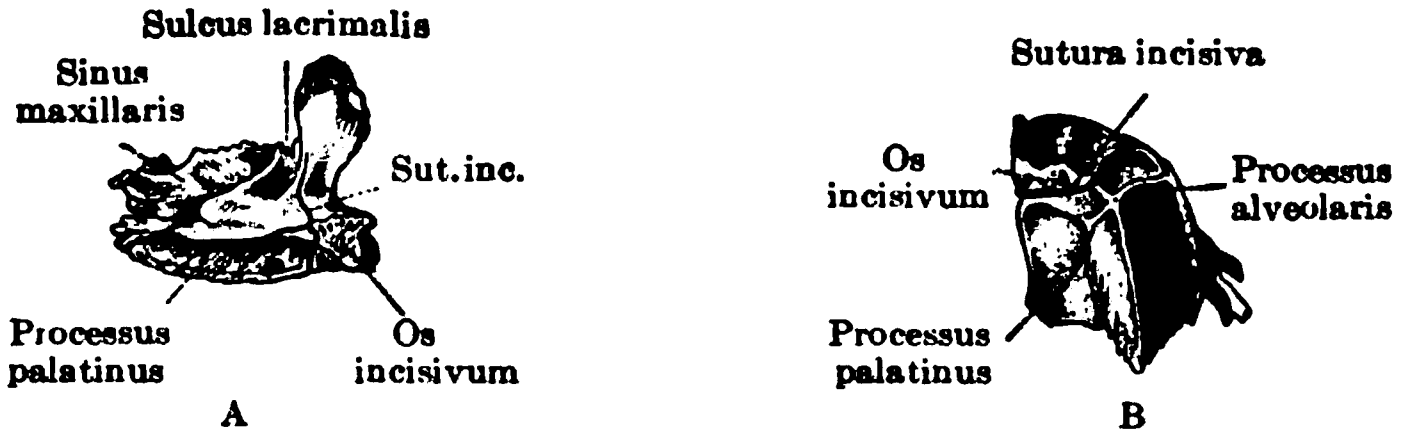

FIG. 323.—(After Toldt, Anat. Atlas, 1900, Heft 1, Figs. 176, 177.) The left maxilla of a fetus 30 cm. long. A. Medial surface. B. Inferior surface.

---

[37] For an account of the transitory sagittal fontanelle between the parietal bones see above under *Os parietale*. For the metopic fontanelle see above under *Os frontale*.

[38] For the time and order of closure of the chief fontanelles see Adachi (1900).

Schultze's illustration of the bones of the skull of an embryo of the third month are cited by Mall in support of his own observations.[39]

At first the maxilla lies lateral to the cartilaginous nasal capsule. After this cartilaginous capsule is in large part absorbed the maxilla helps to bound the nasal cavity, the maxilloturbinale becomes joined to it, some of the ethmoid cells are closed off by it, and the sinus maxillaris is formed. The formation of the alveolar process begins in the fourth fetal month and is completed after the twentieth year. According to Mihalkovics (1899), the proc. paranasalis of the nasal capsule is caught up in the ossifying maxilla. This is said to account for the islands of cartilage sometimes described in the ossifying maxilla.[40] The infraorbital nerve and vessels lie at first in a groove on the orbital surface of the maxilla, but later become enclosed by a lamina of bone which extends upwards on the lateral side, and then bends medialwards (see Fig. 321). The lateral part of the floor of the orbit and the infraorbital nerve lie at first very near the alveolar process of the maxilla. The development of the sinus maxillaris gradually serves to separate them. Compare the maxilla shown in Fig. 321 with that of an adult skull.

The sinus maxillaris at birth is represented by a slight depression on the medial surface of the maxilla opposite the second molar. After birth this depression extends laterally into the maxilla beneath the groove of the infraorbital nerve and blood-vessels. After the second dentition the sinus becomes greatly enlarged.

OS ZYGOMATICUM.

This appears on the 56th day as a small, three-cornered centre in the membranous tissue beneath and lateral to the eye (Fig. 321). On the 58th day it is four-cornered. Two of the corners give rise to processes partially encircling the orbit, one of the others extends to the maxilla, and one toward the temporal bone (Mall, 1906). From this period on, the adult form of the bone is steadily approached.[41]

---

[39] According to Le Double (1906), the number of centres described by various authors for the maxilla, including the incisivum, is as follows: One, Camper, Rousseau, Cleland; two, Jamain; three, Serres, Meckel, Cruveilhier; five, Béclard, Sappey, Leidy, Poirier, W. Krause; five or six, Portal; six, Rambaud and Renault; seven, Weber.

[40] In fetuses of the fourth to fifth month there may arise in the alveolar part small cartilaginous islands which have no connection with the nasal capsule and which disappear during the ossification of the upper jaw (Gaupp, 1906).

[41] In the adult partially or completely bipartite and tripartite malar bones are not very infrequent. In the Japanese and Ainos there is found a considerable percentage of skulls in which the malar bone is partially or completely divided by a horizontal suture (os Japanicum, os Ainoicum). Various writers differ greatly

AUDITORY OSSICLES.

These begin to ossify during the last half of the fifth month.

The *malleus* has a centre of ossification from which all parts of the bone arise except the processus anterior. This centre arises in the upper part of the collum and from here ossification spreads to the other parts. The manubrium, the last part of the bone to become ossified, reaches its definitive form before birth. The processus anterior (Folii) arises at the end of the second month as a slender membrane bone on the medial side of Meckel's cartilage. It reaches its definite length in the middle of the sixth month. The proximal end fuses with the collum mallei toward the end of the fifth month (Broman), at the time of ossification of the latter. When the malleus is ossified it becomes clearly demarcated from the rest of Meckel's cartilage. The latter slowly atrophies, and is replaced by connective tissue, which first appears at its periphery.

The *incus* is ossified from a single centre which appears in the upper part of the crus longum. Ossification extends from here into the other parts of the bone, including the processus lenticularis. The ossification begins in fetuses 19–20 cm. long and by the time of birth has reached its definitive extension (Broman).

In the *stapes,* a centre of ossification usually appears in the basal portion in fetuses 21 cm. long (Broman). From this centre the bone is ossified. The capitulum is usually ossified by the end of the sixth month.

TYMPANOHYALE.

The tympanohyale is probably derived from the cartilaginous tympanohyale described in connection with the chondrocranium, although tympanohyale and stylohyale are fused before ossification appears. Late in fetal life it is ossified from a special centre and becomes included between and fused to the petrosum and the tympanicum. It helps to bound the tympanic cavity medial to the os tympanicum.

---

in the number of centres of ossification which they ascribe to the bone. Le Double (1906) classified these writers as follows:

Those describing one centre of ossification: Meckel, Béclard, Hyrtl, Sappey, Cruveilhier, Jamain, Leidy, Baraldi, Lachi, Romiti, Langer-Toldt, Stieda, Merkel, Graf v. Spee, Hartmann.

Those describing one or two centres: Parker and Bettany.

Those describing two centres: Kerckring, Lieutaud, Garbiglietti, Macalister.

Those describing two or three centres: Morris and Rauber.

Those describing one, occasionally two, rarely three: Breschet, Gruber.

Those describing one, occasionally three: Virchow, Albrecht, Testut, Thane.

Those describing three centres: O. Schultze, Kollmann, Frassetto, Minot, Spix, Calori, Quain, Rambaud and Renault, Schrenck, Poirier, Kölliker, C. Toldt, Le Double.

STYLOHYALE.

The cartilaginous stylohyale gives rise to the styloid process. This ossifies after birth and is usually united to the tympanohyale by cartilage until middle age when it may become united to the latter by bone (Flower, 1870).

KERATOHYALE.

This is derived from the proximal part of Reichert's cartilage. It gives rise to the stylohyoid ligament. Occasionally it may become ossified and fused to the stylohyale and the lesser cornu of the hyoid.

OS HYOIDEUM.

This has five primary centres of ossification,—one for the body and one for each of the greater and each of the lesser cornua. Ossification begins in the body and greater cornua late in fetal life; in the lesser cornua some time after birth. The greater cornua and body unite in middle life. The lesser cornua are united by bone to the body of the hyoid only rarely. Usually a cartilaginous union remains throughout life. According to Rambaud and Renault, the centre in the body arises by fusion of two bilaterally placed centres. After puberty secondary centres for the tips of the greater cornua are described (Poirier, Traité d'Anatomie).

MANDIBLE.

This is ossified in the membranous tissue lateral to Meckel's cartilage. The centre of ossification may appear as early as the 39th day. By the 42d day the ramus and alveolar process may be distinguished. In a fetus 55 days old the beginnings of the coronoid process and condyle are visible. Before the end of the second month sockets for the teeth may be distinguished. By the middle of the third month the mandible has reached its characteristic shape (Mall, 1906).[42] During the development of the mandible cartilage is produced in the membranous tissue of the tip of the condyle, in the angulus, the proc. coronoideus (see Fawcett, 1904; Low, 1905), and, according to Henneberg, in traces also on the superior lateral and the medial alveolar margins and the inferior lateral margin of the jaw. This cartilage has nothing to do with Meckel's cartilage. From Meckel's cartilage, however, there may be derived the cartilage in the symphysis of the jaw in which small bones, ossicula mentalia, develop in the eighth month. There are usually two pairs, or one unpaired bone and one pair of bones. They lie in the lower portion of the symphysis

---

[42] Several investigators, among whom may be mentioned Rambaud and Renault and Wolff (1888), describe several centres of ossification for the mandible.

and after birth become fused to the mandible and help form the protuberance of the chin; see v. Mies (1893), Toldt (1905–6), v. Bardeleben (1905). According to Low (1905), Meckel's cartilage near the incisors becomes ossified and fused to the mandible. According to Fawcett (1904), Meckel's cartilage becomes ossified from the foramen mentale to the median line. The ossified cartilage becomes enclosed in membrane bone. At birth the lower jaw usually consists of lateral parts united at the symphysis by fibrous tissue. Osseous union takes place in the first or second year after birth.

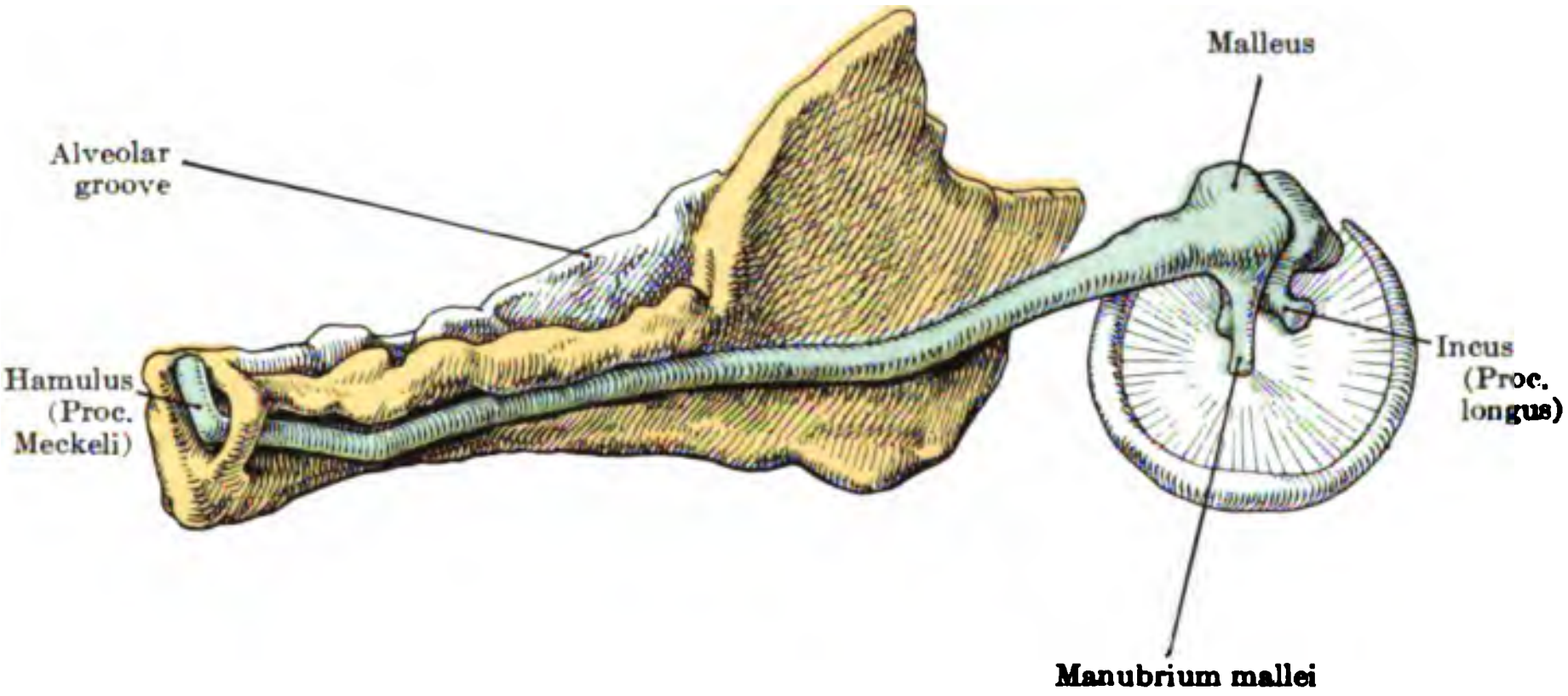

Fig. 324.—(After Kollmann, Handatlas, 1907, Fig. 273.) Mandible, Meckel's cartilage, malleus, and incus of a human fetus 8 cm. long.

TEMPOROMANDIBULAR JOINT.

This joint is developed between the membrane which covers the condyle of the mandible and the periosteum of the squamosum. In the loose tissue between the two a condensation marks the beginning of the differentiation of the discus articularis. On each side of this discus a joint cavity develops. Each joint cavity is throughout life lined by fibrous tissue. Beneath the joint periosteum of the mandible and of the temporal bone a thin layer of cartilage is produced (see Kjellberg, 1904). According to Wallisch (1906), in the new-born the tuberculum articulare is still undeveloped and the condyle is flatter than in the adult. The condyle reaches its definitive form and the tuberculum is developed after the teeth appear.[43]

---

[43] According to Fuchs (1905), the temporomandibular joint in rabbits, and hence by inference in other mammals, is homologous with the quadrato-articular joint of reptiles. As mentioned above, following Reichert, most investigators have come to the conclusion that the reptilian quadrato-articular joint is represented in mammals by the joint between the malleus and incus, while the temporomandibular joint of mammals is phylogenetically a new structure, a squamosodental joint. (See Gaupp, 1906.)

BIBLIOGRAPHY.

(On the development of the human skull. Some references are also given to the literature on the comparative embryology of the skull and on variation in cranial structure.)

Adachi, Buntaro: Uber die Seitenfontanellen. Zeitschrift für Morphol. und Anthropologie. Bd. 2. 1900.

Uber die Knöchelchen in der Symphyse des Unterkiefers. Zeitschrift für Morphol. und Anthropologie., Bd. 7, H. 2. 1904.

Appel, Kurt: Zur Lehre vom anatomischen Sitz der Hasenschartenkieferspalte. Münchner med. Wochenschrift. Bd. 9, S. 41. 1894.

Albrecht, P.: Sur les quatre os intermaxillaires, le bec-de-lièvre et la valeur morphologique des dents incisives supérieures de l'homme. Comm. Soc. d'Anthrop. de Bruxelles 1883.

Uber den morphologischen Sitz der Hasenschartenkieferspalte. Biol. Centralblatt. Bd. 6. 1886.

Anthony, R.: Contribution à l'étude de la régénération osseuse du crâne. Bull. Mém. Soc. l'Anthrop. Sér. 5, T. 7, p. 197–201. Paris 1906.

Acqua, dall, U.: Sopra lo sviluppo delle suture. Monit. Zool. Ital. Vol. 9, p. 150. 1898.

Arai, Harujiro: Der Inhalt des Canalis cranio-pharyngeus. 14 Fig. Anat. Hefte. Bd. 33, p. 411–451. 1907.

Bardeleben, Karl v.: Uber das praefrontale und postfrontale des Menschen. Verhd. der Anat. Gesellschaft auf der 10. Versammlung in Berlin. 1896. Anat. Anz. Erg. H. Bd. 12.

Der Unterkiefer der Säugetiere, besonders des Menschen. Anat. Anz. Bd. 26, S. 104–111. 1905.

Uber den Unterkiefer der Säugetiere. Sitzungsbericht der Gesellschaft naturf. Freunde Berlin. Jahrg. 1905.

Baumüller, B.: Uber die letzten Veränderungen des Meckel'schen Knorpels. Zeitschrift für wissensch. Zoologie. Bd. 32, H. 3. 1879.

Baumgarten: Beiträge zur Entwicklungsgeschichte der Gehörknöchelchen. Archiv für mikrosk. Anat. Bd. 40, S. 512. 1890.

Berkhahn, O.: Zur Entwicklung und Deutung der sogen. Azteken. — Mikrocephalen. Globus. Bd. 73. 1898.

Bessel-Hagen, F.: Vorläufige Mitteilung über die Entwicklungsgeschichte des menschlichen Occiput und die abnormale Bildung des Os occipitis. Monatsbericht der Königl. Preuss. Akademie der Wissenschaften zu Berlin aus dem Jahre 1879. S. 264. Berlin 1880.

Bianchi, S.: Sullo svilluppo della squama occipitale, sul modo di originarsi e sul modo di originarsi delle varii forme delle ossa interparietali e preinterparietali nel cranio umano. Monitore Zool. Ital. Vol. 2, p. 69–91. 1891.

Sopra alcune varieta del cranio osservate in feti umani ed in altri mammiferi. Monitore Zool. Ital. Vol. 4, p. 11–17. 1893.

Sulla divisione dell' osso parietale e sul suo sviluppo. Atti. Accad. Fisiocritici Siena. Ser. 4. Vol. 13. Anno Acad. 210. 1901.

Sullo svilluppo dell 'osso parietale umano. Arch. Ital. Anat. e Embriol. Vol. 2, p. 94–96. 1903.

Biondi, D.: Uber Zwischenkiefer- und Lippenkiefergaumenspalte. Arch. f. Anat. u. Physiol. Physiol. Abt. 1886.

Zur Hassenschartenfrage. Wiener med. Blätter. S. 7–20. 1886.

Lippenspalte und deren Komplikationen. Arch. für patholog. Anat. u. Physiol. und für klin. Medizin. Bd. 111. 1888.

Birkner, Ferd.: Das Schädelwachstum der beiden amerikan. Mikrocephalen (sog. Azteken) Maximo und Bartola. Korresp.-Bl. Deutsch. Ges. f. Anthrop. Ethnolog. Urgeschichte. Jg. 28, N. 11 u. 12. 1898.

Uber die sogen. Azteken. Arch. Anthropologie. Bd. 25. 1898.

Uber eine sehr seltene Verknöcherungsanomalie des Hirnschädels. Petrus Camper. 2. Teil, 2. Afl. 1903.

Bolk, L.: Uber eine sehr seltene Verknöcherungsanomalie des Hirnschädels. Petrus Camper. Bd. 2, Afl. 3. 1903.

Entwicklungsvorgänge in der occipitalen Region des Primordialcraniums beim Menschen. Petrus Camper. Bd. 2, Afl. 3, S. 325–327. 1903.

Zur Frage der Assimilation des Atlas am Schädel beim Menschen. Anat. Anz. Bd. 28, S. 497–506. 1906.

Bovero, Alfonso: Ossicina medio-frontali nei crani di neonati. Giorn. Acad. Med. Torino. Anno 67, Nr. 5/6. 1904.

In riposto ad una lettera aperta del dott. T Della Vedova proposito di studi sullo sviluppo delle cavita nasali. Arch. Ital. Otol. Vol. 15. 1904.

Breschet, G.: Recherches sur différentes pièces osseuses du squelette de l'homme et des animaux vertébrés. Deuxième mémoire. De l'os malaire ou jugal. Annales des Sciences Naturelles. Sér. 3, Zoologie. Vol. 1. 1844.

Broca et Lenoir: Note sur un cas de persistance du cartilage de Meckel avec absence de l'oreille externe du même côté. Considérations sur le développement du maxillaire inférieur et des osselets de l'ouie. Journ. de l'Anat. et de la Physiol. Année 32, p. 559. Paris 1896.

Brock, J.: Uber die Entwicklung des Unterkiefers der Säugetiere. Zeitschrift für wissenschaftliche Zoologie. Bd. 27, S. 287. 1876.

Broman, Ivar: Uber die Entwicklung der Gehörknöchelchen beim Menschen. Verhandl. der Anat. Gesellschaft auf der 12. Versammlung in Kiel, 1898. Dissert. Lund, 1899. Anat. Hefte. Bd. 11, H. 4.

Buhe: (1) Zwei seltene anatomische Befunde am Schläfenbein. (2) Defekt des Bulbus venæ jugularis und des sinus sigmoideus. Arch. für Ohrenheilk. Bd. 57. 1903.

Callender, G. W.: The Formation and Early Growth of the Bones of the Human Face. Philosoph. Trans. of the Royal Society of London. Vol. 159. 1870.

On the Formation of some of the Subaxial Arches in Man. Philosoph. Trans. of the Royal Soc. of London. Vol. 161. 1872.

Caselli, Arnoldo: Sulla permanenza del canale cranio-faringeo nell uomo. Gazz. di Ospedali. Anno 21; Arch. Ital. p. le Malatti Nerv. e Ment. Anno 37. Riv. sper. Freniatria. Vol. 27. 1900.

Chaine, J.: Contribution à l'étude du cartilage de Meckel. C. R. Soc. Biol. T. 55, No. 5. Paris 1903.

Chiarugi: Il terzo condilo e i processi basilari del cranio umano. (Rudimenti di un arco ipocordale occipitale). Monitore Zool. Ital. Anno 6. 1895.

Cleland, J.: On the Relations of the Vomer, Ethmoid, and Intermaxillary Bones. Phil. Trans. of the Royal Society of London. Vol. 152. 1863.

Debierre, C.: Développement du segment occipital du crâne. Journal de l'Anat. et de la Physiol. Année 31. 1895.

Dieulafé, Léon: Les fosses nasales des vértebrés (morphologie et embryologie). Journal de l'Anat. et de la Physiol. Année 40, Nr. 3, p. 268–298; Nr. 4, p. 414–444. 1904.

Dieulafé et Herpin: Développement de l'os maxillaire inférieur. Journ. de l'Anat. et de la Physiol. Année 42, p. 239–242. 1906.

L'apophyse angulaire du maxillaire inférieur (processus Sandifortii). Journ. de l'Anat. et de la Physiol. Année 43, p. 332–340. 1907.

Dixon, A. Francis: Some Specimens showing Indications of the Presence of an Occipital Vertebra. Trans. R. Acad. of Med. in Ireland. Vol. 24, p. 465. 1906.

Double, A. F. le: Le canal cranio-pharyngien, hypophysaire ou pituitaire de l'homme. Bull. et Mem. Soc. d'Anthrop. Sér. 5, T. 4. Paris 1903.

Traité des variations des os du crâne de l'homme et de leur signification au point de vue de l'anthropologie zoologique. Paris 1903.

Traité des os de la face de l'homme et de leur signification au point de vue de l'anthropologie zoologique. Paris 1906.

Dreyfuss, R.: Beiträge zur Entwicklungsgeschichte des Mittelohres und des Trommelfells des Menschen und der Säugetiere. Morphol. Arb., herausgegeben von G. Schwalbe. Bd. 2, S. 607. 1893.

Drüner, L.: Uber die Anatomie und Entwicklungsgeschichte des Mittelohres beim Menschen und bei der Maus. Anat. Anz. Bd. 24, S. 257–289. 1904.

Uber die Wirbeltheorie des Schädels. Ber. Senckenberg naturf. Gesellschaft, S. 152–156. Frankfurt 1905.

Dursy, E.: Zur Entwicklungsgeschichte des Kopfes des Menschen und der höheren Wirbeltiere. Tübingen 1869.

Engstler, G.: Uber den Lückenschädel Neugeborener und seine Beziehung zur Spina bifida. Arch. für Kinderh. Bd. 40. 1905.

Fawcett, Edward: The Ossification of the Lower Jaw of Man. Journ. of Anat. and Physiol. Vol. 39, p. xlvii–xlviii. 1905. The Lancet. Vol. 167, p. 541.

The Early Stages of the Ossification of the Pterygoid Plates of the Human Sphenoid. Proc. of the Anat. Soc. of Great Britain and Ireland, Feb., 1905. Journ. Anat. and Physiol. Vol. 39, N. S. Vol. 19, p. 6 and 7. 1905.

On the Early Stages in the Ossification of the Pterygoid Plates of the Sphenoid Bone of Man. Anat. Anz. Bd. 26, S. 280–286. 1905.

On the Development, Ossification, and Growth of the Palate Bone of Man. Journ. of Anat. and Physiol. Vol. 40, p. 400–466. 1906.

Ficalbi, Eugenio: Sulla ossificazione delle capsule periotiche nell' uomo e negli altri mammiferi. Estratti degli Atti. della Reale Academia medica di Roma. Anno 13, Ser. 2. Vol. 3, 1886–1887.

Considerazioni riassuntive sulle ossa accessorie del cranio dei mammiferi e dell' uomo. Monitore Zool. Ital. Anno 1, Nr. 7/8. 1890.

Filatoff, D.: Zur Frage über die Anlage des Knorpelschädels bei einigen Wirbeltieren. Anat. Anz. Vol. 29, S. 623. 1906.

Fischer, Eugen: Zur Kenntnis der Fontanella metopica und ihrer Bildungen. 2 Tafeln. Zeitschrift f. Morphol. und Anthropologie. Bd. 4. 1901.

Zur Kenntnis des Primordialcraniums der Affen. Anat. Anzeiger. Bd. 20, S. 410 bis 417. 1902.

Zur Vergleichung des Menschen- und Affenschädels in frühen Entwicklungsstadien. Korrespondenzblatt der Deutschen anthropol. Gesellschaft. 1902.

Zur Entwicklungsgeschichte des Affenschädels. Zeitschrift für Morphol. und Anthropologie. Bd. 5. 1903.

Demonstration von Modellen zur Vergleichung der Schädelentwicklung von Mensch und Affe mit besonderer Berücksichtigung der Nase. Verhandl. des Vereins süddeutscher Laryngologen in der Dekade 1894–1903. Würzburg 1904.

Zur Frage der Kinnbildung und Walhoff's "Theorie." Deutsche Monatsschrift für Zahnheilkunde. Jg. 23. 1905.

Fleischmann, A.: Das Kopfskelett der Amnioten. Morphogenet. Studien. Morpholog. Jahrbuch. Bd. 31. 1903.

Forster, Andreas: Beiträge zur Kenntnis der Entwicklungsgeschichte des Interparietale. 1 Tafel u. 45 Fig. Zeitschrift für Morphol. und Anthropologie. Bd. 4. 1902.

Fraser: On the Development of the Ossicula Auditus in the Higher Mammalia. Phil. Trans. Vol. 173, p. 901. 1883.

Frasetto, Fabio: Sulla probabile presenza di quatro nuclei di ossificazione nel parietale dell' uomo e delle scimmie. 4 Fig. Verh. der Anat. Gesellschaft, 14. Versammlung. Pavia 1900.

Sulla legge che governa la genesi delle suture nel cranie. Verh. der anat. Gesellschaft. 1900.

Sur les fontanelles du crâne chez l'homme, les primates et les mammifères en général. 3 Fig. C. R. du Congrès Internat. d'Anthrop. et d'Archéol. Préhist. Ser. 12. Paris 1900.

Contributo alla teoria dei quatro centri di ossificatione nell' osso parietale dell' uomo e dei primati. Bolletino dei Musei di Zoologia et Anatomia comparata delle R. Università di Torino. Vol. 17. 1902.

Le forme craniche degli Antropoidi (Simidæ) in rapporto alle umane. Atti Soc. Roman. di Anthrop. Vol. 10, Fasc. 1–3. 1904.

Parietali tripartiti in crani umani e di scimmie. Monit. Zool. Ital., Anno 15, N. 12. 1904.

Suture, fontanelle ed ossicini fontanellari del palato duro. Anat. Anz. Bd. 27. Ergänz.-Heft. Verh. d. Anat. Gesellschaft. 1905.

Frey, H.: Ein Beitrag zur Anatomie des Schläfenbeins. Arch. für Ohrenheilkunde. Bd. 48, Hft. 1 u. 2, S. 44–62. 1905.

Friedenthal, Adolph: Beitrag zur Kenntnis der embryonalen Schädelentwicklung. Diss. Königsberg 1900.

Froriep, A.: Kopfteil der Chorda dorsalis bei menschlichen Embryonen. Beiträge zur Anat. und Embryol. als Festgabe f. Jacob Henle, dargebracht von seinen Schülern. 1882.

Entwicklungsgeschichte des Kopfes. Ergebnisse der Anat. u. Entwicklungsg. Bd. 3. 1894.

Einige Bemerkungen zur Kopffrage. Ant. Anz. Ergänz.-Heft zu Bd. 21. 1902. Verhandlg. der Anat. Gesellschaft. 1902.

Fuchs, H.: Bemerkungen über die Herkunft und Entwicklung der Gehörknöchelchen bei Kaninchenembryonen. Arch. für Anat. und Physiol. Anat. Abt. Suppl.-Band, S. 1–178. 1905.

Morphologische Bedeutung des squamosum am Säugetierschädel. Zeitschrift für Morphol. und Anthropologie. Bd. 10. 1907.

Fusari, R.: A proposito di un cranio presentate l'osso parietale tripartito. Arch. Ital. Anat. e. Embriol. Vol. 2, Fasc. 3. 1903.

Sulla divisione e sulla fessura marginali dell' osso parietale nella specie umana. Arch. Sc. Med. Torino. Vol. 28, Fasc. 1. 1904.

Ganfini, C.: Sopra alcune faccette articolari del basioccipitale in rapporto ai processi basilari. Monit. Zool. Ital. Anno 17, p. 60–68. 1906.

Gaupp, E.: Ontogenie und Phylogenie der schalleitenden Apparate bei den Wirbeltieren. Ergebnisse der Anat. u. Entwicklungsgesch. Bd. 8. 1899.

Alte Probleme und neuere Arbeiten über den Wirbeltierschädel. 5 Fig. Ergebnisse der Anat. u. Entwicklungsgesch. Bd. 10. 1901.

Uber die Ala temporalis des Säugeschädels und die Regio orbitalis einiger anderer Wirbeltierschädel. Anat. Hefte. Bd. 19. 1901.

Uber die Ala temporalis des Säugetierschädels. Verhandlung der Anat. Gesellschaft. 1901.

Zum Verständnis des Säuger- und Menschenschädels. Korresp.-Bl. d. deutsch. Anthropol. Gesellschaft. Nr. 12. 1903.

Die Nichthomologie des Unterkiefers in der Wirbeltierreihe. Verhandlg. d. Anat. Gesellschaft. 1905. Anat. Anz., Ergänzungsheft. Bd. 27. 1905.

Neue Deutungen auf dem Gebiete der Lehre vom Säugetierschädel. Anat. Anz. Bd. 27. 1905.

Das Hyobranchialskelett der Wirbeltiere. 46 Fig. Ergebnisse der Anat. und Entwicklungsg. Bd. 14, S. 808–1048. 1905.

Die Entwicklungsgeschichte des Kopfskelettes. Hertwig's Handbuch. 1906.

Uber allg. und spez. Fragen aus der Lehre vom Kopfskelett der Wirbeltiere. Anat. Anz., Ergänzungsheft. S. 21. 1906.

GEGENBAUR, C.: Uber die Pars facialis des Lacrymale des Menschen. Morphol. Jahrb. Bd. 7. 1882.

GEMMILL, J. F.: On the Origin of the Stapes and on its Continuity with the Hyoid Arch. Rep. 71st meeting Brit. Ass. Advanc. Sc. Glasgow. 1901.

GIUFFRIDA-RUGGERI: Sul significato delle ossa fontanellari e dei foramini parietali e sulla pretesa penuria ossea del cranio umano. Atti Soc. Rom. di Antrop. Vol. 7, p. 81–92. 1901.

GRADENIGO, G.: Die embryonale Anlage des Mittelohres. Die morphologische Bedeutung der Gehörknöchelchen. Mitteilungen aus dem embryol. Institut der k. u. k. Universität Wien. 1887.

GRUBER, J.: Beitrag zur Entwicklungsgeschichte des Steigbügels und ovalen Fensters. Mitteilung aus dem embryol. Institut der k. u. k. Universität in Wien. 1877. Monatsschrift für Ohrenheilkunde. 1878.

GÜLKE, KARL: Verlauf und Verknöcherung der Stirnnaht. Diss. med. Göttingen 1904.

GÜNTHER, A. FR.: Beobachtung über die Entwicklung des Gehörorgangs bei Menschen und höheren Säugetieren. Leipzig 1842.

HAMMAR, J. AUG.: Studien über die Entwicklung des Vorderdarms und einiger angrenzenden Organe. Arch. für mikr. Anat. Bd. 59. 1902.

HAMY, E. T.: De l'ostéogénie du frontal chez l'homme, à propos d'une double anomalie d'ossification de cet os observé chez. un monstre notencéphale. Bull. du Mus. d'Histor. Nat. 1900.

HANNOVER, ADOLPH: Primordialbrusken og dens Forbening i det meneskelige Kranium for Fodselen. Danske Videnskabernas Selskabs Skrifter. Vol. 11, p. 349–528. 1880.

Le cartilage primordial et son ossification chez le crâne humain avant naissance. Copenhague 1881.

HASSE, C.: Anatomische Studien. Entwicklung des Atlas. Leipzig 1872.

HEGETSCHWEILER, J.: Die embryologische Entwicklung des Steigbügels. 2 Tafeln. Arch. für Anat. u. Physiol., Anat. Abt., Jahrg. 1898, S. 37.

HEITZMANN, CARL, und BOEDECKER, C. F. W.: The Earliest Development of the Lower Jaw-bone. Dental Cosmos. Vol. 37. 1895.

HENNEBERG, B.: Beiträge zur Entwicklungsgeschichte des Unterkiefers beim Menschen. Med. Inaug. Diss. Berlin 1894.

HOLL, M.: Uber die Bildung des Gesichtsschädels. Verhandlg. der Gesellschaft deutscher Naturforscher u. Arzte. 1894.

HRDLICKE, ALES.: Division of the Parietal Bone in Man and Mammals. Bull. Americ. Mus. Nat. Hist. Vol. 19, p. 231. 1903.

HYRTL: Uber wahre und falsche Schaltknochen in der Pars orbitaria des Stirnbeines. Sitzungsbericht der k. Akademie d. Wissensch. zu Wien. Math. Naturwissensch. Kl. Bd. 42, Jhrg. 1860.

IHERING, H. v.: Die Entwicklungsgeschichte des menschlichen Stirnbeines. Arch. für Anat. u. Physiol. u. wiss. Medizin. S. 649–658. Jahrg. 1872.

JACOBSON: On Primordial-Craniet. Verhandlg. der Skandinavischen Naturforsch. Vers. Stockholm 1842.

JACOBY, MARTIN: Ein Beitrag zur Kenntnis des menschlichen Primordialkraniums. Arch. für mikr. Anat. Bd. 44, S. 61–86. 1895.

JOSEPH, L.: Osteologischer Beitrag über das Schläfenbein und den in ihm enthaltenen Gehörapparat. Zeitschrift für rationelle Medizin. Bd. 28. 1866.

JURASZ, A.: Eine seltene Anomalie des Schildknorpels und dessen Verbindung mit dem Zungenbein. Arch. für Anat. u. Entwicklungsg. S. 399–400. 1877.

Kallius, E.: Beiträge zur Entwicklungsgeschichte des Kehlkopfes. Anat. Hefte. Bd. 9, S. 301. 1897.

Kampen, van: Die Tympanalgegend des Säugetierschädels. Morph. Jahrb. Bd. 34, S. 321–422. 1905.

Kazzander, J.: Notiz über die Pneumatisation des Schläfenbeins beim Menschen. Anat. Anz. Bd. 26. 1905.

Keibel, Franz: Zur Entwicklungsgeschichte der Chorda bei Säugern. Arch. für Anat. u. Physiol. Anat. Abt. Jahrg. 1889.

Kerckring, Theod.: Spicilegium anatomicum continens osteogeniam foetuum. Amstelodami 1670.

Kikuthi, J.: Der histologische Bau der Knochenblasen in der Nase nebst Bemerkungen über Wachstum und Entstehung derselben. Arch. für Laryngol. u. Rhinologie. Bd. 14, Heft 6. 1903.

Killian, G.: Zur Anatomie der Nase menschlicher Embryonen. Arch für Laryngologie. Bd. 2, Heft 2. 1895; Bd. 3, Heft 1 und 2. 1895; Bd. 4, Heft 1. 1896.

Kjellberg, Knut: Beiträge zur Entwicklungsgeschichte des Kiefergelenks. Morpholog. Jahrbuch. Bd. 32. 1904.

Kölliker, Th.: Zur Anatomie der Kieferspalte. Arch. für klin. Chirurgie. Bd. 26. 1881.

Zur Zwischenkieferfrage. Centralblatt f. Chir. Jahrg. 11. 1884.

Zur Odontologie der Kieferspalte bei der Hasencharte. Biolog. Centralblatt. Nr. 12. 1885.

Kollmann, J.: Deux espèces des variations corrélatives de la crâne faciale de l'homme. Assoc. Franc. Avanc. Sc. Rouen. 1883.

Varianten am os occipitale besonders in der Umgebung des Foramen occipitale magnum. Verhandl. d. Anat. Gesellschaft. 1905. Anat. Anz. Erg. H. Bd. 30, S. 545–563. 1907.

Der Canalis cranio-pharyngeus. Verh. d. Anat. Ges. Jena. 1904. Anat. Anz. Erg. H. Bd. 25, 1904.

Küss, G., et Pissot, L.: D'un prolongement constant observé sur les cartilages latéraux du nez de l'embryon humain. Bibliogr. Anat. Vol. 7. 1899.

Küstner, Otto: Uber Trigonocephalie. Ein Beitrag zur Lehre von den fetalen Schädelsynostosen. Virchow's Arch. Bd. 83. 1881.

Landzert, Th.: Uber den Canalis cranio-pharyngeus am Schädel des Neugeborenen. St. Petersburger med. Zeitschrift. Bd. 14. 1868.

Centralblatt f. d. med. Wissenschaft. 1869.

Leche: Das Vorkommen und die morphologische Bedeutung des Pfannenknochens (os acetabuli). Internat. Monatschr. f. Anatomie u. Histologie. S. 363, 1884.

Langnick: Untersuchungen über das os Kerckringi. Inaug. Diss. Königsberg i. Pr. 1898.

Leuckart, Friedr. S.: Untersuchungen über den Zwischenkiefer beim Menschen in seiner normalen und abnormalen Metamorphose. Stuttgart 1840.

Levi, Guiseppe: Beitrag zum Studium der Entwicklung des knorpeligen Primordialcraniums des Menschen. Arch. für mikr. Anat. und Entwicklungsg. Bd. 55. 1900.

Low, Alex.: On the Development of the Lower Jaw in Man. Proc. Anat. Soc. Great Britain and Ireland. May 1905. Journ. Anat. and Physiol. Vol. 39. 1905.

Lubosch, W.: Die Stammesgeschichtliche Entwicklung der Synovialhaut und der Sehnen mit Hinweisen auf die Entwicklung der Kiefergelenhe der Säugetiere Biol. Zentralbl. Bd. 28, S. 678–697. 1908.

Luschka, H.: Das Nebentränenbein des Menschen. Arch. für Anat., Physiol. und wissensch. Med. Jahrg. 1858.

MACALISTER, A.: Notes on the Varieties and Morphology of the Human Lachrymal Bone and its Accessory Ossicles. Proc. Royal Soc. of London. Vol. 36. 1884 and Vol. 37. 1884.

MAGGI, LEOPOLDO: Centri di ossificazione e principali varieta morphologische degli interparietali nell' uomo. Rendiconti del R. Inst. Lomb. di Scienze e Lettere. Ser. 2. Vol. 29. 1896.

Centres d'ossifications et principales variétés morphologiques des interpariétaux chez l'homme. Arch. Ital. de Biol. Vol. 26. 1896.

Resultati di ricerche morfologische intorno ad ossa e fontanelle del cranio umano. Comm. preventura. Rend. Instit. Lomb. Scienze e Letteri. Vol. 29. 1896.

Résultats de recherches morphologiques sur des os et des fontanelles du crâne humain. Comm. préventure. Arch. Ital. de Biol. Vol. 27, Fasc. 2. 1897.

Altri resultati di ricerche morphologiche intorno ossa craniali, craniofaciali e fontanelle dell' uomo ad altri mammiferi. Rend. dell' Instit. Lomb. Ser. 2. Vol. 30. Milano 1897.

Autres résultats de recherches morphologiques sur des os craniens et craniofaciaux et sur des fontanelles de l'homme et d'autres mammifères. Arch. Ital. de Biol. Vol. 30, Fasc. 2. 1898.

Suture ed ossa interparietali nell' cranio umano di bambino e di adulto. Rendiconti R. Istit. Lomb. di Scienze e Lettere. Ser. 2. Vol. 37, Fasc. 9. 1904.

MAGITOT, E., ET ROBIN, CHR.: Mémoire sur un organe transitoire de la vie foetale désigné sous le nom de cartilage di Meckel. Annales des Sciences Naturelles, 4 Serie, Zoologie. T. 18. 1862.

MARTINI, VIT.: Sullo sviluppo delle ossa piatte secondarie del cranio de connettivo e sulla loro rigenerazione dopo la trapanazione. R. Univ. Siena, 36 pp. 1886.

MASQUELIN, H.: Recherches sur le développement du maxillaire inférieur de l'homme. Bull. d. l'Acad. Royale des Sciences, des Lettres et des Beaux-Arts de Belgique, p. 371–376. 1878.

MATIEGKA: Uber das "Os malare bipartitum." Anat. Anz. Bd. 16. 1899.

MAYET: Quelques considérations sur le développement du conduit auditif externe. Bull. de la Soc. Anat. de Paris. Année 69. 1904.

MEAD, C. S.: Chondrocranium of an Embryo Pig. Amer. Jour. of Anat. Vol. 9, pp. 167–210. 1909.

MECKEL, J. F.: Uber die Zwickelbeine am menschlichen Schädel. Beitrag z. vergl. Anat. Bd. 1, H. 2. 1809.

Handbuch der menschlichen Anatomie. Bd. 2. Besondere Anatomie, Knochenlehre, Bänderlehre, Muskellehre. 1816. Bd. 4. Eingeweidelehre und Geschichte des Fetus. 1820.

MENDEN, J.: Beitrag zur Casuistik der Ossificationsdefecte am Schädel des Neugeborenen. Marburg 1875.

MEYER, H. v.: Der Zwischenkieferknochen und seine Beziehungen zur Hasencharte und zur schrägen Gesichtspalte. Deutsche Zeitschrift f. Chirurgie. Bd. 26. 1884.

MIES, JOSEPH: Uber die Knöchelchen in der Symphyse des Unterkiefers von neugeborenen Menschen (Ossicula mentalia). Anat. Anz. Bd. 8. 1893.

MIHALKOVICS, VICTOR v.: Wirbelsaite und Hirnanhang. Arch. f. mikr. Anat. Bd. 11. 1875.

Bau und Entwicklung der pneumatischen Gesichtshöhlen. Verh. d. Anat. Ges. 10. Vers. Berlin 1896.

Anatomie und Entwicklungsgeschichte der Nase und ihrer Nebenhöhlen. Heymann's Handb. der Laryngol. u. Rhinologie. Bd. 3. 1896.

Nasenhöhle und Jacobson'sches Organ. Anat. Hefte. Bd. 11, H. 1/2. 1899.

Miloslawski, Fr. W.: Die Stirnhöhlen. Eine anatomisch-topographische und craniologische Untersuchung. Diss. med. Moscow. Ref. in Stieda's 6. Bericht in: Ergebn. Anat. und Entwicklungsg. Bd. 13. 1903.

Moldenhauer: Beiträge zur Anatomie und Entwicklungsgeschichte des menschlichen Gehörorgans. Arch. f. Ohrenheilk. Bd. 11. 1876.

Mouret, Jules: Rapports du sinus frontal avec les cellules ethmoidales. 22 Fig. Bull. et Mém. de la Soc. Franc. d'Otol., de Laryngol. et de Rhinol. Congrès 1901.

Müller, Heinrich: Uber das Vorkommen von Resten der Chorda dorsalis bei Menschen nach der Geburt und über ihr Verhältnis zu den Gallertgeschwülsten am Clivus. Zeitschr. f. rationelle Medizin. 3. Reihe. Bd. 2. 1858.

Munch, F. E.: Uber die Entwicklung des Knorpels des äusseren Ohres. Morph. Arb. Bd. 7, S. 583. 1897.

Musumeci: Sopra un caso singulare di terzo condilo. Monitore Zool. Ital. 1900.

Nicola, Beniamino: Sullo sviluppo, sui canali perforanti e sulle fessure della porzione laterale dell' ala magna dell' os sfenoidale nella specie umana. Mem. Accad. Sc. Torino. Ser. 2. V. 56, pp. 117–146. Torino 1906.

Nicolas, A.: Recherches sur le développement de quelques éléments du larynx humain. Bibliographie anatomique. No. 5, p. 176–190. 1894.

Noorden, W. van: Beitrag zur Anatomie der knorpeligen Schädelbasis bei menschlichen Embryonen. Arch. f. Anat. u. Physiol. Anat. Abt. S. 241–257. 1887.

Olii: How many Months does the Larger Fontanelle of the Japanese Infant Require to Close? The Tokio Jji-Shinoki. Nr. 1175. 1900.

Papillault, G.: Ontogénèse et phylogénèse du crâne humain. 8 Fig. Rev. école d'anthrop. Nr. 4, p. 105–153. Paris 1899.

Paravicini, G.: Di alcune nuove ossicina suturofontanellari del cranio umano giovano ed adulti, appartenente ad alienati ed a normali. R. Ist. Lomb. di Sc. e Lett., Ser. 2, Vol. 35. 1902.

Pariselle, H.: Des fontanelles: anatomie et pathologie. Thèse de doctorat en méd. Paris 1900.

Patel: Sinus frontaux et cellules ethmoidales anormalement développés. Lyon med., p. 319–320. 1902.

Paulisch, Otto: Das vordere Ende der Chorda dorsalis und der Frank'sche Nasenkamm. Arch. f. Anat. u. Physiol. Anat. Abt. 1887.

Pauli, Simon: Uber Pneumaticität des Schädels bei den Säugetieren. Morphol. Jahrb. Bd. 28, H. 4. 1900.

Perna, Giovanni: Die Nasenbeine. Eine embryologische und vergleichend-anatomische Untersuchung. Arch. f. Anat. u. Physiol. Anat. Abt. S. 119–154. 1906.

Peter, Karl: Anlage und Homologie der Muscheln des Menschen und der Säugetiere. Arch. f. mikr. Anat. u. Entwicklungsg. Bd. 60. 1902.

Pölzl, Anna: Zur Entwicklungsgeschichte des menschl. Gaumens. Anat. Hefte. Bd. 27, S. 243–283. 2 Taf., 13 Fig. 1904.

Politzer, A.: Zur Anatomie des Gehörorgans. 2. Uber den Processus styloïdeus. Arch. f. Ohrenheilk. Bd. 4. 1875. Beitr. z. Anat. u. Physiol. als Festgabe f. Carl Ludwig. Leipzig 1875.

Ranke, Johannes: Der Stirnfortsatz der Schläfenschuppe bei den Primaten. Sitzungsberichte der math.-phys. Klasse der k. Bayr. Akad. der Wissenschaften zu München. Bd. 28. 1899.

Die überzähligen Hautknochen des menschlichen Schädeldaches. Abhandlungen der k. Bayr. Akademie der Wiss. 2. Klasse. Bd. 20. München 1900.

Rauber, A.: Schläfenbein des Menschen, ohne pars tympanica, mit Hammerrudiment. Morpholog. Jahrbuch. Bd. 38, S. 1. 1907.

Regnault, Felix: Oblitération prématurée des sutures crâniennes, mécanisme des déformations. 2 Fig. Bull. et Mém. de la Soc. d'Anthrop. de Paris. Sér. 5, Vol. 1. 1900.

Reichert, C.: Uber die Visceralbogen der Wirbeltiere im allgemeinen und deren Metamorphose bei den Vögeln und Säugetieren. Müller's Archiv f. Anat., Physiol. und wissensch. Mediz. 1837.

Rizzo, Agostino: Canale cranio-faringeo, fossetta faringea, interparietali e preinterparietali nel cranio umano. Monit. Zool. Ital., Anno 12, p. 241–252. 1901.

Rousseau, Emmanuel: Description d'un nouvel os de la face chez l'homme (" lachrymal externe ou petit unguis "). Annales des Sciences Naturelles. Vol. 17. 1829.

Rüdinger: Uber die Bildung der Känäle und Hohlräume im menschlichen Schläfenbein. Beiträge zur Anatomie des Gehörorgans. München 1876.

Ruge, G.: Beiträge zum Wachstum des menschl. Unterkiefers. Inaug. Diss. Berlin 1875.

Saint-Remy, G.: Recherches sur l'extrémité antérieure de la corde dorsale chez les amniotes. Archives de Biologie. T. 14. 1896.

Schaeffer, Oskar: Untersuchungen über die normale Entwicklung der Dimensionsverhältnisse des fetalen Menschenschädels. 51 pp. München und Leipzig 1892.

Schaffer, J.: Die Verknöcherung des Unterkiefers und die Metaplasiefrage. Arch. f. mikr. Anat. Bd. 32, S. 266–387. 1888.

Zur Histologie, Histogenese und phylogenetischen Bedeutung der Epiglottis. Anat. Hefte. Bd. 38, S. 455–490. 1907.

Schattauer, F.: Beitrag zur Kenntnis der Mikrognathie. Diss. Königsberg 1903.

Schenk, Fr.: Die erste Anlage des Unterkiefers und der Zahnalveolen. S.-B. K. Akad. der Wiss. Wien, Math.-Naturw. Kl. Bd. 105. 1896.

Vierteljahrsschrift f. Zahnheilk. Jahrg. 12. 1896.

Schlaginhaufen, Otto: Ein Canalis craniopharyngeus persistens an einem Menschenschädel und sein Vorkommen bei den Anthropoiden. Anat. Anz. Bd. 30, S. 1. 1907.

Schmidt, E.: Uber das postembryonale Weiterbestehen des Jacobson'schen Organs und Knorpels beim Menschen und die Beziehung derselben zueiander. Diss. d. Med. Fakultät. Berlin 1896.

Schönemann, A.: Beitrag zur Kenntnis der Muschelbildung und des Muschelwachstums. Anat. Hefte. Bd. 18, H. 1. 1901.

Schumacher, Siegm. v.: Hämalbogen bei menschl. Embryonen. Anat. Anz. Bd. 29. Ergh. S. 173–178. 1906.

Ein Beitrag zur Frage der Manifestation des Occipitalwirbels. Anat. Anz. Bd. 31, S. 145. 1907.

Schwalbe, E.: Entstehung der Hasenscharte nach der Anschauung des vorigen Jahrhunderts. Münch. med. Wochenschrift. 1899.

Schwalbe, G.: Uber die Nasenmuscheln der Säugetiere und des Menschen. Sitzungsber. d. Physik.-Ökon. Ges. zu Königsberg. 1882.

Uber accessorische Schädelknochen des Menschen und accessorische Schädelnähte. Wiener klin. Wochenschrift. 1899.

Uber die Fontanella metopica und ihre Bildung. Zeitschr. f. Morphol. u. Anthropologie. Bd. 3, H. 1. 1901.

Uber den supranasalen Teil der Stirnnaht. Zeitschr. f. Morphol. und Anthropologie. 1901.

Uber geteilte Scheitelbeine. Zeitschr. f. Morphol. und Anthropologie. Bd. 6, S. 361–434. 1903.

Uber die Stirnnaht bei den Primaten. Zeitschr. f. Morphol. u. Anthropologie. Bd. 7. 1904.

SCHWEGEL, ANDR.: Knochenvarietäten. Zeitschr. f. ration. Med. Bd. 5. 1859.

SERGI, G.: Le forme del cranio umano nello sviluppo fetale in relazione alle forme adulte. Rev. de Sc. Biol., Anno 2, p. 401–413, p. 831–847. 1900.

SEYDEL, O.: Uber die Nasenhöhle der höheren Säugetiere und des Menschen. Morphol. Jahrb. Bd. 17. 1891.

SIEBENMANN: Die ersten Anlagen vom Mittelohrraum und Gehörknöchelchen des menschlichen Embryo in der vierten bis sechsten Woche. Arch. f. Anat. u. Physiol. Anat. Abt. S. 355. Jahrg. 1894.

Mittelohr und Labyrinth. Bardeleben's Handb. der Anat. des Menschen. Bd. 5, 2. Abt. Jena 1897.

SIMON, MAX: Uber angeborene knöcherne Choanalatresie im Anschluss an zwei neue Fälle. Inaug.-Diss. Leipzig 1897.

SMITH, G. ELLIOTT: On a Case of Fusion of the Atlas and Axis. Anat. Anz. Bd. 31, S. 166–168. 1907.

SOKOLOW, PAUL: Der canalis craniopharyngeus. Arch. f. Anat. u. Physiol. Anat. Abt. 1904.

SOULIÉ, A., ET BARDIER, E.: Recherches sur le développement du larynx. Journ. de l'Anat. et de la Physiol. Vol. 43, p. 219. 1907.

SOUQUES ET HELLER: Paralysie faciale congénitale par agénésie du rocher. Arch. Internat. d'Otol. 1903.

SPARREL, H., and GEORGE, F.: The Articulation of the Vertebrate Jaw. Proc. Zool. Soc. London. Vol. 1, p. 114–123. 1906.

SPEE, F. GRAF V.: Kopf. Bardeleben's Handbuch der Anatomie des Menschen. Bd. 1, Abt. 2. Jena 1896.

SPERINO, G.: La ossificazione e la posizione della trochlea del musculus obliquus sup. oculi, la spina e la fovea trochlearis. Mem. R. Accad. di Scienze Lettere ed Arti Modena. Ser. 3. Vol. 6. Modena 1905.

SPÖNDLI, HEINRICH: Uber den Primordialschädel der Säugetiere und des Menschen. Inaug.-Diss. Zürich 1846.

SPURGAT, F.: Beiträge zur vergl. Anat. der Nasen- und Schnauzenknorpel des Menschen und der Tiere. Morphol. Arb. Bd. 5, H. 3. 1896.

STADERINI, R.: Intorno alle prime fasi di sviluppo dell Anulus stapedialis. Monit. Zool. Ital. Vol. 2, Anno 2. 1891.

STAURENGHI, C.: Ricerche intorno all' ossificazione della squama dell' occipitale umano, a proposito di un exemplare di os incae tripartitum. Gazz. Med. Lomb., Anno 56. 1897. 2 Titel. Communicazioni preventive di craniologia. 4. Dell' ossificazione del frontale umano. Gazz. Med. Lomb., Anno 57. 1898.

Dell' esistenza di ossa pre- e postfrontali nel cranio umano e dei mammiferi, con un' appendice sulla questione dell' osso sfenotico dei mammiferi. Ref. in Monit. Zool. Ital., Anno 2. Milano 1891.

Contribuzione alla osteogenesi dell' occipitale umano a dei mammiferi con una nota sullo sviluppo del frontale e del parietale dell' uomo. 5 Taf. Pavia 1899.

STEINER, F.: Uber die Entwicklung der Stirnhöhlen und deren krankhafte Erweiterung durch Ansammlung von Flüssigkeiten. Arch. f. klin. Chir. Bd. 13. 1872.

STERNBERG, M.: Ein bisher nicht beschriebener Kanal im Keilbein des Menschen. Anat. Anz. Jahrg. 3. 1888.

Ein bisher nicht beschriebener Kanal im Keilbein des Menschen und mancher Säugetiere. Arch. f. Anat. u. Physiol. Anat. Abt. 1890.

STIEDA, HERMANN: Die Anomalien der menschl. Hinterhauptsschuppe. Anat. Hefte. Bd. 2. 1892.

STIEDA, L.: Uber die Stirnnaht und den Stirnfontanellenknochen. C. R. 12. Congr. Intern. Méd., Moscou 1897. T. 2. 1899.

Strasser, H.: Sur le développement des cavités nasales et du squelette du nez. Arch. des Sc. Phys. et Nat. Genf. 1901.

Sutton, J. Bland: Observations on the Parasphenoid, the Vomer and the Palatopterygoid Arcade. Proceedings Zool. Soc. London 1884.

On the Relations of the Orbito-Sphenoid to the Region Pterion in the Side Wall of the Skull. Journ. of Anat. and Physiol. Vol. 18. 1884.

On the Development and Morphology of the Human Sphenoid Bone. Proceedings Zool. Soc. London 1885.

Swjetschnikow: Uber die Assimilation des Atlas und die Manifestation des Occipitalwirbels beim Menschen. Arch. f. Anat. u. Physiol. S. 155–194. 1906.

Symington: On the Relations of the Larynx and Trachea to the Vertebral Column in the Fœtus and Child. Journ. of Anat. and Physiol. Vol. 9, p. 3. 1875.

Tenchini, Lorenzo: Sopra il canale infra-squamoso di Gruber nell' uomo. Arch. Ital. Anat. e Embriol. Vol. 3. 1904.

Tenchini, L., e. Zimmerl, U.: Sopra i ossa detti "Wormiani" della fossa cranii anteriori nell' uomo. Parma 1902.

Thoma, R.: Synostosis suturae sagittalis cranii. Ein Beitrag zur Histomechanik des Skeletts und zur Lehre von dem interstitiellen Knochenwachstum. Virchow's Arch. Bd. 188. 1907.

Thomson, Arthur: The Orbito-maxillary Frontal Suture in Man and the Apes, with Notes on the Varieties of the Human Lacrymal Bone. Journ. of Anat. and Physiol. Vol. 24. 1890.

Toldt, C.: Osteologische Mitteilungen. 1. Die Entstehung und Ausbildung der conchae und der sinus sphenoidales beim Menschen. 2. Uber die Entwicklung des Scheitelbeines beim Menschen. Lotos. Jahrb. f. Naturwiss. N. F. Bd. 3 und 4. Prag 1882.

Uber die Entwicklung des Scheitelbeines des Menschen. Prager Zeitschr. f. Heilk. Bd. 4. 1883.

Uber die Kinnknöchelchen und ihre Bedeutung f. die Kinnbildung beim Menschen. Korresp.-Bl. d. Deutsch. Ges. f. Anthrop. u. Ethnol. Urgeschichte. Jahrg. 36, S. 115–118. 1905.

Die ossicula mentalia und ihre Bedeutung f. die Bildung des menschlichen Kinnes. S. B. K. Accad. Wiss. in Wien. Bd. 114, Abt. 3. Wien 1905.

Zur Frage der Kinnbildung. Korresp.-Bl. d. deutsch. Ges. f. Anthropol. u. Ethnol. Urgeschichte. Jahrg. 37, S. 9–17. 1906.

Toldt, Karl, Jr.: Entwicklung und Struktur des menschlichen Jochbeines. Sitzungsber. d. kais. Akad. d. Wiss. in Wien, Mathem.-naturwiss. Klasse. Bd. 109, Abt. 3. S. 562–569. 1902.

Varietäten des menschlichen Jochbeines im Lichte der Entwicklungsgeschichte. Verh. d. Ges. deutsch. Naturf. u. Aerzte. Vers. 74. Bd. 2, S. 182–185. 1903.

Die Querteilung des Jochbeines und andere Varietäten derselben. Sitzungsb. d. kais. Akad. d. Wiss. in Wien. Mathem. naturwiss. Klasse. Bd. 112, Abt. 3. 1903.

Tomes, C. S.: Studien über das Wachstum der Kieferbeine. Jahrbuch f. Zahnheilk. Jahrg. 7, Nr. 9 und 10. 1892.

Toyo, C.: Le forme dell cranio nello sviluppo fetale. Atti. Soc. Roman. Antropol. Vol. 11. 1905.

Virchow, Rudolph: Untersuchungen über die Entwicklung des Schädelgrundes im gesunden und krankhaften Zustande und über den Einfluss deselben auf Schädelform. Gesichtsbildung and Gehirnbau. Berlin 1857.

Voit, Max: Das chondrocranium und die Deckknochen von lepus cuniculus. Anat. Hefte, Bd. 38 (116 Heft) 192 Stn. mit 16 Tafeln, 1909; also Freiburger Habilitationsschrift.

Vrolik, A. J.: Studien über die Verknöcherung und die Knochen des Schädels der Teleostier. Niederländ. Arch. f. Zool. Bd. 1. 1873.

Walkhoff: Der menschliche Unterkiefer im Lichte der Entwicklungsmechanik. Deutsch. Monatsschr. f. Zahnheilk. Jahrg. 18, S. 529–538. 1900; Jahrg. 19, S. 111-121. 1901.

Die heutigen Theorien der Kinnbildung. Deutsch. Monatsschr. f. Zahnheilk. Jahrg. 23, S. 580–592. 1905.

Wallisch: Das Kiefergelenk. Arch. f. Anat. u. Physiol. Anat. Abt. S. 303–310. 1906.

Warynski: Contribution à l'étude du bec de lièvre simple et complexe. Virchow's Arch. Bd. 112, p. 507–536. 1888.

Weber, A.: Evolution de la région pterygoide, chez l'homme. C. R. Soc. Biol. Paris. T. 58, p. 1083–1084. 1905.

L'orientation des ailes des apophyses pterygoides chez les primates. C. R. Soc. Biol. Paris. T. 59, p. 225–227. 1905.

Les apophyses pterygoides du crâne de l'homme. Développement, orientation, variation. Bibliog. Anat. T. 15, p. 57–84. 1906.

Les variations ethniques du trou ovale du sphénoide humain. Bibliogr. Anat. Paris 1906.

Weidenreich, Franz: Die Bildung des Kinnes und seine angebliche Beziehung zur Sprache. Anat. Anz. Bd. 24. 1904.

Die Kinnbildung beim Menschen. Anat. Anz. Bd. 25. 1904.

Walkhoff's Theorie der Kinnbildung. Deutsche Monatsschrift f. Zahnheilk. Jahrg. 23, S. 747–752. 1905.

Welker, H.: Uber Wachstum und Bau des menschl. Schädels. Leipzig 1862.

Wichert, Paul: Uber den Canalis ethmoidalis. Med. inaug. Diss. Königsberg 1891.

Williams, L. W.: The Later Development of the Notochord in Mammals. Amer. Jour. of Anat. Vol. 8, p. 251–284. 1908.

Wolff, J.: Uber das Wachstum des Unterkiefers. Virchow's Arch. Bd. 114, S. 493 bis 547. 1888.

Zabel, E.: Varietäten und vollständiges Fehlen des Tränenbeins beim Menschen. Anat. Hefte. Bd. 15, S. 153–201. 1900.

Zander, Richard: Beiträge zur Morphologie der Dura mater und zur Knochenentwicklung. Festschr. z. 70. Geburtstag von Carl v. Kupffer. 1899.

Zanotti: La fontanella metopica ed il suo significato. Bolletino Science Mediche Bologna. Ser. 8, Vol. 2. 1902.

Zondek, M.: Beiträge zur Entwicklungsgeschichte der Gehörknöchelchen. Arch. f. mikr. Anat. u. Entwicklungsg. Bd. 44, S. 499. 1895.

Zuckerkandl, C.: Zur Anatomie und Entwicklungsgeschichte der Nasoethmoidalregion. Medic. Jahrb. Herausg. v. d. k. u. k. Gesellsch. d. Aerzte. Wien 1878.

Normale und pathologische Anatomie der Nasenhöhle und ihrer pneumatischen Anhänge. Bd. 1. Wien 1882.

Uber die morphologische Bedeutung des Siebbeinlabyrinthes. Wien. med. Wochenschrift. Bd. 37. Wien 1887.

Die Siebbeinmuscheln des Menschen. Anat. Anz. Jahrg. 7. 1892.

Die Entwicklung des Siebbeins. 6. Verhandlg. d. Anat. Gesellschaft. (Wien) Anat. Anz. Bd. 7. Erg.-H. S. 261-264. 1892.

Anat. norm. et path. des fosses nasales. Trad. franç. Paris 1895.

Geruchsorgan. Ergebn. d. Anat. u. Entwicklungsgesch. Bd. 2. 1893.

Anatomie und Entwicklungsgeschichte des Kehlkopfes und der Luftröhre. Handbuch der Laryngologie und Rhinologie. Bd. 1. S. 55–133. Wein 1896.

Uber die Entwicklung der concha bullosa. Monatschr. f. Ohrenheilk. sowie Kehlkopf-, Nasen-, u. Rachenkrankheiten. N. F. Jahrg. 33. 1899.

Uber den Jacobsonschen Knorpel und die Ossification des Pflugscharbeines. S. B. d. Wiener Akad. Wiss. math.-naturw. Kl. Bd. 117, Abt. 111. S. 1–55. 2 Tafeln und 26 Textfig. Wien 1909.

XII.

THE DEVELOPMENT OF THE MUSCULAR SYSTEM.

By WARREN H. LEWIS, Johns Hopkins University, Baltimore, Md., U. S. A.

The entire musculature, both cross-striated and smooth, with a few exceptions that are of ectodermal origin, arises from the mesoderm. Since contractility is a fundamental property of all cells it is not surprising that the ectoderm as well as the mesoderm should give rise to cells in which this function is highly developed. The ectoderm of the optic cup undoubtedly gives rise in most vertebrates, probably in all, to the musculus sphincter and the musculus dilatator pupillæ: Nussbaum (1900, 1902), Herzog (1902), Heerfordt (1900), Szili (1901), Lewis (1903), Collin (1903). In mammals these muscles are of smooth fibres, but in birds and reptiles of cross-striated fibres. The muscles of the glandulæ sudoriferæ are also of smooth muscle derived from the ectoderm: Ranvier (1889), Koelliker (1889), Stöhr (1902), Heidenhain (1893).

The mesoderm, however, gives rise to the great bulk of the musculature, both smooth and cross-striated. The smooth and cross-striated muscles are not to be considered as fundamentally different; they represent different grades of development of contractile tissue or different paths of differentiation from a common fundamental form. The smooth muscle shows a lower grade of differentiation. In insects and birds, for example, portions of the intestinal tract are supplied with cross-striated muscle, while in mammals the corresponding regions are supplied by smooth muscle. Marchesini and Ferrari (1895) found that in early development smooth and striped muscles show exactly the same structure. The fact that the myotomes give origin to many of the cross-striated muscles does not distinguish this variety from the smooth muscle, inasmuch as many of the cross-striated muscles —in the head, for example—arise directly from the mesoderm quite independently of the myotomes and in a manner similar to the origin of the smooth muscle.

It has been customary to consider the voluntary musculature as being derived almost entirely from the primitive segments; yet in mammals the attempts to homologize the head muscles with those of the trunk derived from the myotomes have failed, as there are no indications of preotic segments in the head region; the head muscles develop directly from the mesoderm of the branchial arches and the dorsal eye region. The muscles of the limbs likewise arise directly from the mesoderm of the limb buds; but here uncertainty still exists as to what rôle migrating cells from the myotomes may play in their development. The muscles derived directly from the myotomes—namely, the deep muscles of the back and the intrinsic thoraco-abdominal musculature—are to be considered as both phylogenetically and ontogenetically the oldest of the skeletal muscles. The skeletal muscles of the head and limbs are, on the other hand, of later origin, and probably not derived from the more primitive segmental musculature, but directly from the mesoderm. Until, however, we have a more complete picture of the developmental history, not only in mammals but also in the lower vertebrates, the relationships must remain obscure. The development of many of the muscles in man and mammals has never been traced, and of the remainder our knowledge is fragmentary and incomplete.

It has commonly been supposed that the first differentiation of the muscles from the mesoderm takes place under the influence of the nervous system through the agency of the motor nerves, and that self-differentiation of muscles does not occur. Such a belief arose from our knowledge of the very early union of the motor nerves with the developing myotomes and muscle masses. Teratological evidence is at present conflicting. Neumann (1891), from his studies of acephalic and amyelic monsters, concludes that the influence of the motor nerves is necessary for the differentiation of the muscular system. Leonowa (1893) and Fraser (1895) have described human monsters without brain and spinal cord in which the peripheral sensory nerves and musculature were normally developed. On the other hand, E. H. Weber (1851), Neumann (1901), and others have described cases in which absence of certain portions of the central nervous system has been accompanied by total absence of musculature which is normally supplied by the lacking nerves, although skeleton, blood-vessels, and even tendons were normally developed. Neumann would reconcile these apparent differences by assuming that muscles first arise under the influence of the nervous system, but that their nourishment and further growth during the embryonic period take place independently of the central nervous system, and not until the post-embryonic life is reached is the dependence again established. Thus, the nervous system must have developed in the early stages of embryonic life up to a certain point and undergone degeneration after differentiation of the muscular system had taken place. Herbst (1901) concludes, from the same data, that the sensory nerves, including the cells of the spinal ganglia, and not the motor nerves, are necessary to stimulate the differentiation of the muscular substance in the embryo. The well-known fact that a muscle undergoes atrophic changes after its nerve supply has been cut off would at first sight uphold the view that the influence of the nervous system is necessary for the differentiation of contractile tissue. The study of the normal development likewise affords some evidence which might be interpreted as tending to support it, though it does not necessarily do so. In the embryos of lower vertebrates, for instance, the connection of the motor spinal nerves with the muscle plates is established just at the time when the contractile substance begins to be laid down, but in the pig embryo, according to Bardeen (1900), the musculature is differentiated to a considerable extent before the nerves establish a connection with it: Harrison (1904).

It was only by the experimental method on the lower vertebrates that this question seems to have been finally settled, especially by the brilliant work of Harrison (1904). Harrison removed the spinal cord in a series of frog embryos before the histological differentiation in either the muscular or nervous system had begun, so that from the very beginning isolation of the musculature from the nervous system was complete, and all chance for the exertion of any peculiar formation stimulus emanating from the nervous system as such was eliminated; and likewise, owing to the consequent paralysis of the muscles in question, any possible stimulus resulting from the functional activity of the muscle itself was excluded. Still the differentiation of the contractile substance took place in the normal manner, as did the grouping of fibres into individual muscles. It is not likely that the conditions in mammals and man differ from those of the frog. Thus it is seen that all the constructive processes involved in the production of the specific structure and arrangement of the muscle-fibres take place independently of stimuli from the nervous system and of the functional activity of the muscles themselves. Cross-striated muscle tissue and the individual muscles are thus self-differentiating. At a later period during functional activity, as the experiments of severing the nerve to a muscle show, the muscle becomes dependent on the influence of the nervous system for its continued normal existence, either through a trophic influence or functional activity. At how early a period in the development of the ovum this power of self-differentiation of muscular tissue begins can be but problematical. Lewis (1907) found that in the early gastrula stage of the frog, tissue in the lips of the blastopore possesses the power of independent differentiation into muscular substance. Thus it appears that muscle tissue is already predetermined in the early gastrula. It is probable that this predetermination exists much earlier, even in the egg itself. Conklin (1895) has been able to determine in ascidian eggs, even before cleavage begins, the existence of organ-forming substances, one of which, the myoplasm, that has to do with the formation of muscle tissue, is clearly recognizable and can be followed through successive stages of development into formed muscle.

Harrison's experiments likewise show that the formation of the individual muscles from the myotomes and muscle complexes takes place independently of the nervous system. It has often been assumed that this splitting up of the complex muscle masses into the individual muscles has come to pass through the active ingrowth of connective tissue, blood-vessels, and nerves. There is, however, no experimental evidence indicating that either the connective tissue, the blood-vessels, or nerves take an active part in this process, although descriptive observation might readily lead one to such a conclusion. It is more probable that the explanation lies primarily within the muscle mass itself and secondarily to the relations which the muscle masses may have to shifting skeletal elements. Harrison's experiments would also eliminate functional activity as a necessary factor in this formation of individual muscles.

Although the nervous system does not influence muscle differentiation, the nerves, owing to their early attachment to the muscle rudiments, are in a general way indicators of the position of origin of many of the muscles, and likewise in many instances the nerves indicate the paths along which the developing muscles have migrated during development: Mall (1898), Nussbaum, Bardeen and Lewis (1900), Lewis (1902), Bardeen (1907), Futamura (1906), Gräfenberg (1905). The muscle of the diaphragm, for example, has its origin in the region of the fourth and fifth cervical segments. The nervus phrenicus early enters the muscle mass and is carried with the muscle in its migration through the thorax. The Mm. trapezius and sternocleidomastoideus arise in the lateral occipital region as a common muscle mass, into which at a very early period the nervus accessorius extends, and as the muscle mass migrates and extends caudally the nerve is carried with it. The Mm. pectoralis major and minor arise in the cervical region and receive their nerves while in this position; then the mass migrates caudally and ventrally over the thorax. The Mm. latissimus dorsi and the serratus anterior are excellent examples of migrating muscles whose nerve supply indicates their origin in the cervical region. The M. rectus abdominis and the other muscles of the abdominal wall migrate or shift from a lateral to a ventrolateral or ventral position, carrying with them the nerves. The nervus facialis, which early enters the common facial muscle mass of the second branchial arch, is dragged about with the muscle as it spreads over the head and face and neck, and the nerve splits into its divisions parallel with the splitting of the muscle mass into its various muscles.

The nerve supply serves in part as a key to the common origin of certain groups of muscles. The nervus oculomotorius enters in the early embryo a common muscle mass which later splits into various eye muscles supplied by it. The nervus trigeminus first enters the common muscle mass in the mandibular arch which later splits into the various muscles supplied by this nerve and its branches. The lingual muscles arise from two muscle masses which are supplied by the two hypoglossal nerves. The infrahyoid muscles arise from a common mass supplied by the ramus descendens nervi hypoglossi. The M. trapezius and the M. sternocleidomastoideus arise from a single mass.

Where a muscle is supplied by nerves from two or more segments, the indication is that such muscle has had a complex origin, as the Mm. rectus abdominis, obliquus externus and internus; but this is not always the case, for a muscle may receive secondarily new nerves, retaining at the same time its original nerve, as the M. trapezius, which was originally supplied only by the nervus accessorius and later receives branches from the cervical plexus. The M. digastricus also is, according to Futamura (1906), at first entirely supplied by the nervus facialis, later, as the anterior belly becomes constricted off from the posterior, the former obtains its motor nerve secondarily from the nervus mylohyoideus.

The site of entry of a nerve into the muscle, as a rule, marks the region of earliest differentiation (Bardeen, 1907), and in many instances at least the distribution of the nerve within the adult muscle indicates the course of development or growth of that muscle (Nussbaum, 1894).

HISTOGENESIS.

Smooth Muscle.—We have already noted that smooth muscle may arise either from the ectoderm or the mesoderm; the great bulk of smooth muscle, however, arises *in situ* from the mesoderm, either directly from the mesenchymal derivatives of the mesoderm or from embryonal connective tissue. The various stages in its histogenesis from the mesoderm have never been carefully traced in man, and the following account is based on the excellent work of McGill (1907) on the histogenesis of the smooth muscle in the alimentary canal of the pig.

The mesenchyme which arises from the mesodermal germ layer is in the form of a syncytium, with protoplasmic continuity throughout the entire syncytial mass. "The nuclei of the syncytium are round or oval, with distinct nuclear walls and heavy chromatin reticulum.” “The protoplasm shows a fine reticular structure, the strands of the reticulum being made up of rows of fine granules” (Fig. 325). This syncytium persists throughout intra-uterine life and even in the adult. “Separate and distinct smooth muscle-cells or fibres do not exist at any stage of development.” Thus the term “cell” as here used refers to the enlarged, thickened portion of the syncytium surrounding the nucleus. “Before muscle development begins, there is a general condensation of the mesenchyme,” with multiplication of the cells, followed by marked elongation of the nuclei in the region in which muscle is to differentiate. Not all smooth muscle develops from this primitive mesenchyme, for in later stages the muscle comes from the more developed mesenchyme or embryonal connective tissue. In the alimentary tract, for example, the longitudinal muscle appears much later than the circular and arises from the embryonal connective-tissue syncytium into which the primitive mesenchyme has been transformed. “In the areas of muscle formation not all of the mesenchymal cells (or, in later development, of the embryonal connective-tissue cells) elongate; some retain their stellate shape, with oval nuclei, and from these, in later development, muscle-cells may arise; but they form in the main the anlage of the interstitial connective tissue.”

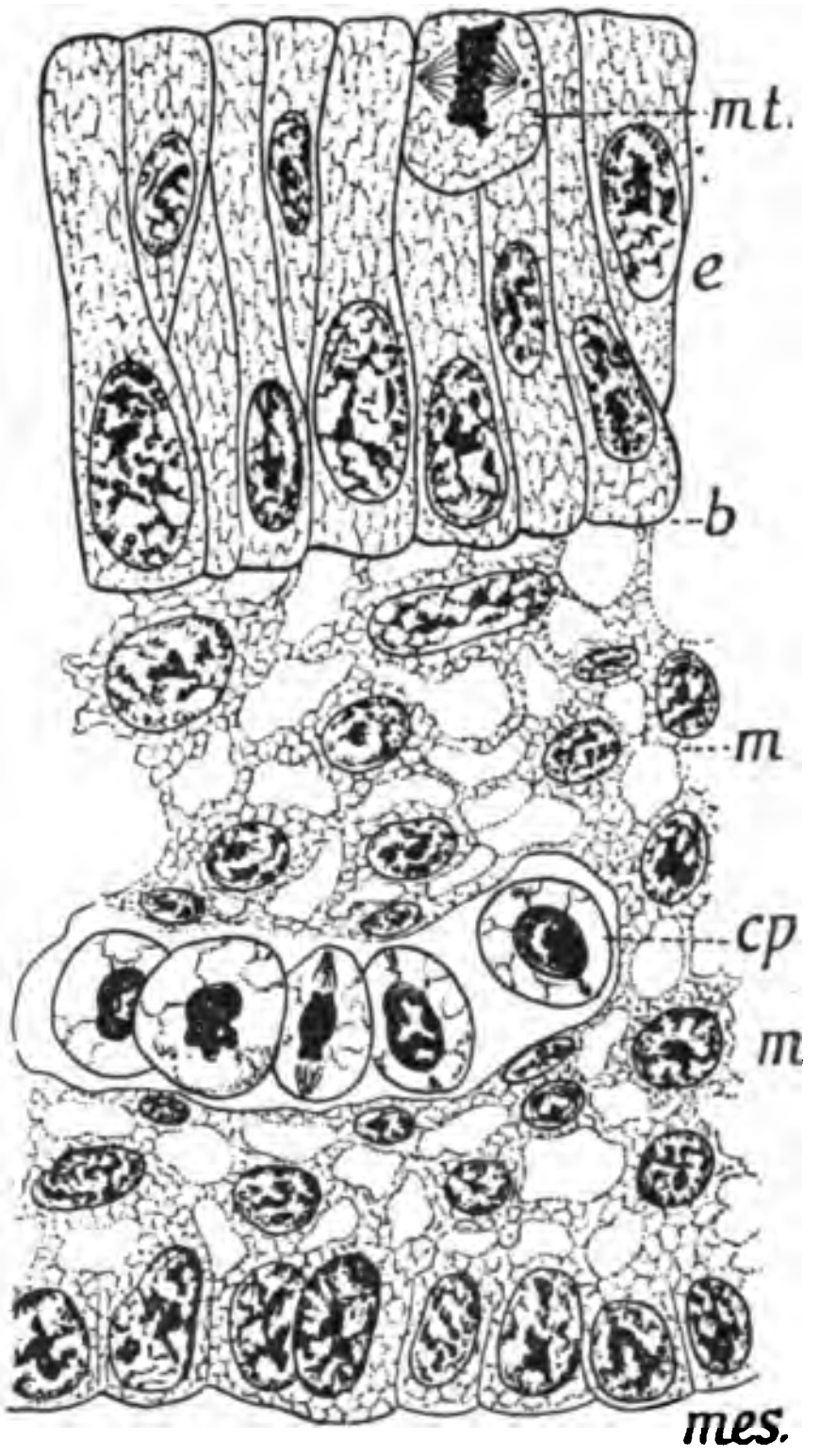

Fig. 325.—(After McGill: Internat. Monatssch. f. Anat. u. Phys., Taf. vii, Fig. 1.) From the œsophagus of a 7-mm. pig, showing condensed mesenchymal syncytium (*m*) with the reticular structure of the granular protoplasm.

“As the elongation of mesenchymal and connective-tissue nuclei continues, in the formation of muscle tissue, there is an increase in the amount of protoplasm surrounding each nucleus. The perinuclear protoplasmic masses also elongate, corresponding to the nuclei, so that the cells change from stellate to spindle-shaped,” without, however, losing the protoplasmic bridges which unite the entire mass into a syncytium; in fact, the bridges become larger in places. During the earliest stages the muscles increase in size by additions from and transformation of the mesenchymal cells. Mitosis is abundant in the mesenchyme and rare in the developing muscle. During the second period, in which the muscles are differentiating by the rapid formation of myofibrillæ and increase in the size of the elongated nuclei, there is little formation of new muscle tissue. Still later there is a second period of muscle growth in the circular layer of the œsophagus, which continues until the adult form is reached. "This increase is apparently due to two factors,—first, differentiation of the embryonal connective tissue both at the margins of the already formed muscle layer and also apparently of that lying between the muscle elements, and second, by the mitotic division of the already formed muscle nuclei."

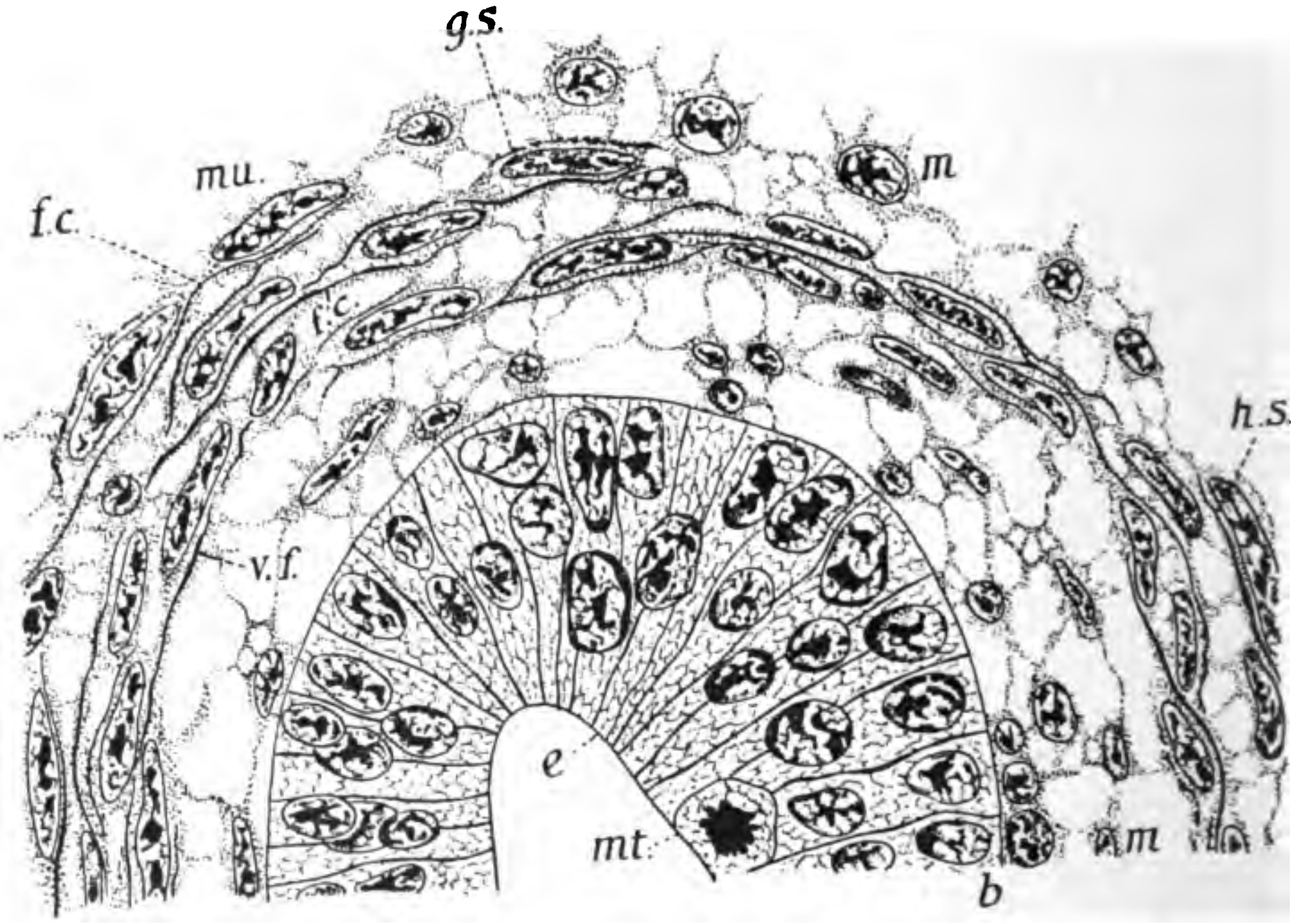

FIG. 326.—(After McGill: Internat. Montassch. f. Anat. u. Phys., 24, Taf. vii, Fig. 3.) From the œsophagus of a 13-mm. pig, showing marked elongation of mesenchymal cells and nuclei, with the formation of coarse myofibrillæ (*fc*), granular spindle (*gs*), granules fused into a homogeneous spindle (*hs*), and their end-to-end union (*hs*), mesenchymal cells (*m*), intimately connected with muscle-cells.

"Immediately following the process of elongation of the mesenchyme, or in later stages of the embryonal connective tissue, the myofibrillæ are formed in the protoplasm of the elongating cells or nuclear masses" (Fig. 326). "There are two kinds of myofibrillæ, coarse and fine." "The coarse myofibrillæ are the first to develop." "The protoplasm of the stellate mesenchyme appears to contain a granular reticulum," and, as the cells elongate to form muscle, the granules increase in number and take a more intense stain than the ordinary protoplasm. "As the elongation continues, the granular fibrils of the protoplasmic reticulum are stretched out more and more, and finally appear as more or less distinct longitudinal striations" (Fig. 327). "The protoplasm of the cell body appears to be made up largely of these irregular, longitudinal rows of granules, instead of the fine-meshed protoplasmic reticulum." "However, at the margins of the cell, in the protoplasmic processes connecting it with neighboring cells and also around the nucleus and between the myofibrillæ, more or less ordinary granular protoplasm remains." These granular fibrillæ represent the rudiments of the myofibrillæ

FIG. 327.—(After McGill: Internat. Monat. f. Anat. u. Phys., 24, Fig. 8, Taf. viii.) From longitudinal section of œsophagus of a 27-mm. pig, showing beginning elongations of mesenchyme (*m*) for muscularis mucosæ (*mm*); *fc*, coarse myofibrillæ and, *ff*, finer fibrillæ in circular layer; *vf*, varicose myofibrilla in longitudinal layer.

and occasionally branch and anastomose with each other. The granular myofibrillæ enlarge at certain points, usually near the nuclei; here the granules become coarser, are closely packed together, and form spindle-shaped structures which taper off at each end into myofibrillæ composed of a single row of granules. "In some cases the end of the spindle appears to break up into several branches of fine granular fibrillæ, which may anastomose with neighboring fibrillæ." "For the most part, however, the spindles are joined by the intermediate fibrillæ into long varicose fibrils which pass through several cells, extending parallel to the elongated nuclei." "The granular stage of the myofibrillæ does not persist long, however," as soon condensation and fusion of the granules both in the spindles and in the anastomosing fibrillæ produce apparently solid varicose smooth fibrillæ. These smooth varicose fibrillæ may be of great length, extending half-way around the œsophagus, for example, and passing through several cells or nuclear territories. "Soon there may be several running through each cell, causing a marked longitudinal striation." "Between the spindles, the fibrillæ are at first slender, but they gradually become thicker, so that the fibrillæ become of a uniform, coarse caliber" (Fig. 328). "Here and there finer fibrillæ do occur, but they are usually granular in structure and are probably merely stages in the formation of the coarse smooth myofibrillæ."

"In later embryos the granular myofibrillæ and spindles are absent or inconspicuous, though smooth, varicose myofibrillæ are not infrequent." "In the late fetus or adult the coarse myofibrillæ are sometimes few in number or altogether absent." The fine myofibrillæ, to all appearances homogeneous, are always present.

In the second period of the formation of smooth muscle from the embryonal connective tissue the development of the myofibrillæ in this embryonal connective tissue seems to follow a different course from that observed in the younger embryos. The presence of the large number of collagenous fibres makes the process difficult to follow. "The fine myofibrillæ appear to arise directly as such, without passing through a granular stage," and the coarse myofibrillæ arise by increase in the caliber or by fusion of several of the fine myofibrillæ into a compact bundle. These coarse myofibrillæ differ from those seen in the earlier stages; they are even larger in caliber and present no spindles or varicosities, but in favorable preparations are seen in places to fray out at the ends into fine homogeneous fibrillæ indicating that they are merely bundles of fine myofibrillæ. In the late fetus and in adult life there is usually a decrease in the number of coarse fibrillæ, with a corresponding increase in the number of fine myofibrillæ, probably from the splitting of the coarse fibrillæ. And "where there are few or no coarse myofibrillæ, and at the same time a rapid increase in the number of fine myofibrillæ," it would seem that the latter increase by longitudinal division. In the later stages, then, the fine myofibrillæ appear while the coarse fibrillæ decrease in number. The fine myofibrillæ arise by splitting of the coarse fibrillæ or in later stages by new formation in the protoplasm. They become uniformly scattered through the protoplasm, while the coarse fibrillæ come to lie in more or less compact bundles, often near the surface. In later stages myofibrillæ cease to develop as new structures, but increase through longitudinal splitting of the fibrillæ already present.

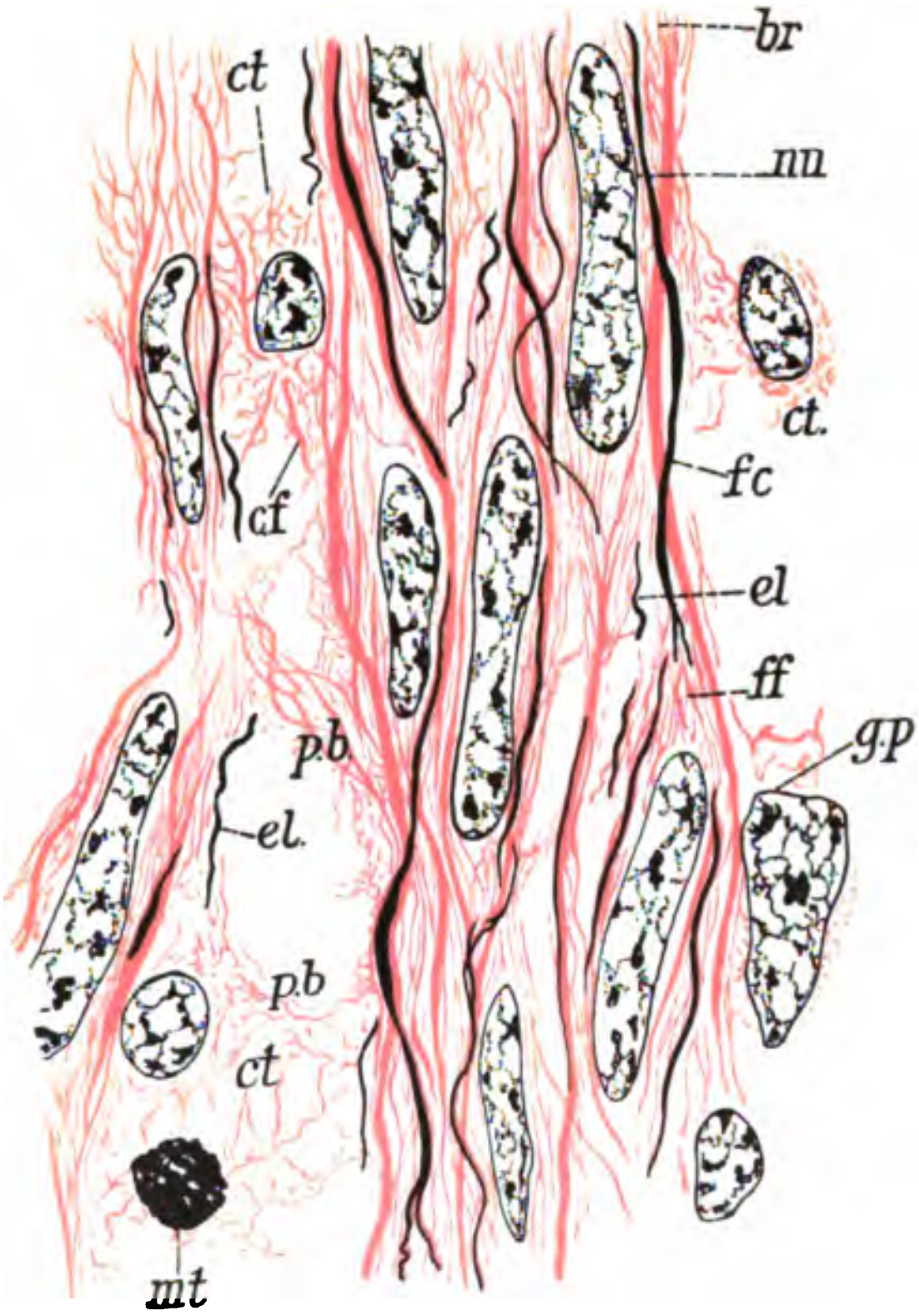

Fig. 328.—(After McGill: Inter. Monat. f. Anat. u. Phys., 24 Fig. 15, Taf. x.) From circular muscle layer of lower œsophagus of a 10-cm. pig embryo, showing persistence of syncytium, elastic fibres (*el*), embryonal connective-tissue cell (*ct*), with collagenous fibrillæ (*cf*), protoplasmic bridges (*pb*), fine myofibrillæ (*ff*), coarse myofibrillæ (*fc*).

At a certain stage in development collagenous fibrillæ begin to form throughout the mesenchyme and also in the smooth-muscle syncytium, and in a single cell both myofibrillæ and collagenous fibrillæ frequently differentiate side by side (Fig. 329). The presence of collagenous fibrillæ in the later stages of the smooth muscle indicates the origin at this time of muscle from the embryonal connective-tissue syncytium in which these fibrillæ have already developed. This intimate relation of the collagenous fibrillæ with smooth muscle may continue even in adult muscle and the collagenous fibrillæ often run from the protoplasm of one muscle-cell into neighboring cells, thus binding the tissue firmly together.

"In development, protoplasmic connections between the muscle-cells and the connective-tissue cells are easily demonstrated." Through the connecting bands of protoplasm, myofibrillæ may enter "the protoplasm of the connective-tissue cells or collagenous fibrillæ make their way into the muscle-cells." "In later development, most of the collagenous fibrillæ are crowded out of the protoplasm of the muscle-cells into the intercellular spaces."

In the walls of the large blood-vessels elastic fibres may arise in the margins of the muscle-cells and are only with difficulty distinguished from the coarse myofibrillæ.

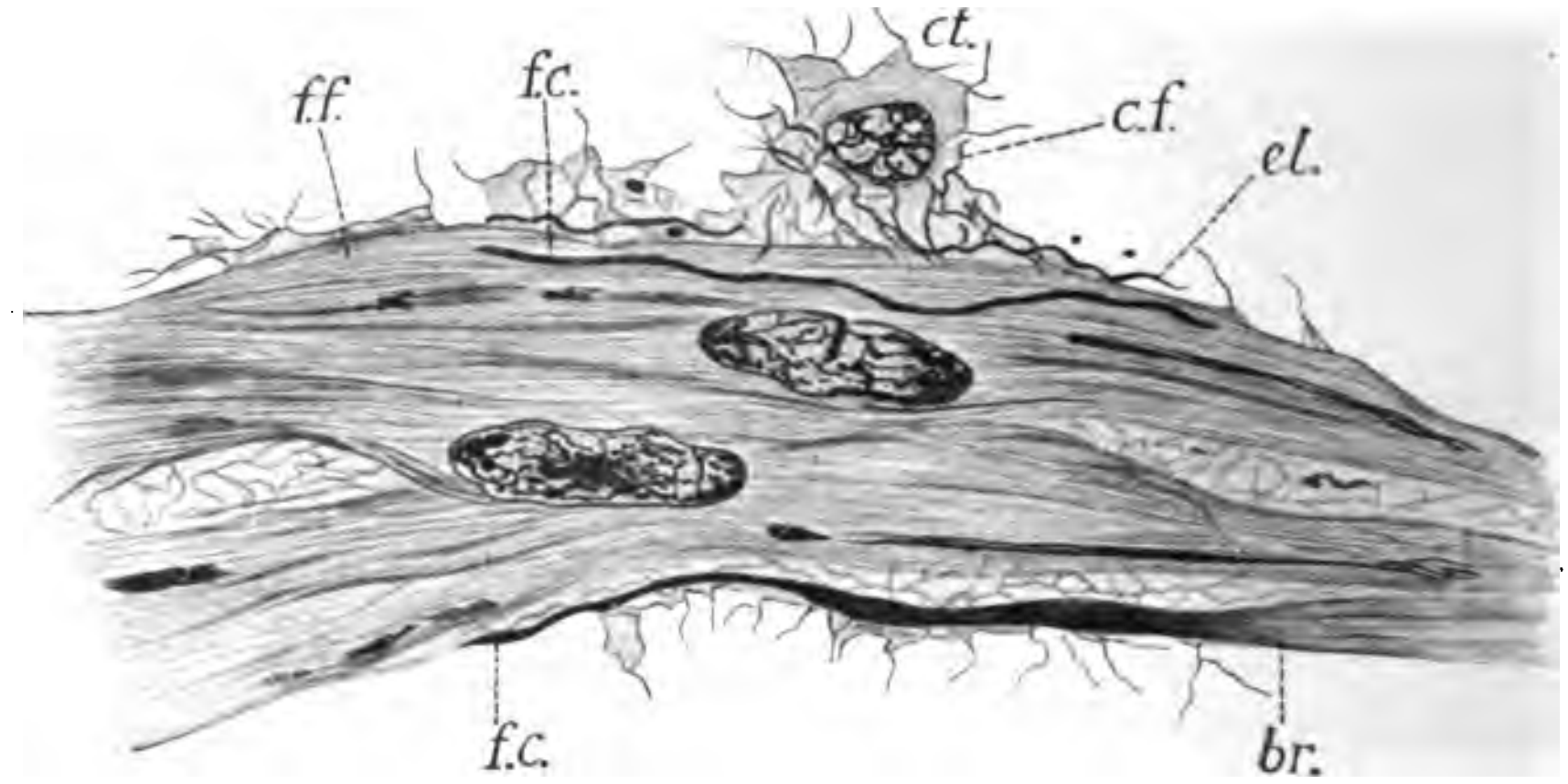

Fig. 329.—(After McGill: Intern. Monat. f. Anat. u. Phys., 24, Taf. xi, Fig. 23.) Smooth muscle from œsophagus of adult pig, showing fine fibrillæ (*ff*), coarse fibrillæ (*fc*), with one breaking up into a brush of fine myofibrillæ (*br*), connective-tissue cell (*ct*), with collagenous fibrillæ (*cf*), elastic fibres (*el*).

"In the region of muscle formation some of the embryonal connective-tissue cells do not elongate or form myofibrillæ, but persist as the interstitial connective-tissue cells. The connective tissue, therefore, does not invade the muscle from without, but arises *in situ.*"

"After the layers of smooth muscle are established, the tissue increases in amount in two ways: first, by a continuation of the process of transformation of mesenchyme (or later of embryonal connective tissue) into smooth muscle at the surface of the muscle layer, or from the transformation of the interstitial cells. This process predominates in earlier embryos. Second, the nuclei of the already formed smooth muscle multiply by mitosis, especially in more advanced fetal stages."

Cross-striated Muscle.—In the mammals and man all the cross-striated muscle arises from the mesoderm, either directly from the mesoderm or its mesenchymal derivatives, as in the head, or indirectly from the primitive segments, as with the deep muscles of the back and the thoraco-abdominal musculature.

The main problem of its histogenesis has been to determine if the adult multinucleated muscle-cell arises from a single cell whose nucleus divides many times or from the fusion of several cells. Each view has had many supporters since the time of Schwann, who held the view of end-to-end fusion, and even to-day the problem is unsettled. Bardeen (1900), in his studies on the pig embryo, takes the view that each muscle-cell arises from a single myoblast which elongates and the nuclei increase within it by direct division. Godlewski (1902), working on the rabbit embryo, found that several myoblasts fuse to form an adult fibre and only rarely do the myoblasts remain single even in the myotomes.

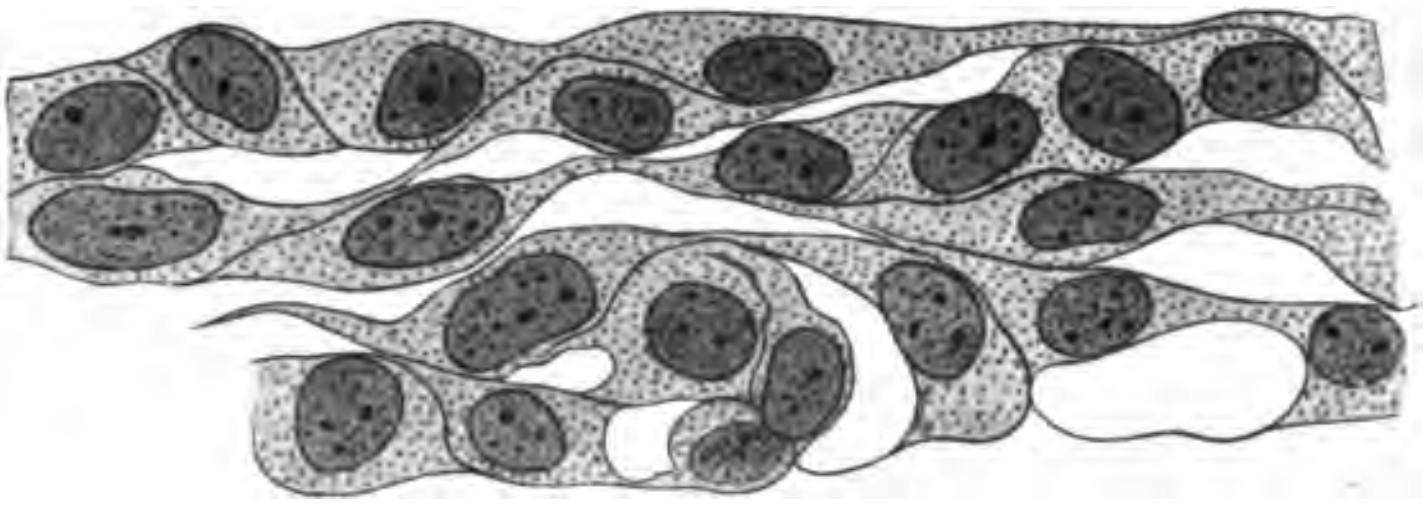

FIG. 330.—(After Godlewski: Arch. f. mikr. Anat., Bd. 60, Taf. vi, Fig. 1.) Myoblast cells in the muscle layer of a 12-day rabbit embryo. Many are obliquely placed and pushed in between other cells Many of the elements are bound together by protoplasmic bridges.

In the myotomes, muscle differentiation progresses from the anterior to the posterior end of the myotome series. At first the long axes of the myoblasts are at right angles to the sagittal plane of the body, but as these epithelial cells of the myotome differentiate into spindle-shaped myoblasts, their long axes become parallel to the long axes of the body. The pointed ends of the myoblasts, according to Godlewski (1902), push in between other cells and anastomose to form a syncytium, and only rarely are single cells found extending the full length of the myotome with only one nucleus (Fig. 330). In this syncytium differentiation proceeds and most muscle-fibres arise from several cells which have thus fused into the syncytium. Cell division goes on in the syncytium, the daughter cells retaining often protoplasmic connections. The syncytium may extend from one myotome to another. Thus, according to the view of Godlewski, cross-striated muscle like the smooth muscle forms a syncytium, and distinct and separate cells or fibres rarely are to be found.

This view is somewhat different from that of Maurer, who found that cell borders at certain stages become invisible, and concluded that the nuclei divided without cell division. Godlewski holds that cell division goes on hand in hand with nuclear division in the earliest stages of muscle formation, the cells retaining protoplasmic continuity.

The muscle-forming cells are at first cylindrical and epithelial-like. As the myoblasts increase in size they are found to contain many small round granules scattered throughout the cell (Fig. 330). These granules soon become arranged in rows, first in the central part of the protoplasm. They then migrate peripheralwards (Godlewski), forming the rudimentary fibrillæ. As the fibrillæ develop the granules lie closer and closer together by increasing in number, rather than size, until finally a continuous thread is formed. Here again is seen a striking similarity between the smooth and cross-striated muscle development in the formation of the fibrillæ. Whether these granules actually fuse or are only pressed together Godlewski could not determine. The granular chains, as well as the continuous fibrillæ which arise from them, in later stages pass through several cell territories, and as the fibrillæ rapidly increase in length they soon extend the entire length of a myotome. The granules between the fibrillæ become rarer and rarer as the fibrillæ increase in number.

The fibrillæ become arranged more and more parallel to the axis of the cells and are grouped about the nuclei. The fibrillæ extend through several cells from one myotome septum to another. The rich connections between the cells often make the myotome one complete syncytial mass. The fibrillæ are gathered together into columns, which become spear or spindle shaped towards the myosepta, and often fuse with the columns in the next myotome through the protoplasmic bridges connecting the myotomes (Fig. 331). The club-like ends of the fibrillæ columns are often seen to be composed of many fine fibrillæ (Fig. 331). In later stages some of the columns may pass through several myosepta, independent of cell or myotome boundaries; many of them, however, end at the myosepta in club-like thickening, often with tufts of fine fibrillæ, the primitive fibre components.

The simple fibrillæ soon begin to show a segmentation into two differently staining substances. Do the segments correspond with the original granules which may not have completely fused into the thread, or are they entirely new structures? The deeply staining segment corresponds with the Q anisotropic band of the adult fibre and the other with the I isotropic striation. Wagner, Bardeen, and others have also observed that the fibrillæ at first show no cross-striation.

The histogenetic process during this first period is essentially the same in muscles which arise independently of the myotomes. This new formation of muscle from the mesoderm Godlewski found was best observed on the surface of developing muscles. The mesodermal cells elongate into spindle-shaped myoblasts, rich in protoplasm and containing many granules. The myoblasts arrange themselves with their long axes parallel and unite into a syncytium by their processes. The nuclei divide by mitosis, but the daughter cells often remain connected together. The fibrillæ form in a similar manner as described above in the myotomes.

The second period begins with the physiological degeneration which has been described by S. Mayer (1886), Barfurth (1887), Bataillon (1891, 1892), Schaffer (1893), Bardeen (1900), Godlewski (1902). This account is based on the description of Godlewski (1902). In certain regions of the developing muscles the fibrillar columns are seen to break up and disappear, the nuclei become irregular, and the direction of the long axis, which until now has been parallel to the long axis of the fibre, is altered so that the nuclei are often diagonal or crosswise. The protoplasm becomes more homogeneous and gathers about the nuclei in stellate masses. The nuclei become pale and poor in chromatin, but often retain the power of division for a long time. In some forms of degeneration the muscle-cells become vacuolated (Fig. 332). Many of the degenerating muscle-fibres disappear. After the stage of degeneration new muscle-fibres are formed by longitudinal splitting of the normal ones already present.

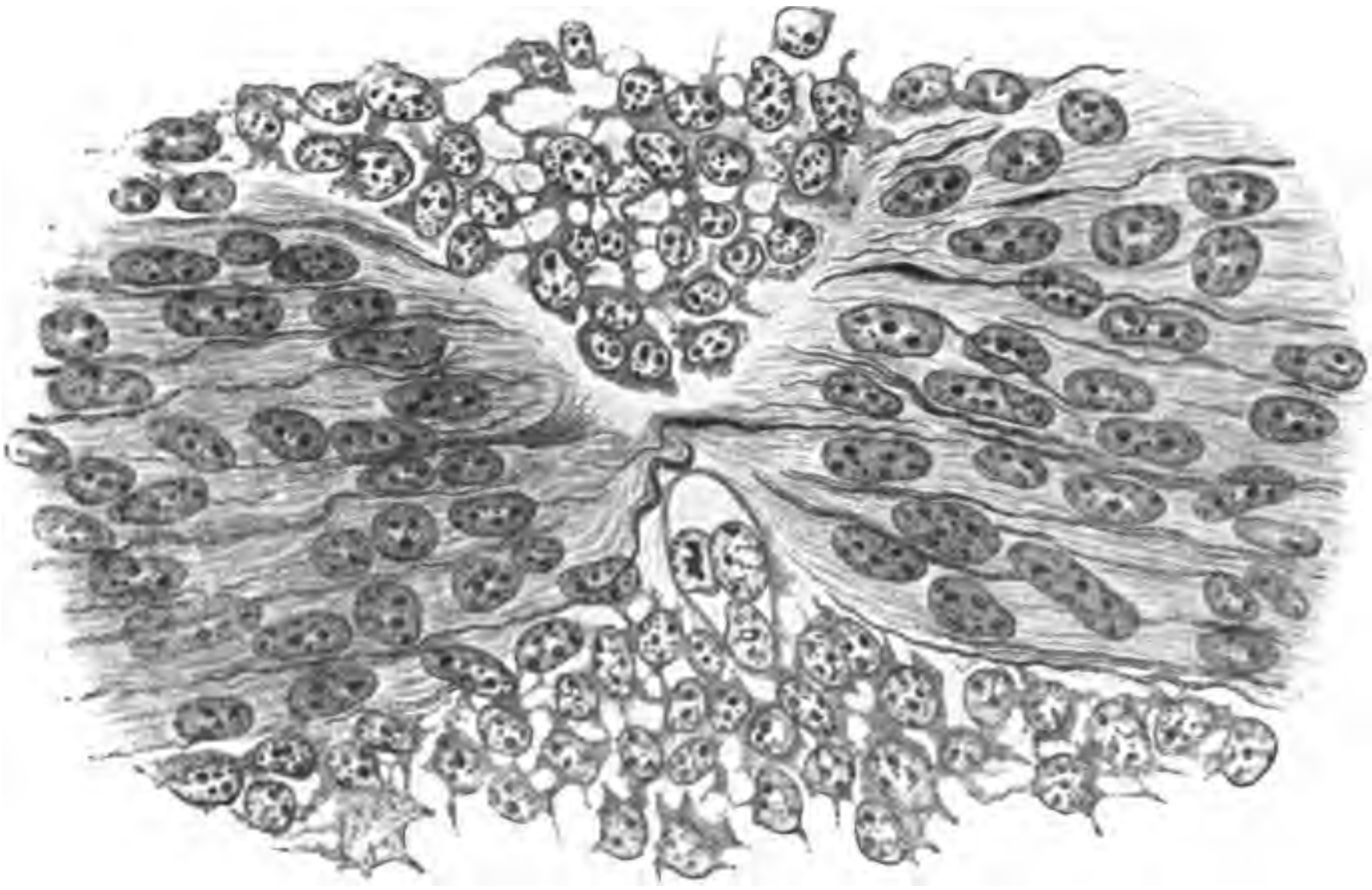

FIG. 331.—(After Godlewski: Arch. f. mikr. Anat., Bd. 60, Taf. vi, Fig. 4.) In the intermyotome bridges the columns of two neighboring segments fuse together by means of their club-shaped ends. Many of the columns end in a fine fibrous structure. Sagittal section, 13-day rabbit embryo.

The fibrillæ multiply by longitudinal splitting and become grouped into the columns in such a manner that similar cross-striations (Q and I) in the same muscle-fibre lie in the same planes. Parallel with this process new striations appear, first the Z and later the M zones. In a ten-weeks human embryo the cross-striation is already completely developed.

Both Bardeen and Godlewski noticed in early stages that during mitosis the protoplasmic granules increase in number. At this time the cell bodies usually split during mitosis, but occasionally more than one nucleus is found in a cell. In later stages amitotic division occurs, and fibres come to have many nuclei, both medial and peripheral. Godlewski believes that the fibrillæ play an active part in the wandering of the nuclei to the periphery. The inner nuclei are present in the earliest phases of development and later wander to the periphery of the muscle-fibre. Mitosis occurs in both inner and outer nuclei.

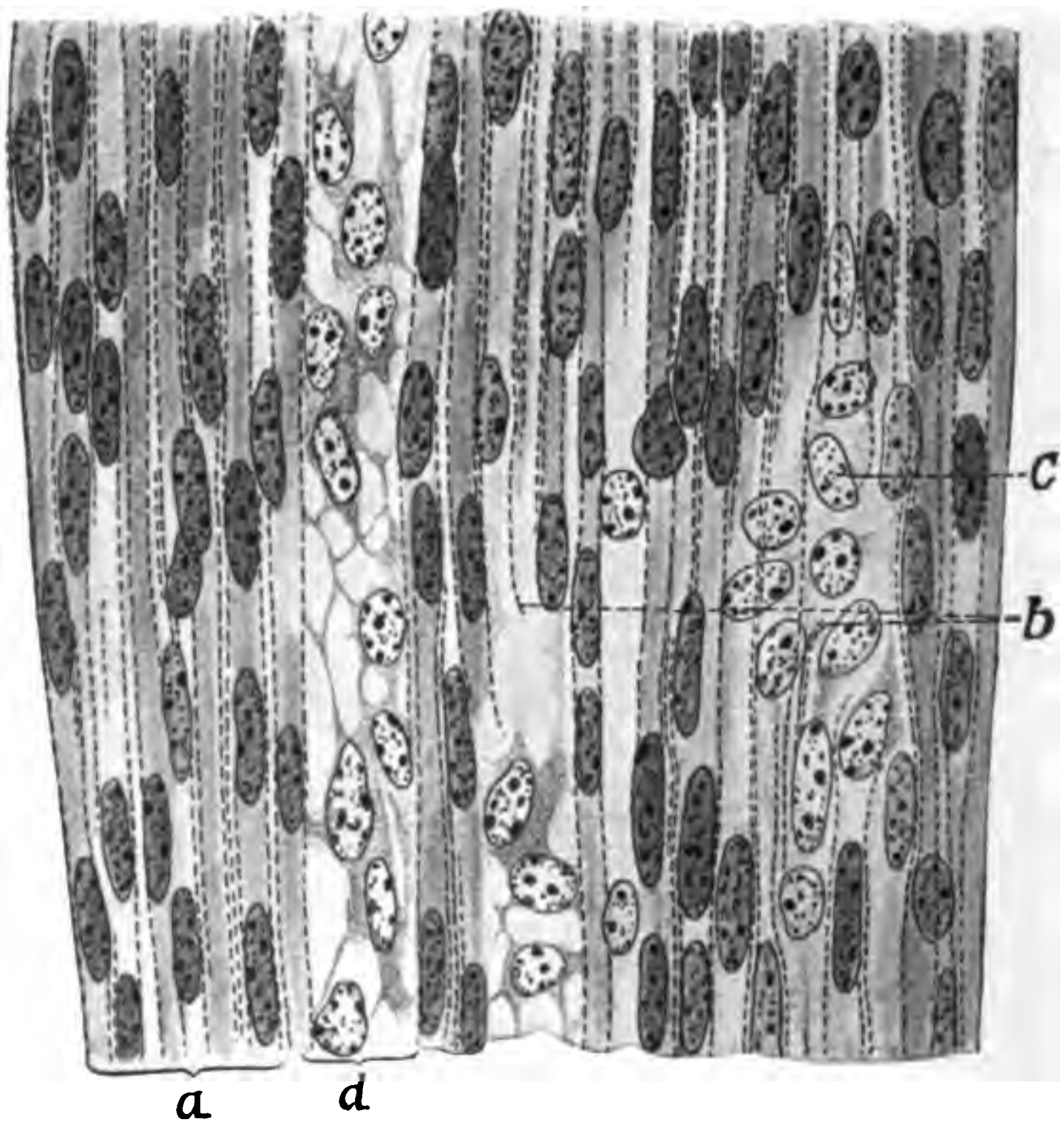

FIG. 332.—(After Godlewski: Arch. f. mikr. Anat., Bd. 60, Taf. vi, Fig. 10.) Guinea-pig embryo 12-mm. long. Beginning of the degeneration process. *a*, zone of a muscle rudiment in which degeneration has not begun; *b*, fibrils in which the continuity is apparently destroyed; *c*, nuclei in altered positions.

During the development of the myotomic muscles new myoblasts seem only to arise through division of the myoblasts already present in the myotomes, and there is probably no direct transformation of mesenchyme cells into myoblasts. But with those muscles arising directly from the mesenchyme there is for a period a continuous transformation of mesenchyme cells into myoblasts, as in the muscles of the limbs and head. This process early ceases, and new muscle-fibres then arise only by cleavage of those present.

According to MacCallum (1898), who counted the fibres of the sartorius muscle in man at various ages, muscle-fibres cease to multiply in fetuses from 130 to 170 mm. in length, and henceforth the muscles increase in size by enlargement of the individual fibres. Meek (1898, 1899) observed in several mammals (rat, cat, and sheep) that the fibres decrease in number soon after birth. The lucky fibres get into better relations with the nutritive supply, etc., while the unfortunate ones are squeezed out and so degenerate (a survival of the fittest). The increase in the size of the muscle after birth is dependent on increase in the size of the individual fibres. Morpurgo (1898) was unable to find this decrease in the number of the fibres, but did observe that multiplication ceases a short time after birth and muscles increased in size by increase in the size of the fibres.

THE SEGMENTATION OF THE MESODERM.

The development of the voluntary skeletal musculature may be said to begin with the segmentation of the dorsal division of the trunk mesoderm into the primitive segments. The musculature arising from the primitive segments is both phylogenetically and ontogenetically the oldest in the body.

It is uncertain which segment is the first one to form, Keibel claiming that in mammals, and Maurer that in all vertebrates, the most anterior one is the first to become segmented off from the mesoderm. Paterson (1907) has shown, by experiments on chick embryos, that the first segment to form is the most anterior one and that segmentation progresses posteriorly. This probably holds true for all vertebrates.

The segmentation of the mesoderm begins in embryos between 1.17 mm. (Frassi) and 1.38 mm. (Kroemer-Pfannenstiel) in length. In the latter embryo there are 5 or 6 pairs of primitive segments and in the former none. There is perhaps some variation in the time of the first appearance of the segments, for in an embryo 1.54 mm. in length (Spee, Gle) there are no primitive segments, while in an embryo 1.6 mm. in length (Unger-Keibel) there are about 9 pairs. In an embryo of 2 mm. in length (Mall, 391) there are 8 to 9 pairs of primitive segments which are still connected with the lateral mesoderm. Segmentation progresses rapidly in a caudal direction. In embryos 2 to 3 mm. in length the number of segments ranges from about 10 to 20 pairs; in embryos 3 to 4 mm. in length, from 20 to 30 pairs; 4 to 5 mm., 30 to 35 pairs; 5 to 6 or 7 mm., 35 to 40 pairs. From 38 to 40 pairs of segments are formed, 3 to 5 occipital, 8 cervical, 12 thoracic, 5 lumbar, 5 sacral, and about 5 coccygeal. In embryos of 7 to 9 mm. in length this segmentation attains its highest development (Figs. 367, 336, 368, 335, 334). The segments soon lose their individual identity as such, and in embryos from 10.5 to 12 mm. in length the myotomes fuse to form a continuous column (Fig. 337). This fusion progresses in an anteroposterior direction.

THE DIFFERENTIATION OF THE PRIMITIVE SEGMENTS.

Just as there is a progressive segmentation of the mesoderm in an anteroposterior direction, so we find there is a progressive differentiation of these primitive segments in the same direction. Thus, in embryos of 4 to 5 mm. in length the anterior segments show quite advanced differentiation while the posterior ones still retain the more primitive conditions.

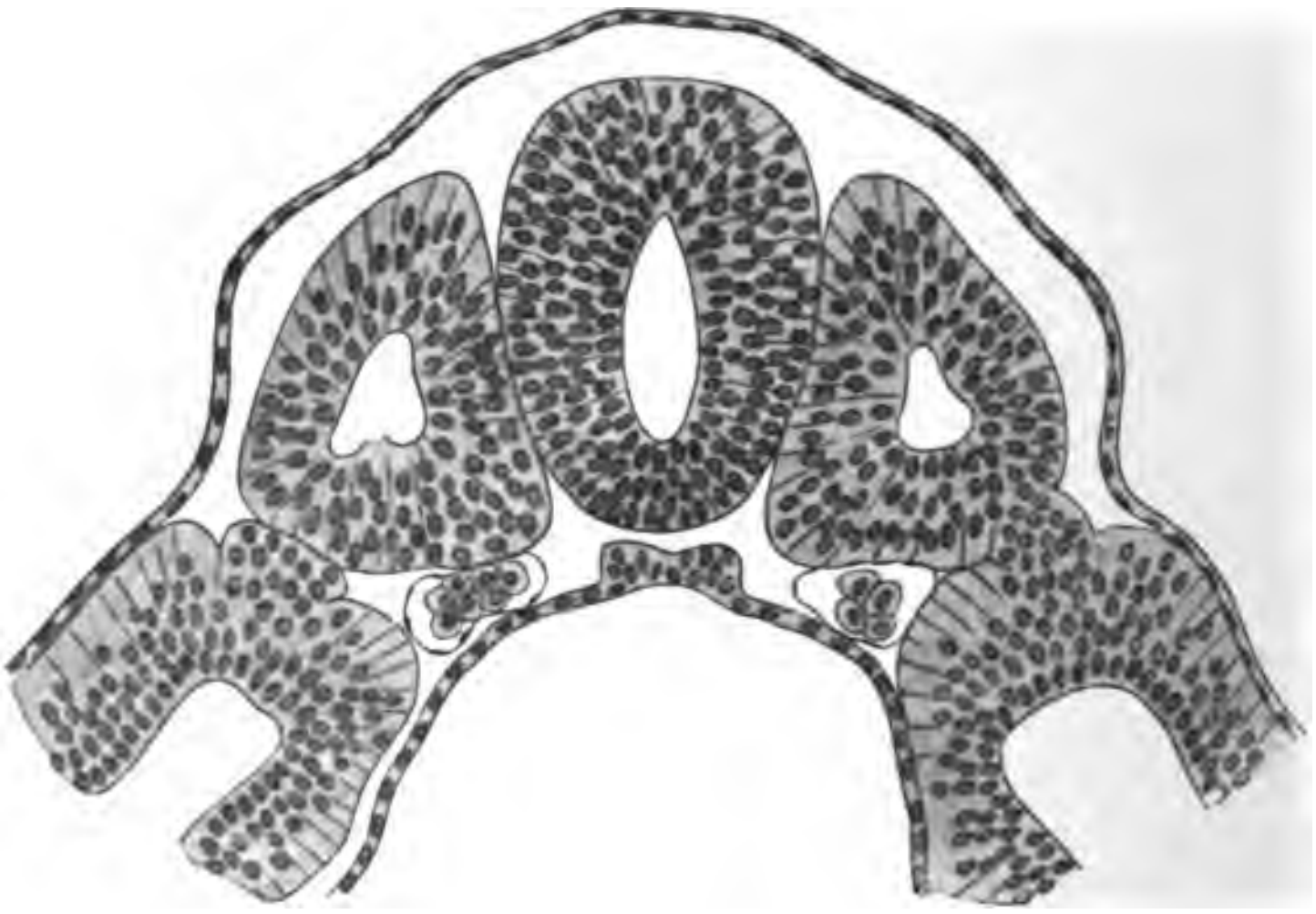

FIG. 333.—(After v. Lenhossek, Arch. f. Anat. u. Physiol., 1891.) Cross-section from the middle part of the body of a human embryo with thirteen primitive segments. Stained in borax carmine. × 280 diam.

The differentiation of each segment follows a common plan progressing in a cranio-caudal and a dorso-ventral direction. The primitive segment is at first cubical, with simple epithelial walls surrounding an empty cavity or myocœl. In sections the dorsal, lateral, medial, and ventral walls are more or less clearly to be recognized (Fig. 333). The first change which takes place is the migration of cells from the walls into the cavity, especially from the medial and ventral walls. Later, as the myocœl becomes filled with these cells, this rudiment, with much of the medial and ventral walls, migrates medially towards the chorda and neural tube, forming the rudiment of the sclerotome. Following the migration of the sclerotome the dorsal wall grows ventrally along the medial surface of the outer lamella to form the medial lamella of what has now become the myotome. With the growth of this medial lamella to the ventral edge of the outer lamella, with which it unites, the myocœl becomes reduced to a narrow cleft between the two lamellæ. The myotome now consists of a two-layered quadrilateral body, with the lateral or cutis plate, the medial or muscle plate, dorsal and ventral edges, and anterior and posterior edges which are in contact with the preceding and succeeding myotomes (Fig. 334). In a three-weeks embryo this condition is found in the anterior segments while the more posterior ones still show the first stages of the primitive segments.

FIG. 334.—(After Bardeen and Lewis.) From embryo 7 mm. in length, showing ninth to twelfth thoracic myotomes.

In an embryo 4.9 mm. in length, for example (Ingalls, 1907), the second coccygeal myotome is just separating from the caudal mesoderm. In the anterior coccygeal myotome the myocœl is filled with sclerotome cells arising from its walls. In the sacral region these cells, together with the medial and ventral walls, are pushing towards the chorda and neural tube, while in the anterior sacral region the cranial part of the medial wall is broken through and it together with the sclerotome cells of the myocœl are migrating towards the chorda and neural tube. In the lumbar region the medial and ventral walls, together with the myocœl cells, have migrated toward the chorda and neural tube, leaving a wide opening into the myocœl, the intervertebral cleft. At the dorsal edge of the myotome the inner lamella (muscle-plate) is beginning to grow ventralwards along the medial surface of the outer lamella. In the thoracic region this inner lamella has grown well towards the ventral edge of the outer lamella, which edge has rolled medially, and from this free edge sclerotome cells are still migrating. With the ventral growth of the inner lamella and its union with the edges of the outer lamella, the opening into the myocœl is gradually reduced in size, but persists towards the caudal end of the ventral border as the intervertebral cleft. In this region later lie the spinal nerves and segmental blood-vessels. The outer lamella during this process has extended further ventrally and also increased in thickness, its cylindrical epithelial cells remaining for the most part with their long axis at right angles to the cleft-like myocœl. The medial lamella as it grows ventrally increases in thickness; its cells become spindle shaped, with their long axis parallel to the dorsal edge of the myotome. The cells of the dorsal edge, however, retain longer their primitive epithelial character and form the vegetative centre for the dorsal extension of the myotome. In the anterior thoracic region cells from the medial surface of lateral lamella separate from it to join the medial or muscle-plate. The ventral edge of the myotome is formed by the bending medially of the ventral edge of the lateral plate, which has elongated ventrally during the formation of the myotome. Ingalls also finds in this 4.9-mm. embryo that in both sacral and lumbar regions the ventral edge is not very sharply marked off from the surrounding mesenchyme. In the lumbar region cells appear to be migrating from the edge of the myotome into the limb bud. In the cervical region the migration of cells into the arm bud is even more marked, and from some of the myotomes distinct epithelial buds project towards the arm bud from the lateral lamella near its ventral border. The fourth, fifth, and sixth cervical myotomes also show migrating cells from their ventral edges.

The cells of the medial or muscle lamella are gradually transformed into elongated spindle cells extending in an anteroposterior direction from one end of the myotome to the other. These cells later form muscle-cells.

The fate of the lateral or cutis lamella is still in dispute, even in the lower vertebrates. Most observers agree that the lateral or cutis lamella gives rise to both muscle and connective-tissue forming cells (Kollmann, Kästner, Fischel). Ingalls found muscle-forming cells, but could not determine in the 4.9-mm. embryo studied by him whether the lateral lamella gives rise to connective-tissue cells or not. Bardeen (1900), in his studies on both pig and man, concluded that the lateral lamella, except for the degeneration of some of its cells, gives rise only to muscle-cells.

The ventral edge or portion of the myotome gives rise to the ventrolateral trunk and neck musculature. The median or muscle lamella is entirely transformed into muscle-fibres. By longitudinal fusion and splitting of the myotomes arise the deep back muscles of the trunk and neck. The deepest layers, however, probably retain more or less of the primitive segmental arrangement (Bardeen).

THE MUSCLES OF THE TRUNK.

The intrinsic muscles of the trunk are derived directly from the myotomes. By the intrinsic muscles I mean, first, the deep muscles of the back,—namely, those beneath the musculi serratus posterior superior and inferior. In the adult the deep muscles, especially in the lumbar and thoracic regions, are encased in the fascia lumbodorsalis. Thus, the muscles from the trunk to the shoulder-girdle are excluded from this group, and, as will be shown below, probably do not come from the myotomes. The second group includes the ventrolateral muscles of the thorax and abdomen,—namely, the Mm. serratus posterior superior and inferior, intercostales, obliquus abdominis internus and externus, rectus and transversus abdominis, and quadratus lumborum. In the third group are the prevertebral muscles, the Mm. longus capitis and colli, and rectus capitis anterior.

FIG. 335.—(After Bardeen and Lewis.) From 9-mm. embryo, showing eleventh and twelfth thoracic myotomes extending into body wall with the ribs.

The Deep Muscles of the Back.—The deep muscles of the back arise from the myotome column which results from the fusion of the myotomes and the disappearance of the myosepta. This fusion, as we have seen, progresses in an anteroposterior direction, and already in a 9-mm. embryo traces of segmentation, at least superficially, are beginning to disappear in the cervical and thoracic regions (Figs. 335, 336). This process is complete in embryos of 11 to 12 mm. in length (Fig. 337). The occipital myotomes, at least the caudal ones, are probably fused into this myotome column (Figs. 367, 368). Superficially all traces of segmentation are lost, but the deeper portion of the myotomes lying in contact with the vertebral column probably retains in man the primitive segmentation, as described by Bardeen (1900), in the pig. Thus, the Mm. interspinales, rotatores breves, levatores costarum, and intertransversarii probably retain throughout intra-uterine and extra-uterine life the primitive segmental arrangement of the myotomes.

By longitudinal and tangential splitting of the myotome column the various muscles of the back arise, and the subsequent segmentation of muscles arising from the myotome column is a secondary one and need bear no relation to the primitive segmentation. This process of splitting has already begun in an embryo 11 mm. in length in the cervical and thoracic regions, even while traces of segmentation are still visible at the caudal end of the myotome column (Fig. 337).

FIG. 336.—(After Bardeen and Lewis.) From 9-mm. embryo, showing myotomes with ventral extension into body wall and premuscle masses of the arm region. The premuscle sheath has been cut away from distal part of the arm.

The superficial portion of the myotome column seems at first to split longitudinally into two main divisions,—a dorsal one which gives rise to the spinalis and longissimus groups, and a ventrolateral one which gives rise to the iliocostalis group of muscles (Fig. 337). In the cervical region this process is more complex than in the thoracic region, while in the lumbar region the more primitive conditions of the myotome column persist to adult life.

The details in the development of the deep back muscles have never been studied. I have observed that in a 14-mm. embryo practically all the deep muscles of the back are to be recognized without great difficulty except the suboccipital muscles. At this stage the Mm. rectus capitis posterior minor and major and the obliquus capitis inferior form a more or less continuous sheet. Through the different attachments of various portions of this muscle sheet one can recognize the position of the individual muscles. In a 20-mm. embryo these muscles are distinct and easily recognized.

The development of the fascia lumbodorsalis proceeds parallel with the development of the myotome column and its muscle derivatives. In an 11-mm. embryo this fascia is already present in the upper thoracic and lower cervical regions, enclosing the muscles in a distinct sheath which extends from the spinous processes into the lateral region of the neck and thorax. This fascia remains an important landmark between the true myotome muscles and those which subsequently migrate into the more superficial region, such as the Mm. trapezius, rhomboideus, and latissimus dorsi, and in part also the Mm. serratus posterior superior and inferior.

The growth of the dorsal muscles towards the mid-dorsal line is dependent on the extension and formation of the vertebral arches.

The Thoraco-Abdominal Muscles. — The thoraco-abdominal muscles arise through the ventral extension of the thoracic myotomes into the body wall. The myotomes begin to grow into the body wall with the development and extension of the ribs. Even in a 7-mm. embryo, before the myotomes are fused into a continuous column, this process has already begun (Fig. 367). In a 9-mm. embryo the myotome processes extend farther ventrally than do the ribs (Figs. 335, 336). As the myotomes extend into the body wall, they lie partially between the ribs and partially lateral to them, where they fuse into a continuous lateral sheet which extends beyond the tips of the ribs, ending ventrally in a continuous column, the rectus rudiment, formed by the fusion of the entire thickness of the myotome processes (Fig. 336). The myotome processes also fuse over the medial surface of the ribs to form a continuous medial sheet, which is continuous with this rectus rudiment lying ventral to the tips of the ribs. The ribs and this ventrolateral musculature gradually grow farther and farther into the body wall and finally reach the mid-ventral region. Meanwhile, long before this occurs, while the ventral edge of this invading skeletal and musculature wall occupies the extreme lateral position along the sides of the embryo, the muscles begin to differentiate (Figs. 337, 347). Through longitudinal splitting off of the muscle column formed by the fusion of the ventral ends of the myotome processes arises the M. rectus abdominis. Through tangential splitting of the lateral sheet arises the M. obliquus abdominis externus and more dorsal to this the Mm. serratus posterior superior and inferior. The medial sheet gives rise to the Mm. obliquus abdominis internus and transversus abdominis. The portions of the myotome processes remaining between the ribs give rise to the Mm. intercostales externi and interni. They are already clearly differentiated in an 11-mm. embryo. The Mm. intercostales apparently always retain the primitive segmentation of the myotomes. The lineæ transversæ of the rectus are often spoken of as representing the primitive myosepta and the muscle bellies between as primitive myotome segments. In the fusion of the ventral ends of the myotomes to form the rectus, I have been unable in early stages to recognize the myosepta, and it may be that the segmentation of the rectus is a secondary process. The segmentation of the M. obliquus abdominis externus is for the

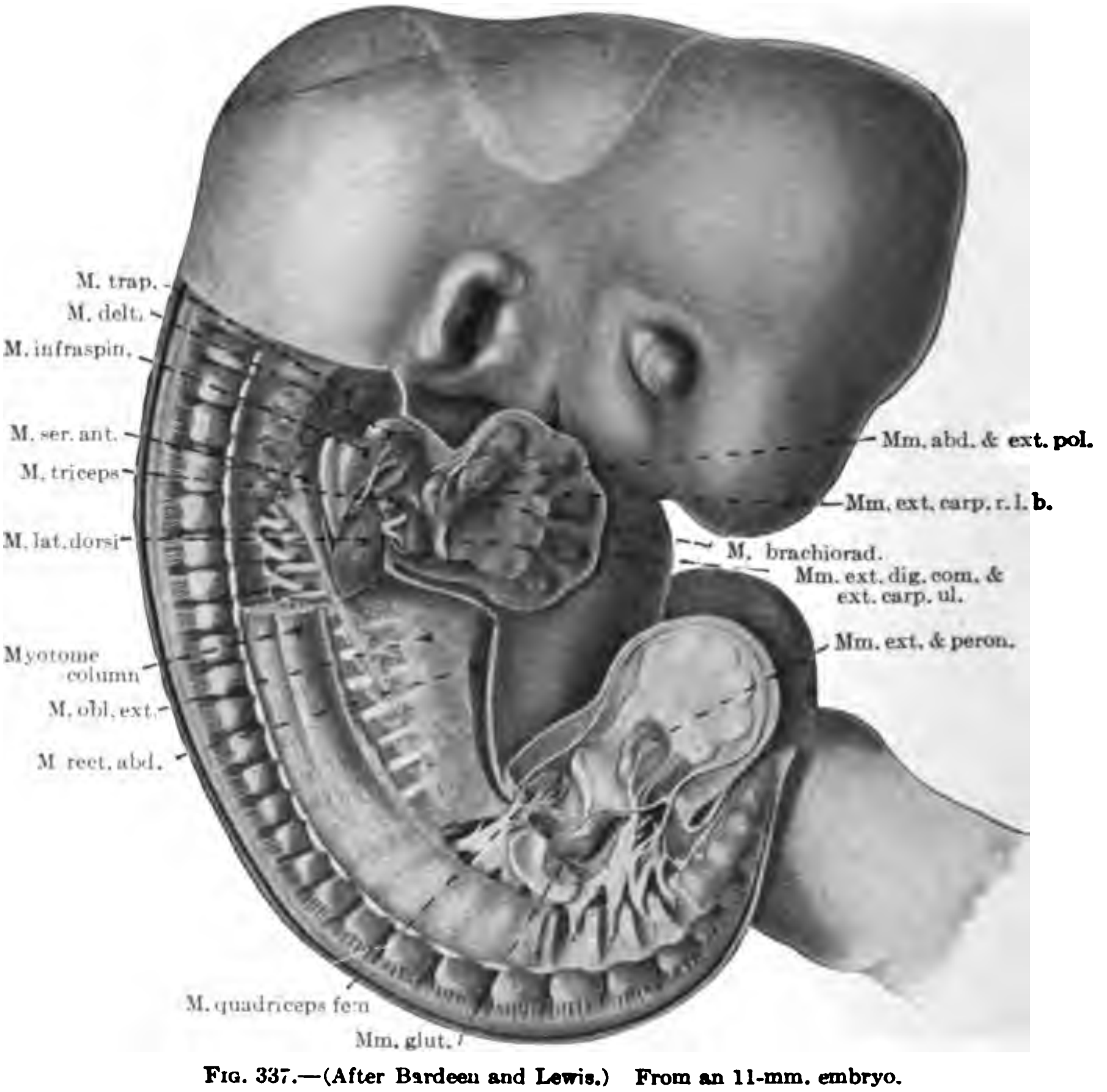

FIG. 337.—(After Bardeen and Lewis.) From an 11-mm. embryo.

most part secondary, except as pointed out by Bardeen (1900), traces of segmentation remain where it lies in direct contact with the intercostales externi throughout its period of development. The Mm. obliquus abdominis internus and transversus abdominis do not retain any traces of the primitive segmentation.

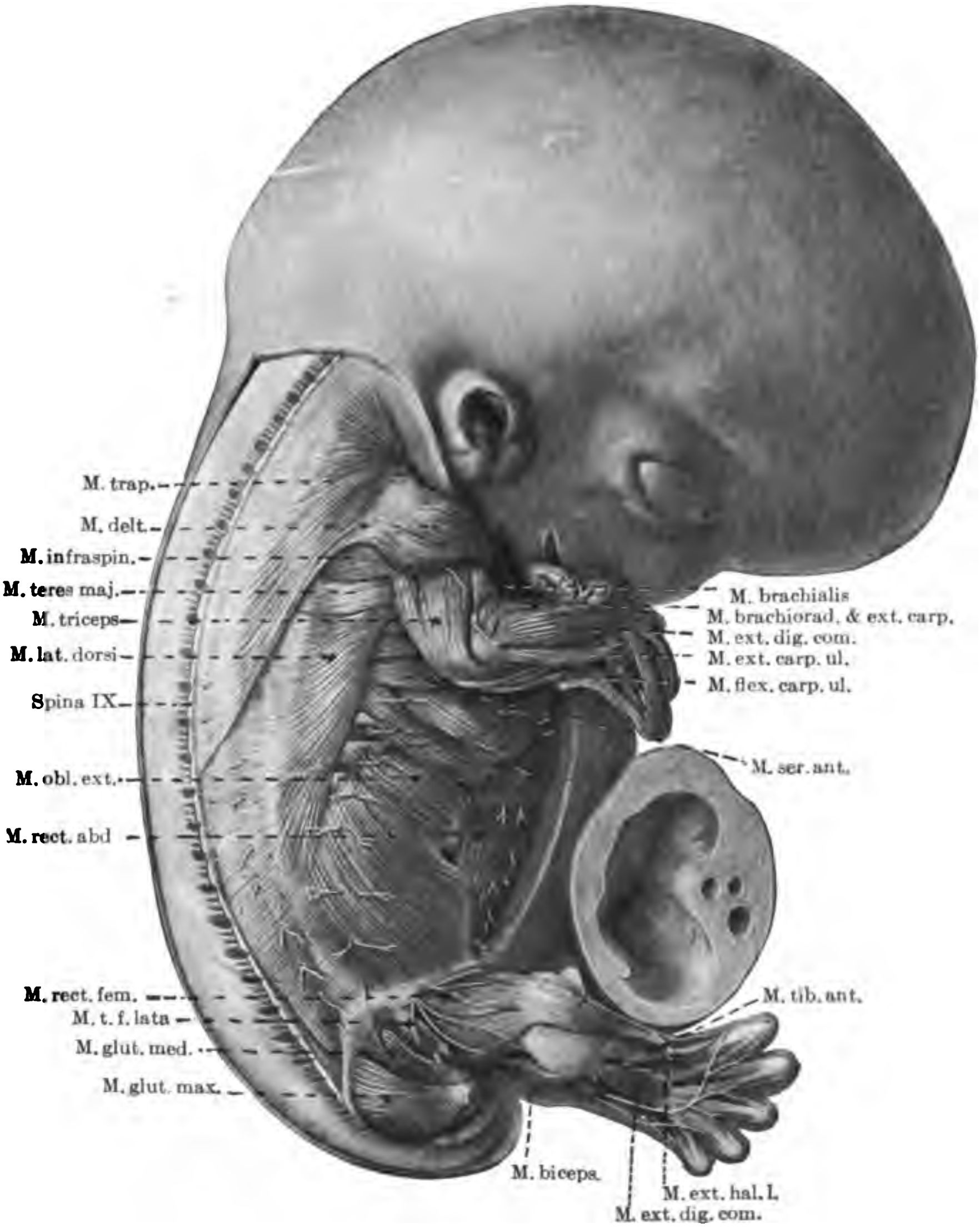

FIG. 338.—(After Bardeen and Lewis.) From a 20-mm. embryo.

In 14-mm. and 16-mm. (Fig. 349) embryos the abdominal muscles are clearly differentiated and present much the adult form, although they still occupy a more lateral position, and even in a 20-mm. embryo the two recti are widely separated (Figs. 338, 339, 348).

There are no observations that I am aware of that explain the origin of the lineæ semicircularis (Douglasi).

The Subvertebral Muscles.—The subvertebral muscles of the cervical region are formed by the growth of the myotomes on to the ventral surfaces of the vertebral bodies and subsequent fusion of these myotome processes into a continuous column to form the Mm. longus colli and capitis. The M. iliopsoas is not derived in this manner, but extends upwards from the femoral region and belongs to the musculature of the leg.

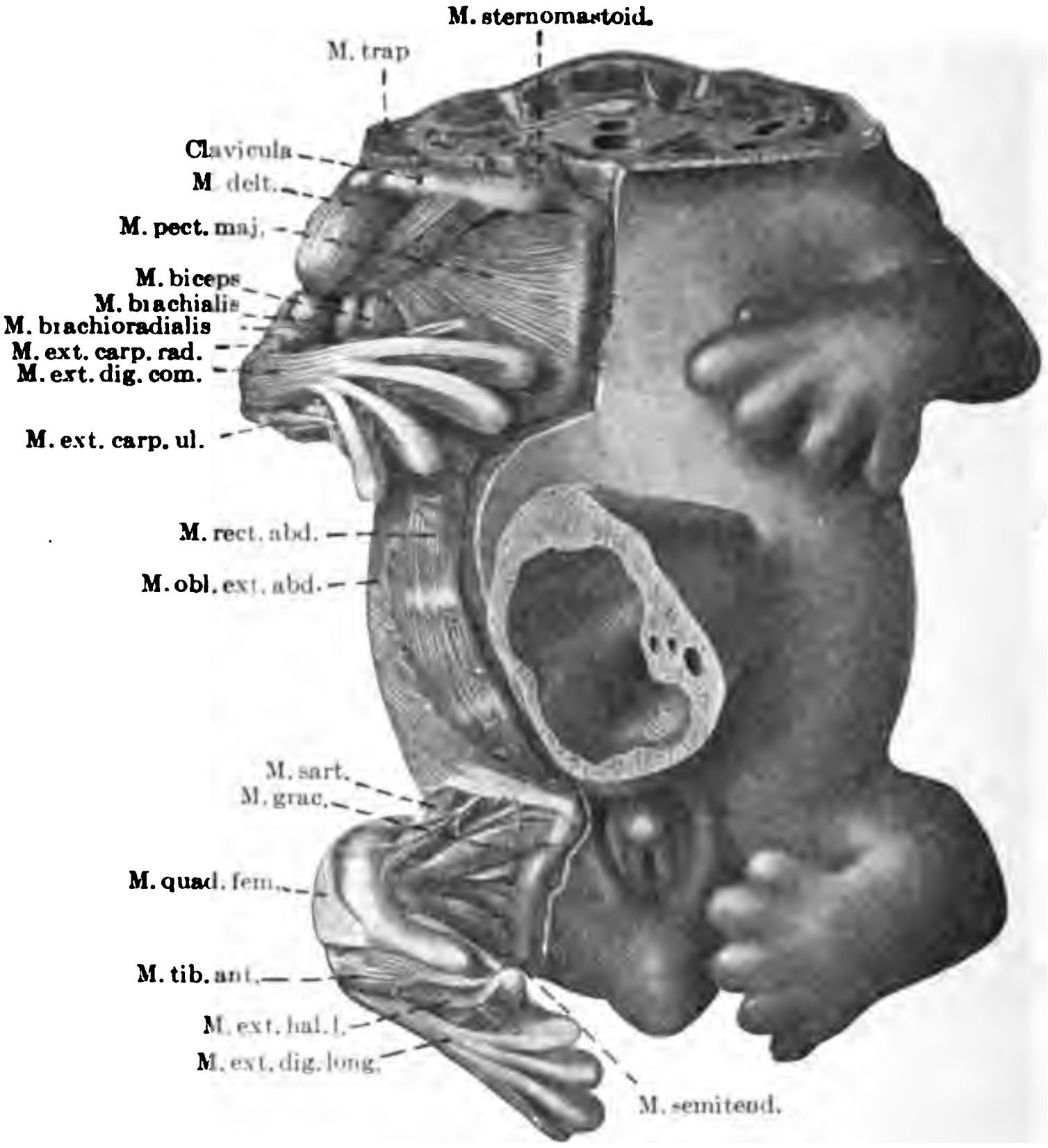

FIG. 339.—(After Bardeen and Lewis.) Frontal view of the trunk and limbs of a 20-mm. embryo.

THE MUSCLES OF THE PERINEUM.

Popowsky (1899) has given the best account of the development of the muscles of the perineum. They arise from the musculus sphincter cloacæ, a skin muscle which is present in a 2-months embryo (Fig. 340). During the third month of fetal life it divides into a M. sphincter ani externus and a M. sphincter sinus urogenitalis (Fig. 341). This division is dependent upon the separation of the simple single cloacal opening into two openings. The M. sphincter ani externus alters very little during the later development, but the M. sphincter urogenitalis undergoes many changes, giving rise as it does to perineal muscles. During the fourth to fifth month the M. sphincter urogenitalis gives rise first to the M. ischiocavernosus, bulbocavernosus, and M. sphincter urethræ membranaceæ (Figs. 342, 343, 344, 345). The M. trans-

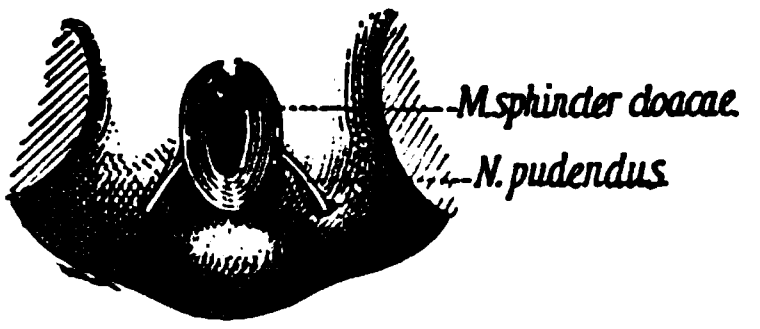

FIG. 340.—(After Popowsky, Anat. Hefte, Bd. 12, Taf. ii, Fig. 1.) Embryo of 2 months.

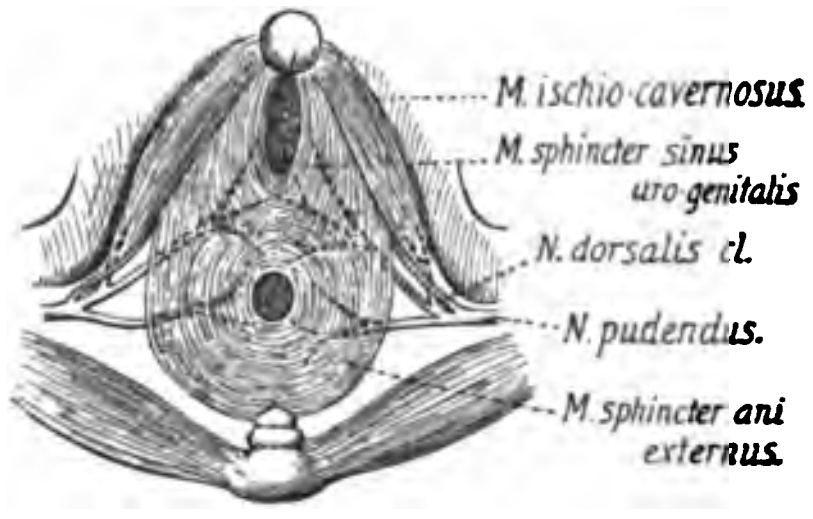

FIG. 343.—(After Popowsky, Anat. Hefte, Bd. 12, Taf. ii, Fig. 4.) Female fetus of 4–5 months.

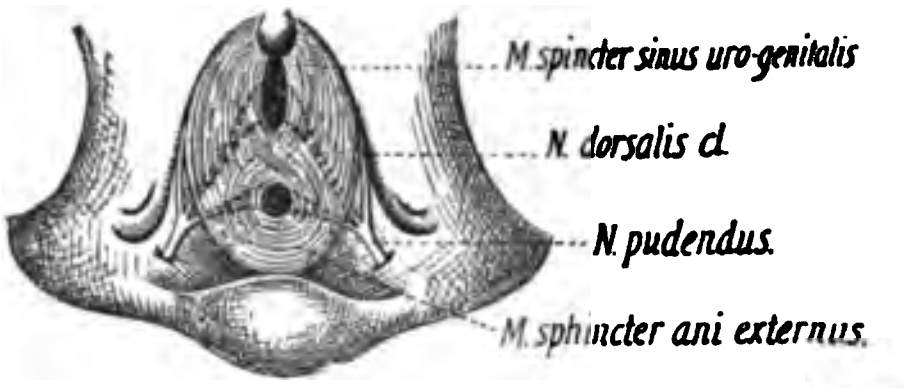

FIG. 341.—(After Popowsky, Anat. Hefte, Bd. 12 Taf. ii, Fig. 2.) Embryo of 3 months.

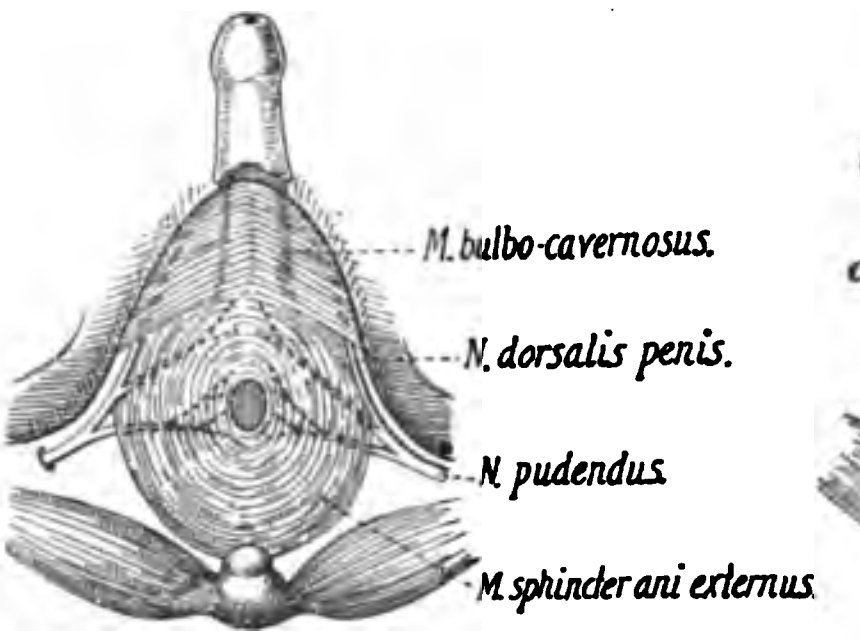

FIG. 342.—(After Popowsky, Anat. Hefte, Bd. 12 Taf. ii, Fig. 3.) Male fetus of 4 months.

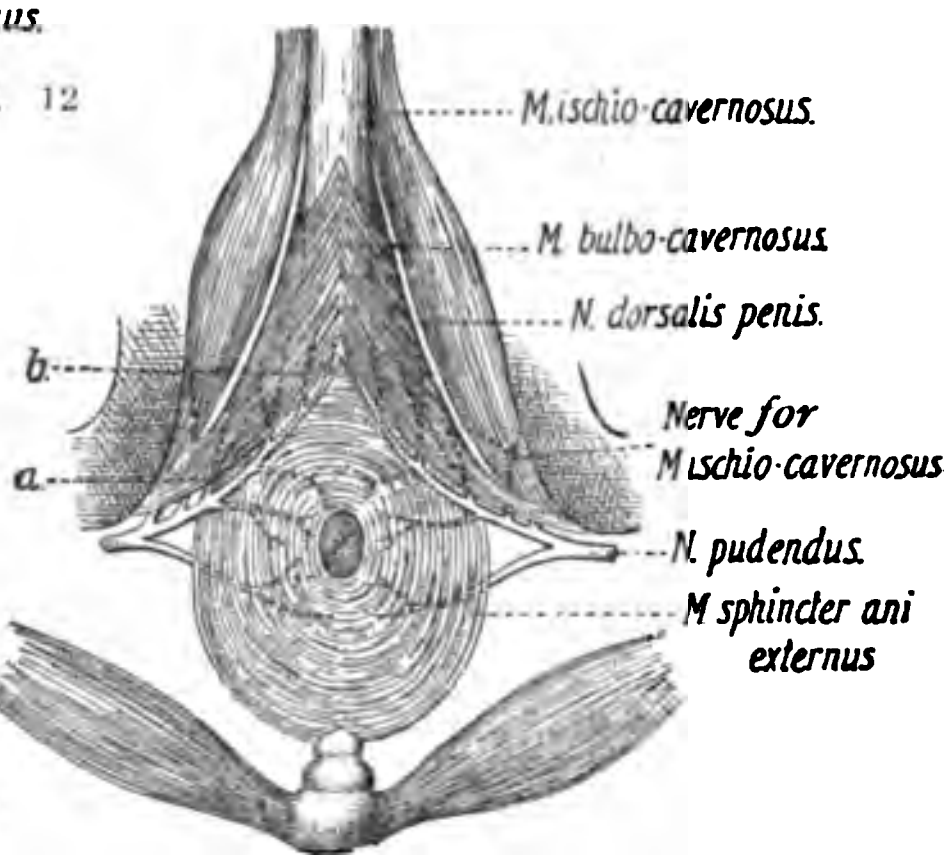

FIG. 344.—(After Popowsky, Anat. Hefte, Bd. 2, Taf. ii, Fig. 6.) Male fetus of 5 months.

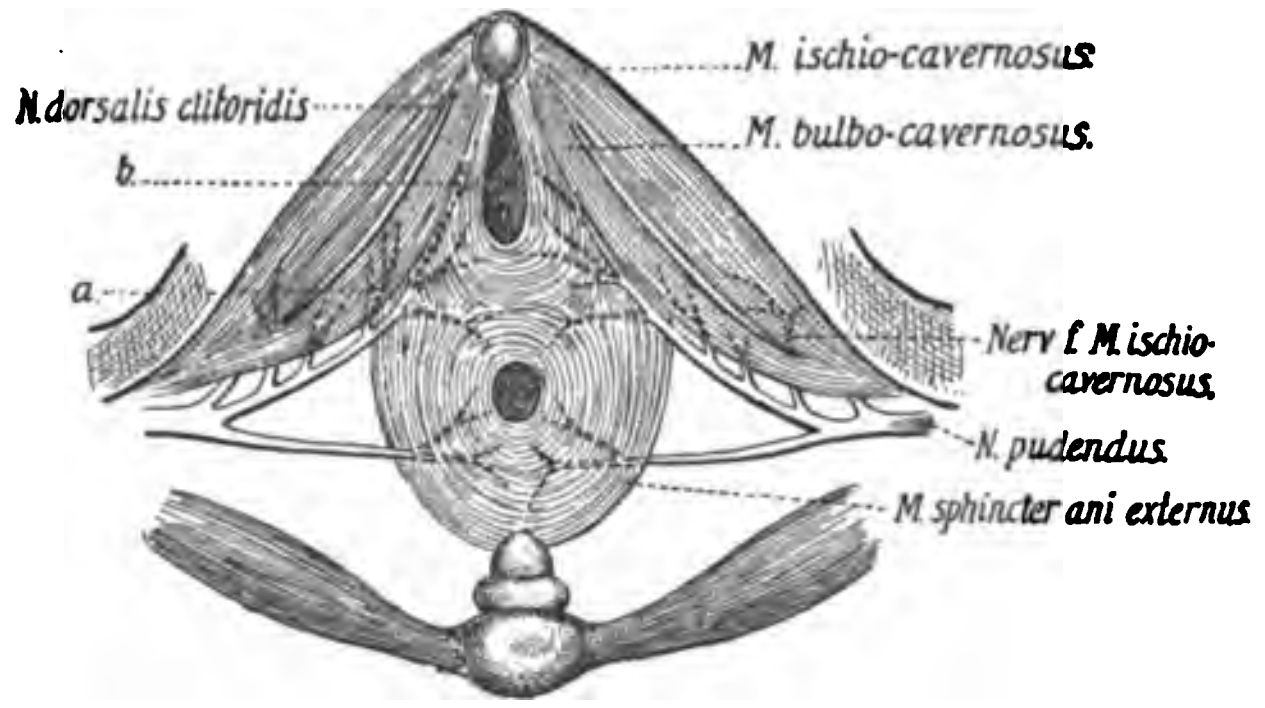

FIG. 345.—(After Popowsky, Anat. Hefte, Bd. 2, Taf. ii, Fig. 7.) Female fetus of 6 months.

versus perinei are the last ones to develop out of the peripheral and lateral part of the M. bulbocavernosus.

The M. levator ani arises from a quite different source and only secondarily comes into relation with the M. sphincter ani and the perineal muscles. The M. levator ani arises in connection with the M. coccygeus and gradually descends to the rectum, bladder, prostate, and vagina and thus comes into contact and intimate union with the muscles of this region.

The difference in the nerve supply between the perineal muscles and the M. levator ani indicates their different origin.

THE VENTROLATERAL MUSCLES OF THE NECK.

Under this heading are included three groups of muscles: (1) the infrahyoid and diaphragm group, (2) the scaleni group, and (3) the levator scapulæ and serratus anterior. The Mm. trapezius and sternocleidomastoideus arise in the occipital region and migrate to the shoulder-girdle, and are described with the muscles of the shoulder-girdle. The myotomes of the cervical region do not appear to extend very far ventrolateralwards into the neck region, as do the thoracic myotomes into the intercostal spaces (Fig. 367). This ventral extension of the thoracic myotomes is closely associated with the origin and development of the ribs. In the cervical region the only apparent ventral extension of the myotomes is between the transverse processes onto the ventral surface of the vertebral column to form the rudiments for the subvertebral muscles. There occurs, however, in the cervical region of very young embryos, 7 mm. in length, closely packed mesenchyme or premuscle tissue in the region where later these three groups of neck muscles differentiate. The origin of this premuscle tissue is uncertain. It may arise entirely from the mesoderm of this region or the myotomes may contribute cells to it, but there is no direct proof of this nor of any distinct myotome buds.

In a 9-mm. embryo the rudiments of the neck muscles are beginning to differentiate. At this stage the infrahyoid premuscle mass is especially well seen and apparently develops more rapidly than the other groups (Fig. 367). In early stages the premuscle tissue is continuous above with the tongue premuscle masses and below with the diaphragm masses. It consists of a distinct band of premuscle tissue extending on either side, from the base of the tongue, caudolaterally towards the tip of the first rib. It forms the most ventral group of the neck muscles and already is supplied by the ramus descendens nervus XII. Above the heart towards the base of the tongue region the two lateral masses approach each other and nearly meet in the midventral line;

as they descend, however, they become widely separated by the heart and occupy a lateral position between the dorsolateral angle of the heart and the vena cava superior. In later stages as the heart descends into the thorax the muscle masses of the two sides approach each other more and more, the approximation extending from above downwards. In a 14-mm. embryo this approximation is nearly complete. At this stage the muscle mass already shows cleavage into the Mm. sternohyoideus, sternothyroideus, and omohyoideus; the latter can now be traced to the scapula. This cleavage process begins in embryos of about 11 mm. in length (Figs. 370, 379). In a 20-mm. embryo the muscles have almost the adult form. The muscles of the two sides lie parallel to each other near the midventral line extending from the hyoid and thyroid cartilages to the rudimentary halves of the sternum.

The diaphragm arises from two premuscle masses, one on either side, which are, in a 9-mm. embryo, closely connected with the caudal end of the infrahyoid masses and at this stage lie in the lower cervical region, and, like the infrahyoid masses, there is no direct proof of their origin from the third to the fifth myotomes (Fig. 369). The diaphragm premuscle mass already extends a short distance into pleuroperitoneal septum, although still some distance above the first rib. The phrenic nerve enters the mass. In an 11-mm. embryo the diaphragm muscle mass has descended some distance into the thoracic cavity, carrying with it the nerve, and all connection with the infrahyoid muscle mass has of course disappeared (Fig. 379). In a 14-mm. embryo the diaphragm and its muscle have descended still farther into the thoracic cavity, to occupy more nearly the adult position, and the muscle masses of the two sides have joined. The muscle is best developed in the dorsal portion of the diaphragm in the region of the vena cava inferior and the œsophagus. The crural attachments to the vertebral column do not develop until later.

The scaleni muscles arise from premuscle tissue, ventral to the lower cervical myotomes. From the material at my disposal I have been unable, however, to trace satisfactorily the early development. Already in an embryo 11 mm. in length three scaleni muscles are fairly well differentiated, with the adult attachments. They apparently develop *in situ* except for the caudal extension of the M. scalenus posterior to the second rib.

The Mm. levator scapulæ and serratus anterior, which arise from the premuscle tissue of the lower cervical region and secondarily migrate to the thoracic region, are described with the muscles of the shoulder-girdle.

THE MUSCULATURE OF THE EXTREMITIES.

The limb buds first appear, in embryos of about 4 mm. in length, as oval projections from the lateral surface of the Wolffian ridge. The arm bud lies opposite the ventral ends of the fifth to eighth cervical and first thoracic segments, and the leg bud opposite the first to fifth lumbar and first sacral segments. At first the limb buds are filled with a closely packed mesenchyme derived from the parietal layer of the mesoderm. As the limb buds increase in size, the myotomes extend ventrally in such a manner that the dorsal attachment of the limb bud lies over the ventral portion of the myotomes.

One of the important and much-disputed questions concerning the origin of the limb muscles is the part which the myotomes play or do not play in their origin. It has often been assumed that the myotomes send off large buds into the limbs which combine in various ways to form the muscles, and that the brachial and lumbosacral nerve plexuses were indicators of the complexity of these combinations. Mall (1898) expressed this idea in describing the relations between nerve and muscle in the following sentence: "As the segmental nerves appear, each is immediately connected with its corresponding myotome, and all the muscles arising from a myotome are always innervated by the branches of the nerve which originally belonged to it." While this remains true for the muscles which actually do come from the myotomes directly, it does not apply to the muscles of the limbs. There are no observations of distinct myotome buds extending into the limbs, such as have been observed in the lower vertebrates or such as can readily be seen extending into the thoracic wall. A number of observers, however, have found in embryos 4.5 to 5 mm. in length a diffuse migration of cells into the limb buds from the ventral and ventrolateral portions of the myotomes that lie opposite the limb buds: Fischel (1895), Ingalls (1907), Kästner (1890), and Kollmann (1891). Ingalls (1907) not only observed this diffuse migration of cells from the ventral portion of the myotomes into the limb buds in an embryo 4.9 mm. in length, but also saw distinct processes from the lateral surface of the myotome near its ventral edge extending lateralwards towards the limb bud.

All observers seem to agree, however, that these migrating cells soon lose their epithelial character and become indistinguishable from the cells of the closely packed mesenchyme filling the limb bud. Kollmann (1891) has pictured these cells from the myotome as forming a continuous band, gradually extending beneath the ectoderm of the limb bud, first on the dorsal then on the ventral side of the limb bud, and continuing on into the ventrolateral body wall. This myotome sheath he pictures as lying between the ectoderm and the axial core of somewhat less closely packed mesenchyme. At the distal end of the limb bud this axial core, according to Kollmann, pushes through the muscle band, thus dividing it into a dorsal or extensor layer and a ventral or flexor layer. Kollman's scheme, however, has not been verified by more recent observers.

Bardeen (1907) and Lewis (1902) were unable to find either myotome buds or distinct migrating cells from the myotomes into the limb buds, and it is possible that the myotomes play no part whatever in the origin of the musculature of the limbs. The character of the mesenchyme found in the early limb buds is very similar to that in the branchial arches from which the head muscles arise. The idea that myotomes play a rôle in the origin of the muscles of the head must be abandoned, even by the most ardent supporter of the segmentation theory. The limbs, phylogenetically and ontogenetically, are of later origin than the branchial arches, and thus there is even less reason for assuming that the limb muscles are derived from the myotomes than that the branchial muscles have a similar origin. As the limbs are of later origin than the trunk musculature, it is but natural to expect the limb musculature to arise independently.

It has been impossible with our present methods for even the strongest adherents of the myotomic origin of the limb muscles to follow the complete history, inasmuch as the cells, if any such are given off from the myotomes, mix with the mesenchyme cells of the limb bud and soon become indistinguishable from them. The description of the differentiation of the limb musculature must begin then, whichever view we may take as to its source, with the first appearance of the premuscle masses in embryos of about 9 mm. in length. Considerable time has thus elapsed between the period when migrating cells have been observed entering the limb buds and the first stages of muscle differentiation.

In both arm and leg the proximal muscles are the first ones to be recognized. There is a progressive proximodistal differentiation, the hand and foot muscles being the last to differentiate. The muscles of the arm differentiate slightly earlier than those of the leg.

THE MUSCLES OF THE SHOULDER-GIRDLE AND THE ARM.

The Shoulder-girdle.—The muscles attached to the shoulder-girdle and connecting it with the trunk may be divided into several groups: (a) the trapezius and sternocleidomastoideus which descend from the occipital region; (b) the rhomboideus major and minor, the levator scapulæ, and the serratus anterior, which arise in the lower cervical region; (c) the subclavius and omohyoideus; (d) muscles, arising from the arm bud, that spread out from the arm and shoulder-girdle to the trunk, the latissimus dorsi, and pectoralis major and minor.

(a) The common rudiment of the Mm. trapezius and sternocleidomastoideus first appears in embryos of about 7 mm. in length, and lies ventral to the two caudal occipital and two anterior cervical myotomes (Fig. 367). It stands, however, more in relation to the branchial arch series than to the myotomic muscles. There are no direct observations on the origin of the cells composing this rudiment, but from its position and nerve supply it may be best considered as the caudal member of the branchial arch series. At this early stage it consists of closely packed cells, indistinguishable from the surrounding mesenchyme cells except for the greater condensation of the mass and the presence of the nervus accessorius which runs for some distance within the mass. The anterior end of the muscle mass lies close to the place where the nervus accessorius leaves the vagus. From this position there is a gradual extension caudalwards towards the arm bud of the premuscle tissue, which in a 9-mm. embryo reaches to about the level of the fourth cervical myotome (Fig. 368). At this stage its caudal end already shows signs of splitting into two divisions for the Mm. sternocleidomastoideus and trapezius. In an 11-mm. embryo the two divisions are quite widely separated caudally, the trapezial portion extending to about the sixth cervical nerve and the sternomastoid portion to near the rudimentary clavicle which at this stage lies far anterior to the first rib (Figs. 337, 347, 367). The trapezius has not attached itself to the shoulder-girdle. The trapezius is a thick columnar mass extending from the occipital region caudalwards parallel and close to the vagus nerve. It has extended only slightly towards the spinous processes and is connected with them by a layer of fascia. The thick deep cervical fascia separates it from the more dorsal lying myotomic muscle masses. In a 16-mm. embryo the entire arm and shoulder-girdle have migrated caudally. The Mm. trapezius and sternomastoideus are now separate and distinct throughout their entire lengths. The trapezius has gained its attachment to the spine of the scapula and adjoining portion of the clavicle (Fig. 349). It has also spread as far caudally as the sixth rib and dorsally towards the spinous processes and ligamentum nuchæ. The anterior end of the muscle does not extend as yet to the occipital cartilage. Not until after the embryo is over 20 mm. in length does the trapezius acquire its adult extent (Fig. 338). The splitting of the trapezius into the divisions sometimes found in the adult is a secondary process and not to be observed in the early embryo.

The M. sternocleidomastoideus also shows marked advance in a 14-mm. embryo, extending as it does from the mastoid process and occipital region to the clavicle. It has already begun to split into two divisions corresponding to the sternomastoid and cleidomastoid. The accessory motor-nerve supply from the cervical region to the trapezius and sternocleidomastoideus is secondary and does not indicate a myotomic origin for any portion of the muscles.

(b) The exact origin of the tissue which gives rise to the Mm. levator scapulæ, serratus anterior, and rhomboidei is uncertain. It has not been possible to trace them back to the myotomes. In a 9-mm. embryo the levator scapulæ and serratus anterior are beginning to differentiate from the mesenchyme in the region of the ventral ends of the lower cervical myotomes (Fig. 368). The premuscle mass forms at this stage a continuous column, with no distinct attachments to the vertebræ or ribs over which it extends for a short distance. In an 11-mm. embryo the muscle mass for the levator scapulæ and serratus anterior is well defined, but still forms a column, oval in section, from the cervical region to the thorax (Fig. 337). The thoracic portion, the future serratus, becomes more and more slender towards the caudal end and has distinct digitations to the upper nine ribs, that to the ninth rib containing but a few fibres. Neither muscle has attached itself to the scapula. The attachments to the cervical vertebræ are present, however. The serratus now begins to change into a broad, flat muscle and the lower digitations enlarge, and in a 14-mm. embryo it begins to resemble the adult form (Fig. 349). At this stage the scapular attachment is present and evidently plays a part in the change of form and extension of the muscle (Figs. 338, 346).

The development of the Mm. rhomboideus major and minor has not been followed. One can distinguish in a 14-mm. embryo the common muscle mass between the dorsal border of the scapula and the spinous processes. Owing to the relatively anterior position of the shoulder-girdle at this stage, the rhomboid mass only covers the uppermost portion of the M. serratus posterior superior. In later stages, as the arm and shoulder-girdle migrate caudally over the thorax, the rhomboidei come to overlap more and more the serratus posterior until finally the adult condition is attained, in which the caudal border of the M. rhomboideus major lies caudal to that of the serratus post. sup.

(c) The M. subclavius apparently develops *in situ* from the mesenchyme of the cervical region before the shoulder-girdle migrates caudally. It is sharply defined in a 14-mm. embryo. At this stage it has an anteroposterior direction, as the clavicle is still some distance anterior to the first rib. As the rib grows towards the midventral line the costal attachment is carried medially, and as this process is taking place the clavicle comes to lie closer to the first rib, and thus the subclavius muscle assumes more and more a horizontal position.

The M. omohyoideus splits off from the infrahyoid muscle mass and has already secured its attachment to the scapula in a 14-mm. embryo.

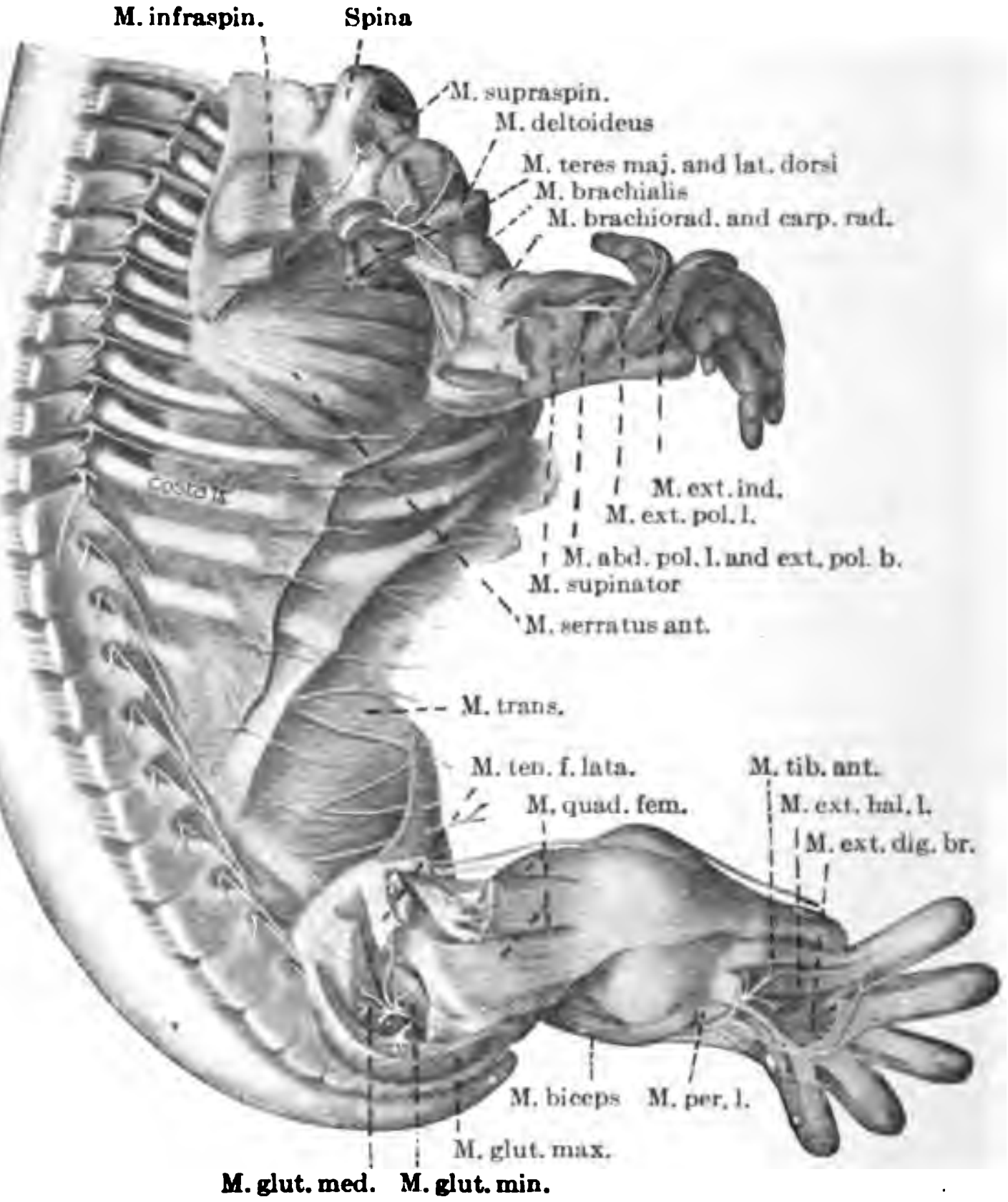

Fig 346.—(After Bardeen and Lewis.) Lateral view of a 20-mm. embryo with deeply dissected trunk and limbs.

(d) The Mm. latissimus dorsi and teres major are closely associated in their origin from the premuscle sheath of the arm, the teres developing *in situ* while the latissimus gradually spreads caudally over the side of the thorax. In an 11-mm. embryo it extends to the fourth rib (Fib. 337), at 14 mm. to the eighth or ninth, and at 16 mm. the attachment to the last three ribs is attained, while dorsally the muscle is continuous with the lumbodorsal fascia. Not until the embryo is over 20 mm. in length do the muscle fibres extend to the crest of the ilium (Fig. 338). The teres major is well developed in an embryo 14 mm. long.

The pectoral premuscle mass from which both the Mm. pectoralis major and minor arise is clearly indicated in a 9-mm. embryo. It lies in the lower cervical region on the medial side of the arm bud. This premuscle mass is widely continuous with the arm premuscle sheath and lies almost entirely anterior to the first rib. In an 11-mm. embryo it reaches about the level of the third rib, but the two muscles still form a single columnar mass attached to the humerus, to the coracoid process, and to the clavicular rudiment (Fig. 347). As the mass differentiates it flattens out and extends caudoventrally to the region of the distal ends of the upper ribs. In a 14-mm. embryo the caudal end of the muscle has extended near to the tip of the fifth rib and the muscle has begun to assume more the adult form, with fibres arising from the upper five ribs and sternal anlage as well as from the clavicle. At this stage the proximal portion of the muscle

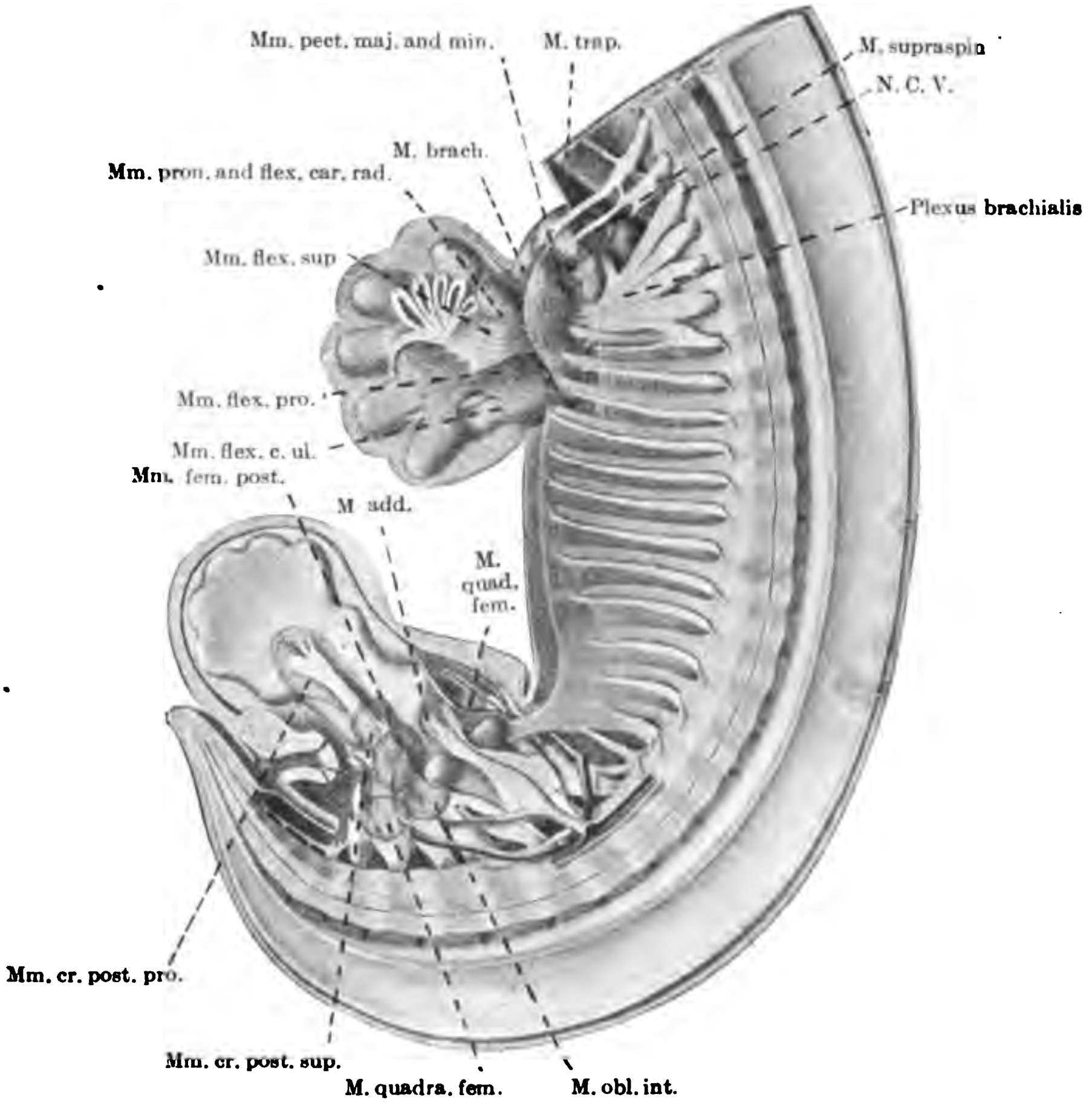

FIG. 347.—(After Bardeen and Lewis.) Median view of body wall and limbs of an 11-mm. embryo.

has split into the major and minor portions, the one attached by tendon to the humerus and the other to the coracoid process. Both muscles fuse together near the costal attachments. In a 16-mm. embryo the two muscles are quite distinct, the pectoralis major now extending to the sixth rib and showing a distinct cleavage between the costal and clavicular portions (Figs. 339 and 349). The pectoralis minor has now its distinct attachment to the second, third, and fourth ribs.

The pectoralis major early splits into a series of overlapping bundles, and during the migration of the muscle the superficial fibres of each bundle move farther caudally than the deeper ones, giving the overlapping condition found in the adult. The tendon of insertion at first consists of a single sheet, but later from its distal end the second deeper sheet gradually spreads proximally and in an embryo of 40 mm. exceeds the superficial or ventral one in breadth. The M. pectoralis major is carried towards the midventral line with the growth of the ribs and sternal rudiments.

The Muscles of the Arm.—The remaining or intrinsic muscles of the arm develop *in situ* and, as they differentiate from the arm blastema, have approximately the same position that they later occupy in the adult. In an embryo of 9 mm. in length the skeletal core has already begun to differentiate as a thick rod in the middle of the arm bud ending distally in the hand plate (Fig. 336). On all sides, however, and at the distal end this skeletal core gradually merges into the surrounding blastemal sheath in which the muscles later appear, although the positions of only the pectoral and latissimus premuscle masses are recognizable at this stage. As the muscles differentiate their tendons likewise form *in situ,* and the muscles are thus from the first in connection with the skeletal structures by a condensed mesenchymal blastema out of which the tendons later develop.

The Muscles of the Shoulder and Arm.—The Mm. deltoideus, teres minor, supra- and infraspinatus arise from a common premuscle mass continuous with the pectoral mass and the common arm sheath (Fig. 336). In an 11-mm. embryo the M. deltoideus has partially split-off from the mass towards its origin from the acromion and clavicula (Fig. 337). In embryos of 14 to 16 mm. in length it has much the adult form (Fig. 349), with usually a distinct slip arising from the fascia over the M. infraspinatus. In a 20-mm. embryo it has practically the adult form and attachments (Figs. 338, 339, 346, 348). The development of the acromion from the cephalic border of the scapula separates in part in an 11-mm. embryo the M. supraspinatus from the M. infraspinatus. The M. supraspinatus lies at first on the medial surface of the scapula (Fig. 347). Later it comes to lie along the cephalic border, as in 16-mm. and 20-mm. embryos (Fig. 350, 351, 346), and only in later stages, with the growth of the cephalic border, does the muscle acquire its position on the lateral surface of the scapula. The Mm. infraspinatus and teres minor are from the first very closely associated and cover in an 11-mm. embryo only a portion of the lateral surface of the scapula (Fig. 337). In a 14-mm. embryo the muscle is quite distinct from the M. deltoideus, but does not cover the whole of the fossa infraspinata even in a 16-mm. or 20-mm. embryo (Figs. 349, 338, 346).

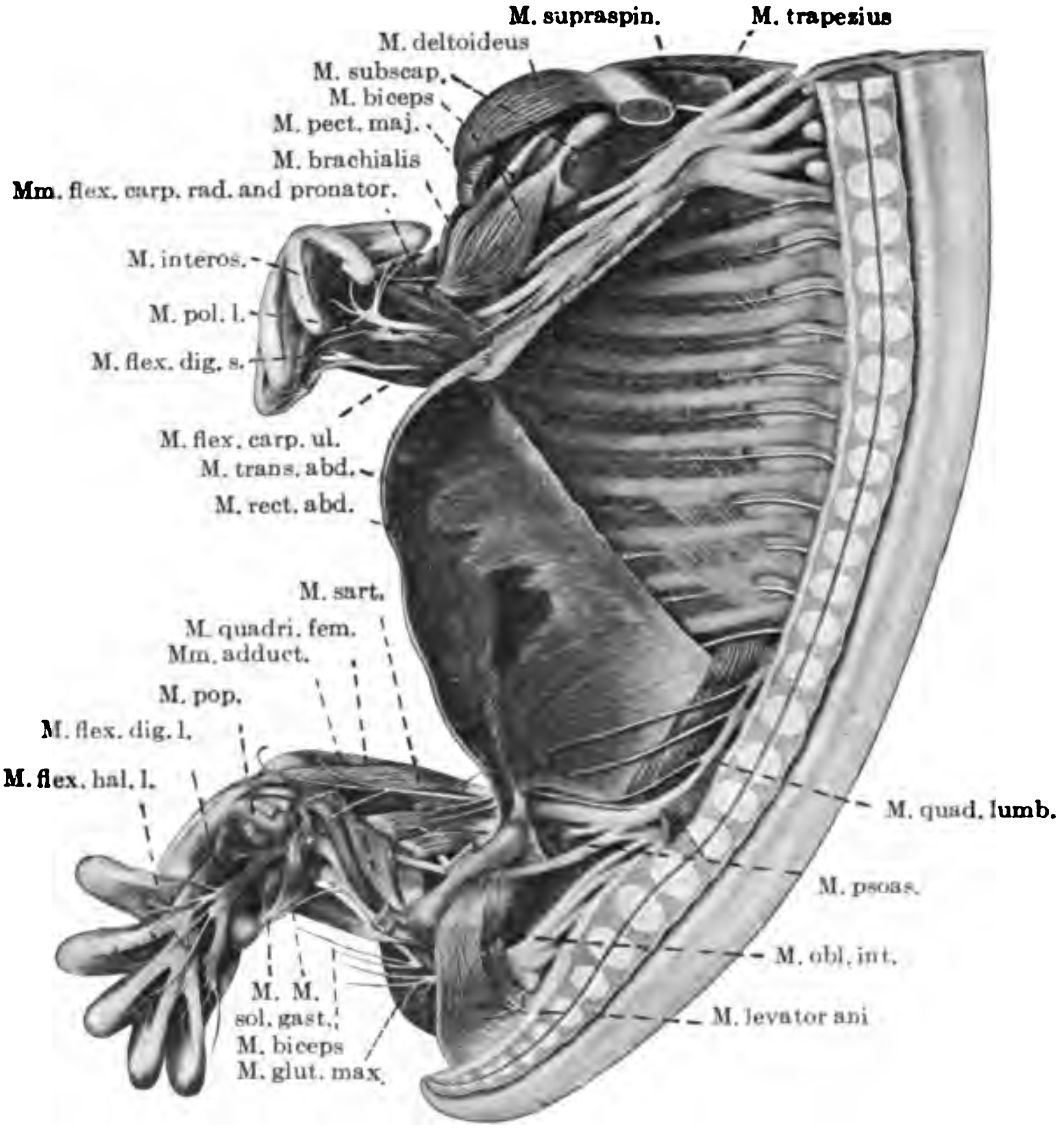

FIG. 348.—(After Bardeen and Lewis.) Median view of body wall and limbs of a 20-mm. embryo.

The M. subscapularis is more or less isolated from the other muscles from its first appearance, and occupies in an 11-mm. embryo only a small portion of the median surface of the scapula, and not until the embryo is more than 20 mm. in length does it occupy the entire medial surface of the scapula (Figs. 350, 351).

The M. triceps brachii arises along the posterior and lateral surfaces of the humerus extending from the scapula to the ulna, and even in an 11-mm. embryo indications of the three heads are present, while in a 16-mm. embryo they are very distinct (Figs. 337, 338, 346, 349, 350, 351).

The Mm. biceps brachii, coracobrachialis, and brachialis are intimately fused together in very early stages and probably arise from a common premuscle mass. The places of origin of the two heads of the biceps at this early stage are close together, and only by the later growth of the scapula do they become separated. The three muscles are to be recognized in embryos of from 14 to 16 mm. in length, and the long tendon of the caput longum is to be recognized in an embryo of 14 mm. The distal end of the common muscle mass differentiates later than the proximal (Figs. 338, 339, 346, 347, 348, 349, 350, 351).

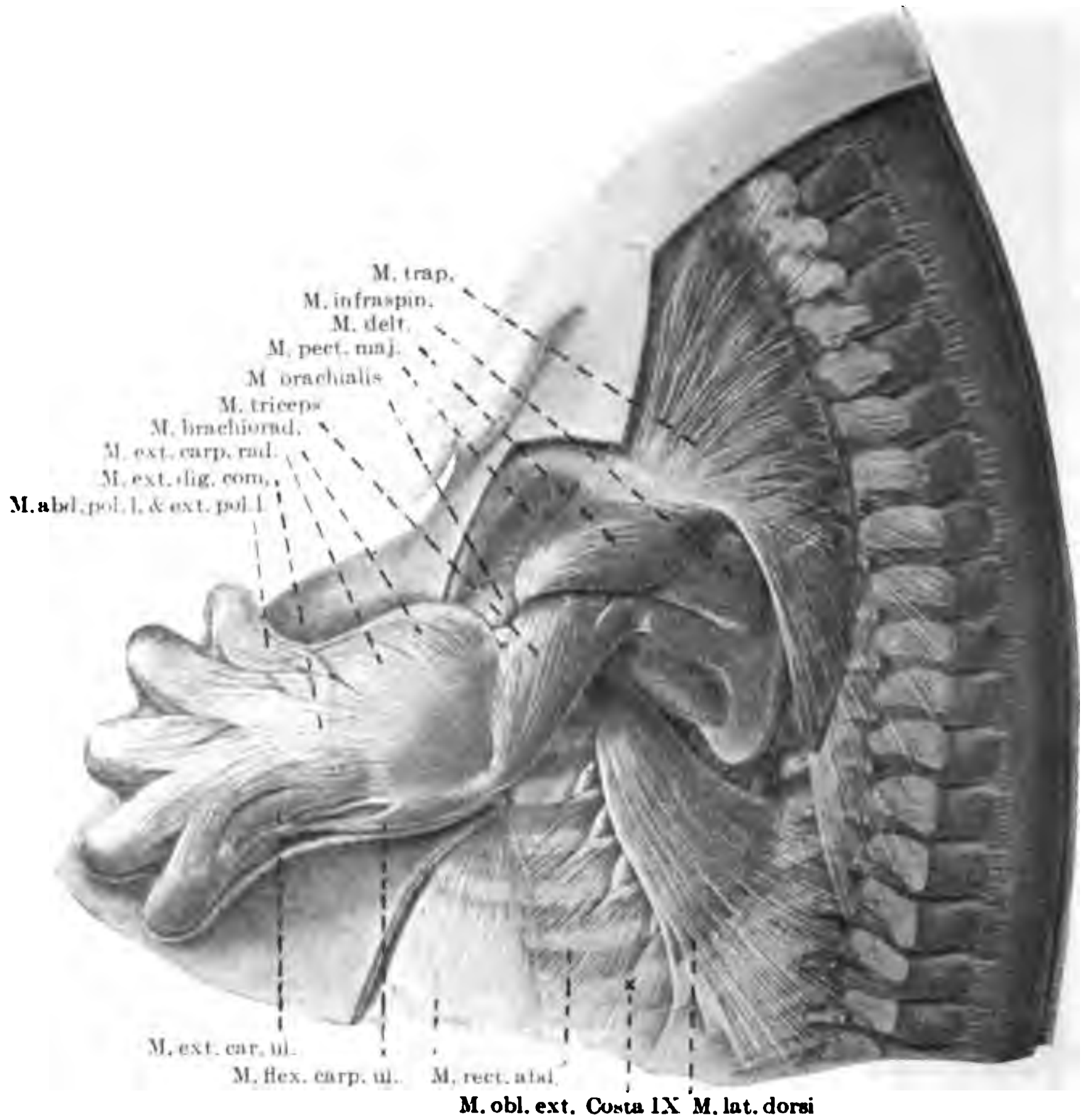

Fig. 349.—(After Lewis.) Lateral view of arm of a 16-mm. embryo.

The Extensor Muscles of the Forearm.—The extensors differentiate somewhat earlier than the flexors (Figs. 337, 338, 339, 346, 349). The common extensor premuscle mass on the laterocephalic side of the forearm first splits, in an embryo of about 11 mm. in length, into three groups of muscles, of which the largest and most superficial extends from the lateral condyle to the four ulnar digits. It is a thin layer spreading over the ulnar two-thirds of the forearm and distally joining the undifferentiated blastema of the digits. On its radial side proximally it is intimately fused with the second or radial group. From the superficial extensor mass later differentiate the Mm. extensor digitorum communis, extensor carpi ulnaris, and the extensor digiti quinti proprius. (According to Gräfenberg (1905), the ext. dig. V. prop. arises in common with the deep extensor mass.) The separation of the muscles of the superficial extensor mass begins in the carpal region and extends proximally (Gräfenberg) in the later stages

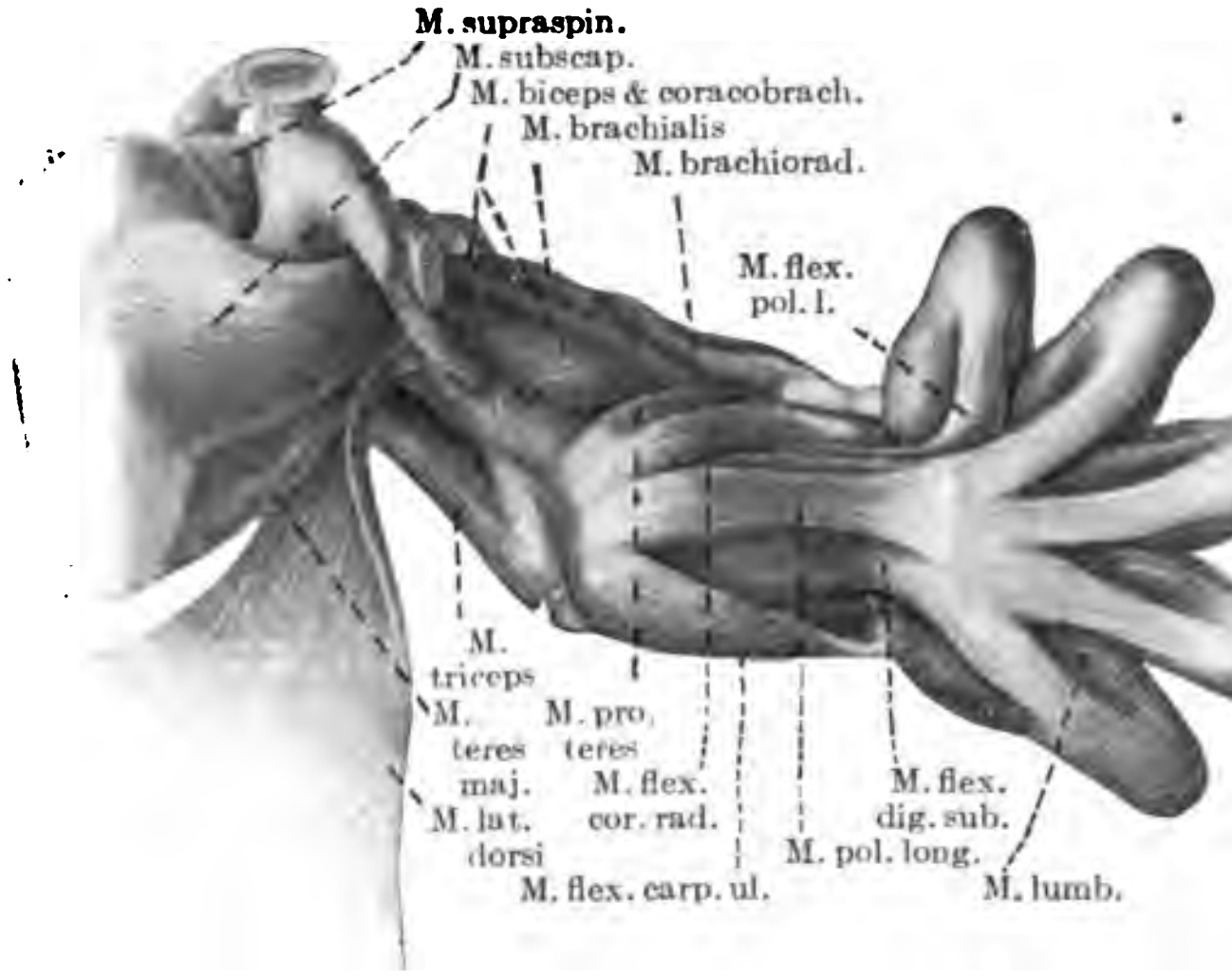

FIG. 350.—(After Lewis.) Median view of arm of a 16-mm. embryo.

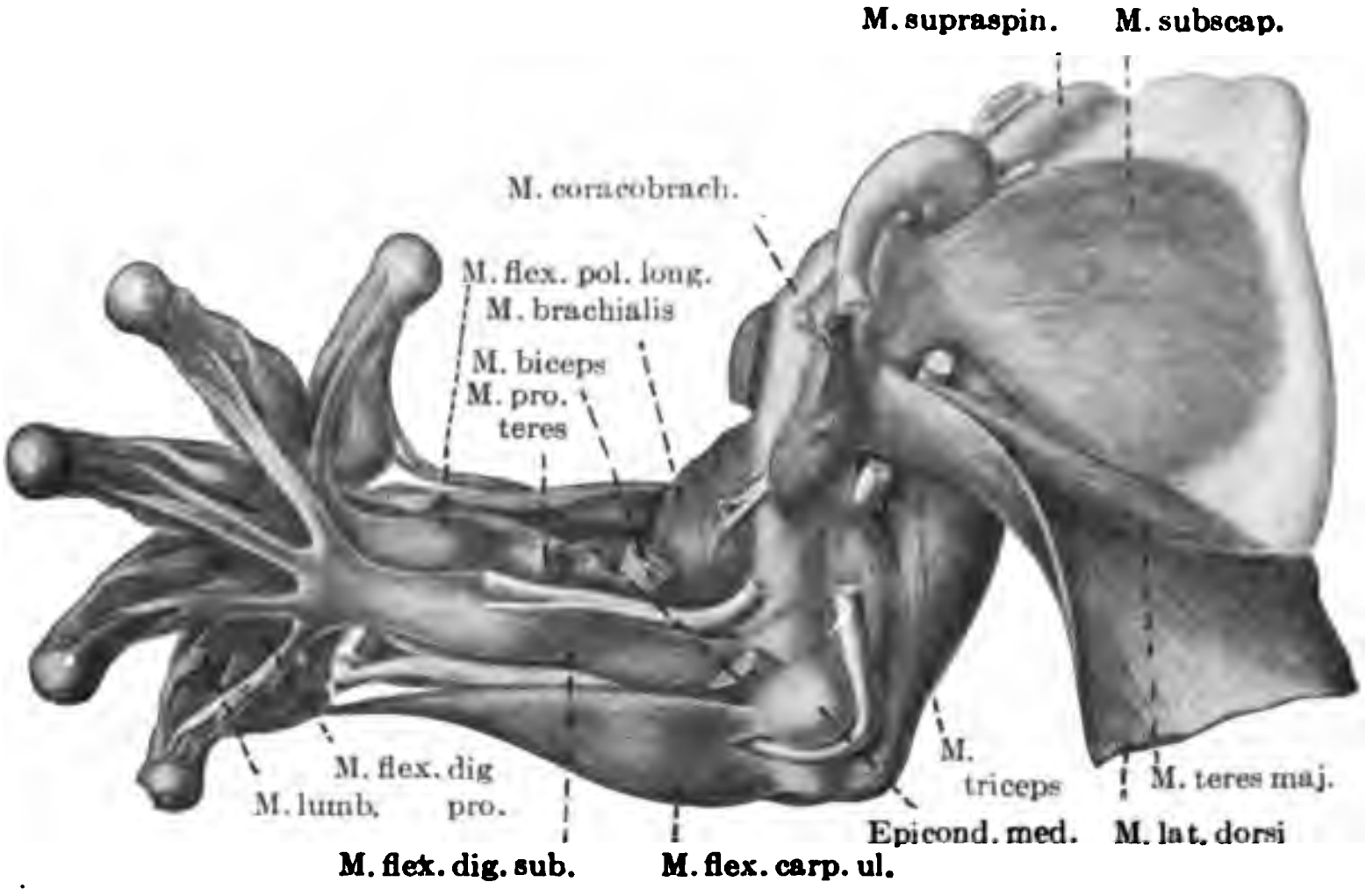

FIG. 351.—(After Lewis.) Median view of arm of a 20-mm. embryo deeply dissected.

as the tendons differentiate from the blastema of the digits. The radial group extends from the epicondylus lateralis and adjoining portion of the humerus distally along the radial and adjoining extensor or dorsal surface of the forearm. It appears to arise *in situ* along the radial surface, and not to have wandered there from the extensor surface as claimed by Gräfenberg (1905). The mass early divides into two parts at the distal end, one, the brachioradialis, fusing with the distal end of the radius, and the other, the extensor carpi radialis longus and brevis, passing beneath the deep extensor mass to fuse with the blastema at the proximal ends of the second and third digits. The deep extensor mass lies beneath the radial portion of the superficial, becoming itself superficial over the distal radial surface of the radius and carpus and fusing with the blastema of the first and second digits. At a later stage this mass divides into two groups, a radial one for the Mm. abductor pollicis longus and extensor pollicis brevis, and probably the supinator, and an ulnar division for the extensor pollicis longus and extensor indicis proprius.

Not until the embryo is about 20 mm. in length does the complete isolation process of the various extensor muscles reach an end. The extensor digiti V. prop. is not split off until later.

The Flexor Muscles of the Forearm.—The development of the flexors is more difficult to follow than the extensors, and, owing to the concave volar surface of the forearm and carpus, the flexor muscle masses extend much farther distally than do the extensors (Figs. 347, 348, 350, 351). In an 11-mm. embryo, however, one can distinguish a small superficial layer and a voluminous deep layer. The superficial layer lies more on the radial side of the volar surface and already shows indications of a radial mass extending from the epicondylus internus to the blastema at the distal end of the radius; later this mass splits into the Mm. flexor carpi radialis and the pronator teres. The latter extends farther distally on the radius in early stages, but, as the distal part of the radius grows faster than the proximal, the distal attachment of the pronator comes to lie farther and farther from the distal end of the radius. The remaining portion of the superficial layer develops into the M. palmaris longus. It is intimately fused with the proximal part of the radial mass, but distally it extends on to the volar surface of the carpus, but with the elongation of the skeleton of the forearm the muscular belly comes to lie more and more over the proximal portion of the forearm.

The deep flexor muscle mass is much more extensive and thicker than the superficial, extending from the epicondylus internus over the entire volar surface of the forearm and carpus into the blastema of the digits. Even in an 11-mm. embryo the ulnar side already shows the beginning of the splitting off of the M. flexor carpi ulnaris which reaches to the blastema of the os pisiforme (Fig. 347). As the M. flexor carpi ulnaris increases in size it spreads over the ulnar side of the deep flexor mass and in an embryo 16 mm. in length is quite a distinct muscle.

The remainder of the deep flexor mass, even in an 11-mm. embryo, shows indication of cleavage into a superficial flexor digitorum sublimis and a deeper flexor digitorum profundus. The mass extends from the epicondylus internus and volar surface of the forearm distally over the carpus without indications at this stage of a longitudinal splitting over the carpal region. The thick portion of the muscle in the carpal region has been designated as a separate M. flexor digitorum brevis by Gräfenberg, but it appears to represent merely the distal part of the mass which later recedes to the volar surface of the forearm as the latter increases in length. The tendons of the two layers of the deep flexor mass gradually differentiate from the blastema of the digits and develop *in situ* as the digits increase in length. In an embryo 20 mm. in length the characteristic adult arrangement of the tendons is attained, although the recession of the muscle bellies on to the forearm is not complete nor the longitudinal splitting which progresses in a distal proximal direction. At this stage the M. flexor pollicis longus is easily recognized, although it is not completely split off from the M. flexor digitorum profundus. The Mm. lumbricales appear to differentiate *in situ* from the distal portion of the deep flexor mass, and I have first been able to recognize them in an embryo 16 mm. in length, but they probably appear slightly before this stage.

The origin of the M. pronator quadratus is uncertain, and I am not able to determine whether it splits off from the deep flexor mass or arises independently. It is easily recognized in an embryo of 16 mm. According to Gräfenberg, it has a greater proximal extent in early stages than in the adult.

The Intrinsic Muscles of the Hand.—The Mm. interossei appear to arise from a common volar muscle mass. In a 16-mm. embryo the first signs of differentiation appear; later the common muscle mass splits into the various muscles which migrate from the volar surface towards the dorsal surface of the hand between the metacarpals.

The Mm. abductor dig. V. and flexor digiti V. arise from a common muscle blastema, lying more on the ulnar side, and later wander volarwards (Gräfenberg). The M. opponens dig. V. differentiates from the common interossei muscle mass (Gräfenberg).

The thumb muscles develop from a common muscle mass, except the M. adductor pollicis, which is always separated from the others by the tendon of the M. flexor pollicis longus.

THE MUSCLES OF THE LEG.

The muscles of the leg, like those of the arm, develop from the premuscle sheath of condensed mesenchyme which surrounds the axial skeletal rudiment. In embryos of about 11 mm. in length this common muscle blastema begins in the proximal part of the leg to differentiate into the muscles. According to Gräfenberg (1904), the nerves enter a common muscle mass for each group and later this mass splits into the various muscles of the group. Gräfenberg's description thus corresponds with that given for the arm. Bardeen (1907), however, finds that the individual muscles differentiate separately from the general muscle blastema, first as small centres about their nerves, and from these centres the muscle gradually extends towards origin and insertion. Whether this extension is brought about by differentiation of the mesenchyme into muscle or by active proliferation of cells of the original muscle nucleus is not clear from Bardeen's account. If we assume, however, that in these early stages the mesenchyme continues to be transformed into muscle about the original centre, Bardeen's observations come more into accord with the observations of Gräfenberg and Lewis (1902). Bardeen's (1907) account is here adopted as a basis for the following section on the development of the muscles of the leg.

The Femoral Group.—The femoral group, comprising the Mm. iliopsoas, iliacus, pectineus, quadriceps femoris, and sartorius, arises from the muscle blastema on the ventral side of the thigh and into it pass the N. femoralis and its branches.

The M. iliopsoas arises from that portion of the femoral blastema which embraces the N. femoralis as it passes into the limb bud. In subsequent development the M. iliacus spreads out over the ilium and the M. psoas major extends upwards along the roots of the femoral nerve to form its attachment to the vertebral column (Fig. 355), and in close union the two muscles extend distally to be attached to the trochanter minor. The M. psoas minor seems to split off from the M. psoas, but this is uncertain.

The origin of the rudiment of the M. pectineus is uncertain, but it probably arises either from the iliopsoas mass or the M. adductor longus. In a 14-mm. embryo it is quite distinct, extending from the pubis to the femur (Fig. 354). A portion of the muscle probably arises in connection with the M. obturator externus.

The rudiment of the M. quadriceps femoris first appears in an embryo of about 11 mm. in length as a single mass lying over the anterolateral aspect of the middle of the shaft of the femur (Figs. 337, 347, 352, 353). In a slightly older embryo the mass

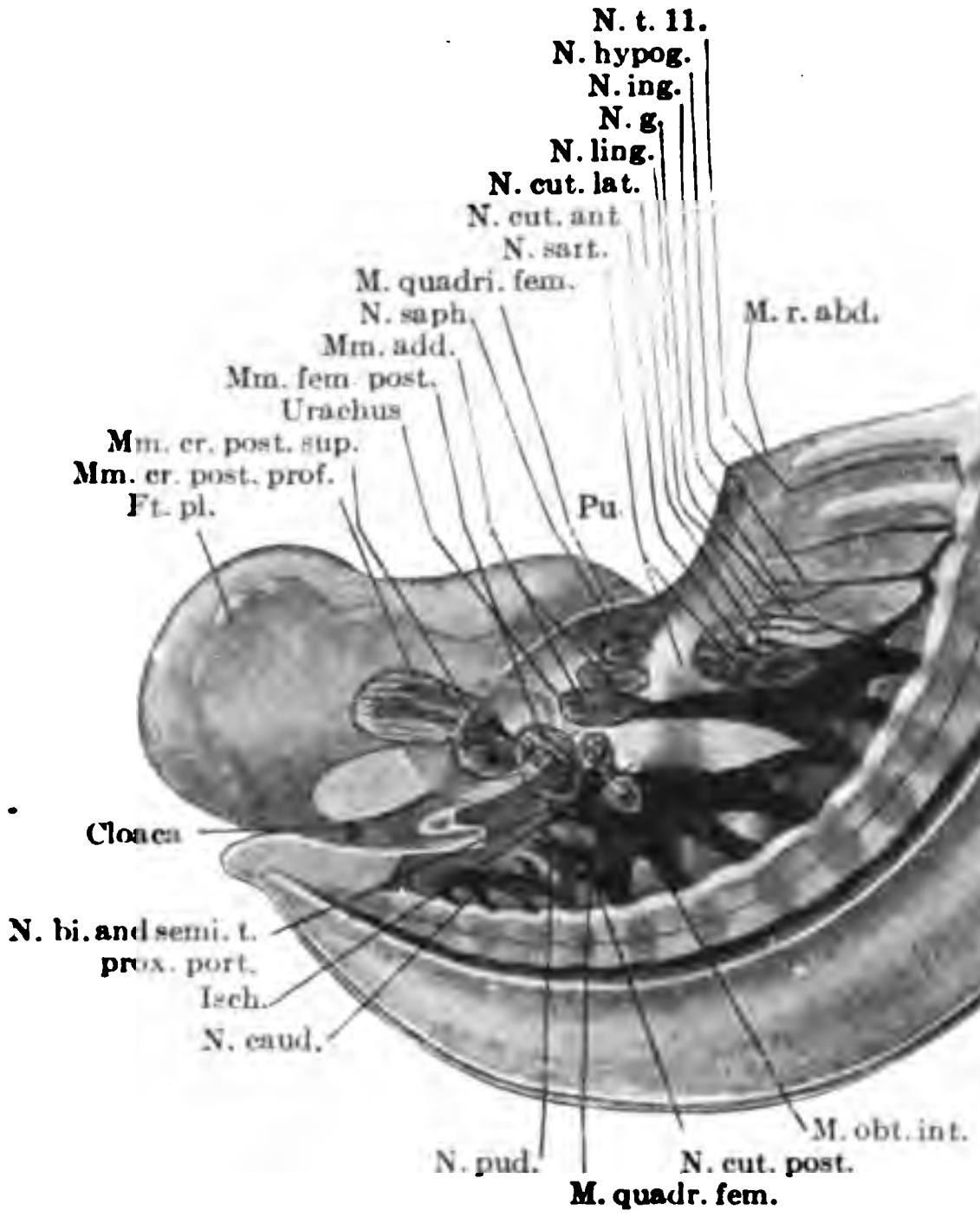

FIG. 352.—(After Bardeen.) Median view of premuscle masses of leg of an 11-mm. embryo.

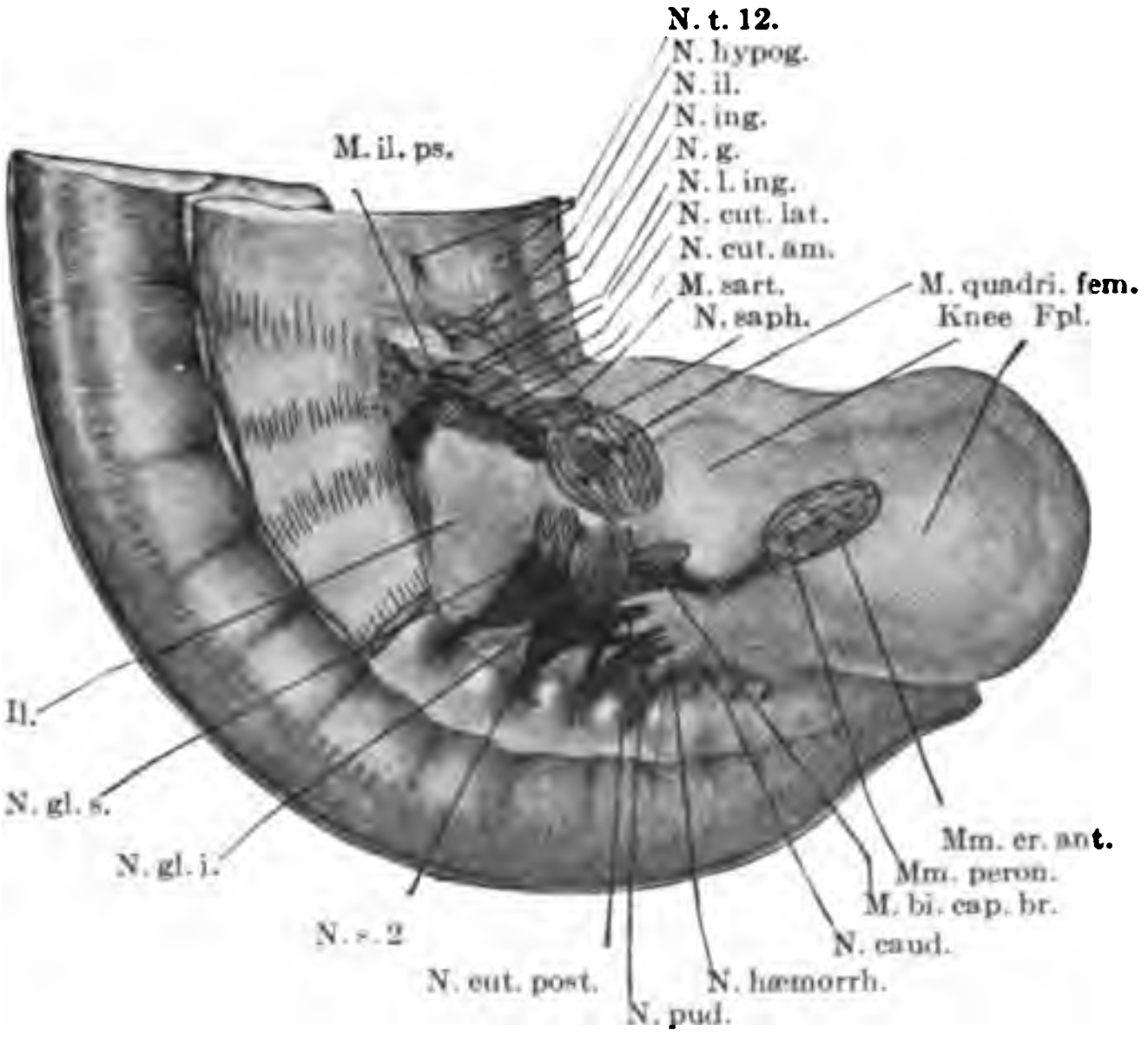

FIG. 353.—(After Bardeen.) Lateral view of the premuscle masses of the leg of an 11-mm. embryo.

begins to show definite differentiation into the four portions, the Mm. rectus femoris, vastus lateralis, vastus intermedius, and vastus medialis (Fig. 354). In a 20-mm. embryo the various muscles of this group are all clearly demarcated and attached to the skeletal apparatus by distinct tendons (Figs. 338, 346, 355).

The M. sartorius appears to arise from a distinct rudiment proximal to that of the quadriceps mass (Fig. 353), and differentiation gradually extends towards the ilium and tibia. The M. sartorius is at first relatively larger than the quadriceps group, but by the fourth month the quadriceps have overtaken it and at birth it is only a little larger relatively than in the adult (Figs. 354, 355, 358, 357, 339, 348).

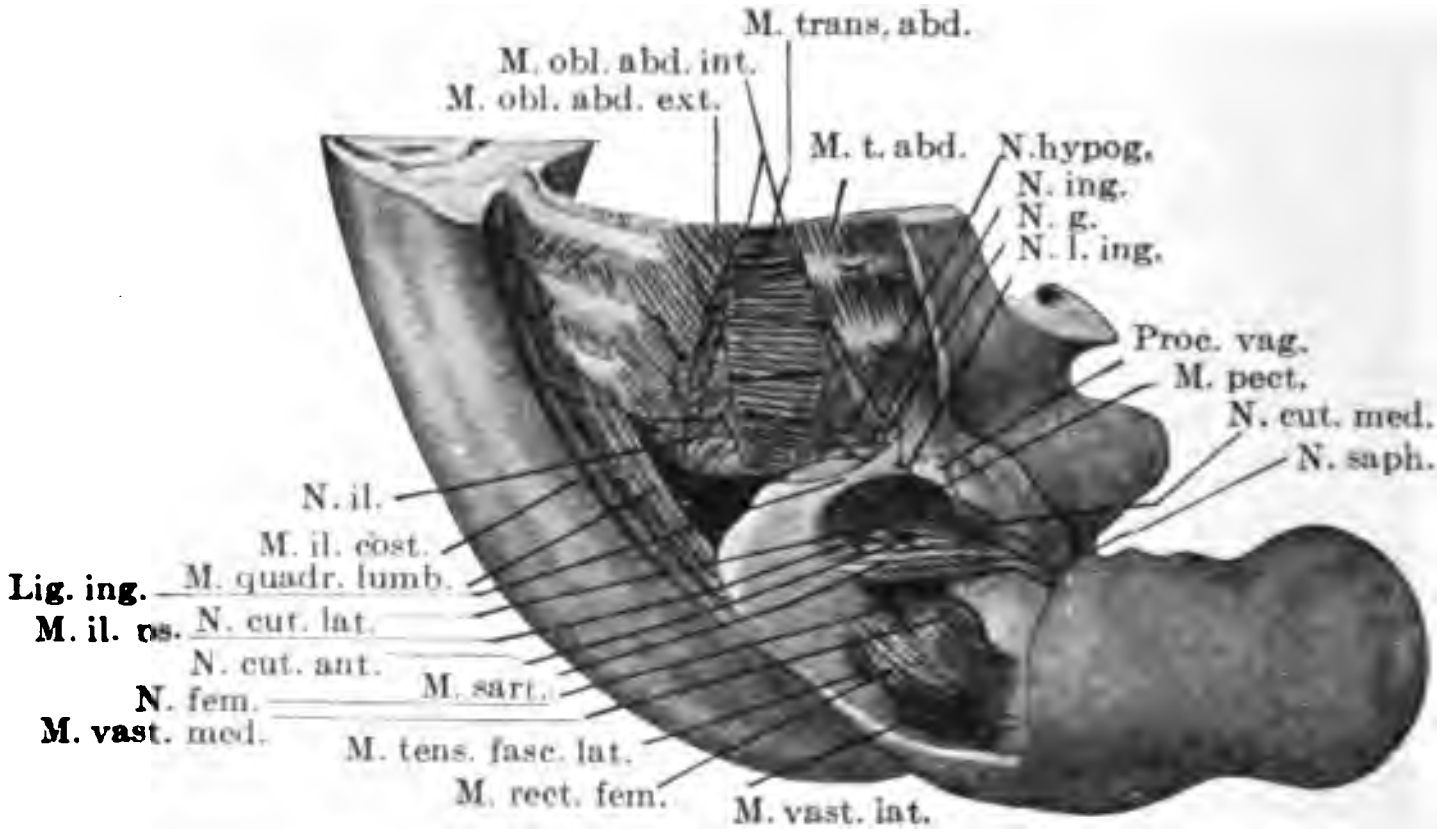

Fig. 354.—(After Bardeen.) Lateral view of the muscles of the thigh of a 14-mm. embryo.

The Obturator Group.—The obturator group probably arises from a common muscle mass lying along the anteromedial portion of the femur (Figs. 347, 352). Cleavage is first apparent, in an 11-mm. embryo, in the proximal section of the region, into masses, one for the obturator portion of the M. adductor magnus and possibly also the M. obturator externus, the other for the Mm. adductor longus and brevis and the gracilis. In an embryo of 14 mm. the individual muscles may be clearly recognized, although the tendons are not as yet well differentiated (Figs. 356, 359). But by the time an embryo is 20 mm. in length the tendons of origin and insertion are well differentiated to the skeletal attachments (Figs. 348, 357, 358, 359, 360) and the obturator and sciatic portions of the M. adductor magnus have fused.

The Gluteal Muscles.—According to Gräfenberg, all the hip musculature, including the Mm. glutæus maximus, medius, and minimus, tensor fasciæ latæ, piriformis, obturator internus, gemellus superior and inferior, and quadratus femoris, arise from a cone-shaped mass found at the distal end of the pelvis during the fifth week. Bardeen derives these muscles from four rudiments which first appear about the ends of their nerves.

The superior gluteal group consists of the Mm. glutæus medius and minimus, piriformis, and tensor fasciæ latæ, which are intimately united in embryos 11 mm. in length (Figs. 337, 353). In a 14-mm. embryo the M. tensor fasciæ latæ has split off from the lateral edge of the two gluteals. According to Gräfenberg, the M. tensor fasciæ latæ is at first inserted into the rudiment of the trochanter major, but after splitting off from the gluteal it migrates laterally and loses its attachments to the trochanter (Figs. 338, 346). At this stage the M. piriformis is still closely fused with the gluteals, which lie over the acetabulum, extending from the femoral margin of the ilium to the rudiment of the trochanter major. The Mm. glutæus medius and minimus gradually extend over the surface of the ala oss. ilium. Gräfenberg finds that the M. piriformis is from the first attached to the sacrum, but, according to Bardeen, it is at first separate and only later extends to its sacral attachment.

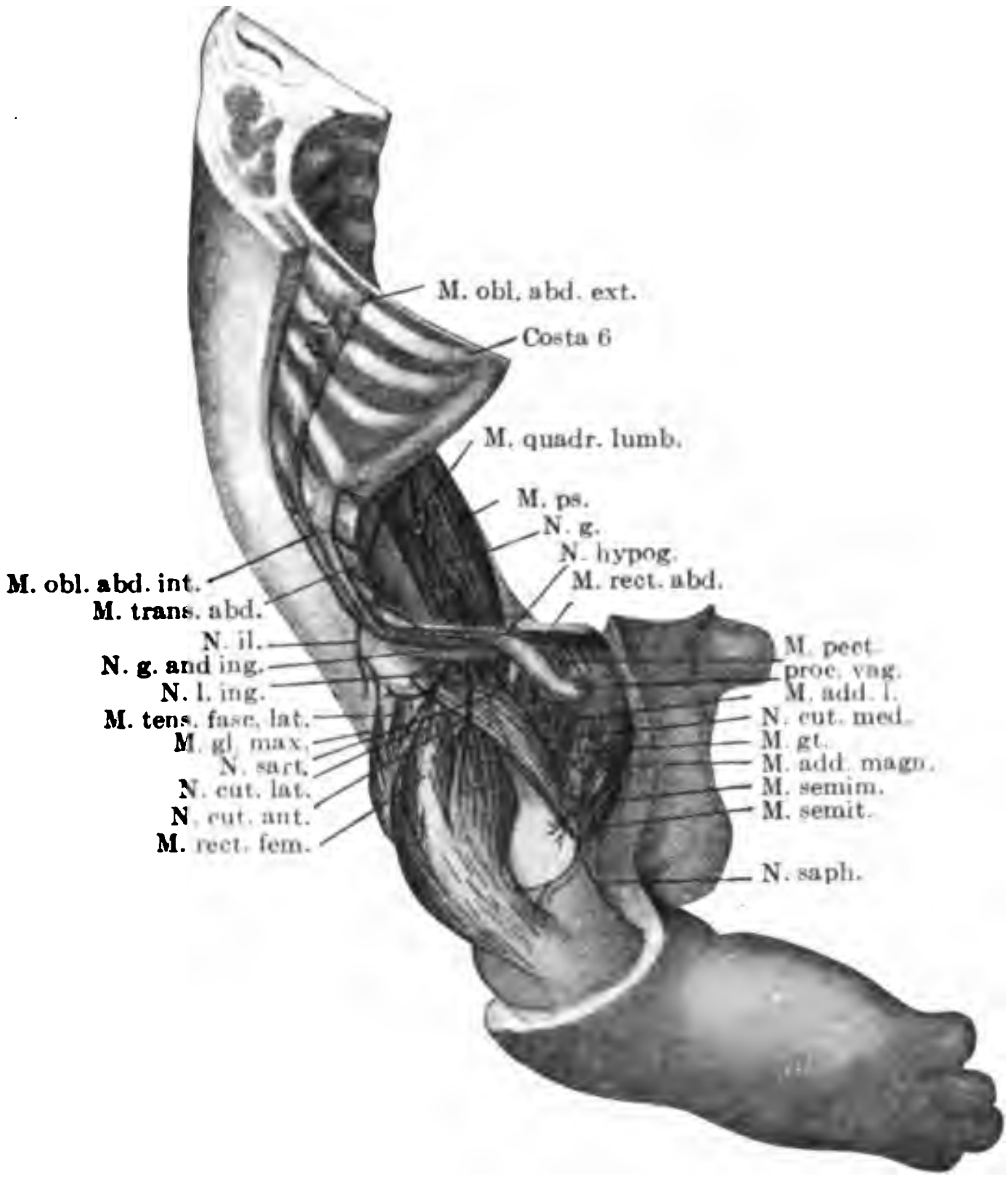

FIG. 355.—(After Bardeen.) Lateral view of the muscles of the thigh of a 20-mm. embryo.

The rudiment of the M. glutæus maximus is separate from that of the other gluteal muscles (Bardeen) and slightly fused with the rudiment of the short head of the biceps. At first it only slightly overlaps the M. glutæus medius in the trochanteric region, but it gradually extends over this muscle to the ilium, sacrum, and coccyx, and becomes separated into two portions, one being inserted into the femur and the other into the fasciæ latæ. In the embryo each portion has a separate nerve.

The M. quadratus femoris (Figs. 347, 352, 359, 360) seems to arise early from a distinct rudiment lying between the anlage of the tuber ischiadicum and the trochanter major, but close to the rudiment for the Mm. obturator internus and gemelli on the ischial side of the hip-joint (Bardeen). The Mm. obturator internus and gemelli are at first closely united, but, as the obturator extends over the pelvic surface of the foramen obturatum from its original attachment to the ischium, the two gemelli retain the original attachment and are thus split off from the obturator. The nerve of the M. obturator int. is carried into the pelvis with the extension of the muscle.

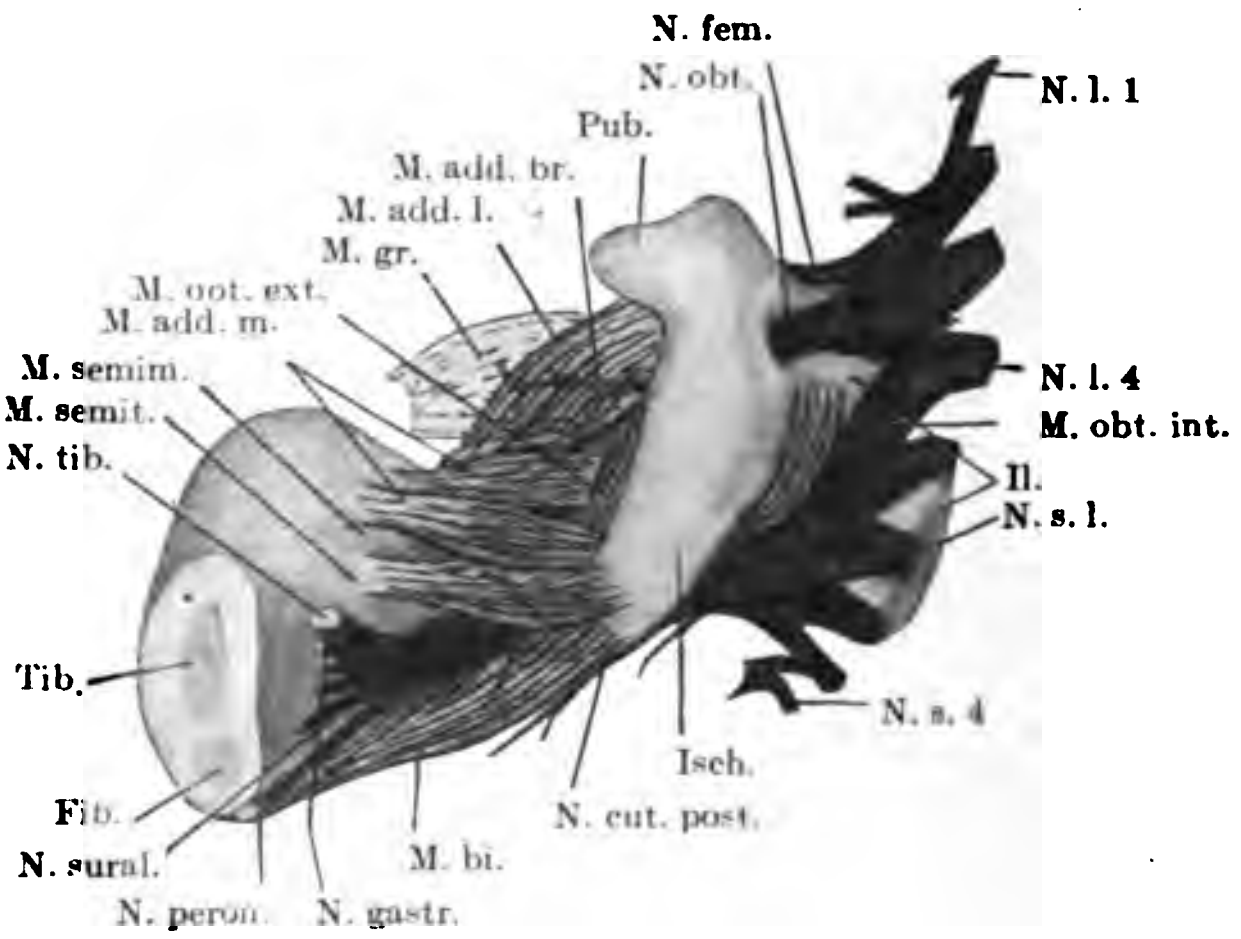

FIG. 356.—(After Bardeen.) Superficial flexor muscles of the thigh of a 14-mm. embryo.

The Posterior Thigh Muscles.—The hamstring muscles, including the Mm. semitendinosus, semimembranosus, biceps femoris, and the sciatic portion of the M. adductor magnus, differentiate from the muscle blastema on the dorsal (plantar) side of the thigh (Figs. 347, 352). They are all distinctly differentiated in a 14-mm. embryo (Fig. 356). The M. semimembranosus arises from a special rudiment in close association with the sciatic portion of the M. adductor magnus (Bardeen). In a 20-mm. embryo the tendons of origin and insertion are already developed (Figs. 348, 357). The M. semitendinosus, according to Bardeen, arises from two separate rudiments corresponding to its two nerves. Gräfenberg, however, finds but a single rudiment. The muscle is well differentiated in a 20-mm. embryo, but its tendon of insertion is attached relatively more distally on the tibia than in the adult.

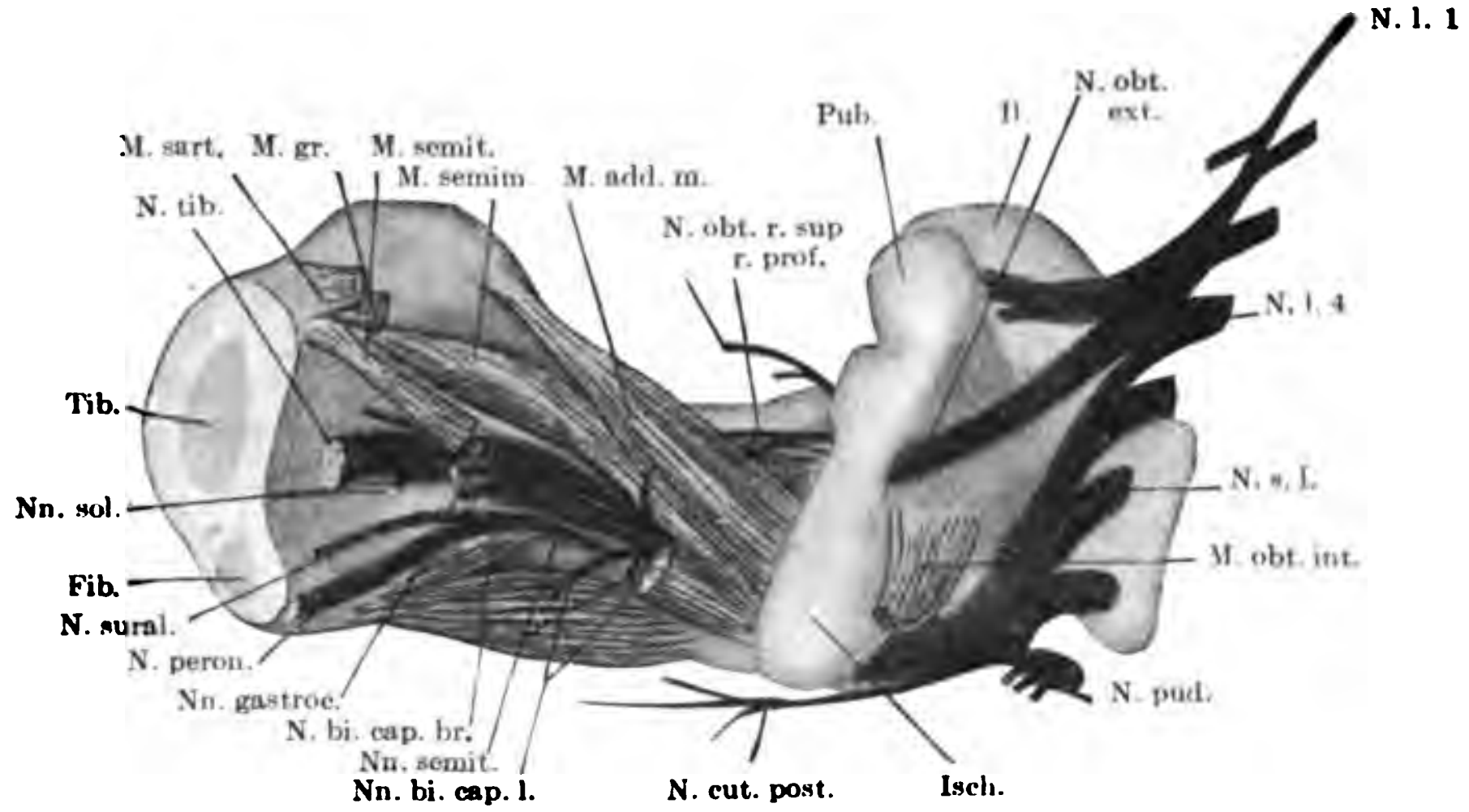

FIG. 357.—(After Bardeen.) Deep muscles of the thigh of a 20-mm. embryo.

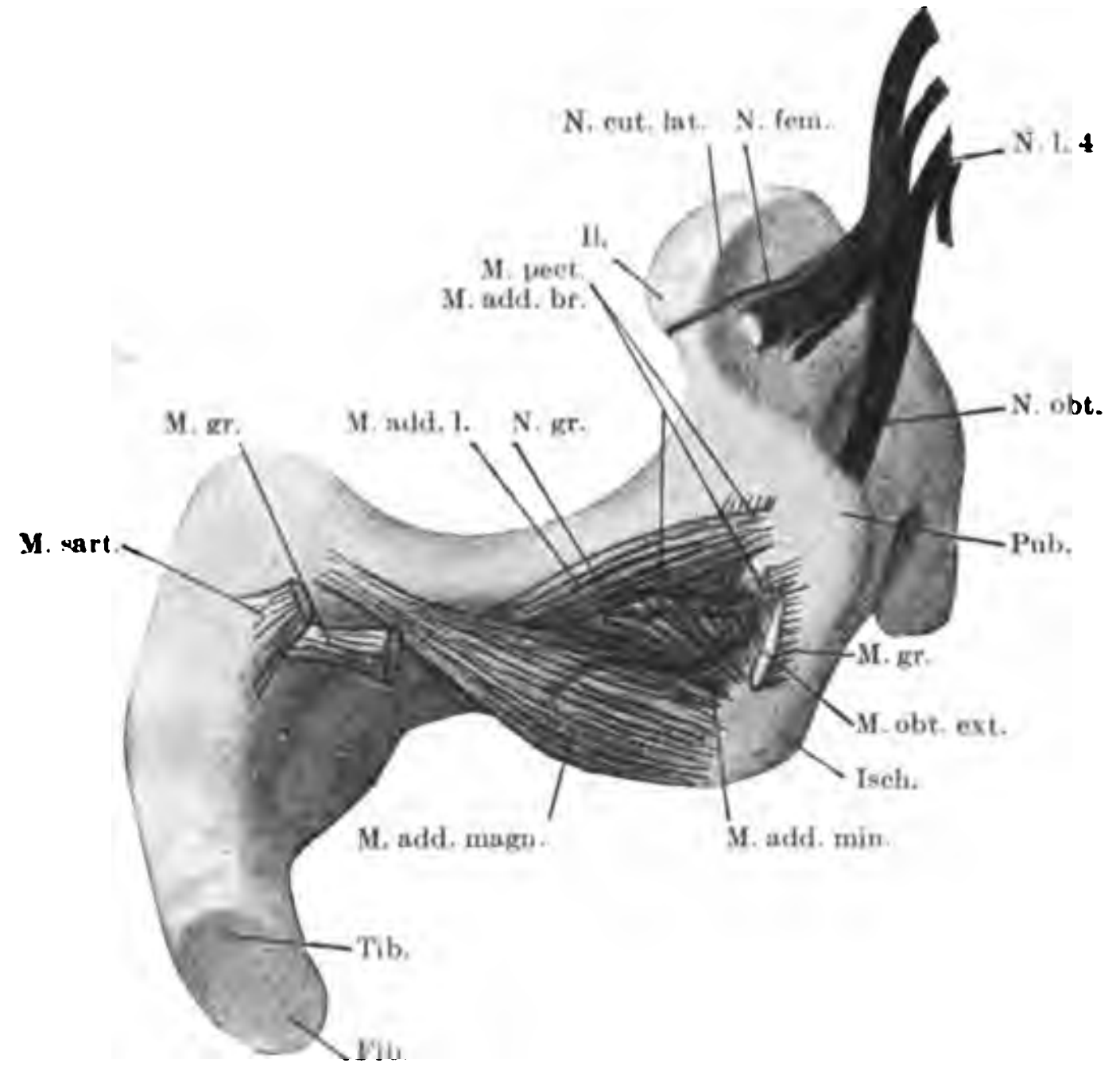

FIG. 358.—(After Bardeen.) Deep muscles of the thigh of a 20-mm. embryo.

The caput longum, M. biceps femoris, arises from a special rudiment near the tuber ischiadicum closely fused with that of the M. semitendinosus. The caput breve arises as a separate rudiment continuous proximally with the M. glutæus maximus and extends distally along the fibular margin of the femur. In a 14-mm. embryo it begins to fuse with the caput longum (Figs. 356, 360).

The Extensors of the Foot.—During the sixth week the rudiment of the peroneal muscles becomes separated from the long extensors of the toes and the M. tibialis anterior, and at the same time the rudiment of each peroneal muscle begins to become distinct (Figs. 361, 362). They differentiate *in situ,* gradually extending from the dorsolateral surface of the proximal end of the fibula. The tendon of insertion of the M. peronæus longus gradually differentiates: in a 14-mm. embryo it can be traced to the base of the fifth metatarsal, in a 20-mm. embryo part way across the sole of the foot, and in a 30-mm. embryo to the first metatarsal, but not until later does the tendon become free in its sheath. The

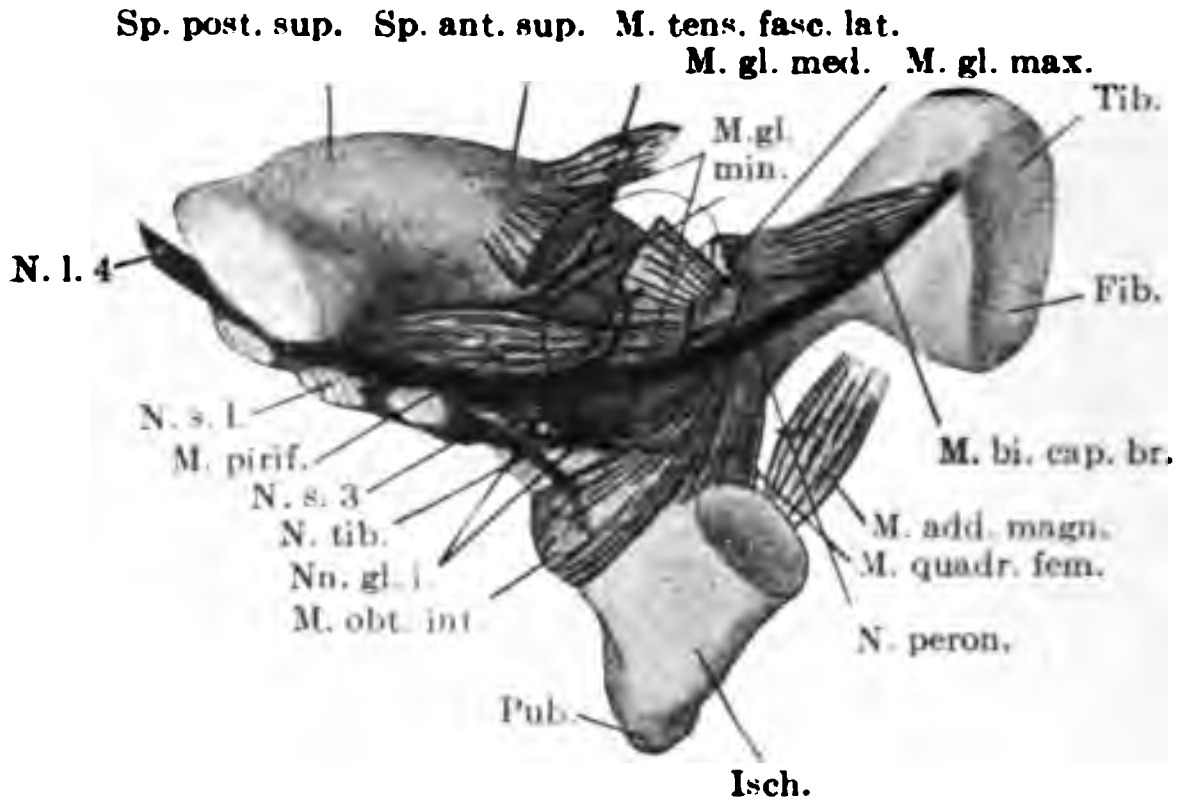

FIG. 359.—(After Bardeen.) Deep muscles of the thigh of a 20-mm. embryo.

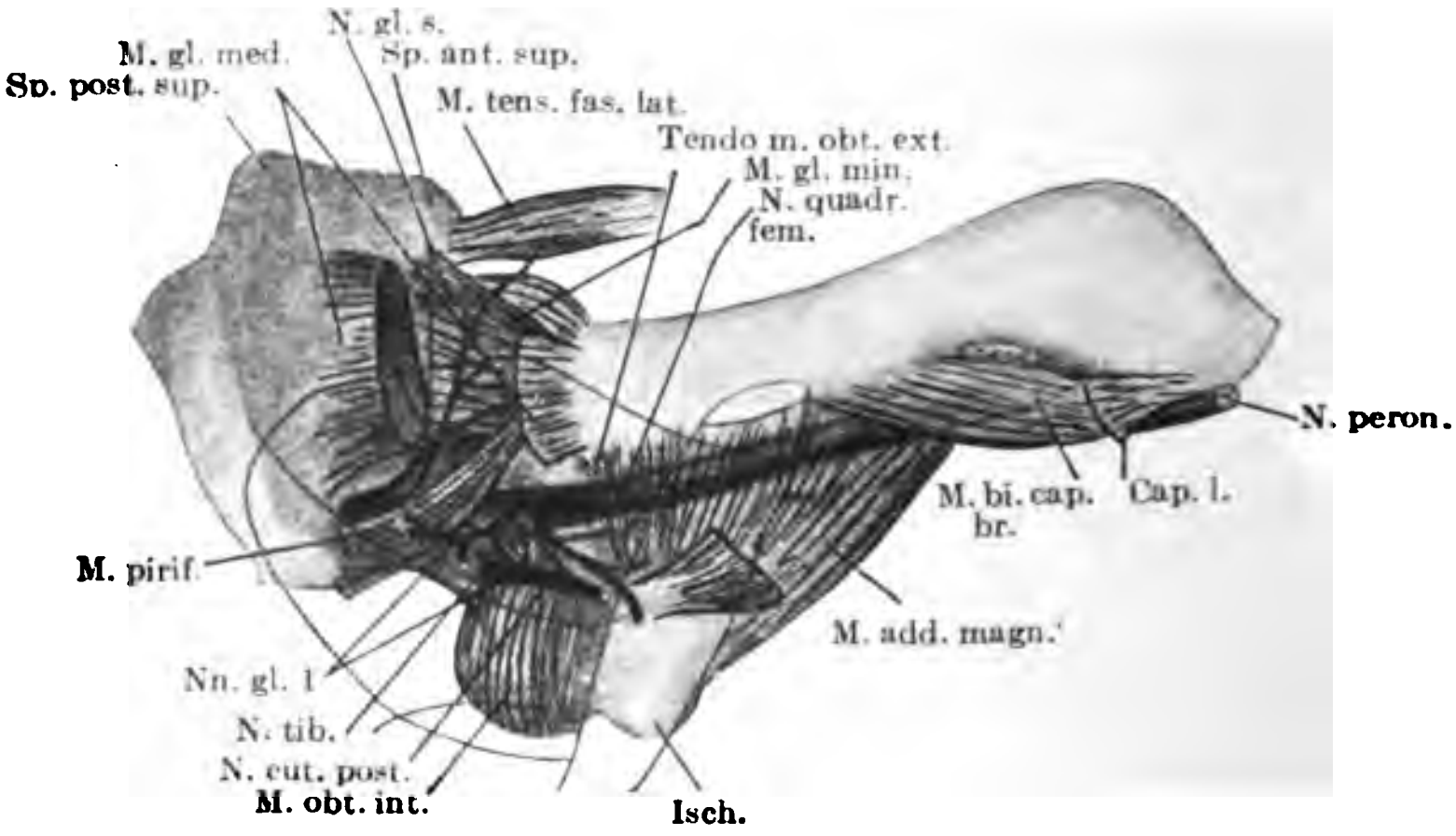

FIG. 360.—(After Bardeen.) Deep muscles of the thigh of a 20-mm. embryo.

tendon is at first lateral to the rudiment of the malleolus lateralis; later (20 mm.) it passes behind it. The muscle also extends proximally to the tibia attachment. The M. peronæus brevis arises relatively more proximal than in the adult position and its tendon splits off from that of the peronæus longus. Schomburg describes an intimate union between it and the M. extensor digitorum brevis persisting until the third month, but Bardeen was unable to find it.

In the early stages (Figs. 337, 353) the common extensor mass of the foot is connected with the peroneal mass, but in a 14-mm. embryo the two masses have become distinct and the extensor mass has already differentiated into the Mm. tibialis anterior, extensor digitorum longus, and extensor hallucis longus (Figs. 338, 339, 346, 361, 362). The Mm. tibialis anterior at this stage can be traced into a broad tendon as far as the region of the os cuneiforme primum, and in a 20-mm. embryo it has the adult attachments (Figs. 338, 339, 346, 361, 362). The M. extensor digitorum longus is differentiated from the central portion of the muscle mass and is relatively more on the fibular side than in the adult. At first it ends distally in a broad flat plate which later, in a 20-mm. embryo, gives off the broad tendons to the digits. According to Schomberg (1900), the M. peronæus tertius is early distinct from the M. extensor digitorum longus, but Bardeen maintains that it later splits off from the M. extensor digitorum longus with which it is often fused in later life. The M. extensor hallucis longus early splits off from the deep portion of the extension mass, although its tendon remains longer fused with that of the M. extensor digitorum longus. The M. ext. dig. brevis differentiates *in situ* beneath the extensor plate somewhat later than the other extensor muscles of the foot (Figs. 346, 361).

The Flexors of the Foot.—In an 11-mm. embryo the common flexor mass begins to show signs of differentiation into the muscle rudiments (Figs. 347, 352). In a 14-mm. embryo the two muscle groups are fairly distinct, a superficial, proximolateral group for the Mm. gastrocnemius, soleus, and plantaris, and a deep, more medial group for the Mm. flex. hal. long., flex. dig. long., popliteus, and tibialis posterior (Figs. 363, 364). The gastrocnemius group is connected with the blastema of the calcaneus and the two long flexor muscles with the flat aponeurotic "foot-plate," from which tendons extend to the blastema of the digits. The gastrocnemius-soleus group gradually spreads from its original lateral position towards the medial side of the leg to attain the tibial attachment, and the two heads of the M. gastrocnemius develop during the second half of the second month, the medial head attaining its attachment later than the lateral (Figs. 348, 365, 366). The M. plantaris seems to split off at a comparatively late stage from the lateral head of the M. gastrocnemius.

The M. popliteus probably develops *in situ* from the proximal end of the deep flexor mass. It is well developed in a 20-mm. embryo (Figs. 363, 366). The rudiment of the M. flexor hallucis longus is quite distinct in a 14-mm. embryo (Fig. 364). It differentiates from the lateral side of the deep flexor mass, ending distally at this stage in the common tendon plate from which its tendon differentiates at a considerably later stage. The M. flexor digitorum longus is differentiated from the medial portion of the deep flexor mass in a 14-mm. embryo, and ends distally in the common tendon plate from which the tendons are beginning to radiate to the digits (Figs. 348, 363). The tibial attachment does not begin to take place until the embryo is about 20 mm. in length. The M. tibialis posterior differentiates from the deeper tibial part of the deep flexor mass over the lower half of the tibia and

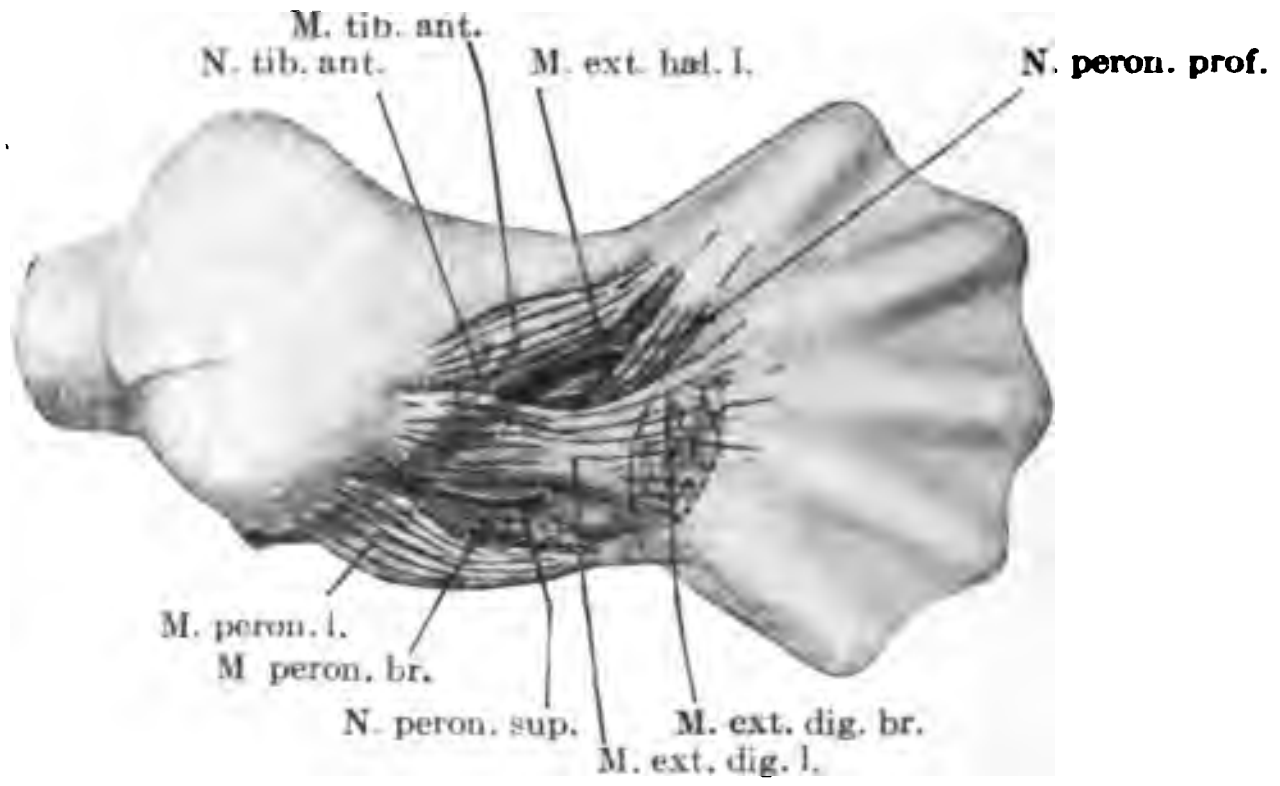

FIG. 361.—(After Bardeen.) Muscles of the crus of a 14-mm. embryo.

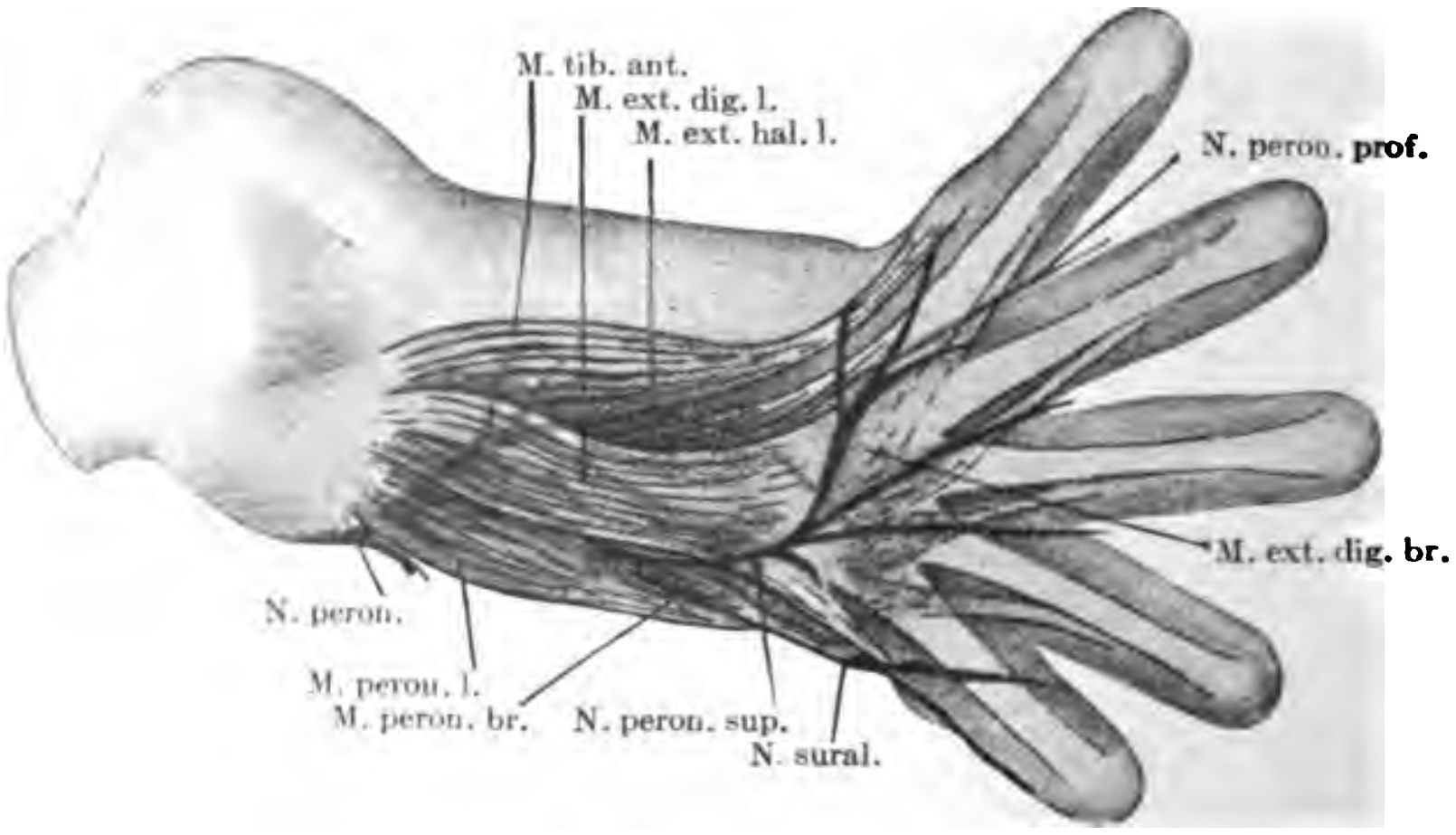

FIG. 362.—(After Bardeen.) Muscles of the crus of a 20-mm. embryo.

extends later in a proximolateral direction. Its tendon is early differentiated.

The Plantar Muscles.—The rudiment of the M. quadratus plantæ has differentiated in a 14-mm. embryo. Schomburg (1900) finds it fused with the M. flexor hallucis longus, but Bardeen did not find this attachment. The M. abductor digiti quinti differentiates at the same stage immediately distal to the tuber calcanei and later moves to a more lateral position (Figs. 364, 366).

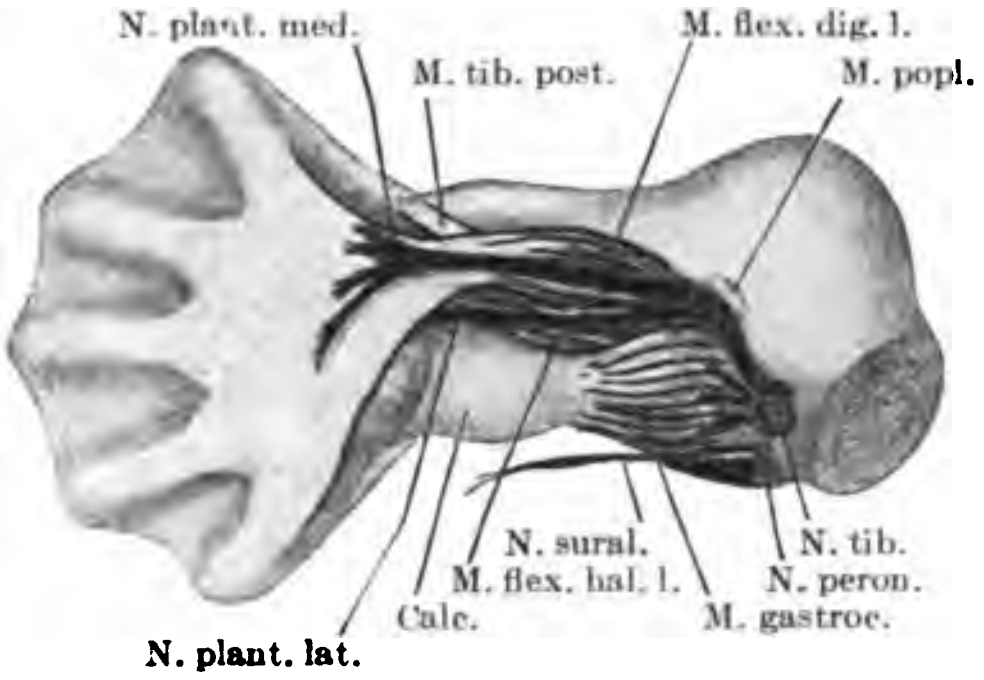

FIG. 363.—(After Bardeen.) Muscles of the crus of a 14-mm. embryo.

The Mm. flexor brevis and opponens digiti quinti arise from a common rudiment somewhat later than the above muscles, and even in a 20-mm. embryo they are not clearly differentiated (Fig. 366).

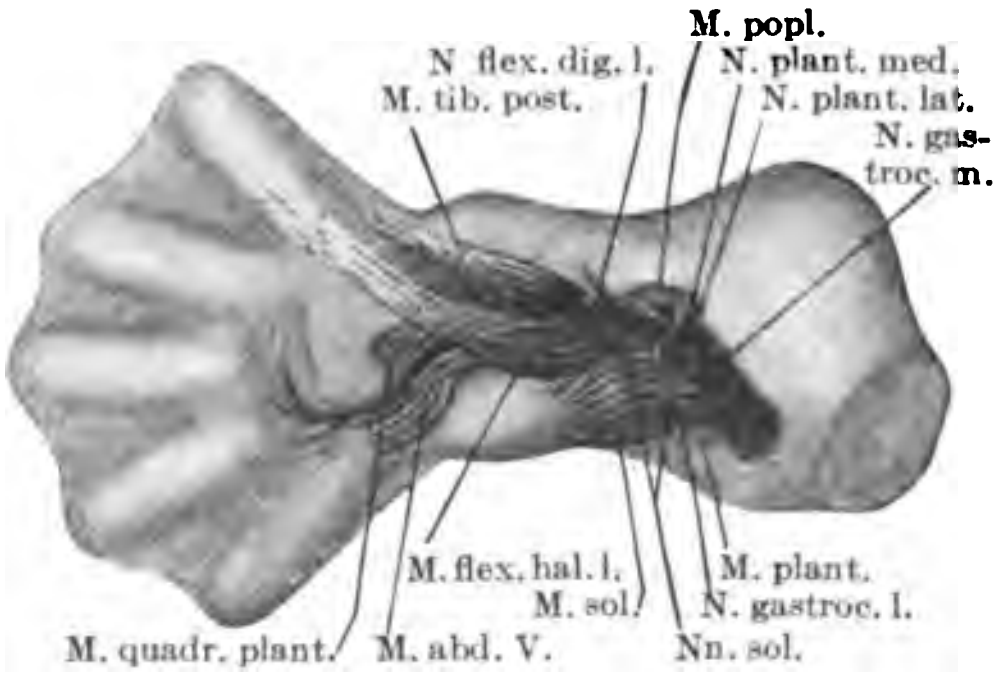

FIG. 364.—(After Bardeen.) Muscles of the crus of a 14-mm. embryo.

The Mm. interossei develop on the plantar surface and the dorsal interossei wander between the metatarsals to the dorsal surface: Ruge (1878), Schomburg (1900). They first appear in embryos over 20 mm. in length (Fig. 366).

The M. adductor hallucis arises at the base of the second metatarsal and wanders to its adult position (Ruge, 1878), and, according to Ruge, the transverse and oblique heads arise from a common rudiment, but, according to Schomburg (1900), from separate rudiments.

The Mm. lumbricales do not differentiate until late, in embryos over 20 mm. in length, and, according to Schomburg, develop as separate rudiments near the distal extremities of the metatarsals and wander towards their attachments to the tendons of the M. flexor digitorum longus. They arise from the medial plantar layer.

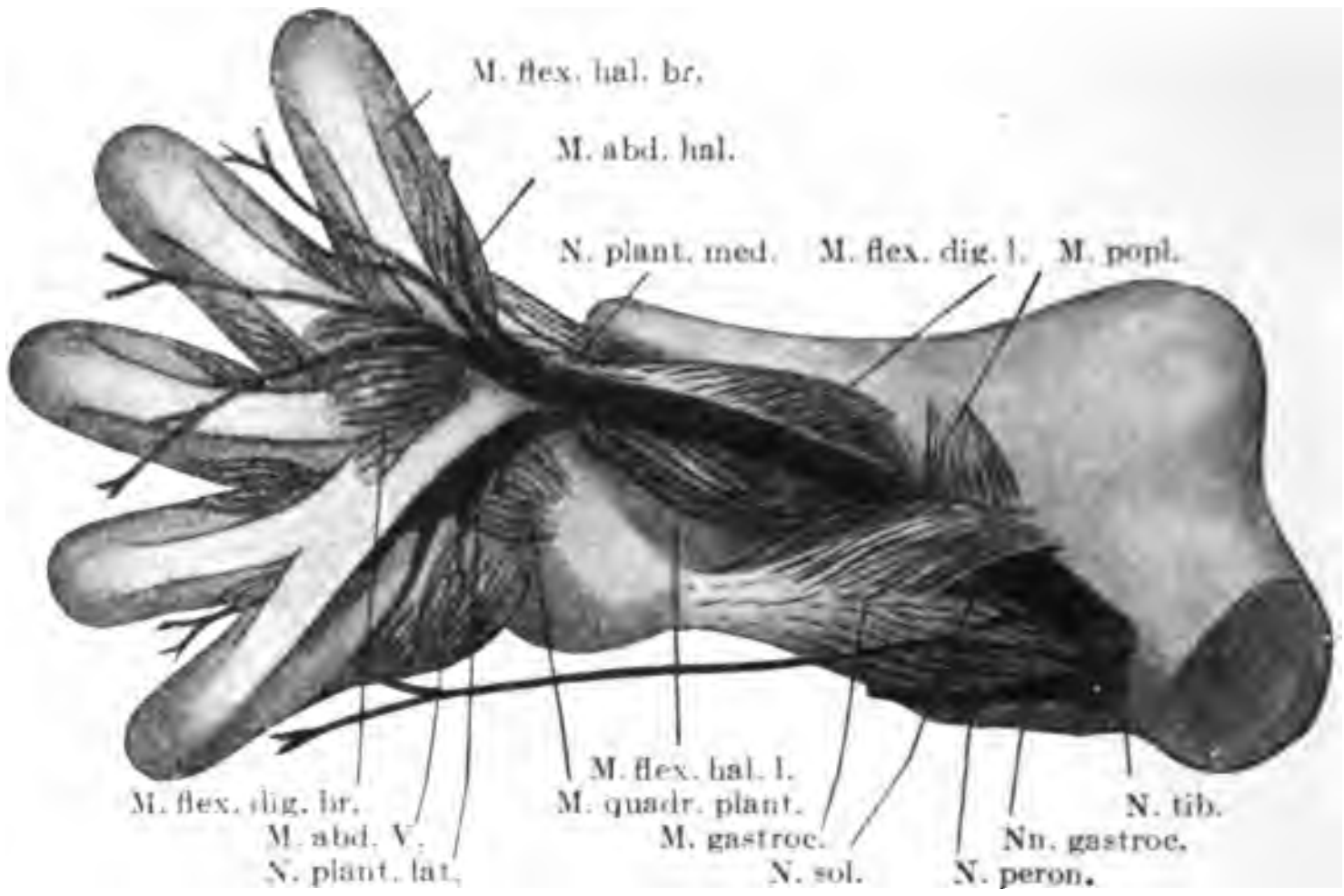

FIG. 365.—(After Bardeen.) Muscles of the crus of a 20-mm. embryo.

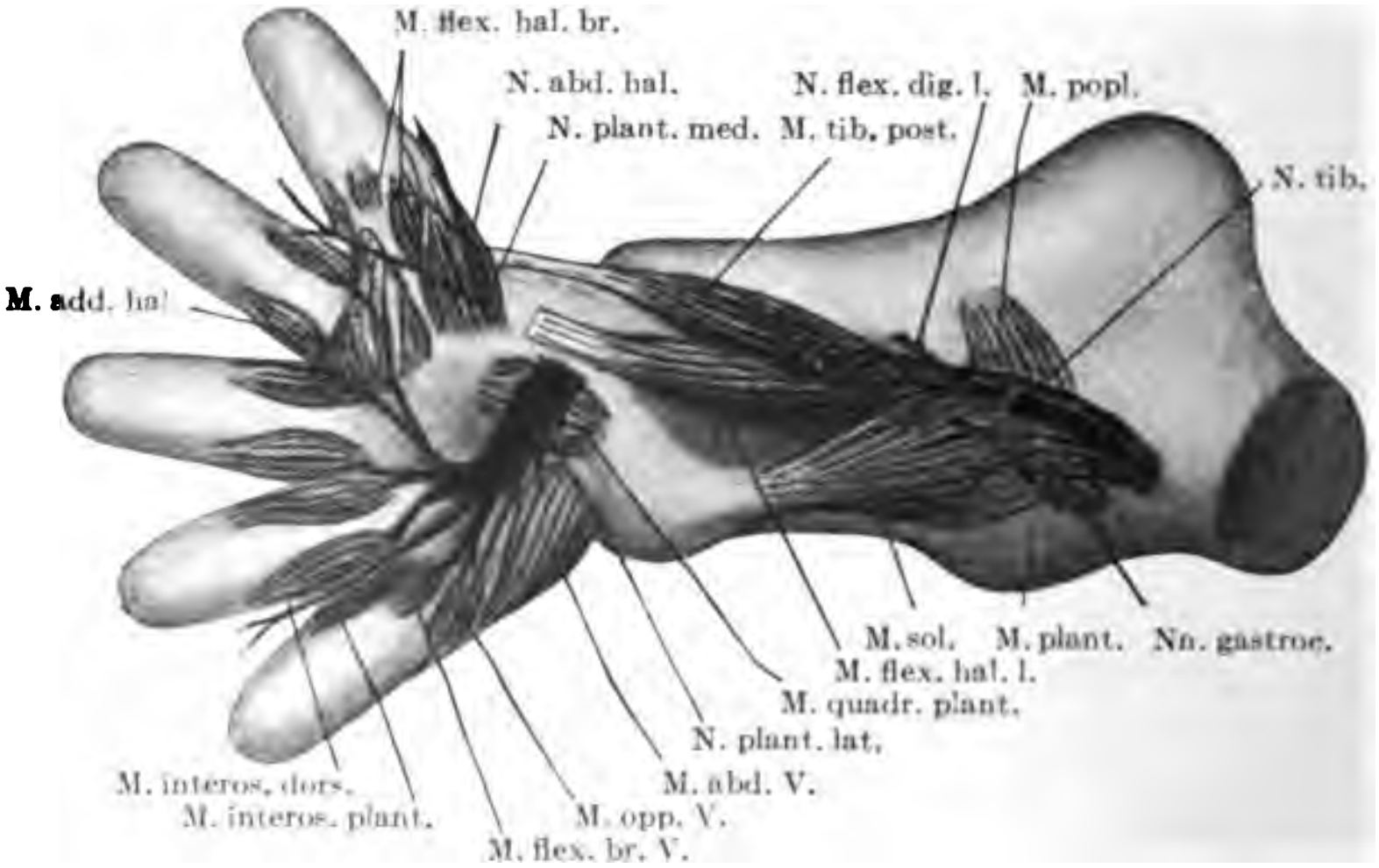

FIG. 366.—(After Bardeen.) Muscles of the crus of a 20-mm. embryo.

The M. flexor digitorum brevis develops relatively late. In a 20-mm. embryo the rudiment is just beginning to differentiate on the surface of the tendon plate of the long flexor muscles over the middle cuneiform cartilage (Fig. 365). Its tendons develop later, as does its proximal extension to the tuber calcanei.

The M. abductor hallucis also develops relatively late. In a 20-mm. embryo it can just be distinguished on the medial edge of the plantar surface of the foot in close association with the M. flexor hallucis brevis (Figs. 365, 366). With the torsion of the foot the abductor extends proximally to be attached to the tuber calcanei.

The M. flexor hallucis brevis, like the other muscles in this group, only begins to appear in a 20-mm. embryo (Fig. 366); later it splits into two parts, the lateral head coming into relation with the M. adductor and the medial with the M. abductor hallucis.

THE MUSCLES OF THE HEAD.

Muscles of the Orbit.—It has commonly been assumed that the muscles of the orbit are derived from anterior head somites; the first somite giving rise to the Mm. levator palpebræ superioris, rectus superior, rectus internus, rectus inferior, and obliquus inferior, supplied by the N. oculomotorius; the second, to M. obliquus superior, supplied by the N. trochlearis; and the third, to the M. rectus lateralis, supplied by the N. abducens. Anterior head somites have, however, never been observed in man or mammals. Zimmermann (1898) observed in a 3.5-mm. embryo several small head cavities in the region where later the eye muscles develop. It is uncertain even that they represent rudimentary head somites, and no connection has been established between them and the eye muscles. On the contrary, the observations of Reuter (1897) on the pig and my own observations on human embryos, which follow here, show that all the eye muscles arise from a common premuscle mass, which occupies, both in the pig and in man, the same general position in the early embryo. This common premuscle mass is first to be recognized in human embryos of about 7 mm. in length (Fig. 367). It consists of a lens-shaped mass of condensed mesenchyme, outlined from the surrounding mesenchyme by a capillary network over its surface. This premuscle mass lies dorsal to the optic stalk, between it and the ganglion Gasseri, and medial to the optic cup. The N. ophthalmicus passes in front of and lateral to the mass, and the N. maxillaris behind and lateral to it. At this stage only the N. oculomotorius enters the anterior end of the muscle mass. The Nn. trochlearis and abduceus do not appear until later.

In a 9-mm. embryo the eye premuscle mass occupies much the same position as in the earlier stage, lying on the dorsal side of the optic stalk and medial to the N. ophthalmicus and maxillaris (Figs. 368, 369). It has enlarged somewhat and extends along the caudal side of the optic stalk. It also begins to show cleavage into separate muscle masses, each supplied by its respective nerve.

The N. trochlearis now enters the anterior portion of the mass which later forms the rudiment of the M. obliquus superior. The N. abducens enters the caudal end of the mass, which has begun to extend out along the path of the nerve and also shows indications of separation from the rest of the mass which lies closer to the optic stalk and into which the N. oculomotorius runs. The muscle mass at this stage has no very distinct attachment either to the precartilage or to the sclera, but there exists a direct continuity with the mesenchyme from which these structures differentiate.

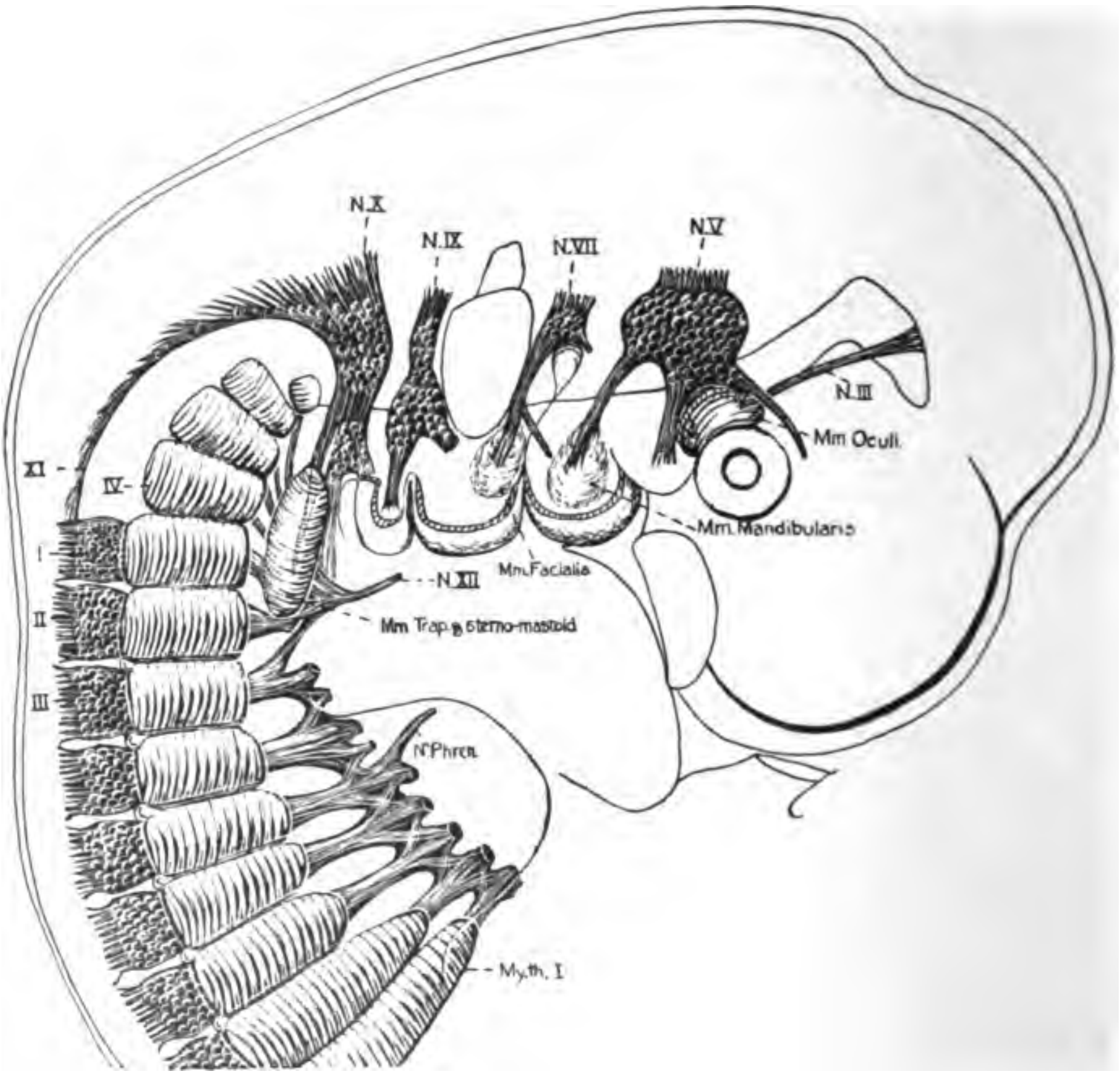

FIG. 367.—Embryo 7 mm. in length. Diagram with premuscle masses of the head and anterior myotomes, from model.

In an 11-mm. embryo the premuscle mass has still farther enlarged and partially split into the rudiments supplied by the three nerves. The anlagen lie on the dorsal and caudal sides of the optic nerve and for the most part medial to the eyeball (Figs. 370, 379). They are continuous laterally with the primitive sclera, which is now beginning to form as a definite condensation of the mesenchyme about the eyeball, and medially with the precartilag-

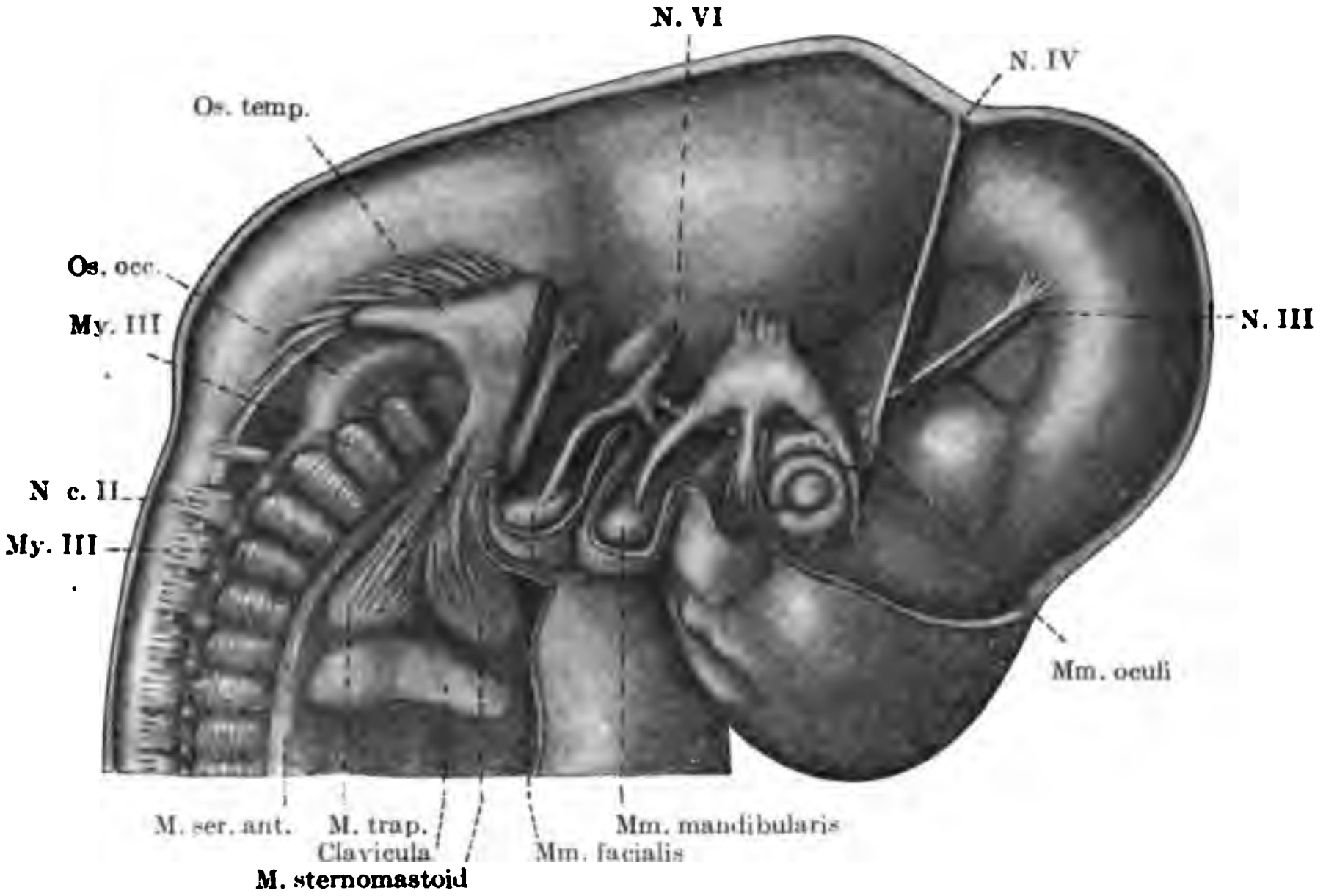

FIG. 368.—Embryo 9 mm. in length. From a model of the premuscle masses of the head and neck and anterior myotomes.

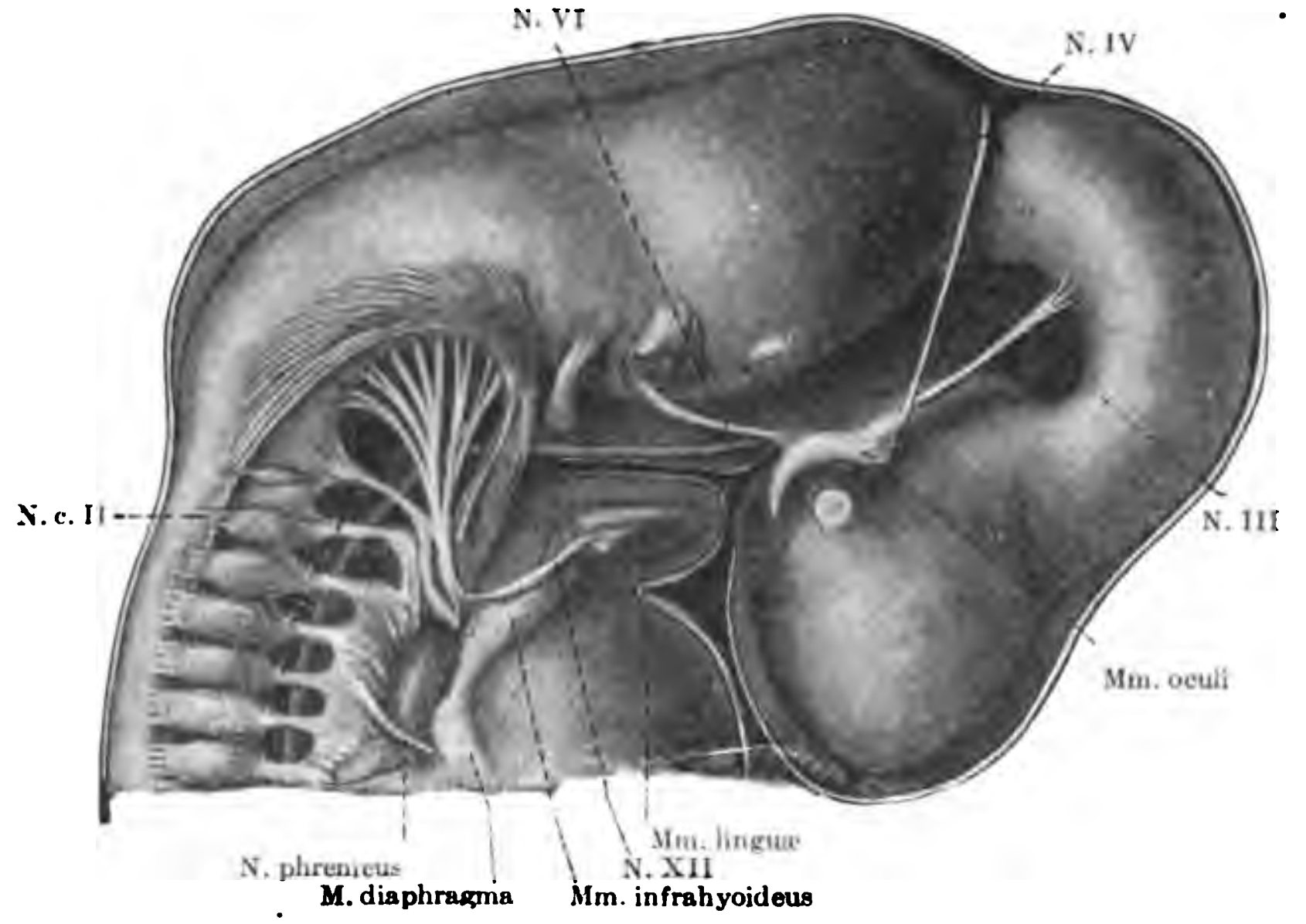

FIG. 369.—Embryo 9 mm. in length. Premuscle masses of the eye, tongue, infrahyoid, and diaphragm regions, from model.

inous tissue about the optic nerve. The M. rectus lateralis has extended farther out along the path of the N. abducens and has as yet no skeletal attachment. The N. ophthalmicus passes above these muscle masses and nearly at right angles to them.

As differentiation progresses the muscle mass of the N. oculomotorius gradually extends around the optic nerve and splits into the various muscles supplied by this nerve. In a 14-mm. embryo all the orbital muscles are to be distinguished and have nearly the adult relations to the bulbus oculi. The M. obliquus inferior, however, does not completely separate off from the M. rectus inferior until a later stage.

The Muscles of the Mandibular Arch.—The mesoderm of the mandibular arch gives rise to the muscles of mastication, including the Mm. temporalis, masseter, pterygoideus externus and internus, and probably to the M. mylohyoideus. The Mm. tensor tympani and tensor veli palatini are also derived from this arch. In a 7-mm. embryo the mandibular arch is filled with a uniformly closely packed mesenchyme, with only the slightest trace of condensation about the peripheral end of the N. mandibularis (Fig. 367). In a 9-mm. embryo, however, this condensation is clearly to be recognized (Fig. 368). This premuscle mass, in which the N. mandibularis ends, lies at about the middle of the arch. It is a simple mass, without indications of splitting and not sharply outlined from the mesenchyme which fills the arch. In an 11-mm. embryo this egg-shaped premuscle mass has increased in size, but

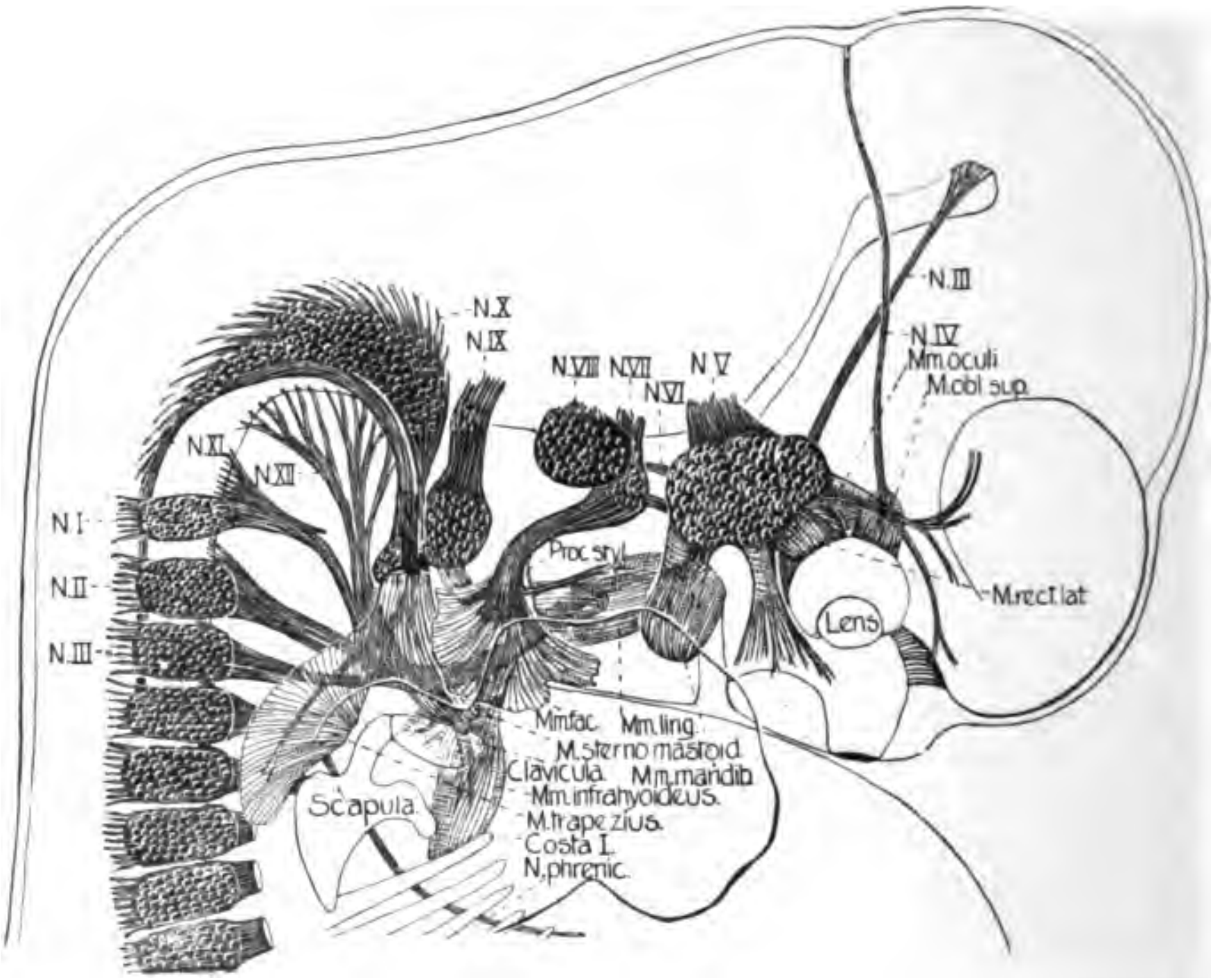

Fig. 370.—Embryo 11 mm. in length. Diagram of muscles of the head and neck, from graphic reconstruction and model.

still shows no indications of splitting into the various muscles (Fig. 370). The differentiation probably takes place in a manner very similar to that described by Reuter in the pig. The premuscle mass is from the very beginning closely associated with the condensed mesenchyme for the mandible, and with the differentiation of the proximal end of the mandible the premuscle mass is partially split into a Y-shaped mass, the handle representing the M. temporalis, the outer limb corresponding to the M. masseter, and the inner deeper limb, separated from the outer by the proximal end of the mandible, the mass for the Mm. pterygoideus externus and internus. In a 14-mm. embryo this process of differentiation has progressed still farther, and the Mm. pterygoideus externus and internus are partially separated by Meckel's cartilage. The processus coronoideus only partially separates the masseter from the pterygoid mass at this stage. With the continued differentiation of the membranous mandible and adjoining portions of the skull to which the muscles of mastication are attached comes the gradual differentiation of these muscles. The muscles are at no time attached to Meckel's cartilage, but are always in relation with the membranous mandible. In a 20-mm. embryo the various muscles of mastication are easily to be recognized, but have only a slight resemblance to the adult form. The M. temporalis is very small in proportion to the size of the head and gradually extends over a much greater proportional area during later stages. The M. masseter is at first attached only to the medial and lower surfaces of the arcus zygomaticus.

The M. mylohyoideus apparently differentiates more rapidly than the other muscles of mastication, and is to be recognized by its nerve supply in an 11-mm. embryo, and in a 14-mm. embryo it has much the adult relations. I have been unable to determine its origin from the common muscle mass.

In a 14-mm. embryo the Mm. tensor tympani and tensor veli palatini are to be recognized and are connected with the pterygoid mass from which they probably arise. The M. tensor tympani has already gained its insertion to the malleus. The later development of these muscles is bound up with the development of the base of the skull, the tuba auditiva, and the soft palate.

The Facial Muscles (The Muscles of the Hyoid Arch.)—The facial muscle group includes all the muscles supplied by the N. facialis. The subcutaneous muscles of expression and certain muscles about the facial openings concerned with the vegetative functions belong to this group.

Futamura (1906) has given the most elaborate recent account of their origin and development, and the following is based upon his work.

This entire facial musculature arises from the closely packed mesenchyme which fills the second branchial or hyoid arch. In a 9-mm. embryo the main stem of the N. facialis, which is very simple at this stage, passes into the hyoid arch to end brush-like in a single mass of premuscle blastema that occupies the ventrolateral portion of the arch (Figs. 367, 368, 371). The condition is very similar to that described by Futamura as existing in a 10-mm. embryo. It is from this premuscle mass that the entire musculature supplied by the N. facialis arises (Futamura). This premuscle mass increases in size (Fig. 370), and in an embryo 13.7 mm. in length has begun to spread out not only ventralwards but also dorsalwards and aborally (Fig. 372). It also extends towards the shoulder to form the platysma. The medial side of the mass becomes thickened to form the rudiment of the Mm. stylohyoideus, digastricus, and stapedius. It extends from the root of the tongue along the posterolateral side of Reichert's cartilage towards the ear capsule.

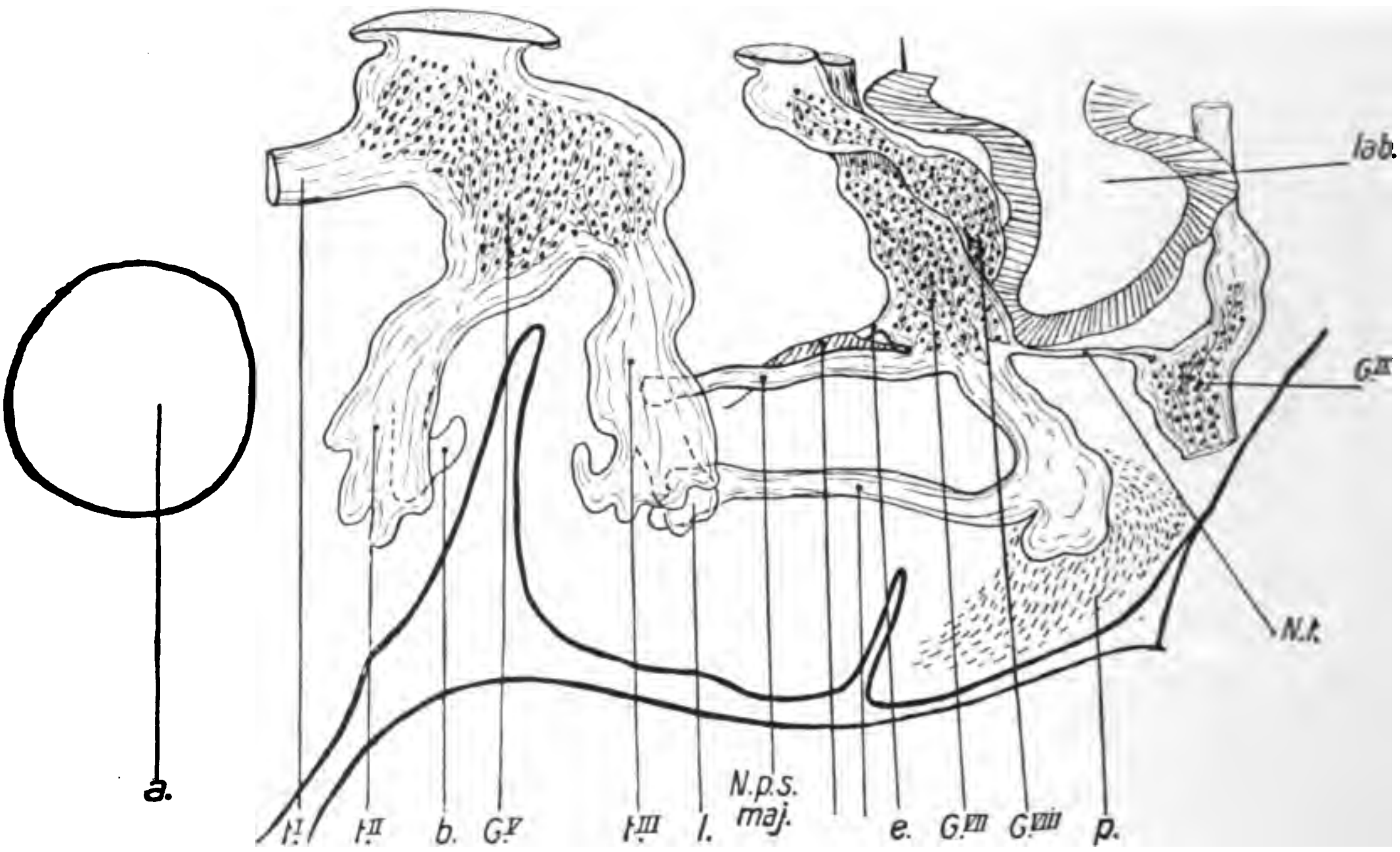

FIG. 371.—(After Futamura, Anat. Hefte, Bd. 30, Fig. 27, on p. 440.) Human embryo, 27–30 days. ×50 dia. Sagittal projection from frontal sections. *a*, eye; *G*.V, ganglion trigemini; *t*I, *t*II, *t*III, ramus primus, secundus, and tertius N. trigemini; *b*, junction of the r. II N. trigemini with N. petrosus superf. maj.; *l*, N. lingualis; *C.t.*, chorda tympani; *N.p.s. maj.*, N. petrosus superficialis major; *G*.VII, ganglion geniculi; *G*.VIII, ganglion acusticum; *P*, the rudiment of platysma; *G*.IX, ganglion glossopharyngei; *lab.*, labyrinth; *N. t.*, N. tympanicus; *e.*, epibranchialis; *h.*, hyomandibular cleft.

As the muscle rudiment spreads out the N. facialis becomes divided into several branches which follow the wanderings of the muscle tissue. Thus, in a 13.8-mm. embryo the nerve stem distal to the chorda tympani divides into three branches, a thin one directed medially into the rudiment of the Mm. digastricus and stylohyoideus, a second large branch, the N. auricularis posterior, and a third large branch which soon divides into the R. temporalis, maxillaris, and cervicofacialis.

In a 15.5-mm. embryo the platysma rudiment has extended orally over the hyoid arch and caudally to the region of the sternum and shoulder-girdle. It has also pushed medially and begins to unite with its fellow of the opposite side (Fig. 373, 374). The spreading of the muscle headwards takes place along two paths, separated by the anlage of the outer ear. The occipital portion gives rise to the Mm. auricularis posterior, transversus nuchæ, transversus and obliquus auriculæ, but at this stage still forming a continuous membrane.

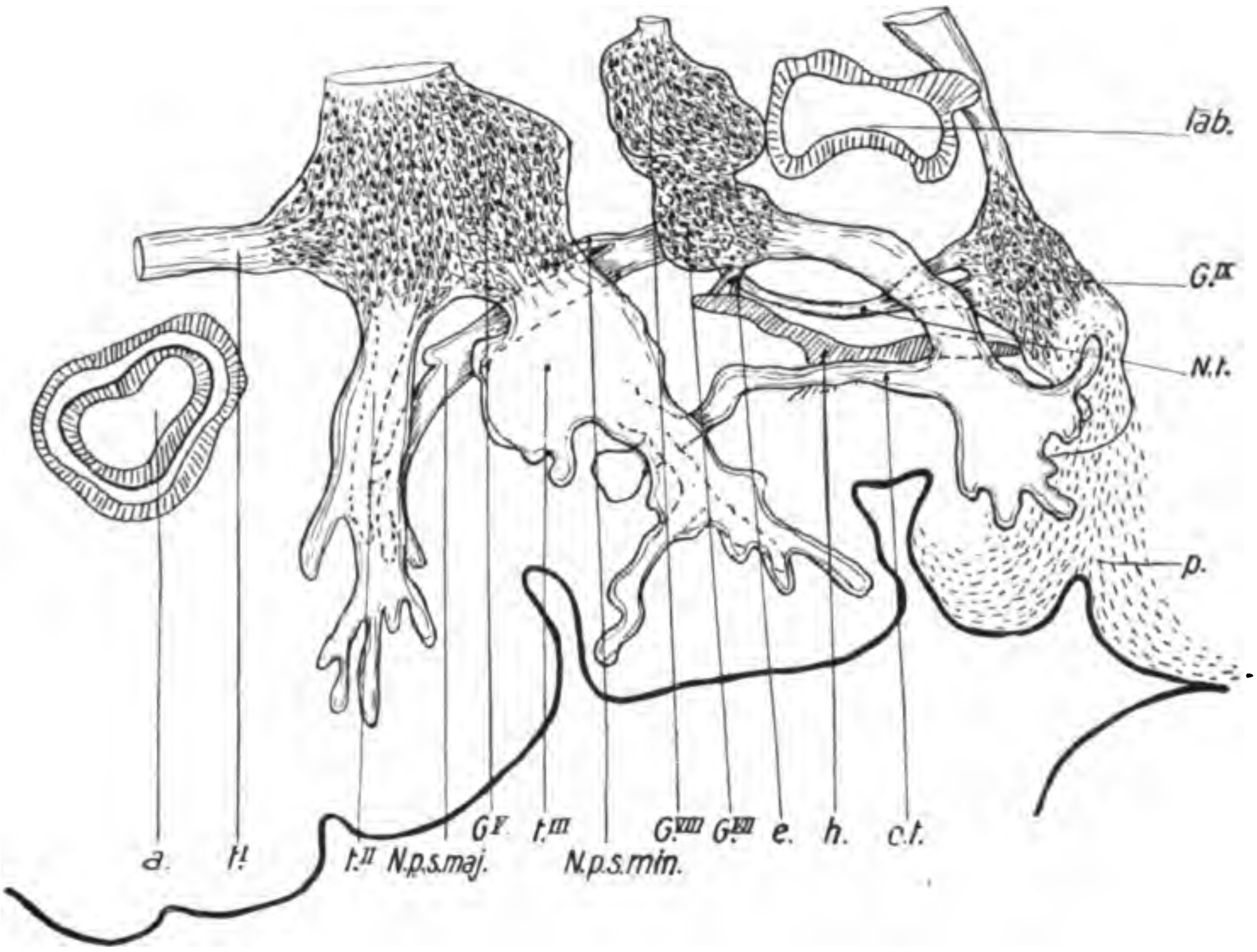

Fig. 372.—(After Futamura, Anat. Hefte, Bd. 30, Fig. 2, on p. 441.) Human embryo of 31–34 days. Sagittal projection from sagittal series. ×38 dia. Explanation as in figure 371. *N.p.s. min.*, N. petrosus superficialis minor.

The facial portion of the platysma splits at the upper part of the neck into two layers, a superficial, lightly staining one and a deeper, more intensely staining one. A capillary network often separates the two layers. Futamura designates the superficial layer as the platysma faciei and the deep layer as the sphincter colli.

The platysma faciei gradually extends over the lower jaw and cheek to the forehead, eye, and temporal region, while the most anterior part goes to the lower lip. At the angle of the mouth the two layers are very difficult to separate from one another. In a 7-wk. embryo (Figs. 375, 376) the platysma faciei over the side of the head and above the ear unites with the platysma occipitale, which has also in the meantime extended cranialwards and broadened out to touch its fellow on the opposite side. The platysma occipitale has, however, now lost its connection with the platysma colli.

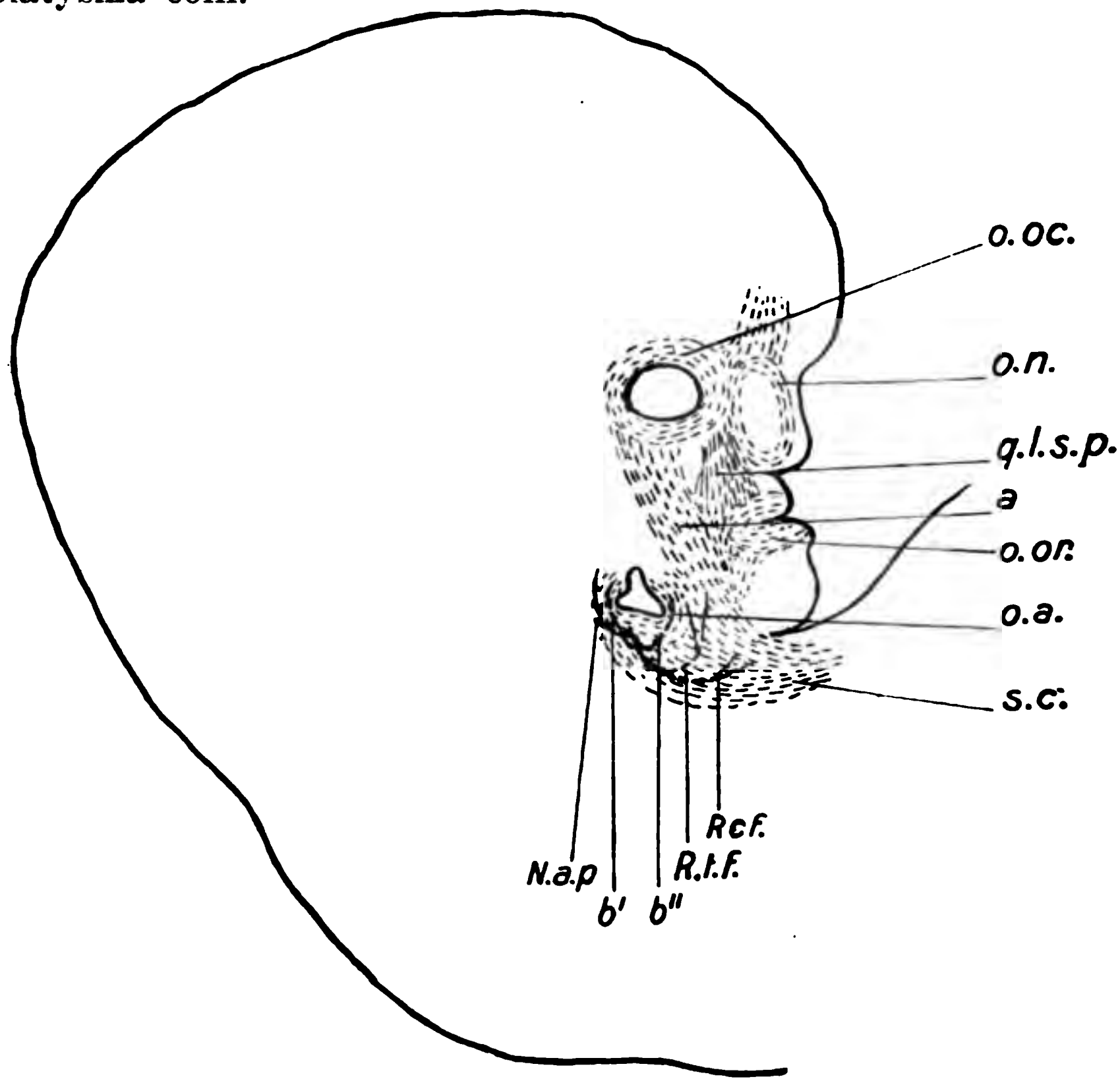

Fig. 373.—(After Futamura, Anat. Hefte, Bd. 30, Fig. 4, A, on p. 444.) Human embryo of six weeks. Sagittal projection from frontal series. ×20 dia. Deep layer. *o.oc.*, orbicularis oculi; *o.n.*, orbicularis nasi; *q.l.s.p.*, the anlage of the M. quadratus labii superioris proprius; *a*, the parts of the sphincter colli going to the lower lateral side of the eye; *o.or.*, orbicularis oris; *o.a.*, orbicularis auriculæ; *N.a.p.*, nervus auricularis posterior; *b'* and *b''*, branches of the facial going to the posterior and anterior surfaces of the ear; *R.t.f.*, ramus temporofacialis; *R.c.f.*, ramus cervicofacialis; *s.c.*, sphincter colli.

The sphincter colli, the deep layer, which underlies the platysma faciei, forms at first by the sixth week a sheet over the face, with sphincter-like differentiations about the mouth, nose, eye, and ear, to form the primitive Mm. orbicularis oris, orbicularis narium, orbicularis oculi, and orbicularis auriculæ (Fig. 373). The differentiation of the sphincter colli begins earlier than the superficial layer and is far advanced in embryos 8–9 weeks old (Fig. 378). The lateral portion of the sphincter colli over the cheek degenerates, as do also the primitive Mm. orbicularis oculi and narium. That part of the sphincter colli between the M. orbicularis oculi and angle of the mouth becomes attached to the maxilla to form the rudiment of the M. quadratus labii superioris. Lateral to this the M. zygomaticus appears to develop from the sphincter colli. The M. orbicularis oris, which comes from this layer, continues to increase in size and, connected with the mouth but having attachment to the skeleton, are differentiated from the sphincter colli the Mm. caninus, incisivus labii superioris and inferioris, and nasalis. The latter replaces partly the M. sphincter narium. The M. triangularis is associated with the M. caninus. The M. risorius is derived later (thirteenth to seventeenth week) from the M. triangularis. The M. buccinator is derived from that portion of the sphincter colli lying between the upper and lower lips, and as the mouth decreases in size the muscle comes to lie deeper.

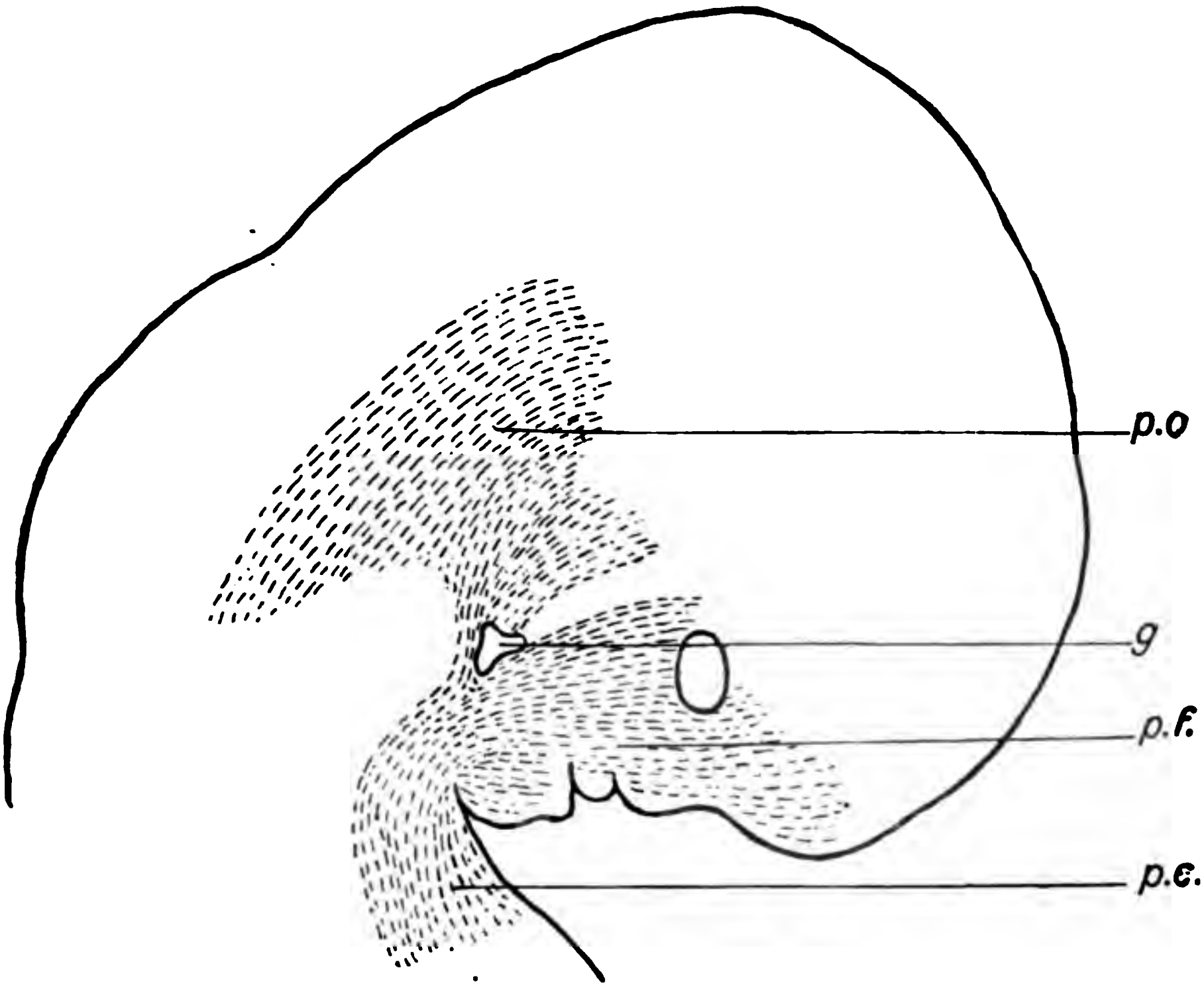

Fig. 374.—(After Futamura, Anat. Hefte, Bd. 30, Fig. 4, B, on p. 445.) Superficial layer of the platysma musculature of the same embryo as in Fig. 373. *p.o.*, platysma occipitale; *g*, oral fossa; *p.f.*, platysma faciei; *p.c.*, platysma colli.

The superficial layer, the platysma faciei, spreads out over the face and head in a continuous sheet, and in a 7-weeks embryo has united over the ear with the platysma occipitale to form the M. fronto-auriculo-occipitalis (Fig. 375). As the sphincters of the deep layer degenerate, there are gradually formed out of the superficial layer a new orbicularis oculi and orbicularis auriculæ (Figs. 375, 377). The medial and lateral part of the M. quadratus labii superioris is derived from this superficial layer and also the Mm. mentalis and quadratus labii inferioris (Fig. 377). From the M. fronto-auriculo-occipitalis are derived the Mm. auricularis superior and anterior, and, through degeneration of the medial portion of the M. fronto-auriculo-occipitalis, the Mm. frontalis and occipitalis become widely separated but joined by the galea aponeurotica which probably represents the degenerated portion of the muscle.

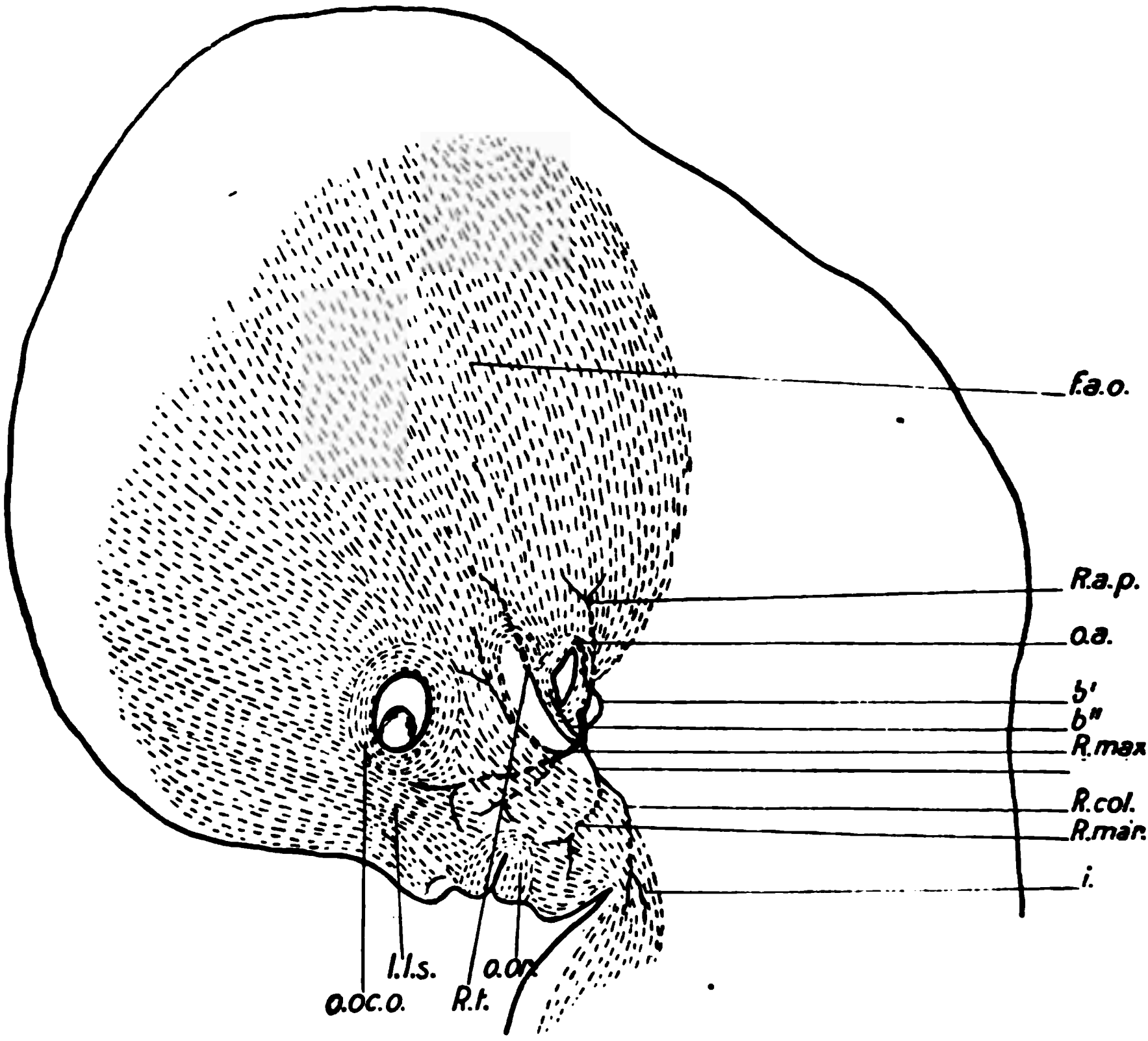

FIG. 375.—(After Futamura, Anat. Hefte, Bd. 30, Fig. 5, A, on p. 449.) Superficial layer of the same embryo as in Fig 376. *F.a.o.*, M. fronto-auriculo-occipitalis; *o.oc.o.*, M. orbicularis oculi (from the platysma colli); *R.t.*, R. temporalis; *l.l.s.*, M. levator labii superioris proprius (alæque nasi); *O.or.*, orbicularis oris; *R. max.*, R. maxillaris; *R. mar.*, R. marginalis; *R. col.*, R. colli; *R.c.f.*, R. cervicofacialis; *b"* and *b'*, the branches of the facial nerve going to the anterior and posterior surfaces of the ear; *o.a.*, orbicularis auriculæ; *R.a.p.*, R. auricularis posterior.

From the platysma occipitalis not only arises the M. occipitalis but also the Mm. auricularis posterior and transversus nuchæ through degeneration of the intermediate parts.

It has already been noted, that on the medial side of the platysma arise the rudiments of the Mm. digastricus and stylohyoideus. In the sixth week this mass is already well developed, extending from the posterior side of the otic capsule in a concave bow towards the angle of the lower jaw. At this stage it is in intimate relation with Reichert's cartilage. With the growth and lengthening of Reichert's cartilage comes the complete separation of the digastric rudiment from the platysma. In the early stages this anlage is supplied entirely by the N. facialis, the N. mylohyoideus entering only the M. mylohyoideus. At first the M. digastricus consists of only a single belly. From this rudiment splits off gradually the M. stylohyoideus. Parallel with this process occurs a constriction and degeneration in the middle of the digastricus, dividing it into two bellies. During the eighth to ninth week this process is quite complete. The innervation of the anterior belly of the digastric by the N. mylohyoideus is first to be recognized in a 7-weeks embryo when the tendon begins to form.

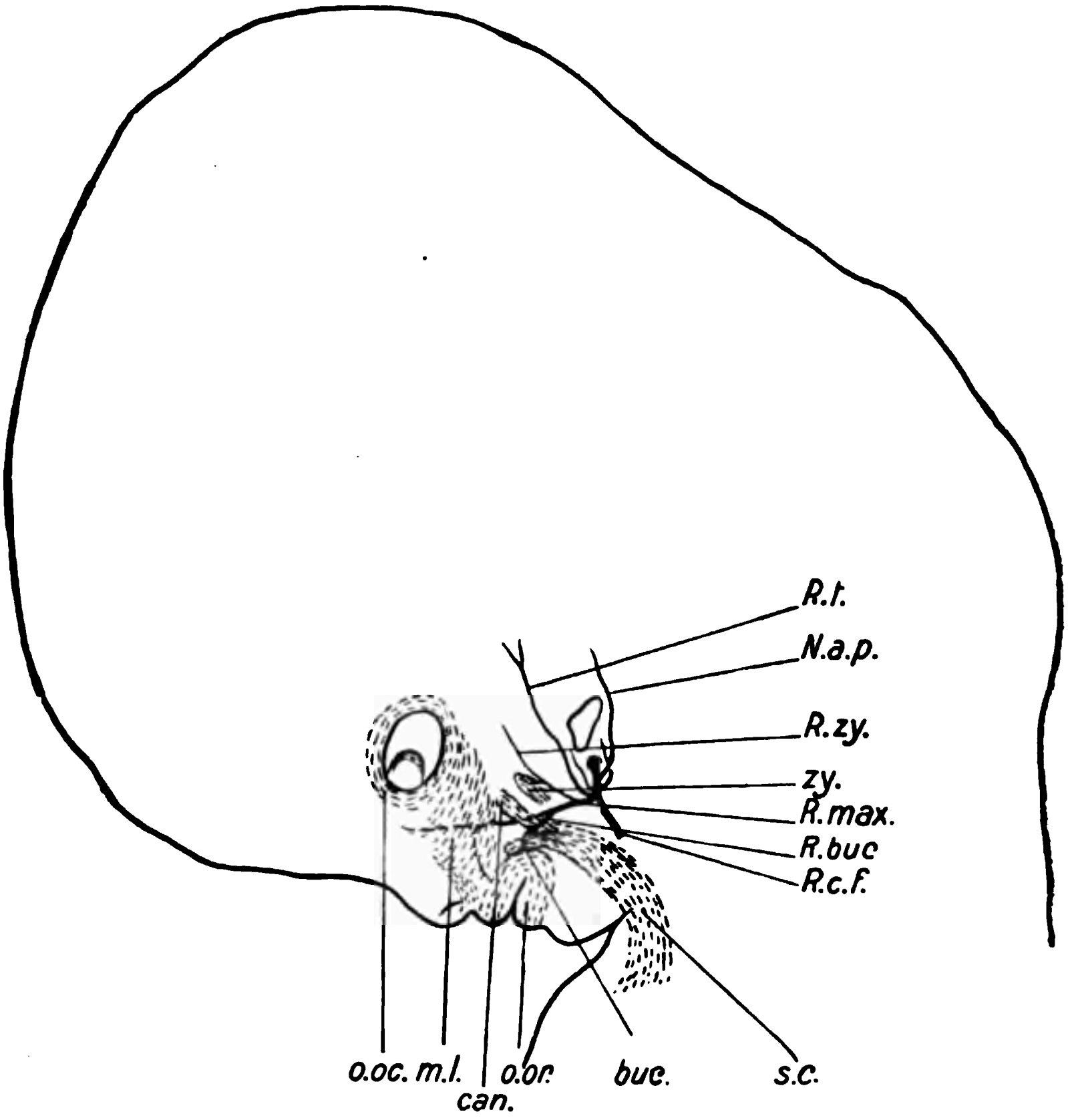

FIG. 376.—(After Futamura, Anat. Hefte, Bd. 30, Fig. 5, B, on p. 450.) Human embryo of 7 weeks. Sagittal projection from frontal sections. × 12 dia. Deep layer. *o.c.*, M. orbicularis oculi (from sphincter colli); *m.l.*, M. maxillolabiales; *o.or.*, M. orbicularis oris; *buc.*, M. buccinator; *can.*, M. caninus; *zy.*, M. zygomaticus; *s.c.*, sphincter colli; *R.zy.*, R. zygomaticus; *R. buc.*, R. buccinatorius; *N.a.p.*, N. auricularis posterior; *R.t.*, R. temporalis; *R.c.f.*, R. cervicofacialis; *R. max.*, R. maxillaris.

The M. stapedius appears to come from the proximal end of the rudiment of the M. digastricus. It gradually becomes separated and enclosed within the otic cartilages. In a 14-mm. embryo it is quite separate from the digastric and lies in close relation to the stem of the N. facialis.

The Mm. levator veli palatini and uvulæ arise from the facial mass. Their development and complete separation from the rest of the facial muscles are bound up with the development of the palate and the tuba auditiva. The M. uvulæ is at first a paired muscle, but with the formation of the soft palate the two muscles unite in the midline.

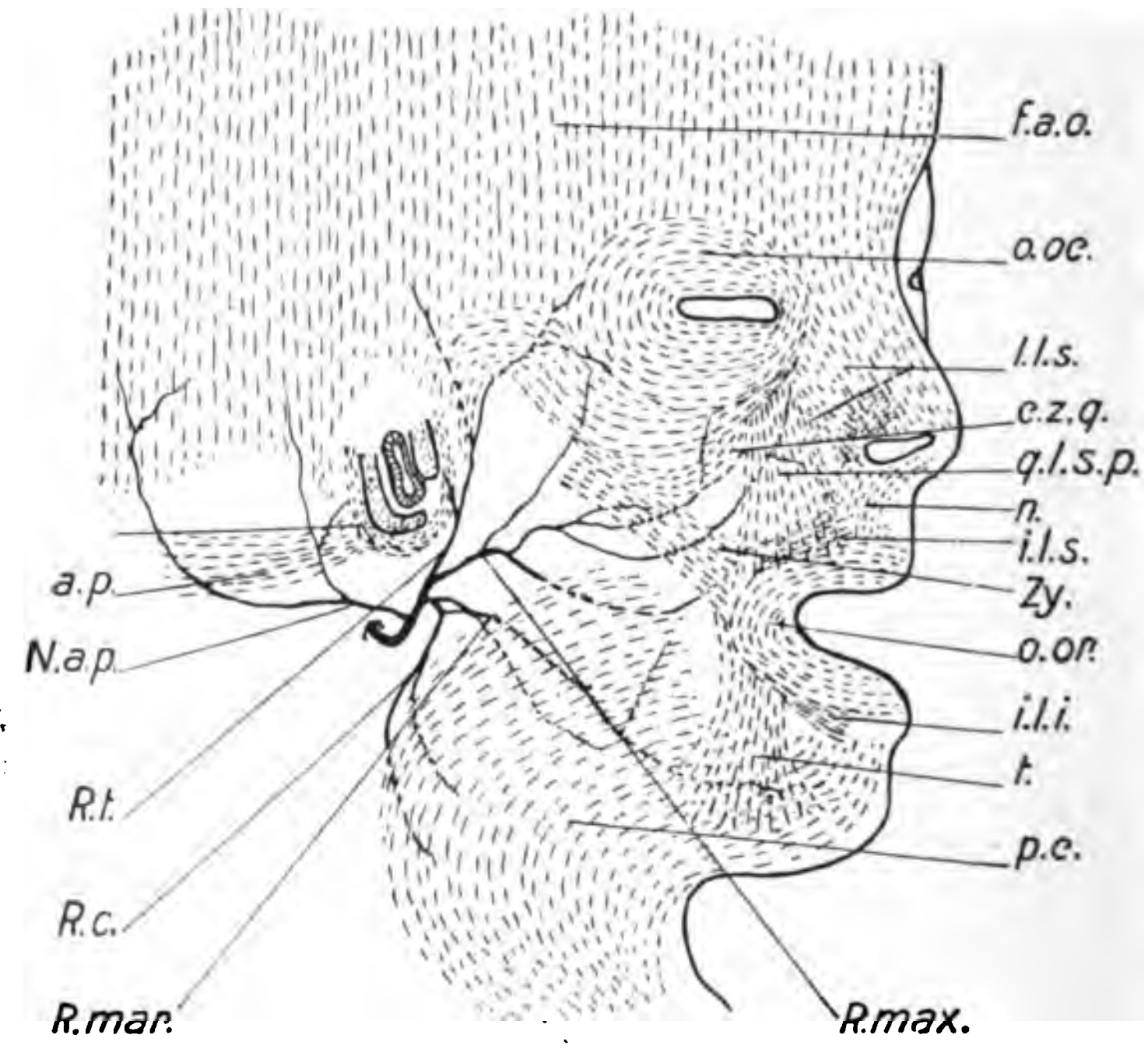

Fig. 377.—(After Futamura, Anat. Hefte, Bd. 30, Fig. 8, A, on p. 456.) Human fetus of 8–9 weeks. Sagittal projection from sagittal series. × 14 dia. Superficial layer of the facial musculature. *f.a.o.*, M. fronto-auriculo-occipitalis; *o.c.*, M. orbicularis oculi; *l.l.s.*, M. levator labii superioris alæque nasi; *q.l.s.p.*, M. quadratus labii superioris proprius; *n.*, M. nasalis; *i.l.s.*, M. incisivus labii superioris; *o.or.*, M. orbicularis oris; *c.z.q.*, caput zygomaticum M. quadrati labii superioris; *zy.*, M. zygomaticus; *i.l.i.*, M. incisivus labii inferioris; *t.*, M. triangularis; *P.c.*, platysma colli; *a.p.*, M. auricularis posterior; *o.a.*, orbicularis auriculæ; *N.a.p.*, auricularis posterior; *R.t.*, ramus temporalis; *R.c.*, ramus colli; *R.mar*, ramus marginalis mandibulæ; *R. max.*, ramus maxillaris.

The Pharyngeal Muscles.—Very little is known concerning the development of the pharyngeal muscles, but the constrictors of the pharynx, as well as the Mm. stylopharyngeus and palatoglossus, probably arise from the third gill arch. The premuscle tissue of this arch is already recognizable in a 9-mm. embryo and into it goes the ninth nerve. The third and fourth gill arches at this stage have already sunken some distance below the surface, and thus the premuscle mass comes to lie in the depths in this region. In an 11-mm. embryo the Mm. stylopharyngeus and constrictors are closely united together at the side of the pharynx, the M. stylopharyngeus having its attachment to the precartilaginous horizontal styloid process near its medial end. With the growth and shifting of the various structures in this region this portion of the styloid gradually assumes a more lateral position, and in a 14-mm. embryo the muscle takes a medial direction toward the thyroid precartilage and the constrictors. One can also distinguish at this stage the attachment of the M. constrictor pharyngis medius to the hyoid and the M. constrictor pharyngis inferior to the thyroid cartilages. These two constrictors are still united into a common mass which is rapidly extending over the dorsum of the pharynx. Concerning the M. constrictor pharyngis superior nothing is known and I am uncertain as to

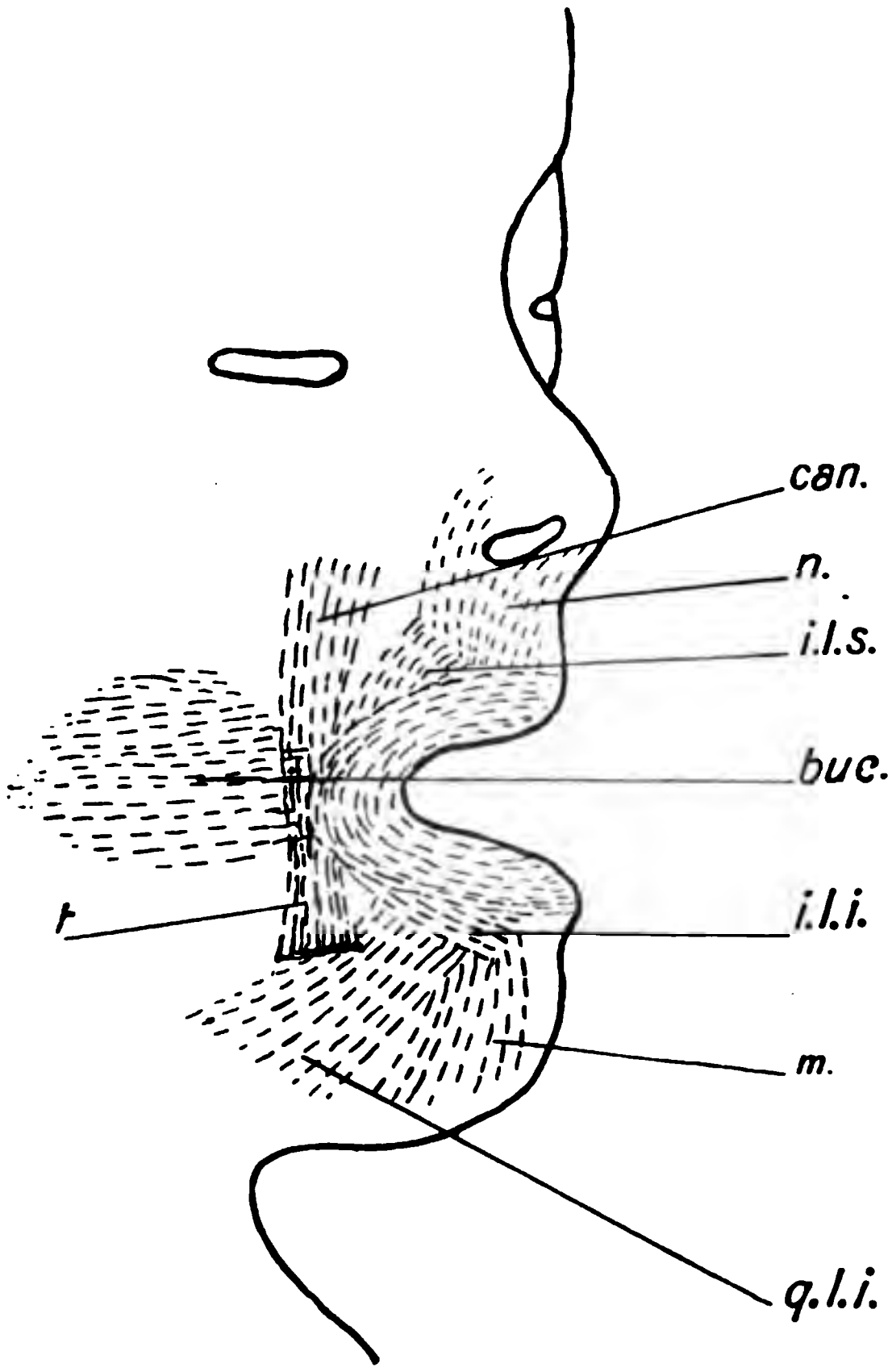

Fig. 378.—(After Futamura, Anat. Hefte, Bd. 30, Fig. 8, B, on p. 457.) Deep layer of the facial musculature of the same embryo as in Fig. 377, with higher magnification. *can.*, M. caninus; *n.*, M. nasalis; *i.l.s.*, M. incisivus labii superioris; *buc.*, M. buccinator; *t.*, triangularis (abgeschnitten); *i.l.i.*, incisivus labii inferioris; *q.l.i.*, M. quadratus labii inferioris; *m.*, mentalis.

whether it arises in common with the others. Its relation with the buccinator suggests that it may arise from the facial mass. The M. constrictor pharyngis inferior is at first continuous with the M. cricothyreoideus. In a 20-mm. embryo the pharyngeal muscles are quite distinct and the constrictors have grown round to the mid-dorsal line of the pharynx.

The Intrinsic Muscles of the Larynx.—The muscles of the larynx probably arise from the ventral ends of the third and fourth gill arches, which early fuse to form a mass of closely packed mesenchyme out of which later differentiate the cartilages and muscles. Soulié and Bardier (1907) found it difficult to recognize laryngeal muscles in a 14-mm. embryo. But in a 19-mm. embryo they were able to recognize clearly the Mm. interarytænoideus, crico-arytænoideus posterior, cricothyreoideus, and thyreo-crico-arytænoideus. They were unable to discover any traces of a sphincter laryngis as described by Strazza (1889), but found that in 32- to 40-mm. embryos the M. thyreo-crico-arytænoideus is clearly distinguishable from the M. thyreo-arytænoideus and towards the middle of the fifth month all the muscles are recognizable.

I have noticed that in a 14-mm. embryo one can distinguish the various muscles, the Mm. arytænoideus, crico-arytænoideus posterior and lateralis, thyreo-arytænoideus, and the crico-thyreoideus. I do not find, as Strazza, the muscles forming a common constrictor of the larynx. I find, with Strazza, that the constrictor of the pharynx is continuous with the M. crico-thyreoideus. With the farther differentiation of the cartilages the muscles become more distinct and in a 20-mm. embryo they have much the adult form.

The Tongue Musculature.—It is usually assumed that the tongue musculature is derived from the occipital myotomes which appear to be serially related to the N. hypoglossus. There is, however, no direct evidence whatever for this statement, and we are inclined to believe from our studies that the tongue musculature is derived from the mesoderm of the floor of the mouth. In a 7-mm. embryo the mesenchyme in the floor of the mouth is similar to that in the mandibular and hyoid arches from which later the musculature of these two arches develops. In a 9-mm. embryo the floor of the mouth has increased in thickness and the groove between the mandibular and hyoid arches has disappeared. In the mesenchyme of this thickened floor are two bilateral masses similar in appearance to the jaw and facial masses found in the mandibular and hyoid arches at this same stage. These bilateral tongue premuscle masses extend from the region in which the mandible later develops to the hyoid region, and are here continuous with a medial mass of condensed mesenchyme which extends into the larynx region and also with the infrahyoid premuscle bands (Fig. 369). The caudal end of this latter mass is in turn continuous with the diaphragm premuscle mass. This lingual-infrahyoid-diaphragmatic band is probably a primitive ventral visceral muscle complex and in no way concerned with the myotomic system. The N. hypoglossus enters the caudal end of the tongue premuscle mass. One is unable at this stage to distinguish any of the individual muscles.

In an 11-mm. embryo (Figs. 370, 379) each homogeneous premuscle mass has split into two masses, a medial ventral mass for the Mm. geniohyoideus and genioglossus and a dorsolateral mass for the Mm. hyoglossus, styloglossus, and chondroglossus. The medial ventral mass extends from the region of the future symphysis menti to the prehyoid mass and dorsally it expands into the tongue region. The main stem of the N. hypoglossus enters its caudal end and passes longitudinally nearly to the anterior end. The dorsolateral mass extends from the prehyoid and medial portion of the styloid process into the dorsolateral region of the tongue for a short distance. A branch of the N. hypoglossus enters its ventral surface. The styloid process at this stage has very nearly a horizontal position and extends nearly to the midline.

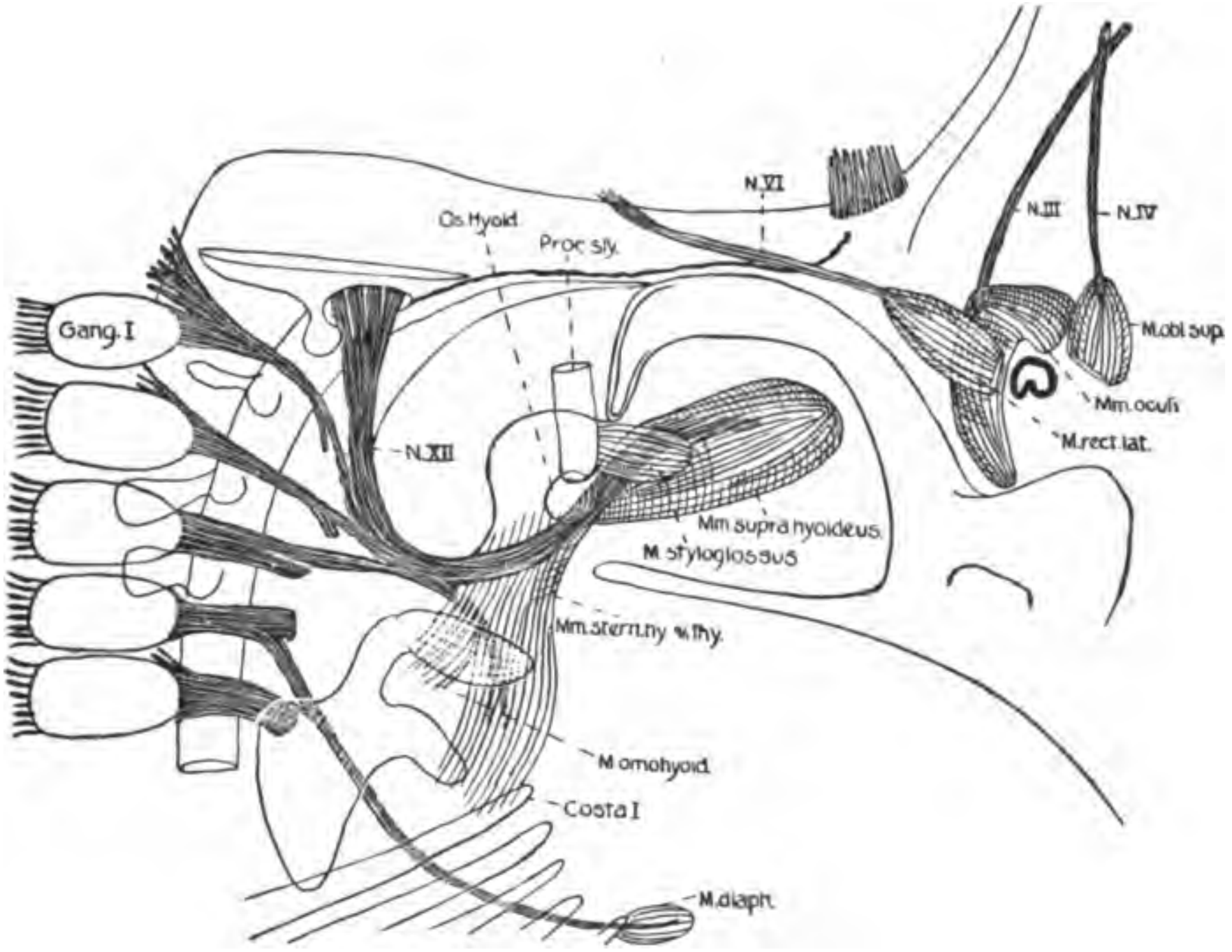

Fig. 379.—Embryo 11 mm. in length. Diagram of muscle masses of eye, tongue, and infrahyoid region, from graphic reconstruction and model.

With the differentiation and development of these muscle masses the tongue gradually becomes raised more and more above the mandibular arch. In a 14-mm. embryo this process is advanced, keeping pace with the differentiation of the mandibular arch in which are now plainly to be recognized Meckel's cartilage and the partially enclosing membranous mandible. From the membranous mandible arise the radiating M. genioglossus, extending a considerable distance fan-like into the tongue, and the M. geniohyoideus, extending to the hyoid precartilage. Over the dorsum and dorsolateral region of the tongue extend the M. hyoglossus and M. styloglossus, from the hyoid precartilage and styloid process respectively, to the tip of the tongue. They lie dorsal and lateral to the radiating genioglossus. Their origins, though distinct, are still close together and parallel. The N. hypoglossus gives off branches to the M. geniohyoideus, then to the Mm. hyoglossus and styloglossus, and passes through the M. genioglossus to its tip, giving off numerous lateral branches into this muscle. There is at this stage apparently very little interlacing of the tongue muscle, nor are we able to recognize either the intrinsic muscles—the Mm. longitudinalis superior and inferior, transversus linguæ, and verticalis linguæ—or the M. glossopalatinus.

In a 20-mm. embryo, however, all the muscles are clearly differentiated and increased in size. The origin of the M. styloglossus has been carried to a more lateral position and enters the tongue at an angle to the M. hyoglossus. The latter has spread out more in its attachment to the hyoid cartilage. The M. glossopalatinus is now recognizable, extending from the laterally placed soft palate to the lateral surface of the tongue. The great development of the intrinsic muscles is most noticeable at this stage, but concerning their origin there are no observations. It is uncertain whether they are derived from the hyoid and mandibular tongue muscles or independently from the mesenchymal matrix. At this stage the interlacing of the tongue musculature is quite advanced.

LITERATURE.

BARDEEN: The Development of the Musculature of the Body Wall in the Pig, Including its Histogenesis and its Relation to the Myotomes and to the Skeletal and Nervous Apparatus, Johns Hopkins Hosp. Rep., vol. ix, 1900. Development and Variation of the Nerves and the Musculature of the Inferior Extremity and the Neighboring Regions of the Trunk in Man, Am. Journ. of Anat., vol. vi, 1907.

BARDEEN and LEWIS: Development of the Back, Body Wall, and Limbs in Man, Am. Journ. of Anat., vol. i, 1901.

COLLIN: Recherches sur le développement du muscle sphincter de l'iris chez les oiseaux, Bibliographie Anatomique, t. 12, p. 183, 1903.

Felix: Teilungserscheinungen an quergestreiften Muskelfasern menschlicher Embryonen, Anat. Anz., Bd. 2, 1888. Ueber Wachsthum der quergestreiften Muskulatur nach Beobachtungen am Menschen, Zeitschrift f. wiss. Zoöl., Bd. 48, p. 224, 1888.

Fischel, A.: Zur Entwicklung der ventralen Rumpf u. Extremitätenmuskulatur bei Vögeln und Säugetieren, Morph. Jahrbuch, Bd. 23, 1895.

Futamura: Ueber die Entwicklung der Facialismuskulatur des Menschen, mit 27 Textabbildungen, Anat. Hefte, Bd. 30, 1906.

Godlewski: Die Entwickelung des Skelet- und Herzmuskelgewebes der Säugetiere, Archiv f. mikr. Anat., Bd. 60, 1902.

Gräfenberg, E.: Die Entwicklung der menschl. Beckenmuskulatur, Anat. Hefte, Bd. 23, 1904. Die Entwicklung der Knochen, Muskeln und Nerven der Hand und der für die Bewegungen der Hand bestimmten Muskeln des Unterarms, mit 19 Abbildungen im Text, Anat. Hefte, Bd. 30, 1905.

Harrison, R. G.: An Experimental Study of the Relation of the Nervous System to the Developing Musculature in the Embryo of the Frog, Am. Journ. of Anat., vol. iii, 1904.

Heerfordt, C. F.: Studien ueber den Musc. Dilatator Pupillæ, etc., Anat. Hefte, Bd. 14, p. 487 to 558, 1900.

Heidenhain, M.: Ueber das Vorkommen von Intercellularbrücken zwischen glatten Muskelzellen und Epithelzellen, etc., Anat. Anz., Bd. 8, 1893.

Herzog, H.: Ueber die Entwicklung der Binnenmuskulatur des Auges, Archiv f. mikr. Anat., Bd. 60, p. 517–586, 1902.

Ingalls, N. W.: Beschreibung eines menschlichen Embryos von 4.9 mm., Archiv f. mikr. Anat., Bd. 70, 1907.

Kotzenberg, W.: Zur Entwicklung der Ringmuskelschicht an den Bronchien der Säugetiere, Archiv f. mikr. Anat., Bd. 60, p. 460, 1902.

Kazzander: Beitrag zur Lehre ueber die Entwicklung der Kaumuskeln, Anat. Anz., Bd. 6, p. 224, 1891.

Keibel, F.: Studien zur Entwicklungsgeschichte des Schweines II. Morphologische Arbeiten, Bd. 5, 1895.

Koelliker: Handbuch der Gewebelehre des Menschen, S. 253, 1889.

Kollmann: Die Rumpfsegmente menschlicher Embryonen von 13–35 Urwirbeln, Archiv f. Anat. u. Phys., Anat. Abt., 1891.

Kroesing: Ueber die Rückbildung und Entwicklung der quergestreiften Muskelfasern, Virch. Arch., Bd. 128, 1892.

Leonowa, O. von: Zur pathologischen Entwicklung des Centralnervensystems (ein Fall von Anencephalie kombiniert mit totaler Amyelie), Neurol. Centralblatt, Jahrg. 12, 1893.

Lewis, W. H.: The Development of the Arm in Man, Am. Jour. of Anat., vol. i, 1901. Observations on the Pectoralis Major Muscle in Man, Johns Hopkins Hosp. Bull., vol. xii, 1901. Wandering Pigmented Cells Arising from the Epithelium of the Optic Cup, with Observations on the Origin of the M. Sphincter Pupillæ in the Chick, Am. Journ. of Anat., vol. ii, 1903.

MacCallum, J. B.: On the Histogenesis of the Striated Muscle-fibre and the Growth of the Human Sartorius Muscle. Johns Hopkins Hosp. Bull., 1898.

Mall: Development of the Ventral Abdominal Walls in Man, Jour. of Morph., vol. xiv, 1898.

McGill, Caroline: The Histogenesis of Smooth Muscle in the Alimentary Canal and Respiratory Tract of the Pig, Internat. Monatschrift. Anat. u. Phys., Bd. 24, 1907.

Marchesini and Ferrari: Untersuchungen ueber die glatten und die gestreiften Muskelfasern, Anat. Anz., Bd. 11, 1895.

Meek, A.: Preliminary Note on the Post-embryonal History of Striped Muscle-fibres in Mammalia, Anat. Anz. 14, 1898, and 15, 1899. On the Postembryonal History of Voluntary Muscles in Mammals, Journ. of Anat. and Physiol., London, vol. xxxiii, p. 546–608, 1899.

Morpurgo, B.: Ueber die postembryonale Entwicklung der quergestreiften Muskeln von weissen Ratten, Anat. Anz., 15, p. 200–206, 1898. Ueber die Verhältnisse der Kernwucherung zum Längenwachstum an den quergestreiften Muskelfasern der weissen Ratten, Anat. Anz., Bd. 16, p. 88–91, 1899.

Neumann, E.: Ueber die vermeintliche Abhängigkeit der Entstehung der Muskeln von den sensiblen Nerven, Arch. f. Entw.-Mech., Bd. 16, p. 642–650, 1903.

Nussbaum, M.: Entwicklungsgeschichte des menschlichen Auges, Gräfe-Sämisch Archiv, Bd. 2, 1900. Die Entwickelung der Binnenmuskeln des Auges der Wirbeltiere, Arch. f. mikr. Anat., Bd. 58, 1902.

Paneth: Die Entwickelung von quergestreiften Muskelfasern aus Sarkoplasten, Sitzungsberichte d. Kais. Akad. d. Wissenschaft, III Abt., Bd. 92, 1885.

Popowsky, J.: Zur Entwickelungsgeschichte der Dammuskulatur beim Menschen, 2 Taf., Anat. Hefte, Bd. 12, 1899.

Reuter: Ueber die Entwickelung der Kaumuskulatur beim Schwein, Anat. Hefte, Bd. 7, 1896. Ueber die Entwickelung der Augenmuskeln beim Schwein, Anat. Hefte, Bd. 9, 1897.

Ruge: Entwicklungsvorgänge an der muskulatur d. menschl. Fusses, Morph. Jahrb., Bd. 4, Suppl., 1878.

Schaffer: Beiträge zur Histologie und Histogenesis der quergestreiften Muskelfasern des Menschen und einiger Wirbeltiere, S. Ber. d. Acad. d. Wiss. Wien, 3 Abt., B. 102, p. 7–148, 1893.

Schomburg, H.: Untersuchungen der Entwickelung der Muskeln u. Knochen des menschl. Fusses, Von der med. Facultät d. Universität Göttingen gekrönte Preisschrift, 1900.

Strazza, G.: Zur Lehre ueber die Entwicklung der Kehlkopfmuskeln. Mittheil. aus dem Embryologischen Institute der K. K. Univ. in Wien, Der Zweiten Folge, 3 Heft, 1899.

Stöhr, Ph.: Entwickelungsgeschichte der menschlichen Wollhaares, Anat. Hefte, Bd. 23, 1902.

Soulie, A., et Bardier, E.: Recherches sur le développement du larynx chez l'homme, Jour. d'Anatomie et de la Phys., t. 43, p. 137–240, 1907.

Szili, A.: Zur Anatomie und Entwickelungsgeschichte der hinteren Irisschichten mit besonderer Berücksichtigung des Musculus sphincter iridis des Menschen, Anat. Anz., Bd. 20, p. 161, 1901.

Zimmermann: Ueber Kopfhöhlenrudimente beim Menschen, Arch. f. mikr. Anat., Bd. 53, 1899.

XIII.

CŒLOM AND DIAPHRAGM.

By FRANKLIN P. MALL.

THE small ovum described recently by Bryce and Teacher is hardly two millimetres in diameter, and is covered with a reticular mass of syncytium, true villi with mesodermal cores not being present. Within there is an extremely small embryo anlage embedded in a delicate cellular reticulum. The mesenchymatous tissue shows no signs of cleavage into a parietal and a visceral layer nor has it arranged itself into a denser layer around the wall of the vesicle. The general appearance of the mesoderm is shown in Fig. 10, Chapter IV, and in Fig. 93, Chapter VII. It is there seen that no exocœlom is present. In comparing this specimen with Peters' ovum, which is somewhat larger, we must imagine a destruction of some of the mesodermal tissue, either in the centre of the ovum or near the embryo, in order to form the primitive exocœlom. In fact this interpretation can be given to the form of the exocœlom in Peters' ovum, as is shown in Figs. 96 and 97, Chapter VII. The first figure is taken from Peters' plate, and the second is an interpretation of this figure by Professor Grosser, who has compared the section from which the Peters drawing was made with the drawing itself. It is seen, therefore, that the exocœlom is not present in an ovum two millimetres in diameter, and that it is well formed in an ovum somewhat larger, that is, at the beginning of the third week of pregnancy.

All the other young human ova which have been studied by embryologists, possibly including that by Peters and those by Graf Spee, have within them a large cavity lined entirely with a layer of mesoderm. The precocious development of this space, the exocœlom, appears to be peculiar to man and monkeys, for it has not been observed in other mammalian ova which have been studied with great care in a large number of species. Hanging freely within this cavity, but attached to one side of the chorion, there is always found in normal ova a relatively small embryonic mass composed of a closed amnion and an umbilical vesicle joined together by the anlage of the embryo, which in the youngest specimens contains only the three primitive blastodermic membranes. In general the diameter of the embryonic mass is but one-fifth of that of the exocœlom, which indicates that the latter began to form by a splitting of the mesoderm when the ovum was very small, unless we assume that the embryonic mass becomes absolutely smaller while the exocœlom is forming. In the Peters ovum the embryonic mass measures about 0.2 mm. in diameter, and that of the exocœlom, which is egg-shaped, averages about one mm.

Until the embryo is 2 mm. long the amnion hugs the embryo closely and does not encroach markedly upon the exocœlom. As the embryo grows a little larger some amniotic fluid accumulates around it, which naturally causes the embryonic mass to grow much more rapidly than the embryo. During this time the embryo also grows relatively faster than the exocœlom and therefore the embryo and amnion soon begin to obliterate the exocœlom. At the time the embryo is 4 mm. long the ratio in size between the embryonic mass and the exocœlom is about 5, and somewhat later it is but 3. When the embryo measures 7 mm. and the ovum is 18 mm. in diameter, the ratio is 2, and by the beginning of the eighth week the exocœlom is obliterated entirely. Now the amnion lines the entire chorion with the exception of a small region around the umbilical vesicle which lies immediately below the chorion and is surrounded by a small space, the last remnant of the exocœlom.

The exocœlom is filled with an albuminous fluid which is held together by a delicate network of fibrils and gives it a jelly-like consistency. This mass, the magma réticulé of the older authors (Velpeau), is also well marked in the exocœlom of monkeys' ova, and is probably more marked in normal ova than is generally believed (Keibel). In case the fibrils of the magma are scanty or beginning to disintegrate, or in case they are greatly increased in number, dense enough partly to obliterate the embryo, the specimen is certainly pathological. Magma which is transparent and contains just enough reticulum to hold it together is to be viewed as the normal constituent of the exocœlom.

The nature of magma fibrils has not been definitely settled, but they appear to be connected with cells in some way as indicated in the ova described by Bryce and Teacher and Peters. Some embryologists are inclined to consider them the product of coagulation. However, they are present in the freshest specimens, and they cannot be stained by Weigert's fibrin stain. I have found reticular magma present in normal ova which were preserved in strong formalin immediately after their abortion. According to Retzius, the magma réticulé contains fibrils of a muco-fibrillar nature which become transparent in dilute acetic acid.

Before the circulation of blood is established between the embryo and the chorion,—that is, before the embryo is 2 mm. long,—the nutrition of the embryo and its umbilical vesicle must pass from the chorion through the magma. This may be the reason why any alteration in the nutrition of the embryo, which affects its normal development, first manifests itself in a change in structure of the magma réticulé. As the exocœlom is gradually obliterated the magma is pushed ahead of the advancing amnion and finally forms a delicate membrane of fibrils between the amnion and chorion.

BODY CAVITIES.

The cœlom of the embryo arises independently of the exocœlom in embryos between 1.5 and 2 mm. long. In specimens less than 1.5 mm. long studied by Peters, Graf Spee, and Minot, there is no trace of either blood-vessels or body cavity within the embryo, but in Graf Spee's well-known embryo *Gle.* (1.54 mm. long) traces of the beginning of the heart and its cœlom are present. Fig. 380, which is through the head of this embryo, contains on either side of the body a few scattered cells between the mesoderm and entoderm. These Graf Spee believes to be the endothelial anlage of the heart. In this same section there is a split in the mesoderm of the embryo, which continues through other sections and marks the beginning of the pericardial cœlom. It may be noted that the endothelial anlage of the heart and its cœlom arise after the foregut is well formed, —that is, after the head of the embryo is separated from the yolk-sac. The different sections show that the cœlom is of irregular form and size and it is surrounded with numerous dividing cells (Fig. 381).

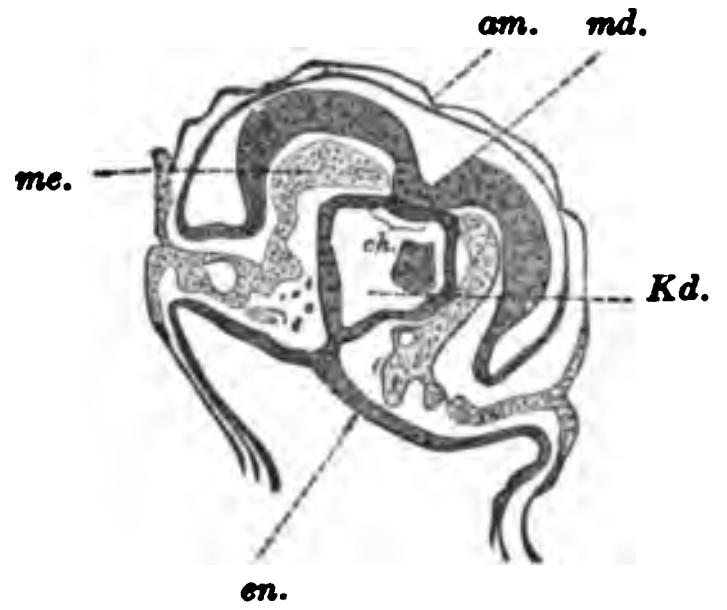

Fig. 380.—Last section (No. 24) through the foregut of Graf Spee's embryo *Gle.* (After Graf Spee.) *am.*, amnion; *md.*, medullary plate; *me.*, mesoderm; *Kd.*, foregut; *ch.*, chorda; *en.*, entoderm. The space in the mesoderm is the beginning of the cœlom, and between it and the entoderm is the anlage of the heart, which is not shown in the drawing.

Since no other human embryo has been studied which follows immediately upon Graf Spee's *Gle.*, we must fill out the gap by observations upon other mammalian embryos; these are very complete and have been made with great care. They do not contradict one another nor any of the observations made upon the development of the human cœlom. For these reasons much confidence can be placed upon facts derived from comparative embryology upon the early formation of the pericardial cœlom and their bearing upon the same in human embryos.

Bonnet's careful study of the development of the cœlom in the embryo sheep fills out perfectly the gap between Spee's *Gle.* and older human embryos. In the sheep the pericardial cœlom appears as irregular spaces on either side of the head much as in Graf Spee's embryo *Gle.* The spaces arise on both sides of the embryo, but are so irregular in position and form that their arrangement can not possibly be considered metameric. Next the spaces unite, thus forming in a relatively short time large spaces on either side of the body, which soon unite with each other at the extreme anterior end of the embryo, forming a horseshoe-shaped canal in the mesoderm on the ventral side of the head. Throughout its development the pericardial cœlom is closed on its lateral sides and does not communicate with the exocœlom, with the exception of its later and indirect communication through the peritoneal cœlom. It may also be noted that in the sheep the whole pericardial cœlom is formed hand in hand with the invagination of the foregut and before the endothelial anlage of the heart has arranged itself into vascular tubes, much as is the condition found in Graf Spee's embryo *Gle.*

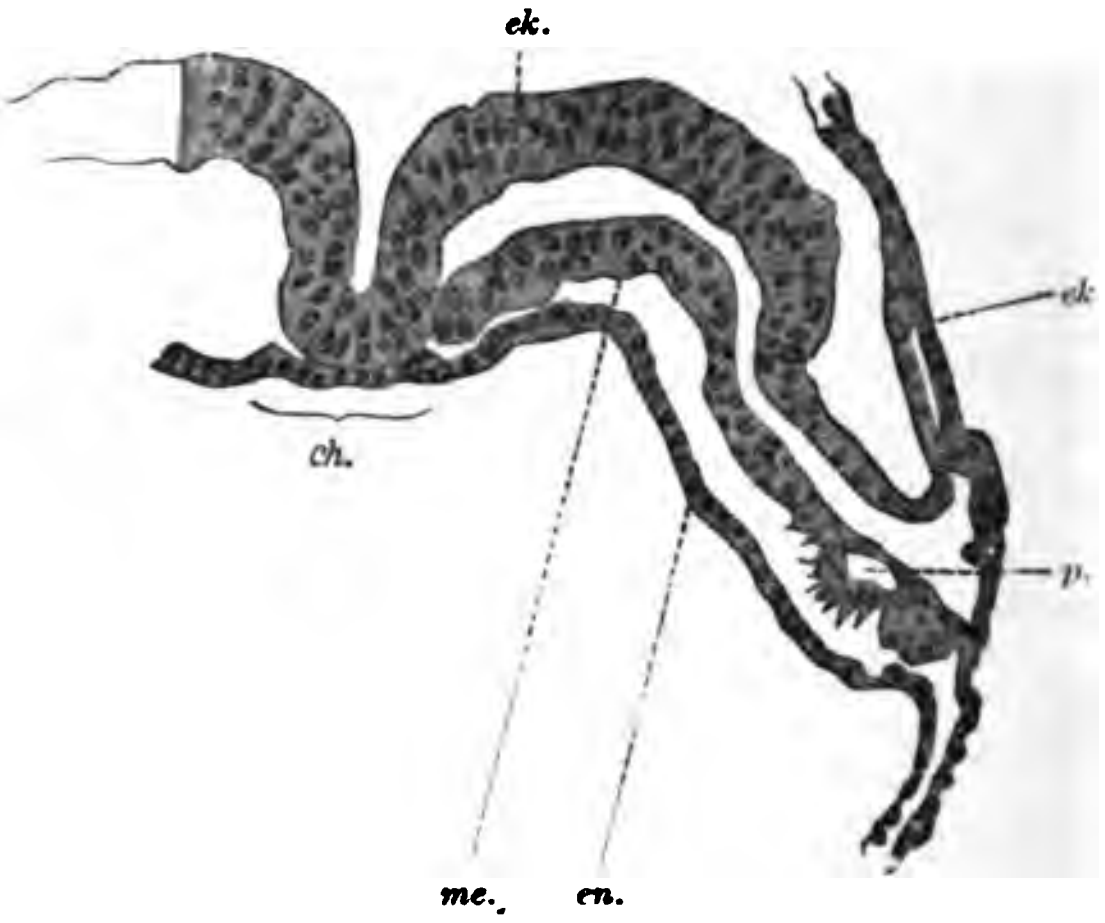

Fig. 381.—Section No. 81 through Graf Spee's embryo *Gle.* (After Graf Spee.) *p.*, pericardial cœlom, near which on the entodermal side, a few loose cells may be seen which may represent the anlage of the heart.

That the pericardial cœlom arises very early and independently of the exocœlom is farther proved by the work of Strahl and Carius, who studied its development in the guinea-pig and the rabbit and confirmed fully the earlier observations of His upon the first formation of the pericardial cœlom (*Parietalhöhle*). In the rabbit the pericardial cœlom ends in two dorsal and two ventral recesses, all four of which connect subsequently with the peritoneal cœlom. However, only the dorsal recesses break into the peritoneal cœlom in the human embryo, and it is this recess or canal which later on encircles the lung and probably forms the main anlage of the pleural cœlom.

We can now return to the human embryo, and the next stage after Graf Spee's *Gle.* which bears upon this point is found in a well-preserved normal human embryo 2 mm. long. The embryo came from a self-inflicted mechanical abortion and was soon preserved in formalin. Before transferring it to alcohol it measured about 2 mm. in length, but due to its shrinkage while being

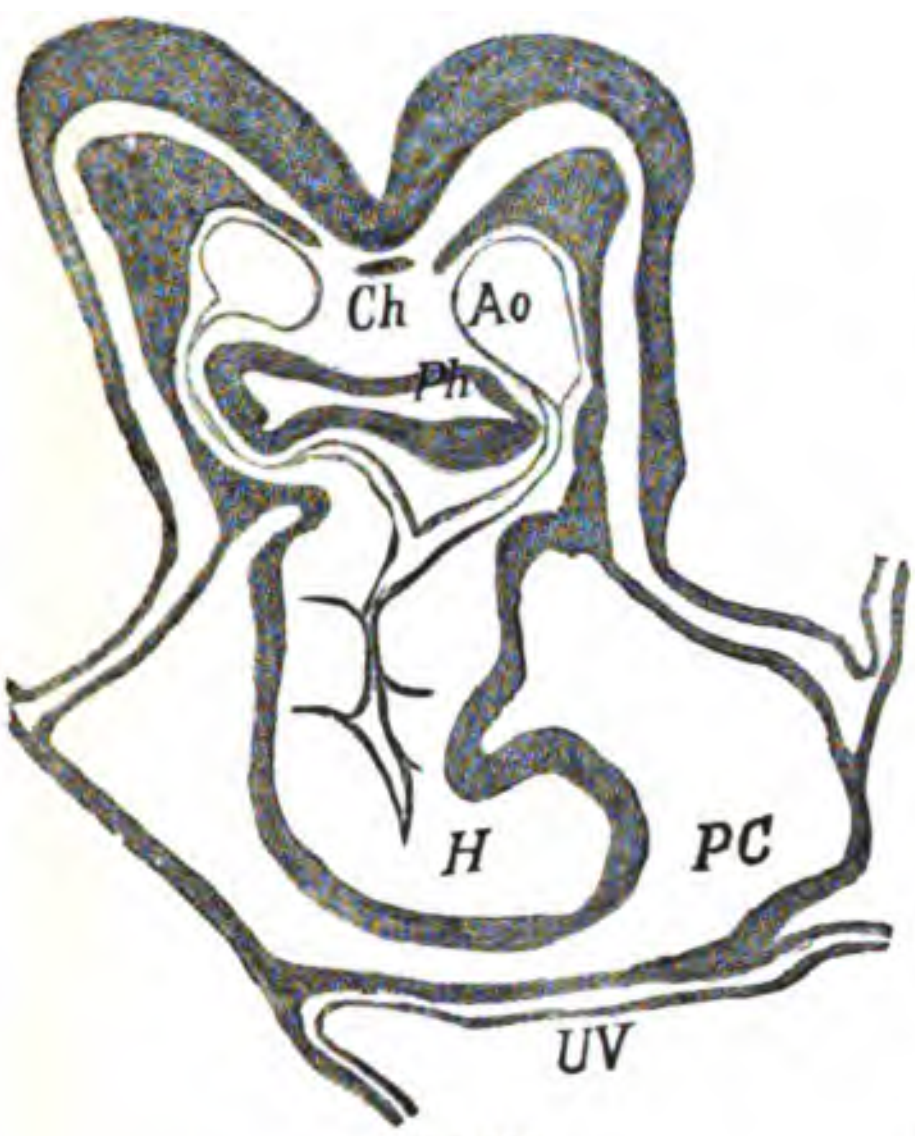

FIG. 382.

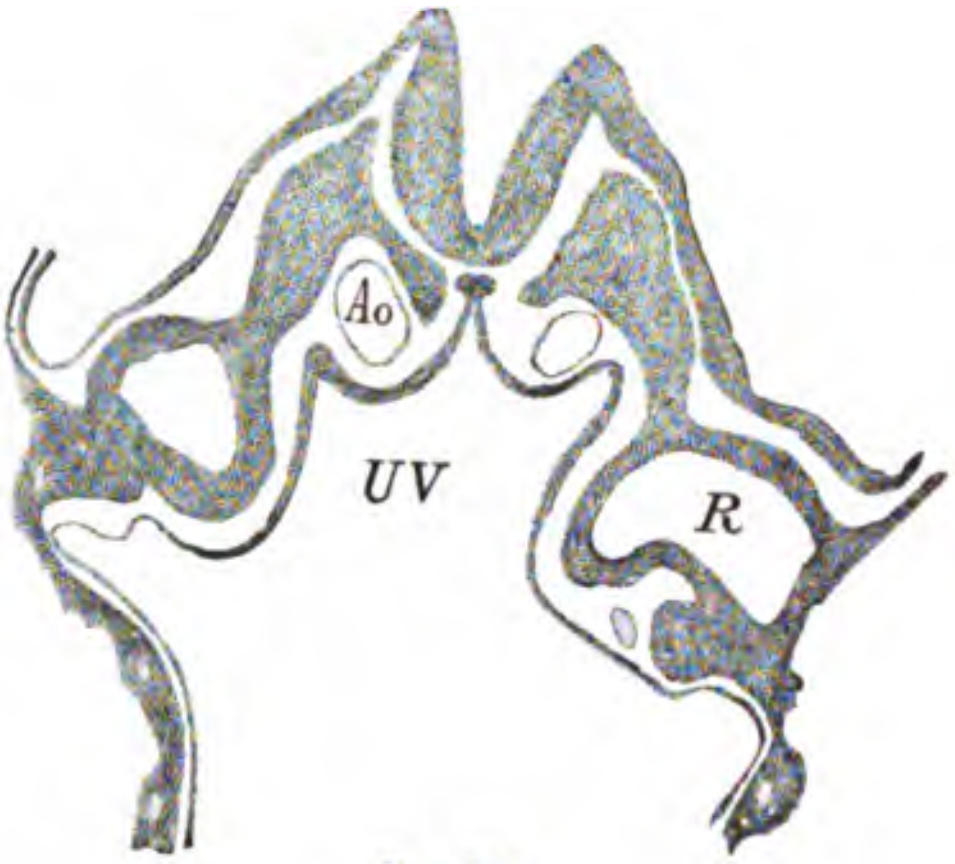

FIG. 384.

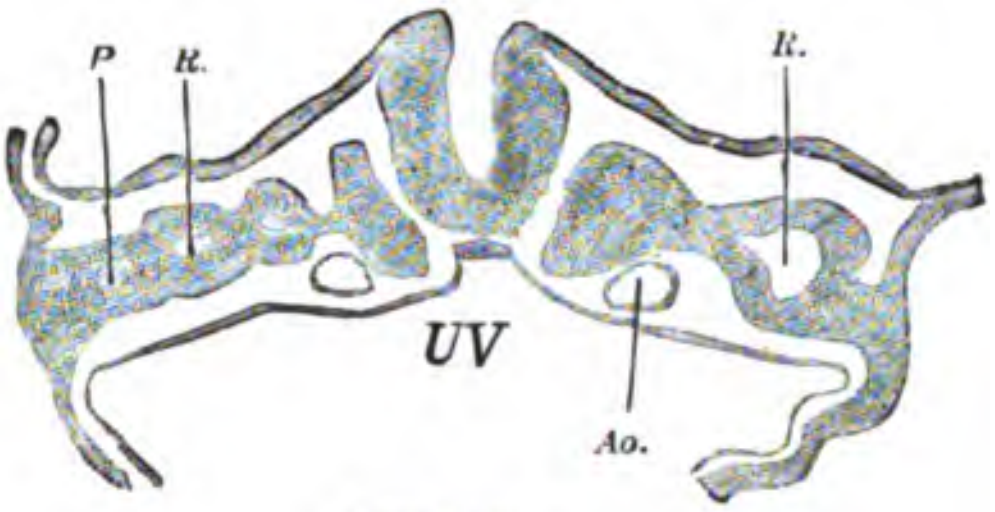

FIG. 385.

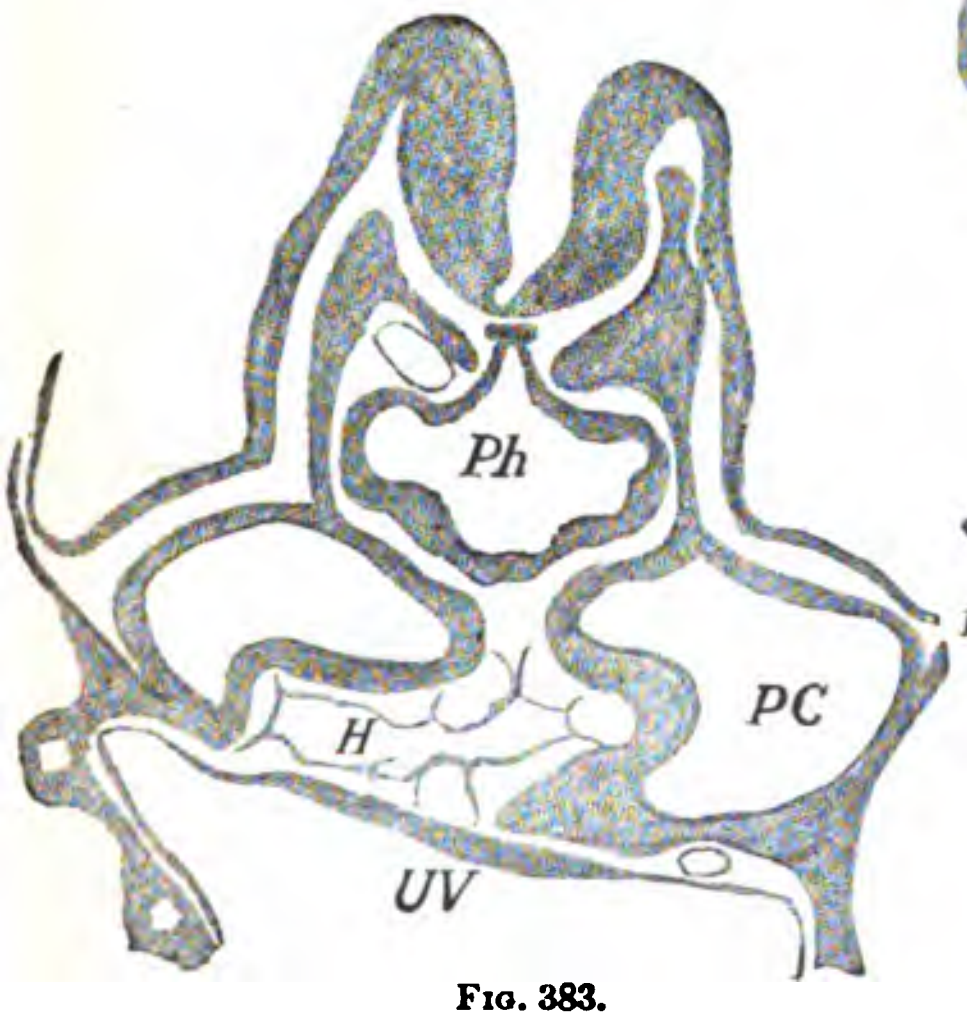

FIG. 383.

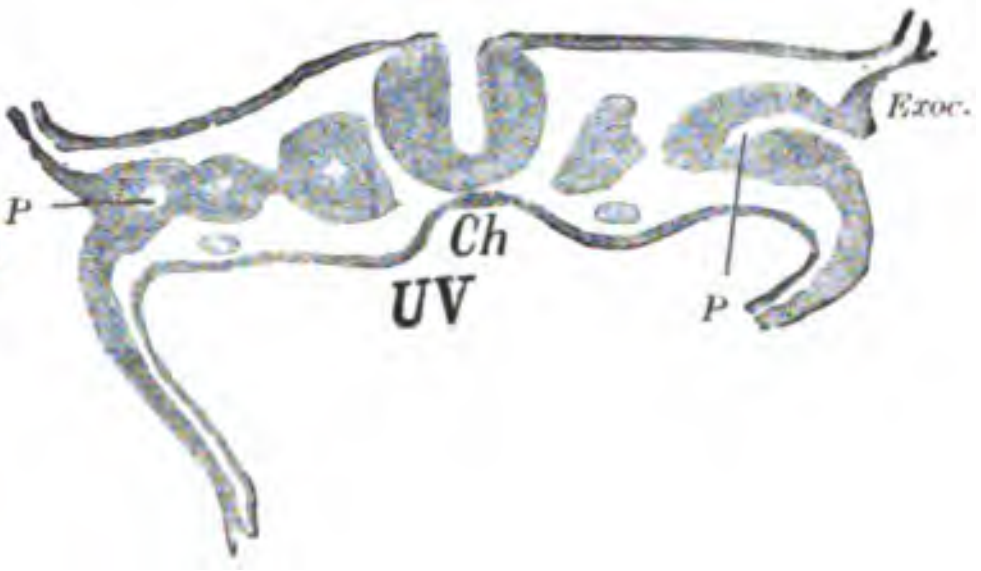

FIG. 386.

FIGS. 382–386.—Sections through a human embryo 2 mm. long (No. 391). Enlarged 100 diameters. Fig. 382, section 27; Fig. 383, 49; Fig. 384, 58; Fig. 385, 76; and Fig. 386, 95. *Ph*, pharynx; *H*, heart; *UV*, umbilical vesicle; *Ao*, aorta; *Ch*, chorda; *PC*, pericardial cœlom; *P.*, peritoneal cœlom; *Exoc.*, exocœlom; *R.*, recess from pericardial cœlom.

embedded it produced but 160 transverse sections each being 10 μ thick. The embryo has 7 myotomes. The figures (382–386) show that the pericardial cœlom encircles the heart on its ventral side and reaches down into a recess which communicates with the peritoneal spaces and through these with the exocœlom. The pericardial cœlom is entirely closed on all sides. The peritoneal cœlom is forming at numerous points in the mesoderm of the trunk of the embryo, not in any regular fashion; some of the spaces connect irregularly with one another, others connect with the exocœlom (Fig. 386), as is found to be the case in the sheep. Dandy has studied this embryo with great care, and a more detailed account of it, containing also a reconstruction of the cœlom, may be found in his publication.

Quite recently Keibel and Elze described an embryo nearly 2 mm. long in which the pericardial cœlom is separated from the exocœlom by a pronounced bridge of tissue. This specimen is of prime importance in the study of the cœlom in the human embryo, for through it we can connect the development of the cœlom in older and younger stages with one another, as well as with the condition found in the rabbit and in the sheep.

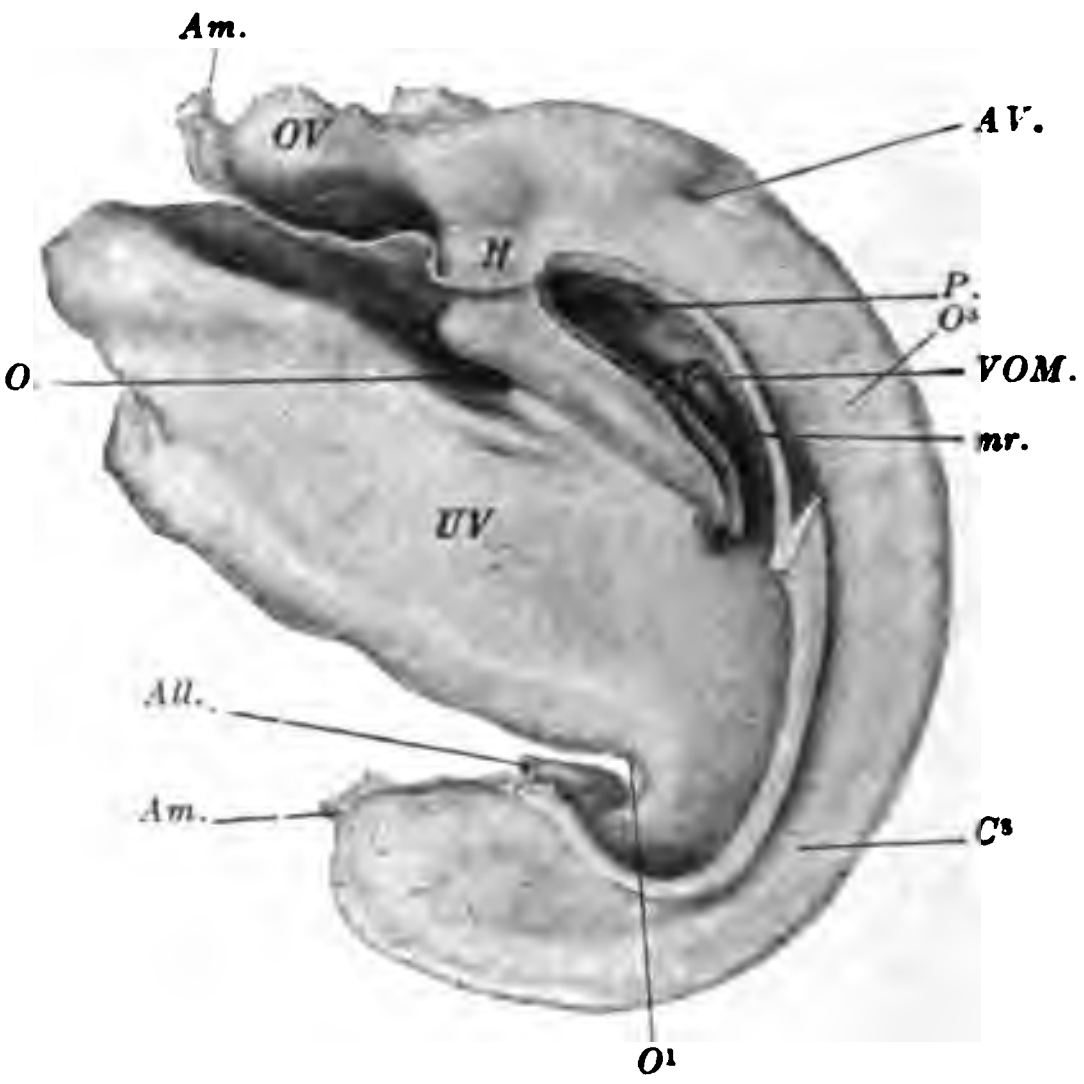

FIG. 387.—Profile reconstruction of an embryo 2.1 mm. long (No. 12). × 25 times. *Am*, amnion; *OV*, optic vesicle; *AV.*, auditory vesicle; *UV*, umbilical vesicle; *H*, heart; *VOM.*, omphalomesenteric vein; *mr.*, septum transversum; *O³*, third occipital myotome; *C⁸*, eighth cervical myotome.

Another embryo slightly older shows that the pericardial cœlom communicates freely with the peritoneal cœlom and this in turn with the exocœlom (Fig. 387). Probably this specimen is not altogether normal, because the brain is not well developed and the spinal cord behind appears to be too wide open. The liver and thyroid are beginning to form and two branchial pockets are well developed from the pharynx. In its caudal shifting the amnion has passed the heart, leaving the ventral body wall covered with ectoderm. The attachment of the umbilical vesicle to the body is constricting from all sides, receding before the amnion in front, at *O*, and from the allantois behind, O^1. Somewhat later, when the constriction is more marked and the amnion comes to lie upon the umbilical stalk, *UV*, the points *O* and O^1 will be the points of communication between the peritoneal cœlom of the two sides of the body. Other sections of this embryo are shown in Fig. 229, Chapter XI.

FIG. 388.—Section through the head of the embryo 2.1 mm. long. × 50 times. *Coe*, cœlom; *Ph*, pharynx; *L*, liver; *ST*, septum transversum; *UV*, umbilical vesicle.

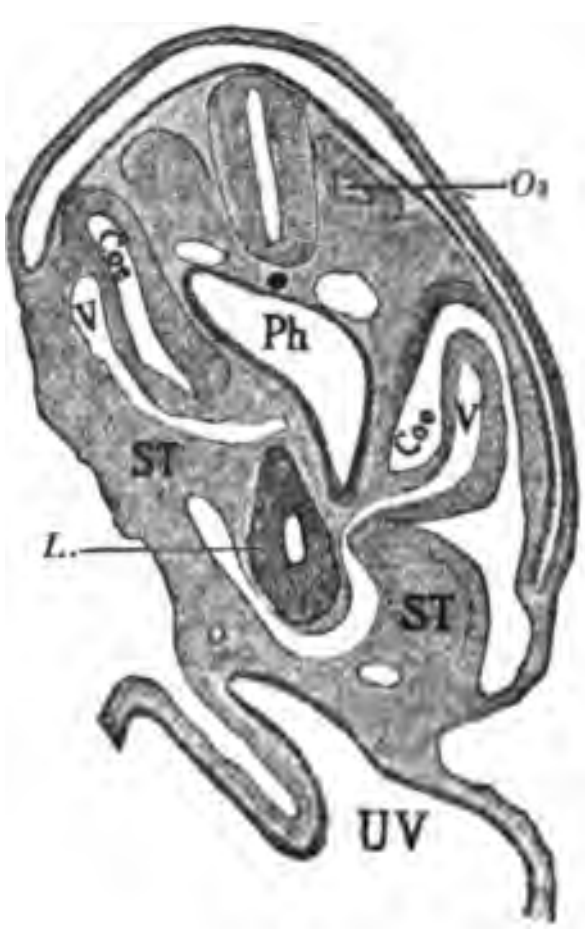

FIG. 389.—Section through the third occipital myotome of the embryo 2.1 mm. long, .04 mm. nearer the tail than Fig. 388. × 50 times. O_3, third occipital myotome; *Coe*, cœlom; *V*, vein; *ST*, septum transversum; *L.*, liver; *Ph*, pharynx; *UV*, umbilical vesicle.

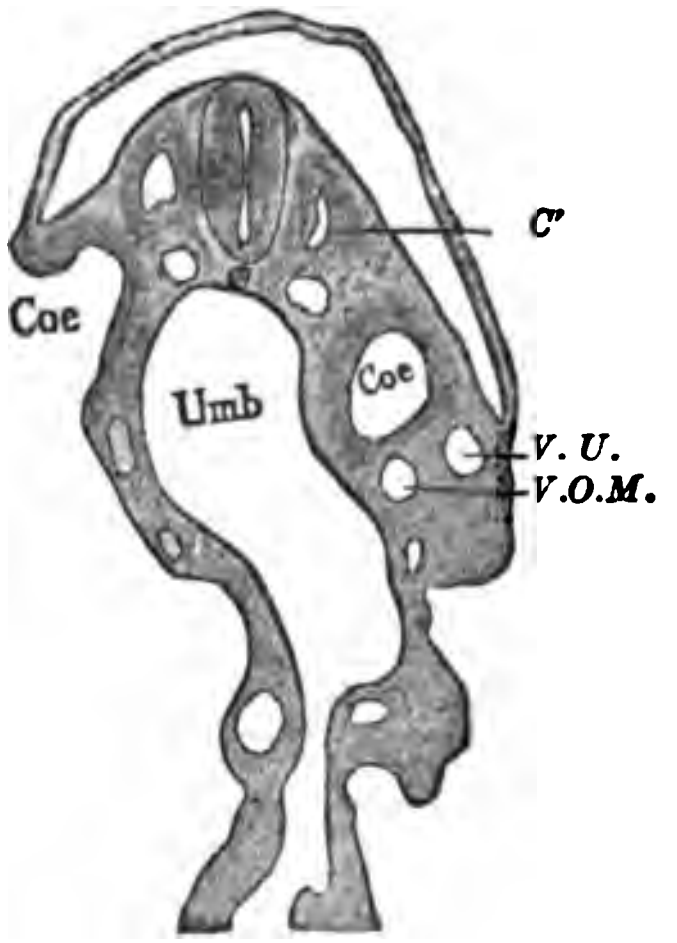

FIG. 390.—Section through the first cervical myotome of the embryo 2.1 mm. long, .23 mm. nearer the tail than Fig. 389. × 50 times. *C'*, first cervical myotome; *Coe*, cœlom; *V. U.*, umbilical vein; *V.O.M.*, omphalomesenteric vein; *Umb.*, umbilical vesicle.

FIG. 391.—Section through an embryo 3.5 mm. long (No. 164). × 50 times. *L*, liver; *Vent*, ventricle; *SR*, sinus reuniens; *Coe*, cœlom.

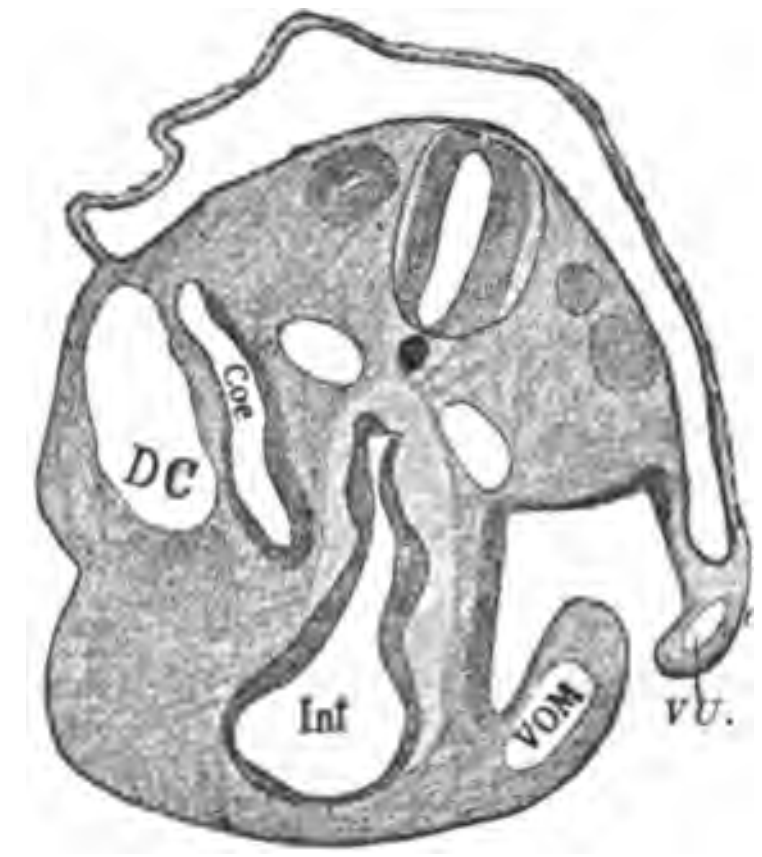

FIG. 392.—Section through the embryo 3.5 mm. long, .18 mm. nearer the tail than Fig. 391. × 50 times. *Coe*, cœlom; *Int*, intestine; *VOM*, omphalomesenteric vein; *VU.*, umbilical vein; *DC* ductus Cuvieri.

In front the yolk-vein, *VOM,* connects freely with the capillaries of the yolk-vesicle, and as it enters the heart it is bounded on its ventral side by a recess, Fig. 388, *Coe,* which, however, does not communicate directly with the peritoneal cœlom or with the exocœlom. Capillary veins also arise in the septum transversum, around the liver bud, Fig. 389. More caudal, Fig. 390, *VU,* a branch of the vein extends to the lateral side of the body, which is no doubt the anlage of the umbilical vein. These veins are more pronounced in an embryo slightly older, Figs. 391 and 392, which shows the ductus Cuvieri, the umbilical vein, the omphalomesenteric vein, and a vein running from the head—the jugular vein. All these veins unite in the sinus reuniens, which in turn enters the heart.

SEPTUM TRANSVERSUM.

It is seen from the description just given that the body cavities arise from two primary spaces, as was first well shown by His, and that each of these in turn is bilateral in origin. In addition to these there is the exocœlom as well as the cavities of the myotomes which in the human embryo soon disappear; they communicate in part with the rest of the body cavity (Keibel and Elze). The two pericardial cœlom cavities soon unite at the front end of the head, and this space later on encircles the whole ventral surface of the heart. Next, two pockets arise from it, extend dorsally, and unite with the two peritoneal cavities. These diverticula barely exist as separate cavities, but blend immediately, as soon as they begin to form, through the peritoneal cavity with the exocœlom. By the end of the fourth week, as represented in Fig. 387, the five primitive cavities form a single cœlom, from which at last seven body cavities arise. The primitive and most fundamental septum by which the common body cavity is broken into compartments was discovered by His, which he described as the septum transversum. Figs. 383 and 384 show that the umbilical vesicle is probably tied to the heart by means of two blood-vessels, which are well embedded in a mass of tissue of the embryo as shown in Fig. 387. Within this mass the blood-vessels go to the heart and into it the liver grows. To the extent in which the pericardial cœlom (*Parietalhöhle*) does not communicate with the peritoneal cœlom, its floor is formed by a mass of tissue which unites the two sides of the trunk of the body with each other, and also binds the sinus venosus to the foregut. It is this mass of tissue which His terms the primitive diaphragm or the septum transversum. From it the principal part of the permanent diaphragm is formed, and by its extension the primary pericardium and the primary diaphragm are completed.

In an embryo slightly larger than the one just described, the septum transversum is well defined, as may be seen in Fig. 394. The lungs have just begun to sprout (Fig. 393), and on the right side there is a diverticulum from the peritoneal cœlom, which marks the beginning of the lesser peritoneal cavity. The liver is beginning to ramify within the septum and protrudes dorsally into the embryonic peritoneal cavity. In another embryo of about the same age the septum transversum is practically complete and in its form and position corresponds exactly with the description of it given by His (Fig. 395). The pericardial, pleural, and peritoneal cœloms communicate as freely as they ever will, for there is as yet practically no sign of the formation of secondary septa. A reconstruction of the region of the septum of this embryo, showing the cœlom, is given in Figs. 396 and 397. The pericardial cavity lies completely on the ventral side of the septum, from which it extends in the form of a U-shaped canal around the septum on either side of the lung, stomach, and intestine. The pleural cœlom—that is, the cœlom which surrounds the lung buds—is much the same in form on both sides of the body, but the peritoneal cœlom shows marked bilateral inequalities due to the changes which have taken place with the shifting of the stomach towards the left side of the body.

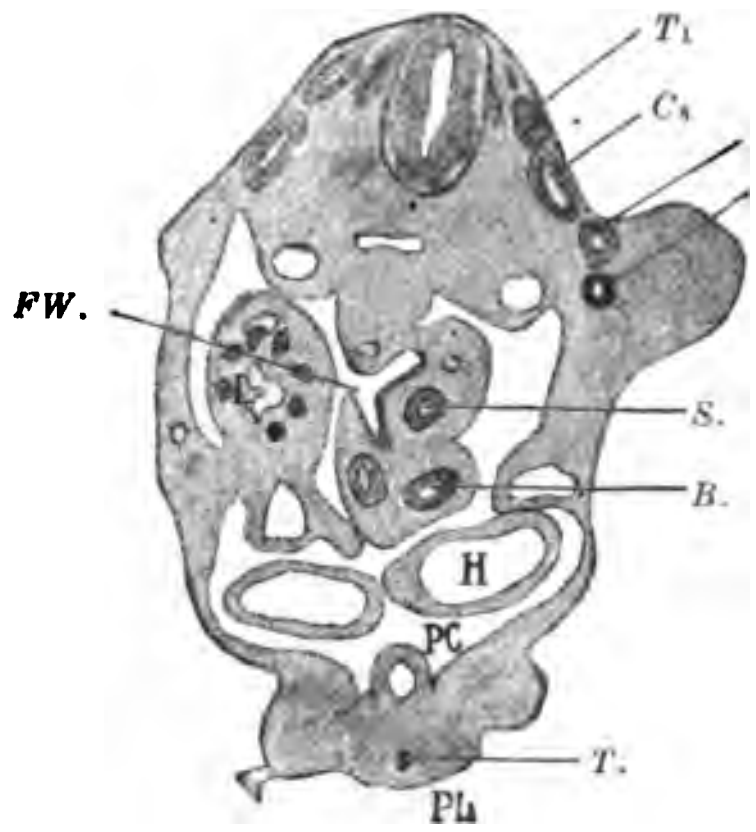

Fig. 393.—Section through an embryo 4.3 mm. long (No. 148). × 25 times. T_1, first thoracic myotome; C_6, C_7, and C_8, cervical myotomes; S., stomach: B. bronchus; H, heart; T., thyroid; PC, pericardial cavity; L, liver; FW., foramen of Winslow.

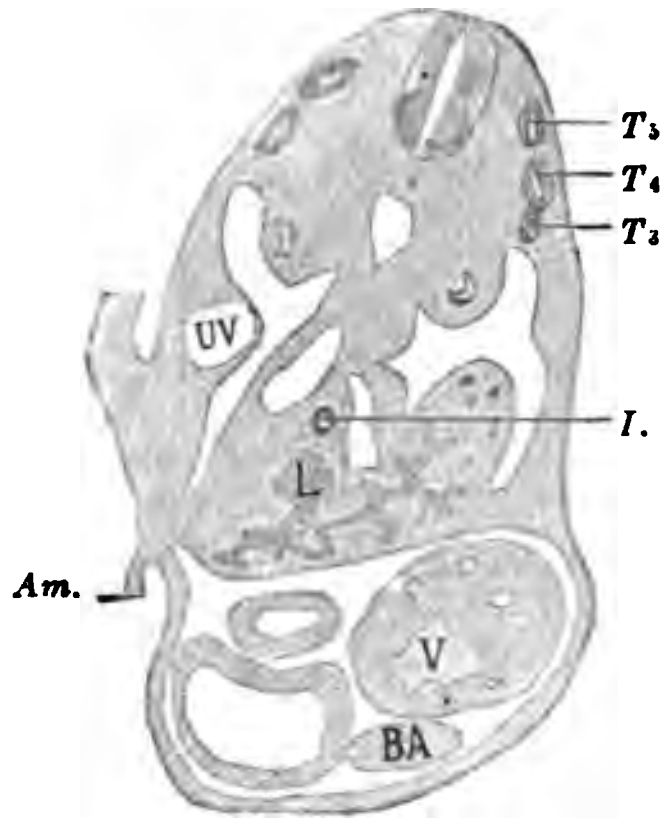

Fig. 394.—Section through the embryo 4.3 mm. long, .4 mm. deeper than Fig. 393. × 25 times. T, thoracic myotomes; I. intestine; L, liver; V, ventricle; BA, bulb of the aorta; Am., amnion; UV, umbilical vein.

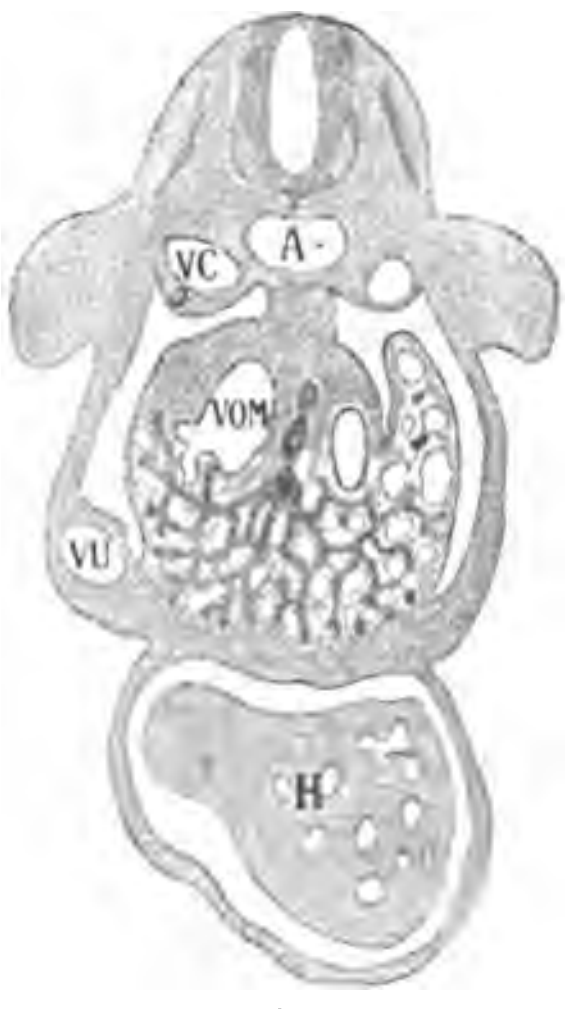

Fig. 395.—Section through an embryo 4.5 mm. long (No. 76). × 25 times. VC, cardinal vein; A, aorta; VOM, omphalomesenteric vein; VU, umbilical vein; H, heart.

In Fig. 396, below the letters *FW*, there is a marked depression, the recessus mesenterico-entericus, which corresponds with the shifting of the stomach to the left. (This is well shown in Fig. 405.) Above *FW* a sac or invagination passes on the dorsal median side of the lung to form the recessus pneumato-entericus dexter. This space also borders upon the liver and forms a third recess, the recessus hepato-entericus, over the region of the lobus Spighelii. These spaces together form the lesser peritoneal cavity and were recognized as such by His in 1880. From this time onward it has been described by numerous embryologists, and the most satisfactory study of it in the human embryo is by Broman, whose terminology I have adopted.

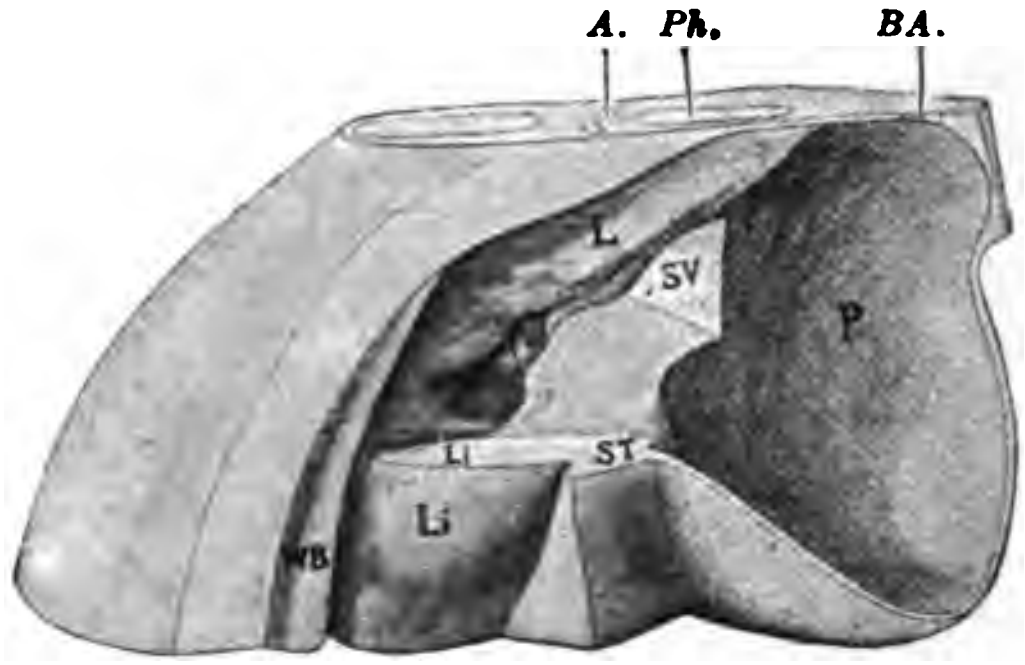

FIG. 396.

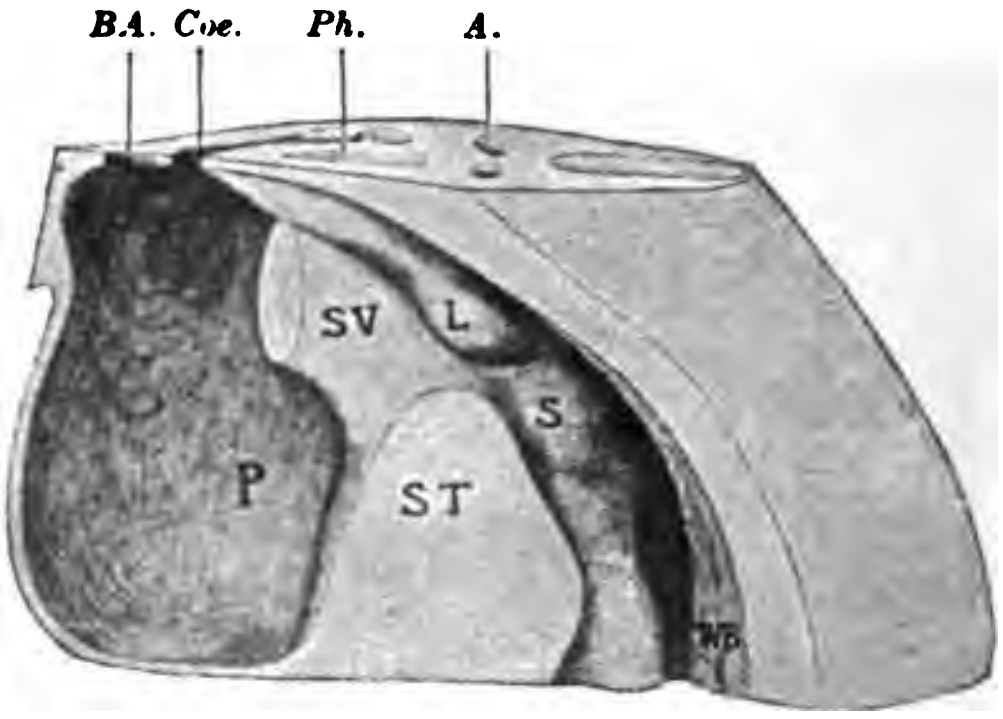

FIG. 397.

FIGS. 396 and 397.—Right and left views of a reconstruction of the embryo 4.5 mm. long. × 25 times. *A.*, aorta; *Ph.*, pharynx; *BA.*, bulbus aortæ; *Coe*, cœlom; *P*, pericardial cœlom; *L*, lung; *Li*, liver; *WB*, Wolffian body; *S*, stomach; *FW*, foramen of Winslow; *SV*, sinus venosus; *ST*, septum transversum.

There is but little to be said about the left pleural recess except that its configuration is that of the lung over which it passes. However, between the lung and the stomach (Fig. 397, *L* and *S*) there is a slight depression. There is present at this point in reptiles and birds a marked pocket, or "left lesser peritoneal cavity," which has also been described in mammalian embryos by Ravn. Ravn's discovery was doubted by a number of embryologists, but recently Broman has found it in all mammalian embryos examined, including the human. According to Broman the left bursa appears in human embryos about 3 mm. long, and vanishes immediately, that is, before they are 4 mm. long. The left recessus pneumato-entericus, as Broman calls it, is decidedly smaller than the right, does not encroach upon the left lung as much as the right does upon the right lung; in fortunate transverse sections they appear to be symmetrical and equal (Fig. 398).

FIG. 398.—Section through the right and the left lesser peritoneal cavities in a human embryo 3 mm. long (No. 239). × 50 times. *OE*, œsophagus; *L*, liver; *R.P.E.D.*, recessus pneumato-entericus dexter; *R.P.E.S.*, recessus pneumato-entericus sinister.

Up to the present stage the septum transversum, which arose in the region of the head, has gradually receded until its dorsal end has fallen to the region of the fifth cervical nerve. This stage is of importance, for it shows how the phrenic nerve enters the septum transversum (Fig. 399, *Ph*). This section shows that the nerve grows at first between the subclavian and cardinal veins along the lateral wall of the pleural cœlom towards the ductus Cuvieri. Subsequently, when the pericardial cœlom is separated from the pleural by the growth of the pleuropericardial membrane from the wall of the ductus Cuvieri to the root of the lung, it leaves the nerve on the lateral edge of this separating membrane. Later, when the lung burrows to extend around to the side and the front of the heart (Fig. 414), the nerve is pushed into the pleuropericardial membrane between the heart and the lung. This additional rotation in the development of the viscera makes this nerve the most important landmark by which we retain our conception of the relation of these organs.

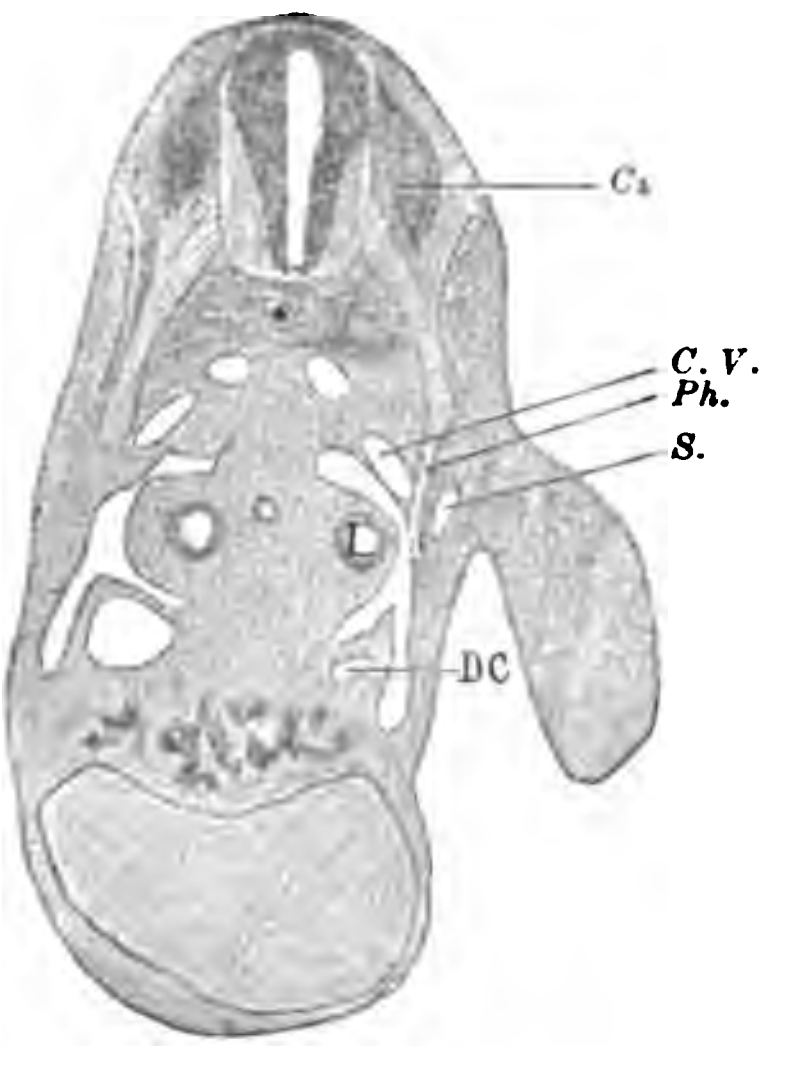

FIG. 399.—Section through an embryo 5 mm. long (No. 80). × 25 times. C_5, fifth cervical nerve; *C.V.*, cardinal vein; *S.*, subclavian vein; *DC*, ductus Cuvieri; *L*, lung; *Ph*, phrenic nerve.

In addition to the rotation of the organs around the phrenic nerve in the transverse plane of the body, there is another and greater shifting of the organs in their descent from the region of the head down into the thorax. This well-known descent of the diaphragm during development was first observed by von Baer, and later was more completely studied by His, Uskow, and myself. The accompanying scheme, Fig. 400, illustrates this process. On the right side of the schema, which is in the form of an embryo six weeks old, the numbers of the segments of the body are given. The space marked *Co* represents the communication between the pleural and the peritoneal cœloms. The rectangular blocks in front represent the position of the septum transversum in embryos of various sizes which are indicated by the accompanying numbers. Thus, the block in the head region represents the position of the septum in an embryo 2 mm. long and that in the lower thoracic region the position of the finished diaphragm in an embryo 24 mm. long. The arrows indicate that the septum is moving more rapidly where they are located than elsewhere. In general there are two main foci around which the diaphragm rotates:

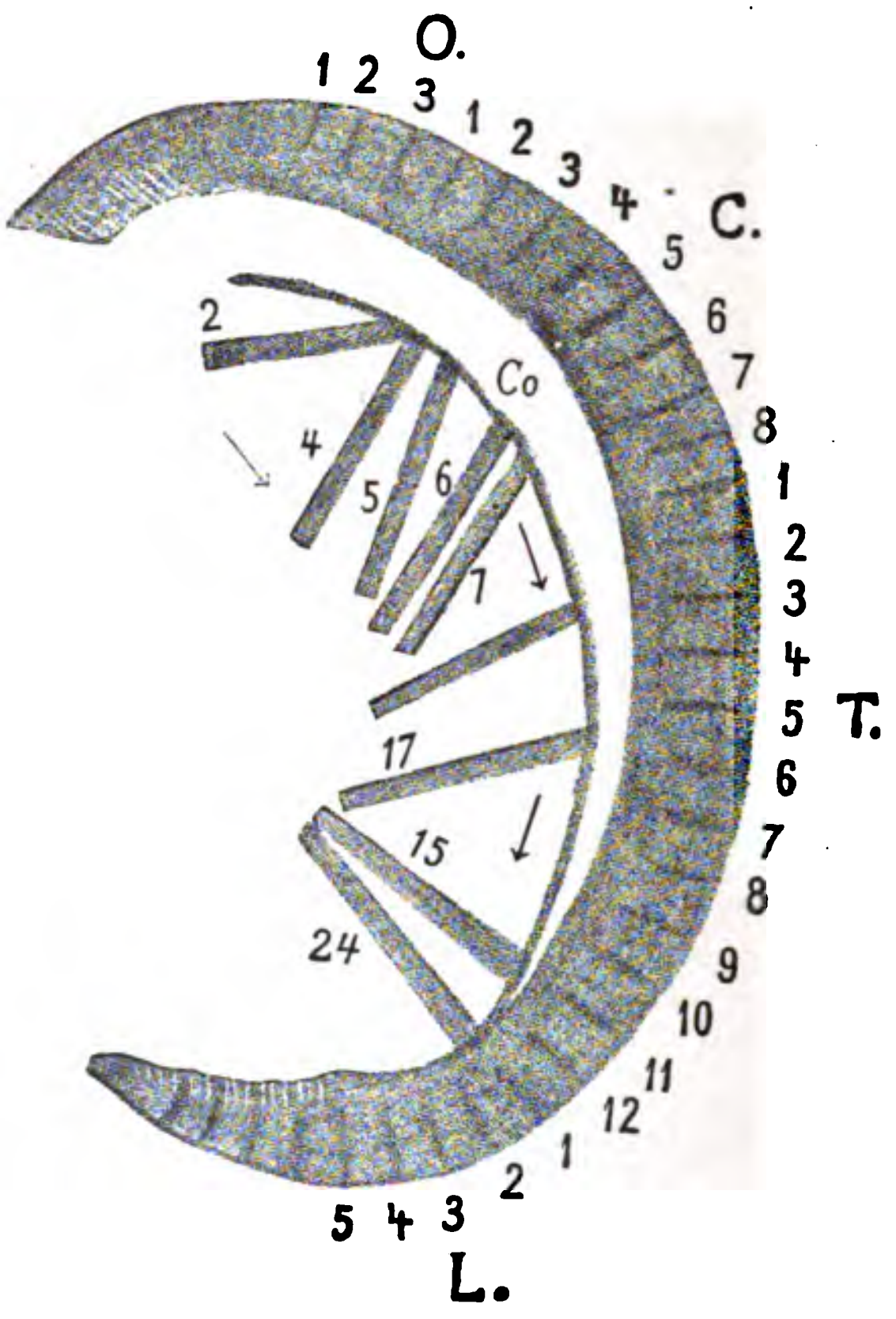

FIG. 400.—Scheme showing the position of the septum transversum within the body in human embryos from 2 to 24 mm. long. For description see text. *O.*, occipital region; *C.*, cervical; *T.*, thoracic; *L.*, lumbar; *Co*, cœlom.

(1) in the upper cervical region at the dorsal end of the septum, which is its position in embryos 4 to 7 mm. long, and (2) in the thoracic region at the ventral end of the septum, which is brought about by the growth of the heart and lungs within the thorax.

Up to the end of the fifth week there is no sign whatever of a separation between the various portions of the cœlom, but now a line of separation makes its appearance between the pericardial and pleural cœloms, due to a constriction of its walls along the course of the ductus Cuvieri, or rather the ductus lies in a ridge of tissue encircling the canal of communication between the pleural and the pericardial cœloms. This ridge is not present in one embryo 5 mm. long, but in another of this size there is an elevation on the dorsal wall of the pleural cœlom, Fig. 401, which encircles the lung and joins the dorsal end of the septum transversum. This ridge is one of the pillars of Uskow, or the beginning of the *pulmonary ridge,* as I have termed it. It gradually widens to cover the whole lung; on its cephalic end it gives rise to the pleuropericardial membrane of Uskow, and on its caudal end to the pleuroperitoneal membrane of Brachet. For the present, while it still represents two structures, it should carry a single name, and I believe *pulmonary ridge* to be a suitable one. In later stages, when the pulmonary ridge gives rise to the pleuropericardial and the pleuroperitoneal membranes, the name should be dropped.

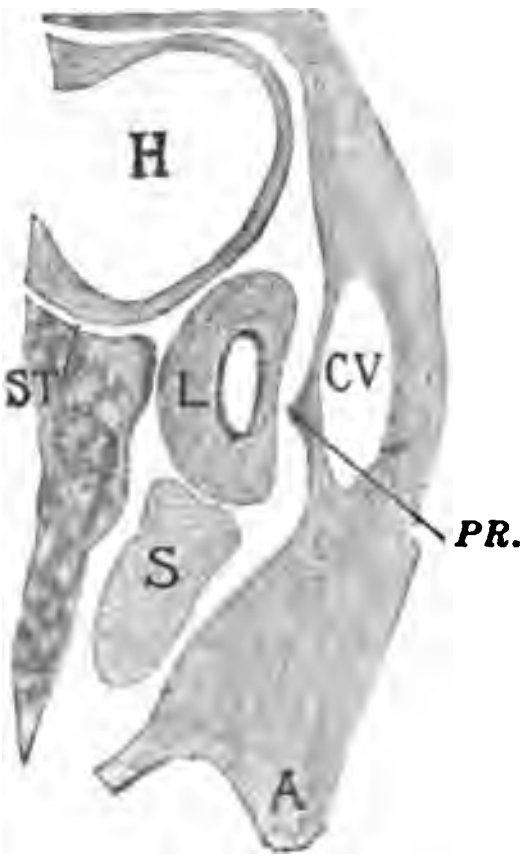

FIG. 401.—Sagittal section through an embryo 5 mm. long (No. 136). × 25 times. *H,* heart; *CV,* cardinal vein; *ST,* septum transversum; *L,* lung; *S,* stomach; *A,* arm; *PR.,* pulmonary ridge.

SEPARATION OF THE PERICARDIAL, PLEURAL, AND PERITONEAL CAVITIES.

The first steps required to bring about a separation of these cavities have been taken and are well under way in an embryo 7 mm. long (Figs. 402–405). The embryo is well kinked upon itself and the septum transversum in its wandering is entering the thorax, as Figs. 400 and 402 show. The communications between the pericardial and pleural cœloms have been reduced to narrow slits, as indicated by the arrow in Fig. 402 and in the cast of the cœlom as shown in Fig. 403. A section through the lung region, Fig. 404, shows the two ridges cut across four times. The reconstruction, Fig. 402, gives the relation of the pulmonary ridge to the surrounding organs and to the structures of the body in its immediate neighborhood. This ridge is well shown in the His *Atlas,* embryos A and B, as well as in Piper's reconstruction, and it may be seen in any human embryo of this stage. The relation of the ridge to the phrenic nerve, as well as its form in older embryos, makes of it the anlage of both pleuropericardial and pleuroperitoneal membranes. It lies in the sagittal plane of the body in this embryo in the region of the fourth cervical nerve, immediately over the lung bud, and connects the dorsal end of the septum transversum with the Wolffian body. In sagittal sections of embryos of this stage the ridge may also be cut twice, as Fig. 406 shows.

FIG. 402.—Embryo 7 mm. long (No. 2). Enlarged 14 times. *D.C.*, ductus Cuvieri; *Ph.*, phrenic nerve; *l*, lung; *Li*, liver; *S*, stomach; *W*, Wolffian body.

The embryos just described are kinked to their maximum, and in the next stage, with the disappearance of the sinus præcervicalis and the beginning of the development of the neck, the head begins to erect itself and the pulmonary ridge widens and spreads both towards the heart and the stomach, as Fig. 407 shows. The connection between the pleural and pericardial cavities is reduced to a small narrow slit, which is guarded on the pericardial side by a valve-like membrane, the pleuropericardial membrane.

As the pulmonary ridge widens to encircle most of the lung, the dorsal end of the septum transversum sinks into the thorax

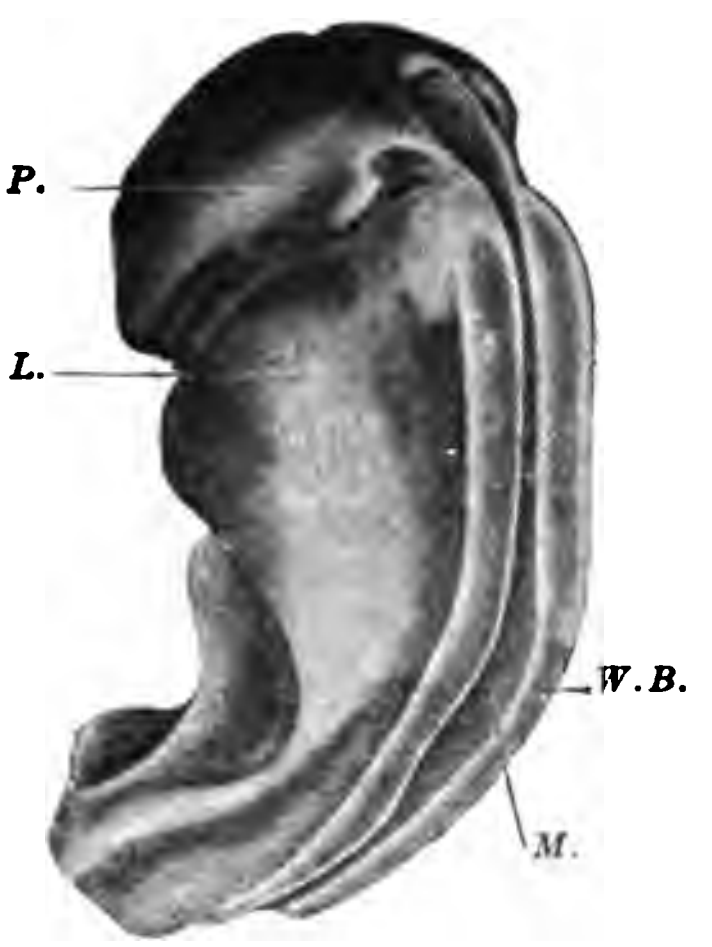

FIG. 403.—Cast of cœlom of the embryo 7 mm. long. × 14 times. *P.*, pericardial cœlom; *L.*, cœlom encircling liver; *W.B.*, position of Wolffian body; *M.*, position of mesentery.

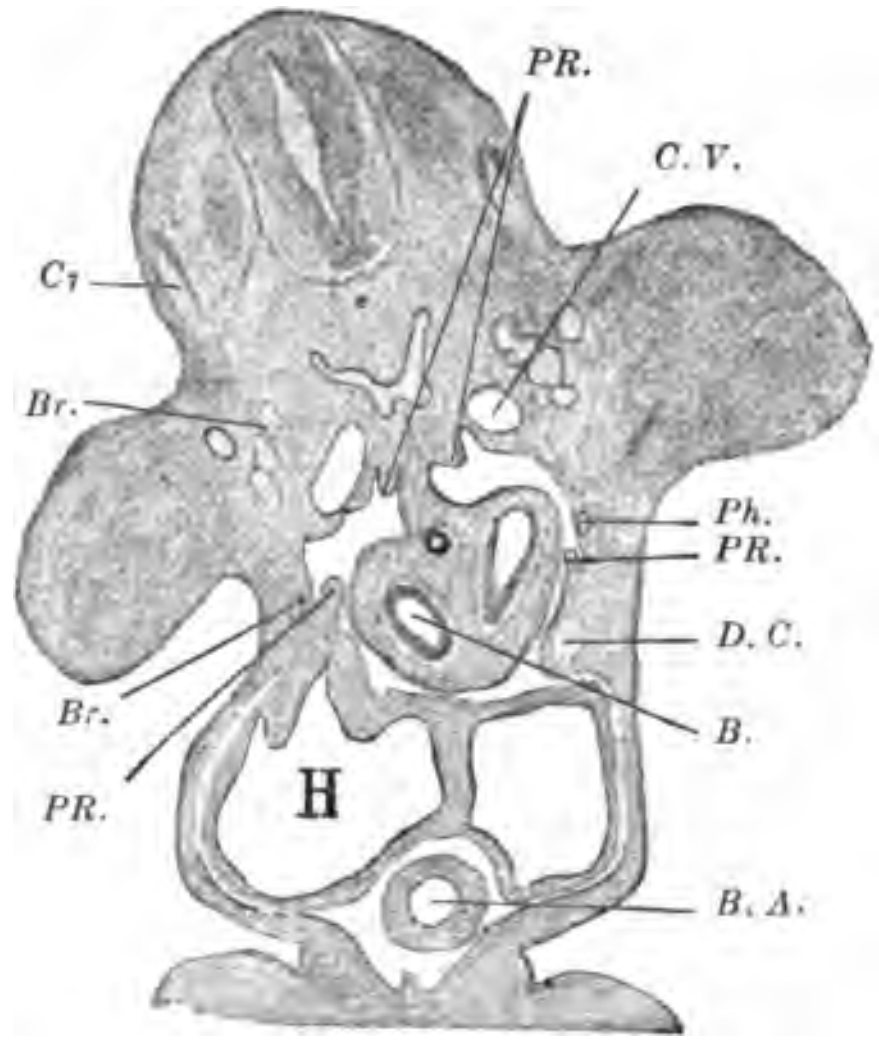

FIG. 404.—Section through the seventh cervical segment of the embryo 7 mm. long. (No. 2). × 25 times. C_7, seventh cervical myotome; *C.V.*, cardinal vein; *D.C.*, ductus Cuvieri; *Br.*, brachial plexus; *PR.*, pulmonary ridge; *Ph.*, phrenic nerve; *B.*, bronchus; *H*, heart; *B.A.*, bulbus aortæ.

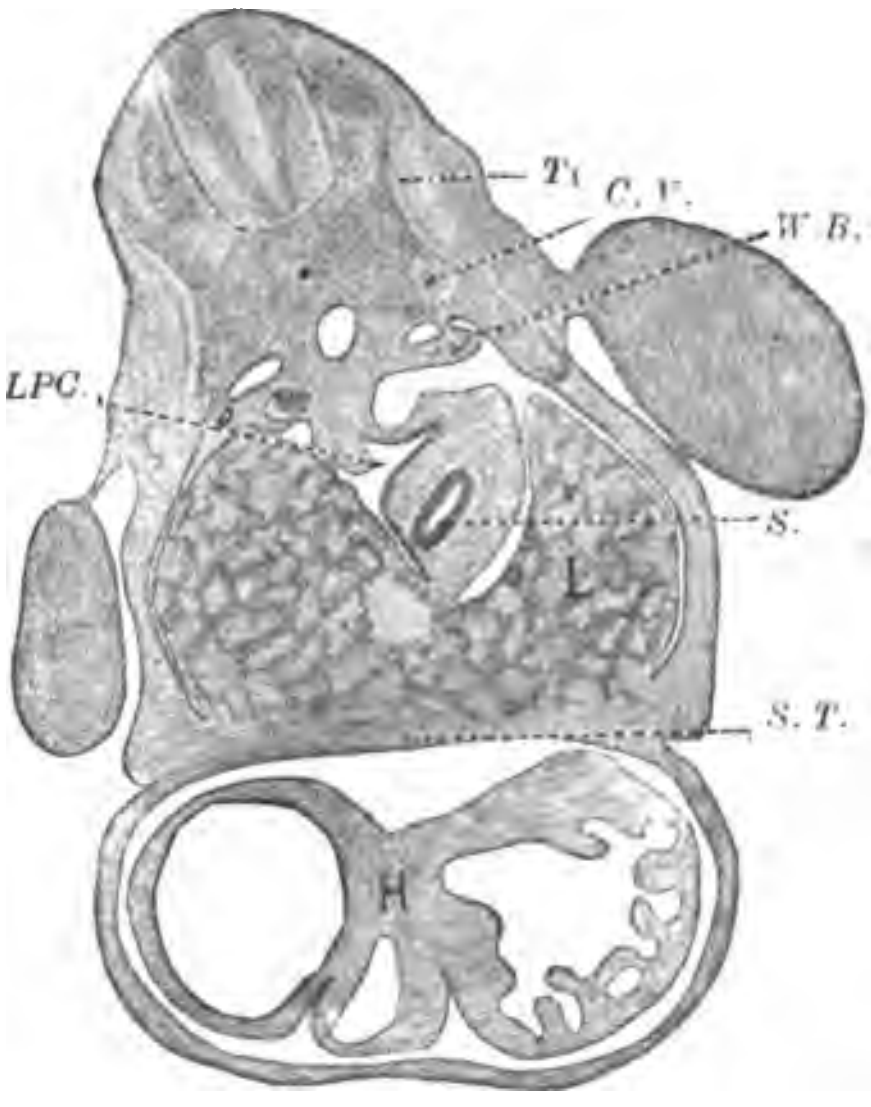

FIG. 405.—Section through the embryo 7 mm. long, .6 mm. deeper than 404. × 25 times. T_1, first thoracic myotome; *C.V.*, cardinal vein; *W.B.*, Wolffian body; *S.*, stomach; *LPC.*, lesser peritoneal cavity; *L*, liver; *H*, heart; *S.T.* septum transversum.

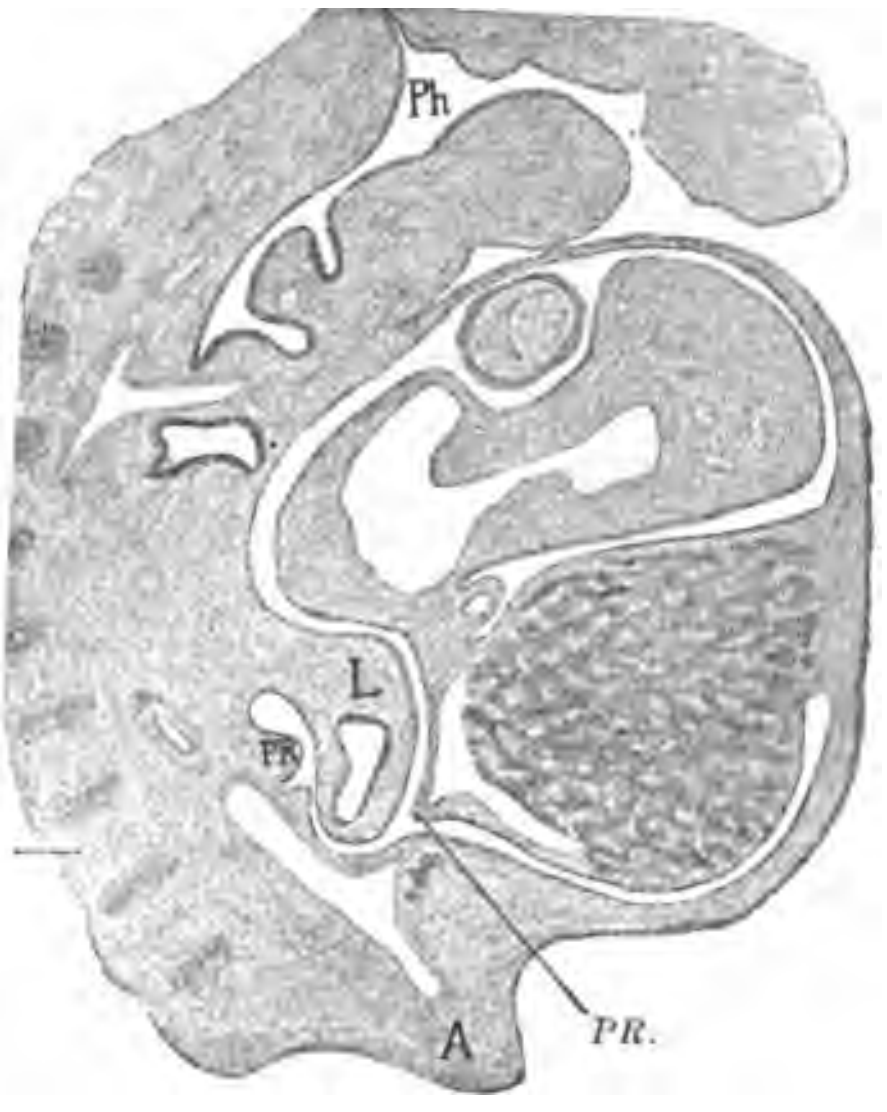

FIG. 406.—Section through an embryo 6.5 mm. long (No. 116). × 25 times. *Ph*, pharynx; *A*, arm; *PR.*, pulmonary ridge; *L*, lung.

more rapidly than does its ventral end. By this process the septum gradually turns a half revolution. The side that was its ventral surface in an embryo 7 mm. long (Fig. 402) has become its dorsal surface in an embryo 11 mm. long (Fig. 414). All this is well

Fig. 407.—Embryo 9 mm. long (No. 163). × 9 times. *D.C.*, ductus Cuvieri; *Ph.* phrenic nerve; *l*, lung; *Li*, liver; *S*, stomach; *W*, Wolffian body.

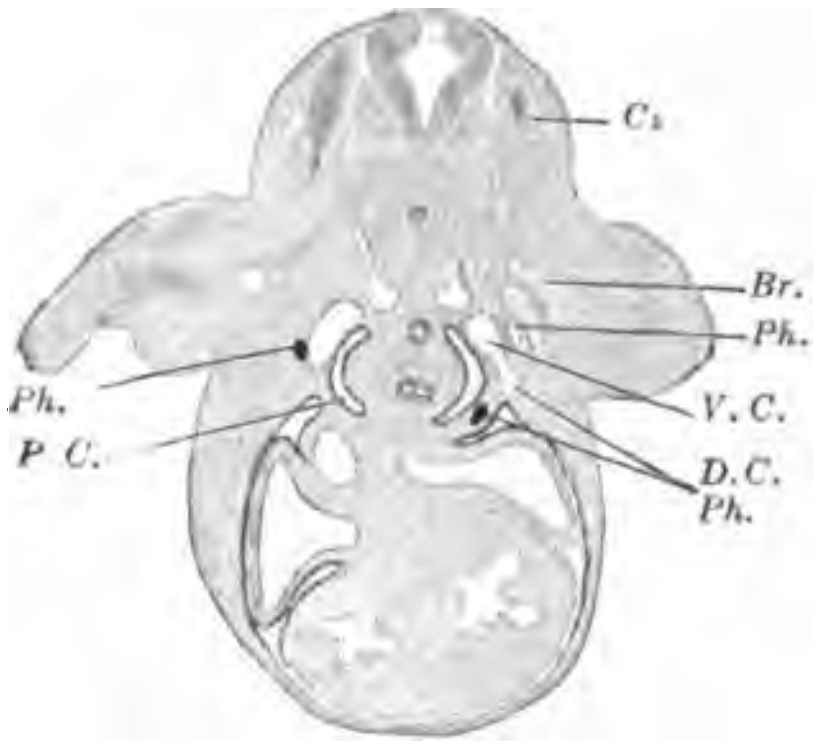

Fig. 408.—Section through the fifth cervical myotome of the above embryo. × 12 times. C_5, fifth myotome; *V.C.*, cardinal vein; *D.C.*, ductus Cuvieri; *Br.*, brachial plexus; *Ph.*, phrenic nerve; *P.C.*, cephalic end of the pulmonary ridge forming the beginning of the pleuropericardial membrane.

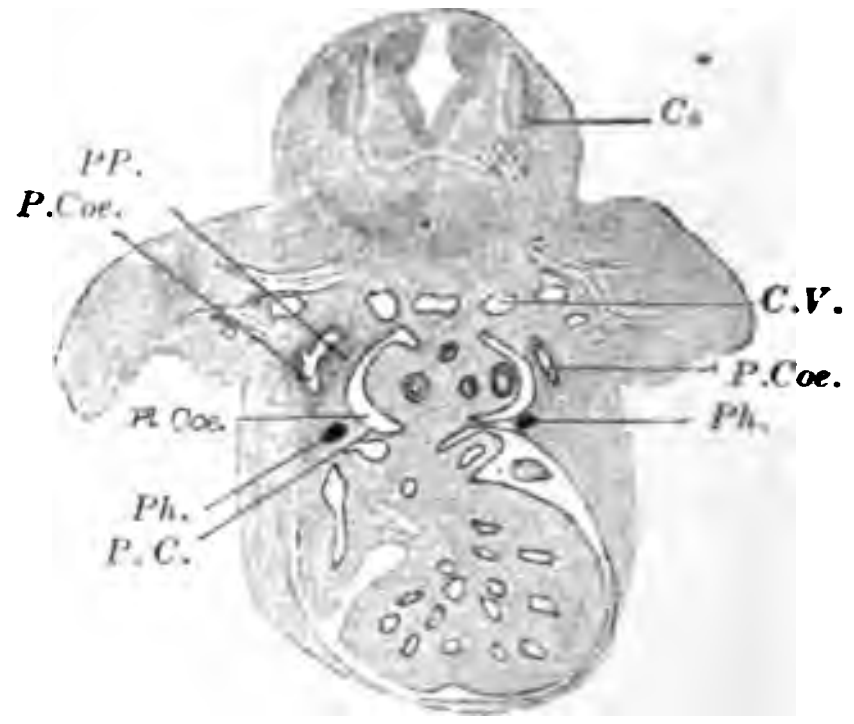

Fig. 409.—Section .16 mm. lower than Fig. 408. × 12 times. C_6, sixth cervical myotome; *C.V.*, cardinal vein; *Ph.*, phrenic nerve; *P.C.*, pleuropericardial membrane: *PP.*, pleuroperitoneal membrane; *Pl. Coe.*, pleural cœlom; *P. Coe.*, peritoneal cœlom.

shown in the three reconstructed figures as well as in the diagram (Fig. 400). As the pulmonary ridge widens, the lung buds become buried deeper and deeper in the body walls of the embryo, and as the liver gradually shifts with the rotation of the septum, the lungs are forced, step by step, to the side of the septum opposite the liver (Fig. 414). So, therefore, the lung which was in contact with the liver is shifted to the upper side of the septum by the widening of the pulmonary ridge and by the more rapid rotation of the dorsal end of the septum which carries the liver ventralwards.

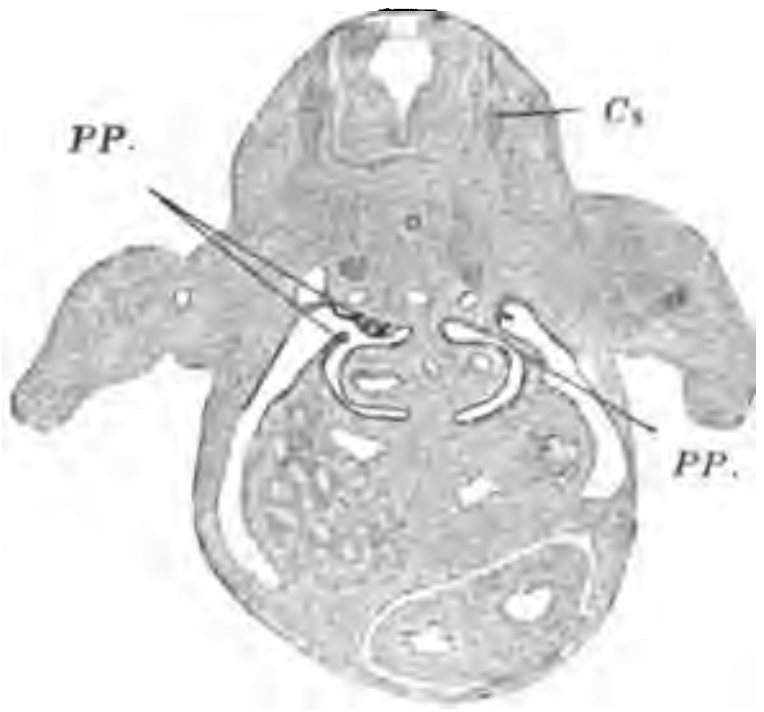

Fig. 410.—Section .16 mm. lower than Fig. 409. × 12 times. C_8, eighth cervical nerve; *PP.*, pleuroperitoneal membrane.

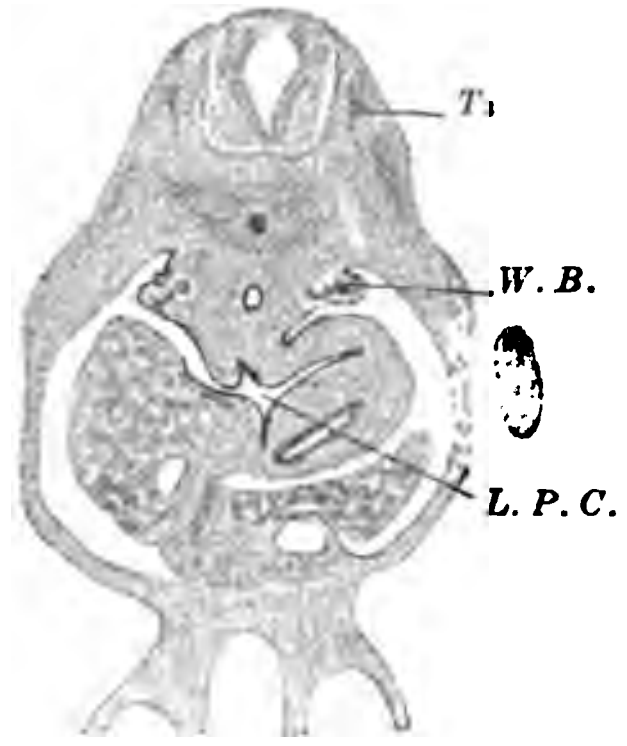

Fig. 411.—Section .84 mm. lower than Fig. 410. × 12 times. T_3, third thoracic myotome; *L.P.C.*, lesser peritoneal cavity; *W.B.*, Wolffian body.

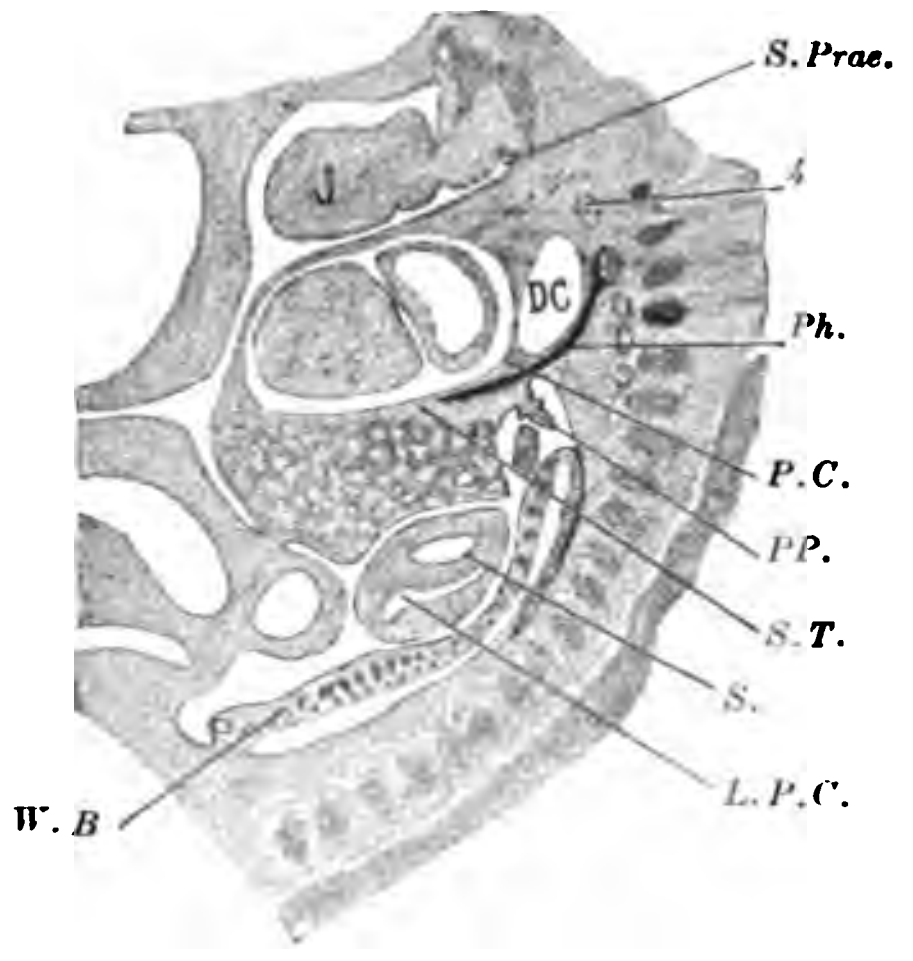

Fig. 412.—Sagittal section through an embryo 8 mm. long (No. 113). × 10 times. *J*, lower jaw; *S. Prae*, sinus præcervicalis; 4, fourth cervical nerve; *Ph.*, phrenic nerve; *S.T.*, septum transversum; *DC*, ductus Cuvieri; *P.C.*, pleuropericardial membrane; *PP.*, pleuroperitoneal membrane; *S.*, stomach; *L.P.C.*, lesser peritoneal cavity; *W.B.*, Wolffian body.

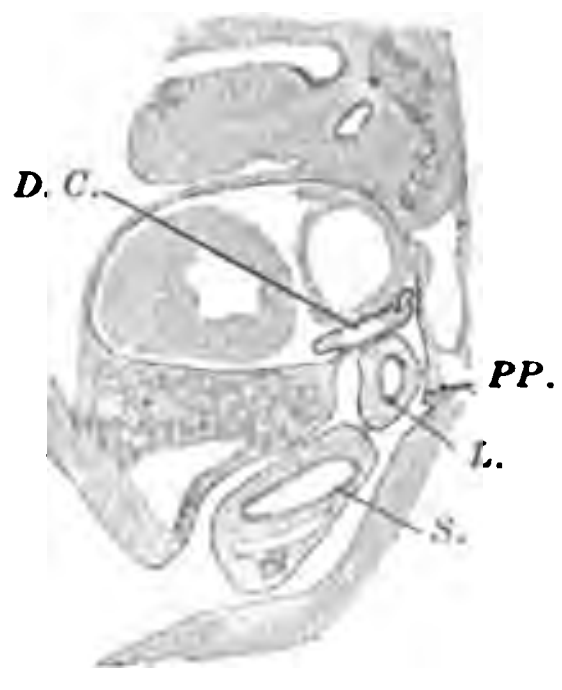

Fig. 413.—Section through the embryo from which Fig. 412 is taken, nearer the middle line. × 10 times. *D.C.*, ductus Cuvieri; *L.*, lung; *S.*, stomach; *PP.*, pleuroperitoneal membrane.

The sections of the embryo pictured in Fig. 407 are shown in Figs. 408–411. They do not include the communication between the pleural and pericardial cœloms. However, they show the position of the phrenic nerve, and this, because of its later position, indicates the extent of the pleuropericardial membrane. In Fig. 409 a cavity is seen dorsal and lateral to the pleural cœlom, and this burrowing continues until it approaches the pericardial cœlom, where a new membrane is formed, the membrana pericardiaco-peritonealis. This membrane is farther emphasized when the liver begins to separate from the septum transversum, leaving but a thin membrane between the pericardial and peritoneal cœloms.

Figs. 412 and 413 are from sagittal sections of an embryo about as large as the one pictured in Fig. 407. The phrenic nerve is shown throughout its whole course, from the fifth cervical nerve to the pleuropericardial membrane. Hanging from the pleuropericardial membrane a section of the pleuroperitoneal may be seen (Fig. 412), which extends around the lung and unites with the dorsal body wall (Fig. 413) immediately in front of the Wolffian body. About this time that portion of the pulmonary ridge destined to become the pleuropericardial membrane unites with the root of the lung and separates the pericardial space completely from the pleural. All this has just taken place in an embryo 11 mm. long and is shown in Figs. 414, 415, and 416. The plane of the pleuropericardial membrane is now practically that of the septum transversum, the two together being transverse to the long axis of the embryo. The course of the ductus Cuvieri is along the edge of the pleuropericardial membrane, and that of the phrenic nerve is well within it (Fig. 416).

FIG. 414.—Embryo 11 mm. long (No. 109). × 9 times. *Ph*, phrenic nerve; *L*, lung; *Li*, liver; *S*, stomach; *W*, Wolffian body.

The relation of the ductus Cuvieri to the point of closure between the pleural and pericardial cavity was first pointed out by His in 1881, and since then little has been added to our knowledge of the process by which the separation is made.

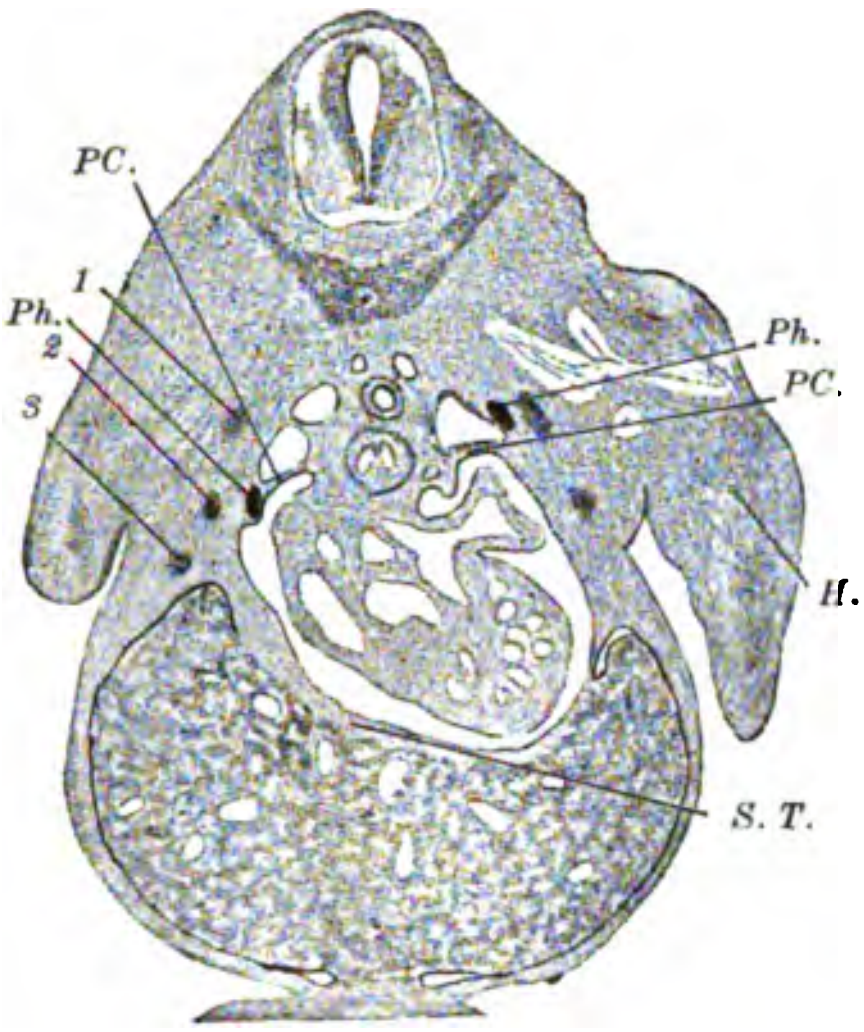

Fig. 415.—Section through the body of the same embryo shown in Fig. 414. × 10 times. *Ph.*, phrenic nerve; *PC.*, pleuropericardial membrane; *S. T.*, septum transversum; *H.*, humerus; 1, 2, 3, ribs.

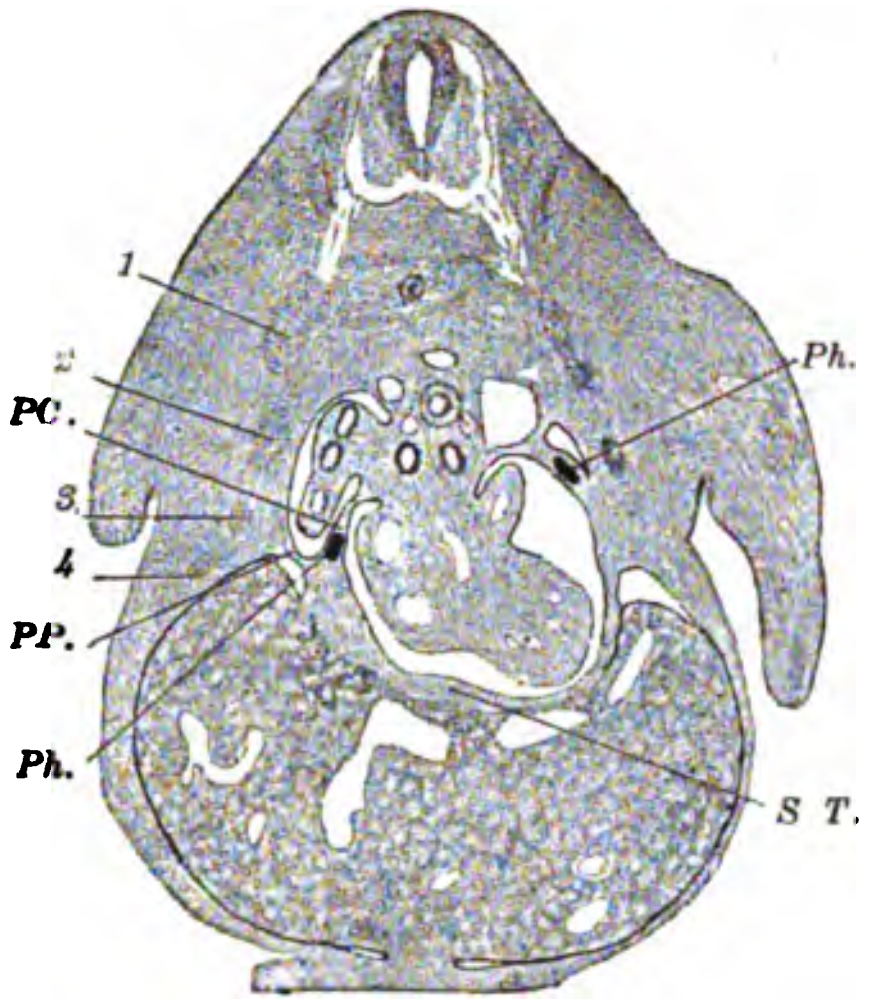

Fig. 416.—Section through the same embryo .18 mm. lower than Fig. 415. × 10 times. *Ph*, phrenic nerve; *S.T.*, septum transversum; *PC.*, pleuropericardial membrane; *PP.*, pleuroperitoneal membrane; 1, 2, 3, 4, ribs.

At the time of the closure the small ridge of tissue called the pleuropericardial membrane (Uskow) is very insignificant, its extension being due to a subsequent rapid growth of the lung. It is, however, to the credit of Brachet to have shown that the canal connecting the pleural and pericardial cavities is only constricted by the ductus Cuvieri, and that its complete closure is due to the active growth of the anlage of the pleuropericardial membrane.

After the pericardial cavity is fully isolated the pulmonary ridge spreads out rapidly over the lung buds (Fig. 414) and forms an incomplete membrane at its lower tip, through which the pleural and peritoneal cavities communicate for some time longer. This membrane—the pleuroperitoneal membrane of Brachet—soon forms a <-shaped figure, with the pleuropericardial

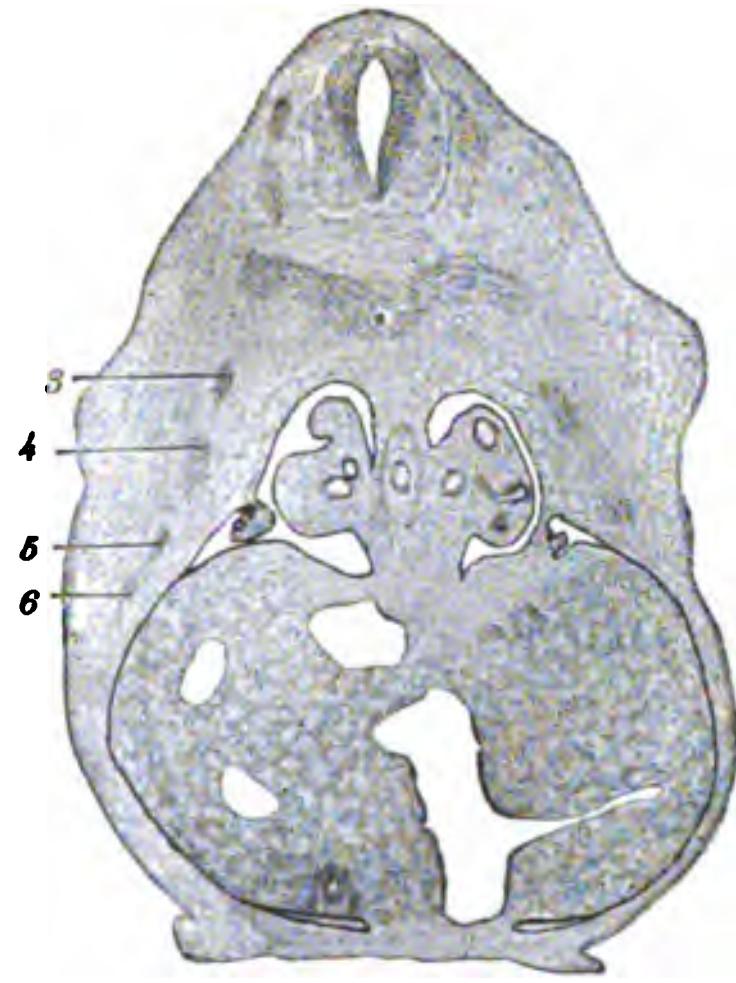

Fig. 417.—Section .46 mm. lower than Fig. 415. × 10 times. The pleuroperitoneal membrane is incomplete on one side; 3, 4, 5, 6, ribs.

membrane above and the septum transversum on its ventral side. On its dorsal it is closely related to the Wolffian body, whose descent it follows closely. Before this membrane is completed there must be added to it the ridge of tissue from the septum transversum to the Wolffian body, described by Uskow as the dorsal pillars of the diaphragm. The true nature of these pillars and their relation to the permanent diaphragm was finally determined by Ravn and Brachet, and by Swaen for the human embryo.

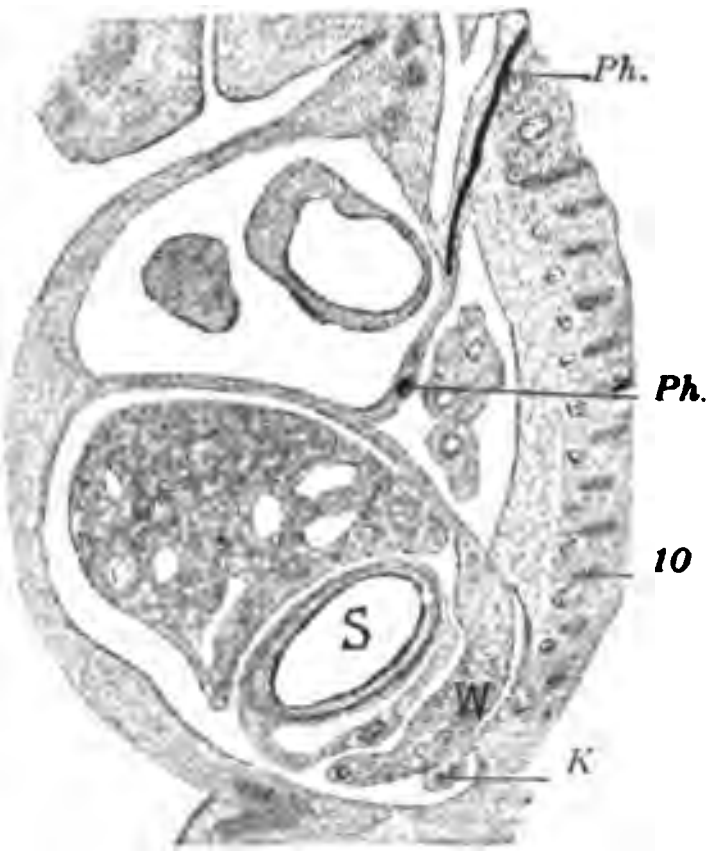

FIG. 418.—Sagittal section through an embryo 14 mm. long (No. 144). × 10 times. *Ph.*, phrenic nerve; 10, tenth rib; *S*, stomach; *K*, kidney; *W*, Wolffian body.

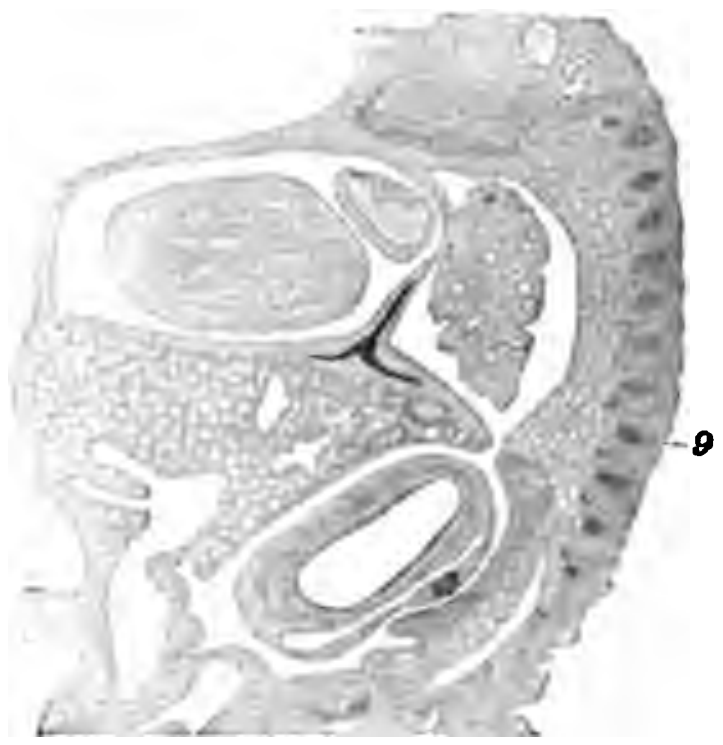

FIG. 419.—Sagittal section through an embryo 16 mm. long (No. 43). × 8 times. 9, ninth rib.

In a human embryo 11 mm. long, immediately after the completion of the pleuropericardial membrane, it is seen that the rotation of the liver and septum transversum is accelerated, and that the pleuroperitoneal membrane extends rapidly down into the thorax as the Wolffian body recedes. (Compare Figs. 407 and 414.)

FIG. 420.—Transverse section through an embryo 19 mm. long (No. 74). × 10 times. 7, seventh rib. The pleuroperitoneal membrane, *PP.*, is incomplete on one side.

The ≺-shaped section of the septum transversum and pleuropericardial and peritoneal membranes (Fig. 414) is soon changed by the growth of the lung and the shifting of the diaphragm (Figs. 417 and 418), which gradually places the pleuropericardial membrane at right angles to the diaphragm. The opening behind the pleural and peritoneal cavities gradually becomes smaller and smaller (Fig. 419), closes first on the right and then on the left side (Fig. 420); usually both membranes are complete in embryos 19 mm. long.

As the lungs invade the thorax in the wandering of the diaphragm they must carry their surrounding pleural space with them, which calls for a radical shifting of the mesenchyme between the parietal pleura and the ribs. In fact there is a great mass of mesenchyme just at this point (Figs. 417 to 420), which in embryos at this stage has many unusually large spaces in it indicating that they are normal tears. After the diaphragm has reached its permanent position and the lungs begin to grow relatively larger, they encroach upon this tissue and it is reduced in quantity to make room for them. The lung also burrows between the pleuropericardial membrane and the main body wall, increases the extent of the membrane, and pushes it with its inclosed phrenic nerve to the medial side of the lung, between it and the heart.

To what extent the permanent diaphragm is formed from the pleuroperitoneal membrane is difficult to determine. It is probable that the portion dorsal to the attachment of the pleuropericardial membrane of the septum transversum is formed by the pleuroperitoneal membrane. At any rate, the point of entrance of the phrenic nerve may be viewed as the most fixed point, one difficult to shift, for it is closly associated with the muscle of the diaphragm which invades the septum transversum when it is still high in the neck of the embryo. However, this kind of reasoning is not altogether sound and should be taken with some reserve. The shifting of large masses of organs, their power to burrow and extend as the lung does around the heart, and the fact that the liver grows into the pleuroperitoneal membrane (Fig. 418) while it is being separated from the septum transversum on its ventral side (Fig. 417), should make us somewhat reserved in our statements regarding the origin of the dorsal and ventral diaphragms. In reality we have gotten but a little further than to confirm His, who stated that the septum transversum is extended dorsally and separates the pleural from the pericardial and peritoneal cavities. Defining the septum transversum as he did, proved to be the foundation-stone of all subsequent study regarding the separation of the body cavities.

The cœlom cavities of the myotomes are in general independent of the peritoneal cavity in man, with the exception of the second, which, according to Keibel and Elze, communicate with this cavity in an embryo 1.38 mm. long. These cavities of the myotomes are well developed in embryos 2 mm. long, but after this stage they soon disappear.

The diverticulum of the cœlom into which the testis wanders begins to form as the Wolffian body atrophies during the third month of pregnancy. At first there is an evagination of the abdominal wall in the inguinal region, forming the inguinal bursa, which is lined by a sac of peritoneum, the vaginal process. This in turn sinks into the embryonic scrotum, which has formed independently. Soon the bursa is partly filled again by a marked thickening of its apex to form the conus inguinalis or gubernaculum, which continues into the genito-inguinal ligament to the testis. During the seventh month the final descent of the testis takes place. At this time the bursa becomes markedly enlarged, the conus retracts, and the testis moves into the embryonic tunica vaginalis, which becomes completely separated from the peritoneal cavity at about the time of birth.

A similar but much less marked process takes place in the female. In the case of the ovary the migration is slight, although provision for the descent has been made in the formation of both inguinal bursa and ligament. The lumen of the vaginal process usually disappears, but may remain open to form what is known as the diverticulum of Nuck.

In not all cases does the testis enter the inguinal bursa, but instead remains in the abdominal cavity or within the inguinal canal. In other cases the processus vaginalis does not close after the descent of the testis and some of the abdominal viscera may enter the canal, forming congenital inguinal hernia. A similar hernia of the diaphragm may occur when the communication between the pleural and peritoneal cœlom is not completely cut off. This kind of anomaly is much more common in the left side of the body than on the right, probably on account of the corresponding unequal growth of the liver on the two sides of the body. Congenital hernia may also occur in the umbilical cord when the cœlom of the cord is not obliterated after the intestine returns from it into the abdominal cavity. In case the opening with the exocœlom of the cord is very large, most of the abdominal viscera —liver, spleen, large and small intestines—may extend into it. In such cases the extruded viscera are covered only by a thin membrane composed of peritoneum and amnion.

There remains still one very fundamental pocket of the peritoneal cœlom; it is, the pocket which forms the lesser peritoneal cavity. This pocket, the bursa omentalis, was first recognized in the embryo by His, and later Ravn discovered that it developed not only on the right side of the body but on the left side also, and that the cephalic tip of the right cavity separated and formed one of the serous spaces which comes to lie in the region of the right lung. More recently the development of the lesser peritoneal cavity in man has been studied by Swaen and by Broman. Broman's admirable study is comparative and includes numerous human embryos; he confirms for the human embryos Ravn's discoveries in the rabbit, mentioned above.

In an embryo 3 mm. long there are two peritoneal pockets on either side of the œsophagus, the right being somewhat larger than the left. The left is of but short duration in the human embryo; it evaginates, Broman believes, but the right, the recessus pneumato-entericus dexter, is closely associated with the lesser peritoneal cavity. Just below this recess there is another depression (Fig. 396, below *FW*), the recessus mesenterico-entericus of Swaen, which soon extends between the stomach and liver and later gives rise to the omental bursa.

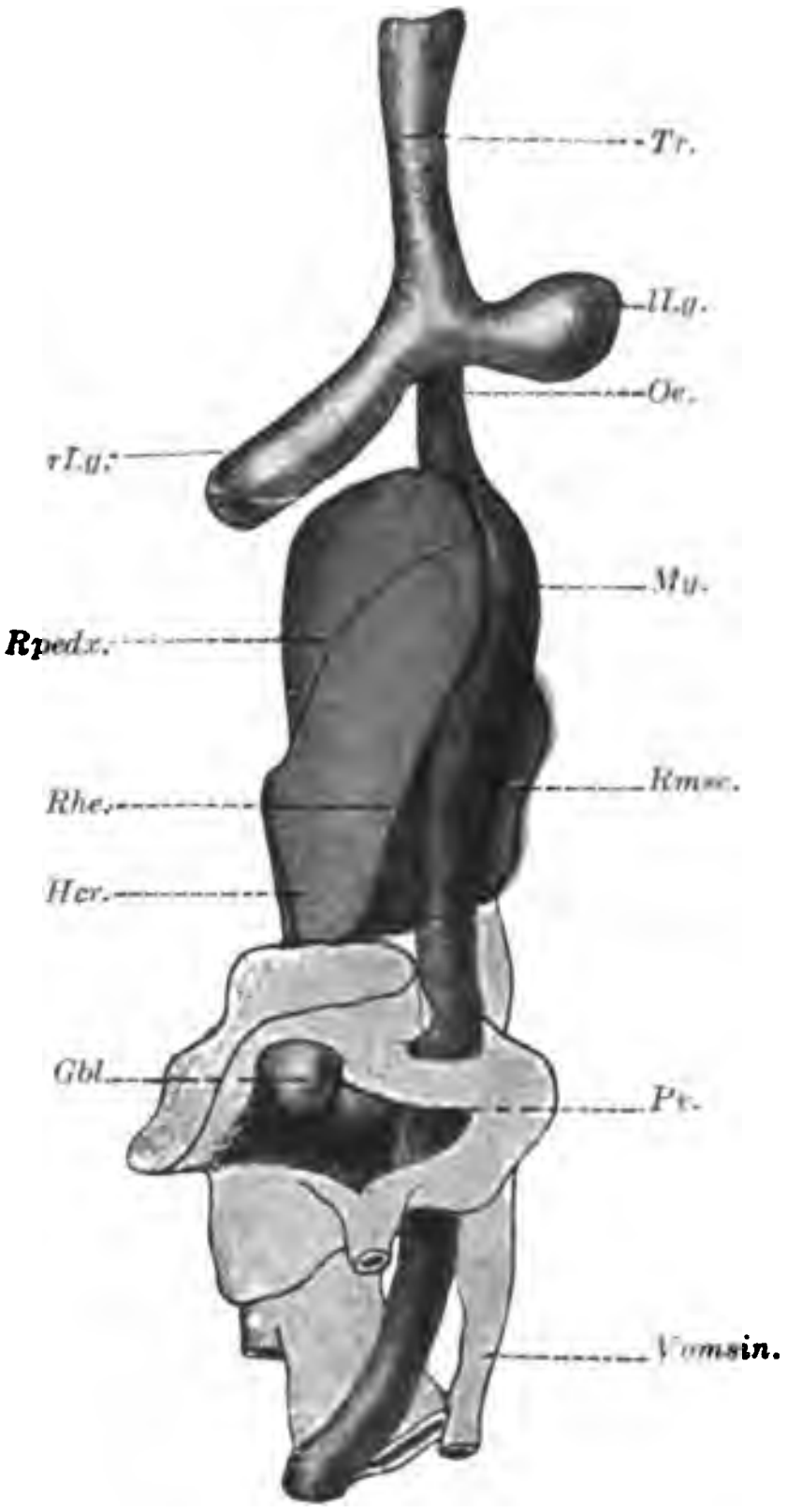

Fig. 421.—Cast of the lesser peritoneal cavity encircling the intestine, from a human embryo 5 mm. long. (After Broman.) *Rpedx.*, recessus pneumato-entericus dexter; *Rmse.*, recessus mesenterico-entericus; *Rhe.*, recessus hepato-entericus; *Hcr.*, hiatus communis recessuum.

A reconstruction of the right recess, in an embryo 5 mm. long, is shown in Fig. 421. The upper recess (*Rpedx*) reaches to the lung bud of the right side, the dorsal recess extends into the mesentery of the stomach, and the ventral recess, recessus hepato-entericus, borders on the liver and later encircles the Spighelian lobe. Below they communicate with the peritoneal cavity through the hiatus communis recessuum (*Hcr*) or the primitive foramen of Winslow. Sections through the hiatus may be seen in three different stages in Figs. 393, 405, and 411. As the stomach grows and bends to the left, it gradually gives form to the lesser peritoneal cavity, as is shown by a cast of it from an embryo 11.7 mm. long (Fig. 422). It is easily seen that the hiatus of Fig. 421 has become the true foramen of Winslow, the recessus hepato-entericus has become the cavity of the lesser omentum (*Bomin*), and the recessus mesenterico-entericus has become the cavity of the greater omentum (*Bomaj*). The cavity of the greater omentum is formed, according to Swaen, by a burrowing of the cavity into the wall of the stomach, and not by a simple bend of its mesentery, as is indicated, for instance, in Fig. 411. According to the B.N.A., the bursa omentalis is divided into a vestibulum and a recessus superior, which form together Broman's bursa omenti minoris, and a recessus inferior, which is the same as the bursa omenti majoris. In my opinion, it would be better to apply the terms of the B.N.A. to these spaces in the embryo as soon as their fate is clear. For the same reason I have used the term pericardial cavity in describing the smallest embryos, for the relation of this space to the heart enables us to identify it. Additional unnecessary names only complicate the subject.

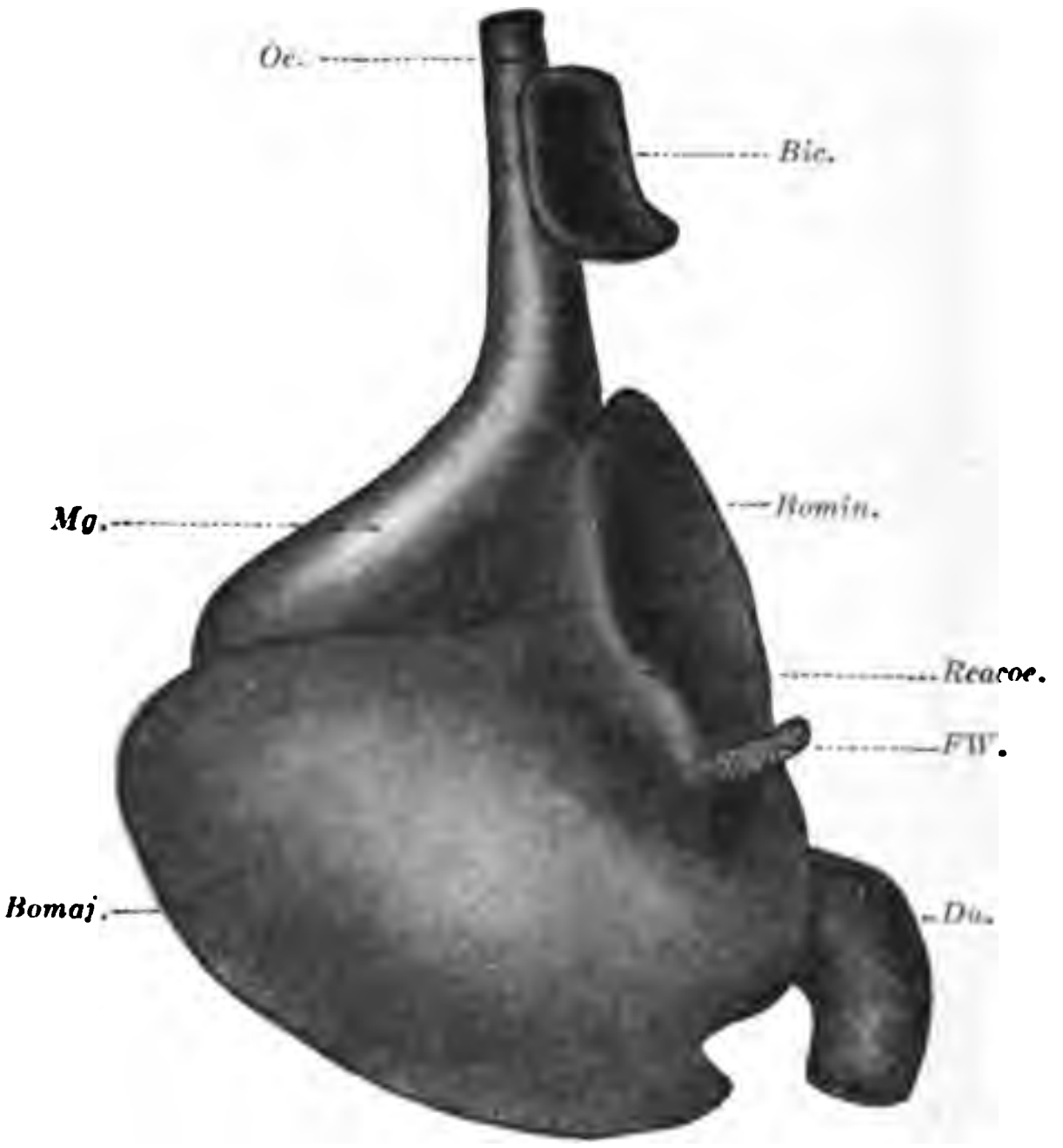

Fig. 422.—Cast of the lesser peritoneal cavity from an embryo 11.5 mm. long. (After Broman.) *Bomin.*, bursa omenti minoris; *Bomaj.*, bursa omenti majoris; *Rcacoe.*, atrium bursa omentalis; *FW.*, foramen of Winslow; *Bic.*, bursa infracardiaca.

According to Broman, the recessus pneumato-entericus of Ravn extends upward in the human embryo to the bifurcation of the lungs. By the time the embryo is 11 mm. long, the recessus pneumato-entericus begins to separate from the lesser peritoneal cavity and is soon pinched off to form the bursa infracardiaca, as shown in Fig. 422. From now on, it can be found in all embryos as a closed sac lying between the right side of the œsophagus and the diaphragm. It gradually grows in size and is about one centimetre in diameter at birth; in a specimen from an adult man (Fig. 423, *Bic*) it measures 42 x 20 mm. This third pleural cavity, very well developed in all animals which have an infracardial lobe of the lung, is therefore found in all human embryos and probably also in most adults. Its frequency will have to be established by statistics.

The various body cavities communicate freely with one another in all vertebrate embryos. In later stages this primitive cavity is divided into several compartments by the formation of the septa described above. Only in Myxine does it remain single, while in Petromyzon the division takes place at the time of metamorphosis.

In selachians the pericardial cavity becomes separated completely from the remaining peritoneal cavity by the septum pericardiacoperitoneale. This membrane is present also in ganoids and teleosts, but as yet it has not been studied carefully.

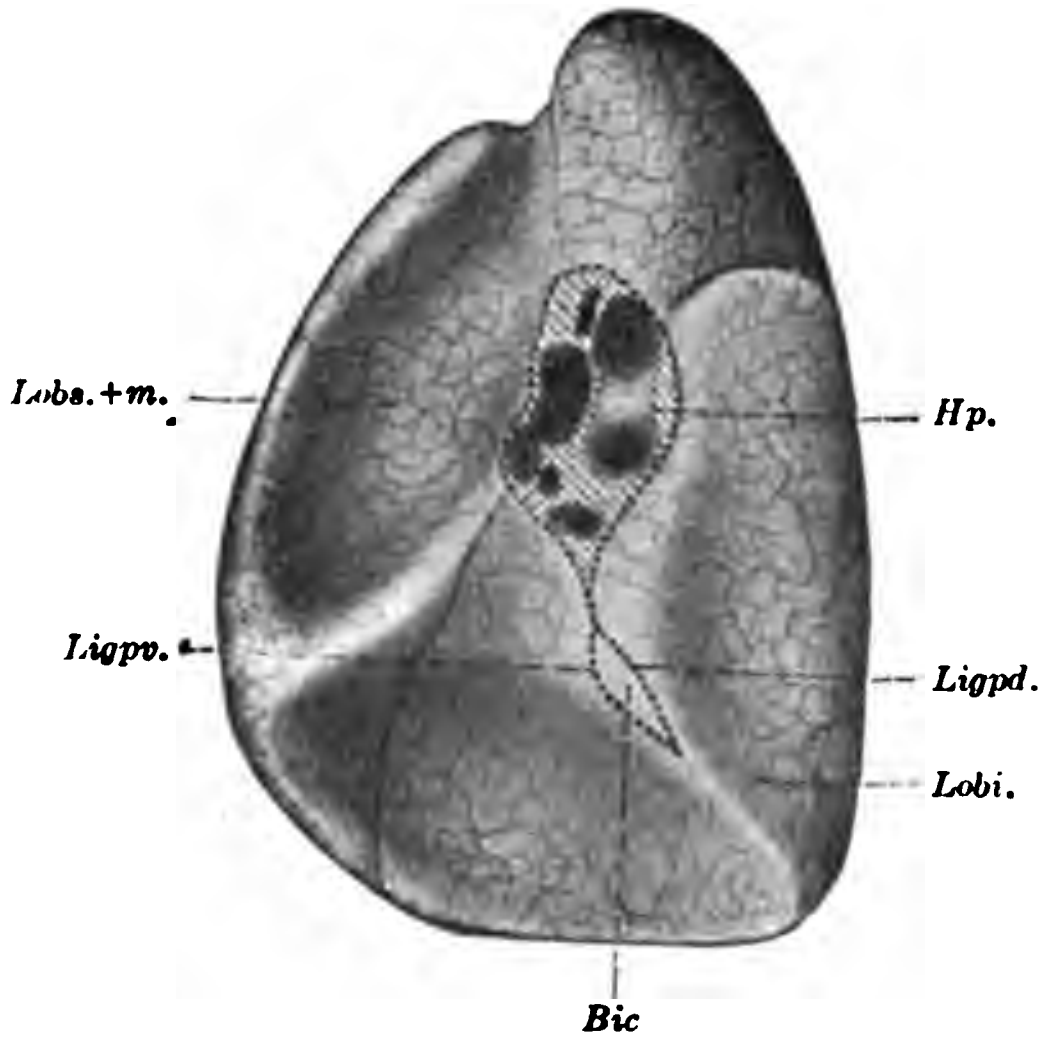

FIG. 423.—Right lung of an adult man showing the bursa infracardiaca, *Bic*. (After Broman.)

Independent pleural cavities are not found in amphibians nor in most reptiles; in birds, however, there is always a complete pleuroperitoneal membrane present. The process of the subdivision of the cœlom is far more complex in mammals than in the remaining vertebrates. In them the septum pericardiacoperitoneale is called the septum transversum, from the dorsal end of which both the pleuropericardial and pleuroperitoneal membranes arise. A chief difference between mammals, on the one hand, and birds, reptiles, amphibia, and fishes, on the other, is the very early formation of the septa in the former and their late appearance in the latter.

LITERATURE.

BONNET: Beiträge zur Embryologie der Wiederkäuer, Arch. für Anat. und Physiol., Anat. Abt., 1889.

BRACHET: Die Entwicklung der grossen Körperhöhlen und ihre Trennung voneinander, Ergebnisse der Anat. und Entwicklungsgesch., Bd. 7, 1897.

Bulletin de l'Académie Royale de Médecine. Vol. xix. Bruxelles, 1906.

Broman: Beschreibung eines menschlichen Embryo von beinahe 3 mm. Länge, Morphol. Arbeiten, Bd. 5, 1894.
  Entwicklung des Zwerchfelles beim Menschen, Verhandl. d. anat. Gesellsch., 1902.
  Die Entwicklungsgeschichte der bursa omentalis, Wiesbaden, 1904.
Bryce and Teacher: Contribution to the Study of the Early Development and Imbedding of the Human Ovum, Glasgow, 1908.
Dandy: A Human Embryo with Seven Pairs of Somites, Measuring About 2 mm. in Length, Amer. Journ. of Anatomy, vol. 10, 1910.
Herzog: Contribution to Our Knowledge of the Earliest Known Stages of Placentation and Embryonic Development in Man, Amer. Journ. of Anatomy, 1909.
His: Anatomie der menschl. Embryonen, Heft 1, 1880.
  Mitteilung zur Embryologie der Säugetiere und des Menschen, Arch. f. Anat. u. Physiol., Anat. Abt., 1881.
Hochstetter: Die Entwicklung des Blutgefäss-Systems, Hertwig's Handb. d. vergleich. und exper. Entwickl. d. Wirbeltiere, Bd. 3, 1906.
Keibel: Menschenaffen, IX. Lieferung von Selenka's Werk, Wiesbaden, 1906.
Keibel und Elze: Normentafeln zur Entwickl. d. Wirbeltiere (Mensch), Heft 8, 1908.
Klaatsch: Uber den descensus testiculorum, Morph. Jahrbuch, Bd. 16, 1890.
Kölliker: Entwicklungsgeschichte des Menschen, Leipzig, 1879.
Mall: Development of the Lesser Peritoneal Cavity in Birds and Mammals, Journ. of Morphol., vol. 11, 1891.
  Development of the Human Cœlom, Journ. of Morphol., vol. 12, 1897.
  Supplementary Note on the Development of the Human Intestine, Anat. Anz., Bd. 16, 1899.
  Contribution to the Study of the Pathology of Human Embryo, Johns Hopkins Hospital Rep., vol. 9, 1900, and Journ. of Morph., vol. 19, 1908.
  On the Development of the Human Diaphragm, Johns Hopkins Hospital Bulletin, vol. 12, 1901; and Proceedings of Amer. Assoc. Anatom., vol. 5, Washington, 1901.
Mazilier: Contribution de l'embryologie du diaphragma, Lille, 1907.
Müller, E.: Beiträge der Anatomie des menschlichen Fetus, Kgl. Schwedische Akademie, Bd. 29, 1897.
Muller, I.: Uber den Ursprung der Netze, Meckel's Arch., 1830.
Piersol: Human Anatomy, Philadelphia, 1907.
Piper: Uber ein im Ziegler'schen Atelier hergestelltes Modell eines menschlichen Embryos von 6.8 mm. Nackenlinie, Anat. Anz., Bd. 21, 1902.
Ravn: Uber die Bildung der Scheidewand zwischen Brust- und Bauchhöhle in Säugetierembryonen, Arch. f. Anat. u. Physiol., Anat. Abt., 1889.
Retzius: Biolog. Untersuch., Bd. 1, 1890.
Spee, Graf v.: Beobachtungen an einer menschlichen Keimscheibe mit offener Medullarrinne und canalis neurentericus, Arch. f. Anat. u. Physiol., Anat. Abt., 1889.
Strahl: Beiträge zur Entwicklungsgeschichte des Herzens und der Körperhöhlen, Arch. f. Anat., 1889.
Swaen: Recherches sur le développement du foi, Journ. d'Anat. et de Physiol., vol. 33, 1897.
  Note sur la Topographie des Organs abdominaux, Bibliog. Anat., 1899.
Toldt: Uber die Geschichte der Mesenterien, Verhandl. d. Anat. Gesellsch., 1893.
Uskow: Uber die Entwicklung des Zwerchfells, des Pericardiums und des Cöloms, Arch. f. mikr. Anat., 1883.
Velpeau: Embryologie ou Ovologie humaine, etc., Paris, 1833.
Waldeyer: Lehrbuch der topographisch-chirurgischen Anatomie, Bonn, 1899.